

A cross-sectional study of long-term satisfaction after surgery for congenital syndactyly: does skin grafting influence satisfaction?

Journal of Hand Surgery
(European Volume)
2019, Vol. 44(3) 296–303
© The Author(s) 2018



Article reuse guidelines:
sagepub.com/journals-permissions
DOI: 10.1177/1753193418808183
journals.sagepub.com/home/jhs



Bien R. Ferrari and Paul M.N. Werker

Abstract

Syndactyly correction without skin grafting is advocated because it prevents graft-related complications and donor site morbidity. In this cross-sectional study, we compared satisfaction among patients who underwent correction with and without skin grafting to determine preference based on subjective and objective parameters. Retrospective chart analysis was performed among 27 patients (49 webs) who were seen at follow-up after a median follow-up period of 7.4 years, at which the Patient and Observer Scar Assessment Scale, the Withey score and a satisfaction survey were used. Notably, there were no significant differences in complication rates or observer rated scar scores. Although the need for an additional surgical procedure was higher after skin grafting, patient-rated satisfaction scores were similar irrespective of the use of grafting. Our data suggest that corrections can best be performed without skin grafts if seeking to minimize the need for an additional procedure, but that the use of skin grafts does not appear to affect patient satisfaction.

Level of evidence: IV

Keywords

Syndactyly, skin grafts, web creep, congenital hand surgery, patient satisfaction

Date received: 2nd March 2018; revised: 26th September 2018; accepted: 29th September 2018

Introduction

Syndactyly is a congenital malformation in which there is unification of at least two adjacent digits (Flatt, 2005; Netscher, 1998). It is a heterogeneous disorder that has highly variable subtypes (Malik, 2012). Clinically, the union or webbing is typically classified based on complexity (i.e. simple, complex or complicated) and completeness (i.e. incomplete or complete). Simple syndactyly involves a connection between soft tissues only, whereas complex syndactyly involves the interconnection of osseous tissue (i.e. distal phalanges). By contrast, complicated syndactyly implies the presence of bony abnormalities, such as interposing accessory phalanges or missing phalanges, which increase the risk of neurovascular abnormalities (Flatt, 1974; Van der Biezen and Bloem, 1994). Complicated syndactyly is a broad category but is common in constriction ring syndrome and Apert syndrome (Braun et al., 2016; Ciurea and Toader, 2008; Kozin, 2001).

Surgical treatment is nearly always indicated for syndactyly because the improved functional outcomes associated with separation generally outweigh the risks of surgery (Kay et al., 2017; Oda et al., 2010). Over time, different techniques have been developed based on general principles (Flatt, 2005; Kvernmo and Haugstvedt, 2013). Interdigitating zig-zag flaps based on Cronin's technique, first described in 1957, remain the preferred method of digit separation, with web space reconstruction usually performed via a proximally based dorsal flap. However, when two digits are separated, they have circumferences that are approximately 22% larger

University Medical Centre Groningen, University of Groningen, Groningen, The Netherlands

Corresponding Author:

Bien R. Ferrari, Department of Plastic Surgery, University Medical Centre Groningen, University of Groningen, HPC BB81 P.O. Box 30.001, 9700 RB Groningen, The Netherlands.
Email: bien.ferrari@gmail.com

than in the fused state (Kozin and Zlotolow, 2015). Although potential flap tension can be reduced by removing excess fat before closure (Flatt, 2005; Kozin, 2001), there remains a serious risk of having insufficient skin to close any remaining defects, especially immediately distal to the newly created web (Braun et al., 2016). Different techniques are therefore used to provide sufficient skin, with some involving skin grafts and others avoiding them entirely.

When grafting is performed, full-thickness skin grafts (FTSGs) are preferred by most surgeons because split-thickness skin grafts (STSGs) may cause the resulting web to 'creep' distally due to scar contraction (Flatt, 2005). Full thickness skin grafts are frequently harvested from the distal wrist or groin, and despite their widespread use, have some notable drawbacks. Complications include incomplete take at the recipient site, hyperpigmentation, hair growth and donor site scarring (Deunk et al., 2003; Kozin and Zlotolow, 2015; Oda et al., 2010; Sykes and Percival, 1989). Graft-less techniques have therefore been developed to avoid these complications. For example, Niranjani and de Carpentier (1990) designed a dorsal trilobed flap for web space construction of the proximal cleft. Though many variations of dorsal flaps have since been described, this was the first to avoid using skin grafts. Since then, Giele and Cassell, 2008 described using a rectangular-shaped flap with two triangular-shaped sides, while Magdi Sherif (1998) described a V-Y dorsal metacarpal perforator flap. More recently, Ni et al. (2015) used the hourglass dorsal advancement flap for web space construction. The main disadvantage of these techniques, however, is that they often result in larger scars on the dorsum of the hand (Magdi Sherif, 1998).

When comparing skin graft techniques to graft-less techniques, the latter have been found to cause fewer complications and prevent the need for additional procedures (Magdi Sherif, 1998; Sullivan and Adkinson, 2017; Sykes and Percival, 1989). Sullivan and Adkinson (2017) performed a systematic review comparing complications and results between skin grafts and the dorsal metacarpal advancement flap. They found a significantly higher incidence of web creep in the skin graft group ($p \leq 0.05$). However, they only included cases of simple syndactyly. For the reasons mentioned above, graft-less techniques are employed whenever possible. However, skin grafts are still widely used and will probably always have a place in the surgical repertoire, especially for treating complex or complicated syndactyly. In our literature review, we did not identify any long-term studies comparing patient satisfaction after surgery using skin grafts and graft-less techniques. Thus, it is unconfirmed

whether graft use affects patient satisfaction after surgical correction of syndactyly.

We compared the outcomes of surgery for congenital syndactyly release between patients treated with skin grafts and those treated with graft-less techniques. Complication rates, long-term scar quality, web creep and patient or parental satisfaction were compared.

Methods

Study design

This was a cross-sectional study of patients who underwent primary release for congenital syndactyly and who were invited for follow-up at our institution between 2000 and 2016. The local Medical Ethical Committee determined that this study fell outside the scope of the Medical Research Involving Human Subjects Act. All participants were required to provide written informed consent.

All traceable patients were approached (we excluded deceased patients) and relevant details were collected from their medical and surgical records. Specifically, we collected data on the following: sex; age; age at the time of surgery; time between surgery and data analysis; concomitant syndromes; type of syndactyly; extent of the webbing; hands affected (left, right or both); synonychia; design for web space construction; STSG or FTSG (if used); donor site; and complications (e.g. infection, neurovascular damage, partial or total graft failure, hypertrophic scarring, scar contractures, web creep and extent, revision surgery and number of revision procedures). These data were collected out of the medical records, as reported during postoperative visits at our outpatient clinic, not specifically at scheduled intervals. During the follow-up assessments, questionnaires were used to measure three main outcomes of interest: long-term postoperative success from the observer's perspective; scar quality from the patients' and the observer's perspectives; and satisfaction with surgical outcomes from the patients' perspectives. An independent observer performed all follow-up examinations.

For analysis, patients were retrospectively divided into a group that received skin grafts (the graft group) and a group that underwent graft-less procedures (the graft-less group).

Surgical technique

The standard procedure for syndactyly release consisted of interdigitating zig-zag flaps to separate the

digits, with defatting performed before closure. Web spaces were constructed with either a dorsal rectangular flap or a design that redistributed the dorsal skin, such as the trilobed flap (Niranjan and de Carpentier, 1990) or Giele's flap (Giele and Cassell, 2008). If skin grafts were used, our preference was for FTSG, with the groin as the donor site. If synonychia was present, the nail walls were constructed using skin flaps from the distal pulp. The retrospective design meant that we could not determine the rationale for using skin grafts or graft-less techniques.

Questionnaires

Three questionnaires were used, as follows: long-term results were assessed using the Withey score for postoperative success (Withey et al., 2001); scar quality was assessed using the Patient and Observer Scar Assessment Scale (POSAS) (Draaijers et al., 2004); and patient satisfaction with surgical outcomes was assessed using a visual analogue scale (VAS).

The Withey score for postoperative success was completed by the independent observer (Withey et al., 2001). Specifically, scar quality, flexion-extension deformity, web creep, lateral flexion deformity and rotation deformity were rated (Table 1).

The POSAS, originally developed by Draaijers et al. (2004), has been shown to be a reliable and validated

scale for assessing post-surgical scars in patients aged ≥ 15 years (Truong et al., 2007; Tyack et al., 2012; van de Kar et al., 2005). The patient and observer scales each consist of six parameters: the patient scale includes pain, itching, colour, pliability, thickness and relief; the observer scale includes vascularity, pigmentation, thickness, relief, pliability and surface area. Each item is scored from 1, indicating 'normal skin', to 10, indicating the 'worst imaginable scar'. The totals for each item are then added to give a total scar grade that is in the range of 6–60. The validated Dutch language version was used (Draaijers et al., 2004). We asked the parent or patient (if aged ≥ 15 years) to complete the patient scale for each constructed interdigital space. The independent observer completed the observer scale for each separated web.

A VAS (from 0 to 10) was used to assess patient satisfaction, with 0 corresponding to total dissatisfaction and 10 to ultimate satisfaction. If the patient was aged < 15 years, the VAS was completed by a parent to retain consistency with the validated age for the POSAS. The VAS was used to rate digital function, scar aesthetics, web space aesthetics, digit contours and overall satisfaction. If skin grafts were used, and/or synonychia was present before surgery, patients were asked to rate their satisfaction with nail wall construction, recipient site scarring and donor site scarring. Given that this survey was used to assess

Table 1. Withey score for postoperative success.

Parameter	Grade	Description
Scar quality	1	Thin and narrow
	2	Wide and flat
	3	Raised and thick
Flexion-extension deformity	0	Normal digit
	1	Finger cannot be hyperextended
	2	Finger has a fixed flexion deformity
Web creep	0	Soft web, abduction mirrors the adjacent web or equivalent web on the other hand
	1	No web advancement, but thickening of the web with reduced span
	2	Creep of web to one-third of the distance between base of the web and PIPJ crease
	3	Creep of web to two-thirds of the distance between base of the web and PIPJ crease
	4	Creep of web to the PIPJ crease
Lateral flexion deformity	0	Absent
	1	Present
Rotation deformity	0	Absent
	1	Present

PIPJ: proximal interphalangeal joint (Withey et al., 2001).

overall satisfaction with outcomes, only one questionnaire was completed per patient.

Statistical analysis

Although all data were included in the descriptive statistics, to fulfil the assumption of independence, only one web, randomly selected by throwing a dice, was included per patient in the statistical analysis. One questionnaire was completed per released web, except for the VAS. If the patient had received a graft for a web reconstruction, even if they had undergone other surgery without grafting, that patient was analysed as part of the graft group for the assessment of patient satisfaction. Cases of acrosyndactyly were excluded from the analysis of web-related outcomes.

Data are reported as medians and interquartile ranges (IQRs) or as absolute numbers, unless

otherwise stated. Mann–Whitney *U* tests were used to compare continuous data between the graft group and the graft-less group. Chi-square or Fisher’s exact tests were used for the analysis of all other data.

Results

Out of 55 patients, 27 patients with 49 webs were traced for follow-up and seen at our outpatient clinic. The other patients were either deceased, had no interest in participating or had invalid contact details (Figure 1).

Of the 49 included webs, 27, seven and 15 were classified as simple, complex and complicated, respectively. Among the simple syndactylies, 13 had incomplete webbing and 14 had complete webbing. Concomitant syndromes included constriction ring syndrome and Poland syndrome. The median follow-up time after surgery was 7.4 years (IQR 5.1–12.6). Skin grafts were applied to 19 of the 49 web spaces that underwent correction, of which one suffered from graft failure. The groin was the most frequently used donor site for FTSG, but STSG was used two times. The age of the patient at the time of surgery was significantly younger in the graft group ($p = 0.019$) (Table 2).

Four patients were aged ≥ 15 years at follow-up and were eligible to complete the questionnaires independently.

Complications noted in the files

There were two perioperative complications: one nerve laceration that was repaired immediately and one wound infection that was treated with antibiotics.

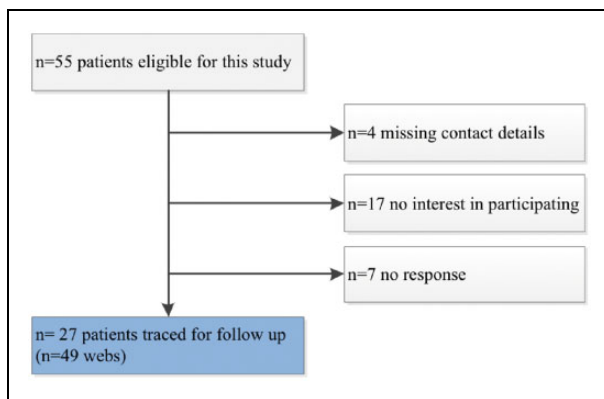


Figure 1. Exclusion flow chart.

Table 2. Baseline characteristics.

	All webs				Randomly selected webs				<i>p</i>
	Graft-less (n = 30)		Skin graft (n = 19)		Graft-less (n = 15)		Skin graft (n = 12)		
	N	IQR (%)	N	IQR (%)	N	IQR (%)	N	IQR (%)	
Age at surgery (years)	1.4	1.0–1.8	0.7	0.7–1.9	1.2	1.0–1.9	0.9	0.5–1.1	0.019 ^a
Follow-up (years)	6.8	4.4–12.3	12.1	6.2–14.1	7.3	5.2–12.3	8.9	2.9–12.5	0.782 ^b
Type of syndactyly									0.723 ^c
Simple	17	56.7	10	52.6	10	66.7	8	66.7	
Complex	3	10.0	4	21.1	1	6.7	2	16.7	
Complicated	10	33.3	5	26.3	4	26.7	2	16.7	
Acrosyndactyly	5	16.7	0	0	2	13.3	0	0	0.487 ^c

^aStatistically significant $p < 0.05$.

^bCalculated by Mann–Whitney *U* test.

^cCalculated by Fisher’s exact test.

N: absolute number or median; IQR: interquartile range.

Table 3. Complications and additional procedures.

	All webs		Randomly selected webs		<i>p</i> ^a
	Graft-less	Skin graft	Graft-less	Skin graft	
Webs (n)	30	19	15	12	
Perioperative complication ^b	1 (3.3)	1 (5.3)	1 (6.7)	1 (8.3)	1.000
Web creep ^c	3 (12.0)	4 (21.1)	2 (15.4)	3 (25.0)	0.645
Hypertrophic scarring	1 (3.3)	3 (15.8)	0 (0)	2 (16.7)	0.188
Scar contracture	0 (0)	2 (10.5)	0 (0)	2 (16.7)	0.188
Revision surgery	4 (13.3)	7 (36.8)	2 (13.3)	4 (33.3)	0.357
Revision procedures (n)	4	10	2	6	0.459

Values are presented as n (%) unless otherwise stated.

^aCalculated by Fisher's exact test.

^bIncludes neurovascular damage and wound infection.

^cAcrosyndactyly webs are excluded for this variable.

Table 4. Scar quality and postoperative success.

	Total (n = 49)	Graft-less group (n = 30)	Graft group (n = 19)
POSAS			
Patient scale	22.0 (13.0–32.0)	22.5 (12.0–32.5)	21.0 (15.3–30.0)
Observer scale	18.0 (15.0–24.0)	15.0 (13.0–20.0)	20.0 (18.0–23.0)
Total	42.0 (33.0–49.5)	42.0 (26.0–47.5)	41.0 (34.0–53.0)
Withey score			
Total	4.0 (3.0–6.0)	3.0 (2.8–5.0)	5.0 (3.0–7.0)
Simple webs only	4.0 (3.0–6.0)	4.0 (3.0–6.0)	4.0 (3.0–7.0)

Values are presented as median (IQR).

IQR: interquartile range; POSAS: Patient and Observer Scar Assessment Scale.

The chart study did not reveal significant differences in web creep, hypertrophic scarring and scar contractures, although a higher rate of additional procedures after skin grafting was found (Tables 3–6).

Withey score for postoperative success

The overall median Withey score was 4.0 (IQR 3.0–6.0) and only differed by two points in favour of the graft-less group. When assessing only simple webs, the median scores were the same for both groups. There were no significant differences between the two groups, regardless of whether analysis included all cases or simple cases only (Tables 4–6).

Scar quality (POSAS)

Scar quality, as rated by the patient or parent, differed by 1.5 points in favour of the graft group. The observer-rated assessment of scar quality indicated a greater difference of 5.0 points, in favour of the

graft-less group. However, the differences were not statistically significant (Tables 4–6).

Patient satisfaction

The results for patient satisfaction are summarised in Table 5. Total satisfaction was rated as 8.4 (IQR 6.8–8.9) and was similar in each group. When comparing the average scores for all survey parameters, the median scores were the same in each group and the IQRs were similar. The highest total satisfaction score was given for digit function (median 8.7) and the lowest was given for nail wall construction (median 5.9) (Tables 4–6).

Discussion

This report does not show a statistically significant difference in perioperative complications, hypertrophic scarring, scar contracture and web creep between techniques with or without skin grafting. Nonetheless,

Table 5. Patient satisfaction survey.

	Total (n = 27)	Graft-less group (n = 12)	Graft group (n = 15)
Scar quality	7.6 (6.6–8.7)	7.9 (5.4–9.2)	7.0 (6.7–8.4)
Digital function	8.7 (7.2–9.4)	9.1 (7.5–9.4)	8.1 (5.8–8.3)
Contour digit	7.9 (6.4–8.3)	7.3 (6.5–8.5)	8.1 (5.8–8.3)
Web space ^a	7.4 (5.9–8.3)	7.0 (5.4–9.0)	7.5 (6.2–7.9)
Skin graft ^a	7.7 (7.0–9.0)	–	7.7 (7.0–9.0)
Donor site ^a	8.5 (7.3–9.5)	–	8.5 (7.3–9.5)
Synonychia ^a	5.9 (4.7–8.4)	8.2 (4.4–9.1)	5.4 (4.4–6.8)
Total satisfaction	8.4 (6.8–8.9)	8.4 (7.9–9.2)	8.2 (6.4–8.9)
Average	7.9 (6.7–8.5)	7.9 (6.3–8.4)	7.9 (6.7–8.6)

Values are presented as median (IQR).

^aOnly answered if applicable.

Table 6. Statistical analyses of outcome assessments.

Parameter	n	Total	n	Graft-less	n	Skin graft	<i>p</i>
PSAS	27	23.0 (20.0–35.0)	15	23.0 (19.0–35.0)	15	25.5 (20.3–35.3)	0.476 ^a
OSAS	27	20.0 (15.0–24.0)	15	15.0 (13.0–24.0)	12	22.5 (19.3–24.0)	0.093 ^a
POSAS	27	46.0 (38.0–53.0)	15	46.0 (37.0–50.0)	12	49.5 (40.3–54.8)	0.476 ^a
Withey	24	4.0 (3.0–6.0)	15	4.0 (3.0–6.0)	12	4.5 (3.0–7.0)	0.425 ^a
Withey simple webs	15	4.0 (3.0–6.0)	8	4.0 (3.0–6.0)	7	4.0 (3.0–7.0)	0.572 ^a
Satisfaction	27	7.9 (6.7–8.5)	12	7.9 (6.3–8.4)	15	7.9 (6.7–8.5)	0.829 ^b

Values are presented as median (IQR) unless otherwise specified.

^aCalculated by Fisher's exact test.

^bCalculated by Mann-Whitney *U* test.

PSAS: Patient Scar Assessment Scale; OSAS: Observer Scar Assessment Scale; POSAS: Patient and Observer Scar Assessment Scale.

skin grafting at syndactyly release increased the need for an additional surgical procedure.

We found an overall 5.0-point difference in observer-rated scores, but comparable patient/parental scores, when comparing scar quality between the two study groups. Thus, despite a small difference in observer-rated scores, the presence or absence of grafting did not affect patient satisfaction. It was also noteworthy that patients who received grafts tended to be satisfied with the donor site scars, even reporting greatest satisfaction with this outcome (median 8.5, IQR 7.3–9.5).

Sykes and Percival (1989) found that the degree of complexity was the most influential factor for surgical outcomes in the treatment of syndactyly. In complicated syndactyly there is an increased risk of neurovascular damage because of abnormal digital anatomy. Furthermore, the need for a skin graft is in general higher for construction of complex or complicated syndactyly, as the remaining defects are usually larger than after correction for simple syndactyly. However, of the patients seen at

follow-up in this study, a greater percentage of complicated webs was treated without a graft than with the use of a skin graft. Therefore, in this case it is unlikely that the complexity of the webbing has biased the results of the graft group in comparison to the graft-less group.

Web creep is among the most important of complications but has a highly variable incidence of 8–60% (Kozin, 2001). This is possibly because of the different definitions of web creep used in studies, the relevance of which was supported by the different results we obtained when web creep was defined in two different ways. First, we looked at the medical records retrospectively and found the overall creep rate to be 14%, which was in line with other studies (i.e. 6–31%) using similar follow-up times (Arcangelo et al., 1996; Deunk et al., 2003; Lumenta et al., 2010; Niranjana et al., 2005; Widerberg et al., 2016). However, during the follow-up clinical investigations, we used the Withey score to judge postoperative success (Withey et al., 2001) and identified web creep in 13 out of 44 webs (30%), of which 11 had a low grade

of web creep that only extended one-third of the distance from the base of the web to the proximal interphalangeal joint crease (Withey grade 2). An explanation for the difference in rates could be that only two of the patients were contemplating additional surgery, which might have led to them visiting our outpatient clinic for examination earlier. Other explanations could be that the observer and original surgeon were different or that the surgeons inspected the constructed webs earlier after surgery and compared it to the position of the web as it was immediately after surgery. Regardless of the cause, our findings emphasise the need to use a uniform scoring system for web creep, possibly at scheduled intervals for up to 18 months, and documentation of web-position post-operatively. This would also improve the documentation of other complications. Revision procedures performed at our institution and complications as wound infections and neurovascular damage were recorded accurately. Long-term unfavourable outcomes, however, such as hypertrophic scarring and scar contractures, were documented at different intervals.

The differences in observer-rated scar quality between the two groups were not statistically significant. This could partially be explained by the small sample size. Performing an objective assessment of scar quality after surgery can be challenging. Many researchers have only reported 'acceptable' (Ekerot, 1999) scar quality and 'good cosmesis' (De Smet et al., 1998), which are difficult to interpret and compare (Sullivan and Adkinson, 2017). Although various scar scales are available, only a few studies of syndactyly have made use of them (Lumenta et al., 2010; Sulser et al., 2016; Widerberg et al., 2016). We selected the POSAS to assess scar quality because it is a comprehensible scale that has previously been used in a study of patients with syndactyly (Sulser et al., 2016). Also, in a systematic review by Tyack et al. (2012), the POSAS was shown to have superior performance compared with other scar scales and was recommended for use in cross-sectional studies. The POSAS is specifically validated for use with burn scars and linear post-surgical scars; moreover, the PSAS and OSAS components each have a good internal consistencies, with Cronbach alphas in the range of 0.74–0.90 (van de Kar et al., 2005).

This study has limitations that should be considered. First, only 50% of the patients eligible for this study could be traced for follow-up. This was partially due to missing contact details, emigration and patients that did not respond to our invitation. Seventeen patients had no interest in participating; most of these patients noted that they had moved to another city which increased travelling time. Some parents explained they preferred not to take their

child to the hospital if it was not necessary for health reasons. None of these patients or parents stated that the result of the surgery performed, either bad or good, was a reason for not participating.

Second, because complication severities differed, it could be argued that we should not have grouped them for analysis. For example, one case sustained a nerve laceration, which despite the patient regaining full function, is a serious complication. Third, clinicians did not use agreed definitions of hypertrophic scarring and web creep in their notes, so it is likely that there is inconsistency of measuring or even reporting these findings. A last limitation that should be mentioned concerns the cross-sectional design of the study, which precludes making assertions about causality. Besides, because of the study design, the documentation that was used for some parameters of the chart study, was too inconsistent to support possible trends; hence, a prospective study design is needed for future studies on syndactyly in which also the rationale for the use of a skin graft, or not, is recorded.

Employing a uniform scoring system at scheduled intervals to assess web creep and other complications by subtype of syndactyly would further improve the quality of any obtained data and aid comparability for subsequent meta-analyses and systematic reviews.

In conclusion, this long-term study of outcomes after primary syndactyly correction showed no differences between the skin graft group and the graft-less group. At the same time, an additional surgical procedure was more often employed after skin grafting procedures. Nonetheless, the type of technique does not affect the patient's final degree of satisfaction with the surgical outcomes or the scar appearance.

Acknowledgements The authors thank Dr Robert Sykes (www.doctored.org.uk) for providing editorial services.

Declaration of conflicting interests The authors declared no potential conflicts of interest with respect to the research, authorship, and/or publication of this article.

Funding The authors received no financial support for the research, authorship, and/or publication of this article.

References

- Arcangelo MD, Gilbert A, Pirrello R. Correction of syndactyly using a dorsal omega flap and two lateral and volar flaps. *J Hand Surg Am.* 1996, 21: 320–4.
- Braun T, Trost J, Pederson W. Syndactyly release. *Semin Plast Surg.* 2016, 30: 162–70.
- Ciurea A, Toader C. Genetics of craniosynostosis: review of the literature. *J Med Life.* 2008, 2: 5–17.

- De Smet L, van Ransbeeck V, Deneef G. Syndactyly release results of the Flatt technique. *Acta Orthop Belg.* 1998, 64: 301–4.
- Deunk J, Nicolai J, Hamburg S. Long-term results of syndactyly correction full thickness versus split-thickness skin grafts. *J Hand Surg Br.* 2003, 28: 125–30.
- Draaijers L, Tempelman F, Botman Y et al. The Patient and Observer Scar Assessment Scale: a reliable and feasible tool for scar evaluation. *Plast Reconstr Surg.* 2004, 7: 1966–7.
- Ekerot L. Correction of syndactyly: advantages with a non-grafting technique and the use of absorbable skin sutures. *Scand J Plast Reconstr Hand Surg.* 1999, 33: 427–31.
- Flatt AE. Practical factors in the treatment of syndactyly. In: Littler JW, Cramer LM, Smith JW (Eds) *Symposium on reconstructive hand surgery.* St. Louis, Mosby, 1974, Vol. 9: 144–56.
- Flatt AE. Webbed fingers. *Proc (Bayl Univ Med Cent).* 2005, 18: 26–37.
- Giele H, Cassell O. Congenital. In: Giele H, Cassel O (Eds) *Plastic and Reconstructive Surgery (Oxford Specialist Handbooks in Surgery).* Oxford, Oxford University Press, 2008, 206–208.
- Kay SP, McCombe DB, Kozin SH. Deformities of the Hand and Fingers. In: Wolfe S, Pederson W, Hotchkiss R, Kozin S (Eds). *Green's operative hand surgery.* Philadelphia, Elsevier, 2017: 1291–316.
- Kozin SH, Zlotolow DA. Common pediatric congenital conditions of the hand. *Plast Reconstr Surg.* 2015, 136: 241–57.
- Kozin SH. Syndactyly. *J Am Soc Surg Hand.* 2001, 1: 1–13.
- Kvernmo HD, Haugstvedt JR. Behandling av medfødte sammenvokste fingre. *Tidsskr Den Nor legeförening.* 2013, 133: 1591–5.
- Lumenta DB, Kitzinger HB, Beck H, Frey M. Long-term outcomes of web creep, scar quality, and function after simple syndactyly surgical treatment. *J Hand Surg Am.* 2010, 35: 1323–9.
- Magdi Sherif M. V-Y dorsal metacarpal flap: a new technique for the correction of syndactyly without skin graft. *Plast Reconstr Surg.* 1998, 101: 1861–6.
- Malik S. Syndactyly: phenotypes, genetics and current classification. *Eur J Hum Genet.* 2012, 20: 817–24.
- Netscher DT. Congenital hand problems. *Clin Plast Surg.* 1998, 25: 537–9.
- Ni F, Mao H, Yang X, Zhou S, Jiang Y, Wang B. The use of an hourglass dorsal advancement flap without skin graft for congenital syndactyly. *J Hand Surg Am.* 2015, 40: 1748–54.
- Niranjan N, Carpentier D. A new technique for the division of syndactyly. *Eur J Plast Surg.* 1990, 13: 101–4.
- Niranjan NS, Azad SM, Fleming ANM, Liew SH. Long-term results of primary syndactyly correction by the trilobed flap technique. *Br J Plast Surg.* 2005, 58: 14–21.
- Oda T, Pushman A, Chung K. Treatment of common congenital hand conditions. *J Plast Reconstr Surg.* 2010, 126: 121–33.
- Sullivan MA, Adkinson JM. A systematic review and comparison of outcomes following simple syndactyly reconstruction with skin grafts or a dorsal metacarpal advancement flap. *J Hand Surg Am.* 2017, 42: 34–40.
- Sulser PS, Kalisch M, Weber DM. Retroauricular full-thickness skin grafts in syndactyly repair: outcome and comparison with inguinal full-thickness skin grafts: retrospective [cross-sectional] study. *J Plast Surg Hand Surg.* 2016, 50: 281–5.
- Sykes N, Percival P. Syndactyly: a review of the factors which influence surgical treatment. *J Hand Surg Am.* 1989, 14: 196–200.
- Truong PT, Lee JC, Soer B, Gaul CA, Olivotto IA. Reliability and validity testing of the Patient and Observer Scar Assessment Scale in evaluating linear scars after breast cancer surgery. *Plast Reconstr Surg.* 2007, 119: 487–94.
- Tyack Z, Simons M, Spinks A, Wasiaik J. A systematic review of the quality of burn scar rating scales for clinical and research use. *Burns.* 2012, 38: 6–18.
- Van de Kar AL, Corion LUM, Smeulders MJ, Draaijers LJ, van der Horst CM, van Zuijlen PP. Reliable and feasible evaluation of linear scars by the Patient and Observer Scar Assessment Scale. *Plast Reconstr Surg.* 2005, 116: 514–22.
- Van der Biezen J, Bloem J. Dividing the fingers in congenital syndactyly release: a review of more than 200 years of surgical treatment. *Ann Plast Surg.* 1994, 33: 225–30.
- Widerberg A, Sommerstein K, Dahlin LB, Rosberg H. Long-term results of syndactyly correction by the trilobed flap technique focusing on hand function and quality of life. *J Hand Surg Eur.* 2016, 41: 315–21.
- Withey S, Kangesu T, Carver B, Sommerlad N. The open finger technique for the release of syndactyly. *J Hand Surg Eur.* 2001, 26: 4–7.