

elective abortion by age 45 years.<sup>S1</sup> Our survey found similar results, with 25.3% of women with prior pregnancy reporting at least 1 elective termination. Our survey did not query reasons for termination, such as whether underlying disease played a role, but these remain as questions for future studies. In addition, more data are needed on safety and use of both medical and surgical abortion procedures in this population.

Nephrologists have previously reported lacking confidence in contraception counseling.<sup>S2</sup> The majority of respondents here felt comfortable discussing contraception and desires for pregnancy with their nephrologist. However, our small sample size and low response rate caution against the generalizability of our results. Larger studies across a broader demographic are needed to assess these outcomes on both a national and international level. Overall, comprehensive reproductive counseling from nephrologists to women with glomerular disease and/or vasculitis is prudent to help avoid mistimed or unwanted pregnancies. By promoting effective contraception while preserving reproductive autonomy, nephrologists can support women in making informed decisions regarding family planning.

## DISCLOSURE

All the authors declared no competing interests.

## ACKNOWLEDGMENTS

MLR was supported by NIDDK/NIH 2T32DK007750-20. VKD, LNB, CJP, SLH and RJF received support from NIH/NIDDK 5P01DK058335-20. Study data were collected and managed using REDCap electronic data capture tools hosted at UNC. REDCap grant support UL1TR002489 from the Clinical and Translational Science Award program of the National Center for Advancing Translational Sciences, National Institutes of Health. This work was presented as an American Society of Nephrology (ASN) abstract

(Reynolds M, Poulton C, Blazek L, Nichols A, Hogan S, Falk R, Derebail V. Contraceptive use and elective terminations in women with glomerular disease, TH-PO731) at ASN Kidney Week, November 5–10, 2019, Washington, DC.

## SUPPLEMENTARY MATERIAL

[Supplementary File \(PDF\)](#)

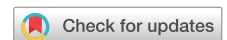[Supplementary Methods.](#)

[Supplementary References.](#)

## REFERENCES

- Finer LB, Zolna MR. Declines in unintended pregnancy in the United States, 2008–2011. *N Engl J Med.* 2016;374:843–852.
- Shah PS, Balkhair T, Ohlsson A, et al. Intention to become pregnant and low birth weight and preterm birth: a systematic review. *Matern Child Health J.* 2011;15:205–216.
- Blom K, Odutayo A, Bramham K, Hladunewich MA. Pregnancy and glomerular disease: a systematic review of the literature with management guidelines. *Clin J Am Soc Nephrol.* 2017;12:1862–1872.
- Curtis KM, Tepper NK, Jatlaoui TC, et al. U.S. medical eligibility criteria for contraceptive use, 2016. *MMWR Recomm Rep.* 2016;65:1–103.
- Daniels KAJ. Current contraceptive status among women aged 15–49: United States, 2015–2017. NCHS Data Brief, no 327. Hyattsville, MD: National Center for Health Statistics; 2018.
- Kavanaugh ML, Jerman J. Contraceptive method use in the United States: trends and characteristics between 2008, 2012 and 2014. *Contraception.* 2018;97:14–21.
- Schwarz EB, Manzi S. Risk of unintended pregnancy among women with systemic lupus erythematosus. *Arthritis Rheum.* 2008;59:863–866.
- Krajewski CM, Geetha D, Gomez-Lobo V. Contraceptive options for women with a history of solid-organ transplantation. *Transplantation.* 2013;95:1183–1186.
- Attini R, Cabiddu G, Montersino B, et al. Contraception in chronic kidney disease: a best practice position statement by the Kidney and Pregnancy Group of the Italian Society of Nephrology [e-pub ahead of print]. *J Nephrol.* <https://doi.org/10.1007/s40620-020-00717-0>. Accessed July 7, 2020.

# Whether Antibiotic Prophylaxis Is Necessary in Peritoneal Dialysis Patients Undergoing Elective Colonoscopy With Postprocedural Peritoneal Lavage



Kullaya Takkavatakarn<sup>1,2,3</sup>, Satimai Aniwani<sup>4</sup>, Nutcharin Kamjohnjiraphunt<sup>5</sup>, Piyaporn Towannang<sup>2</sup>, Nopparat Maeboonruen<sup>2</sup>, Thunvarat Saejew<sup>3</sup>, Preeyarat Pavatung<sup>3</sup>, Chanchana Boonyakrai<sup>6</sup>, Kamonrat Chongthanakorn<sup>7</sup>, Piyapan Prueksapanich<sup>4</sup>, Somchai Eiam-Ong<sup>1</sup>, Rungsun Rerknimitr<sup>4</sup> and Talerngsak Kanjanabuch<sup>1,2,3</sup>

<sup>1</sup>Division of Nephrology, Department of Medicine, Faculty of Medicine, Chulalongkorn University, Bangkok, Thailand; <sup>2</sup>Peritoneal Dialysis Excellence Center, King Chulalongkorn Memorial Hospital, Bangkok, Thailand; <sup>3</sup>Center of Excellence in Kidney Metabolic Disorders, Faculty of Medicine, Chulalongkorn University, Bangkok, Thailand; <sup>4</sup>Division of Gastroenterology, Department of Medicine, Faculty of Medicine, King Chulalongkorn Memorial Hospital, Chulalongkorn University, Bangkok, Thailand; <sup>5</sup>Department of Medicine, Makarak Hospital, Kanchanaburi, Thailand; <sup>6</sup>Division of Nephrology, Department of Medicine, Taksin Hospital, Bangkok, Thailand; and <sup>7</sup>Division of Nephrology, Department of Medicine, Charoenkrung Pracharak Hospital, Bangkok, Thailand

**Correspondence:** Talerngsak Kanjanabuch, Division of Nephrology, Department of Medicine, Faculty of Medicine; Chulalongkorn University, Bangkok 10330, Thailand. E-mail: [golfnephro@hotmail.com](mailto:golfnephro@hotmail.com)

Received 31 March 2020; revised 29 June 2020; accepted 7 July 2020; published online 17 July 2020

*Kidney Int Rep* (2020) 5, 1783–1787; <https://doi.org/10.1016/j.ekir.2020.07.007>

© 2020 International Society of Nephrology. Published by Elsevier Inc. This is an open access article under the CC BY-NC-ND license (<http://creativecommons.org/licenses/by-nc-nd/4.0/>).

Peritoneal dialysis (PD)–associated peritonitis is a major cause of technique failure and fatality and has been described as the Achilles heel of PD. One of the common causes of infection is transmural migration (enteric route), which is commonly related to constipation, diarrhea, and invasive intraluminal gastrointestinal (GI) procedures. A recent meta-analysis study demonstrated an increased risk of colorectal cancer in patients with end-stage kidney disease (ESKD).<sup>1</sup> Therefore, a recommendation of colorectal cancer screening has been advocated in such patients, beginning at age 50 years.<sup>2</sup> However, some concerns about the risk of postcolonoscopic peritonitis from mucosal tear or colonic microperforation from the therapeutic procedures (polypectomy or tissue biopsy) during colonoscopy, suggests the need for antibiotic prophylaxis. Thus, the International Society for Peritoneal Dialysis (ISPD) Peritonitis guidelines 2016<sup>3</sup> and the 2015 American Society for Gastrointestinal Endoscopy guidelines<sup>4</sup> recommended antibiotic prophylaxis before colonoscopy. However, the level of evidence was graded as “low” (2C). Nonetheless, the British Society of Gastroenterology<sup>5</sup> and the European Society of Gastrointestinal Endoscopy<sup>6</sup> did not mention this issue. The inconsistency of the recommendations results in a wide variety of current clinical practice in the use of antibiotic prophylaxis in PD patients undergoing colonoscopy.<sup>7</sup> Therefore, an interventional study was conducted to demonstrate the evidence of microorganism translocation and the unnecessary of antibiotic prophylaxis during elective colonoscopy in patients undergoing PD for colorectal cancer screening with a “dry” abdomen condition and postprocedural peritoneal lavage.

## RESULTS

A total of 51 PD patients undergoing elective colonoscopy for colorectal cancer screening without clinical suspicion of colonic abnormalities besides positive heme tests were included in this interventional study

(Table 1). Polypectomy was performed in 55% of the patients, and 1 tissue biopsy was performed at cecal ulcers. All of the polyps were benign. No intra- or postcolonoscopic complications were demonstrated (Table 1).

A total of 102 PD effluent (PDE) cultures from 51 colonoscopies were obtained. No significant leukocytes (>100 cells per high-power field) were found in any PDE specimens, including those at 1 week after the procedure. All precolonoscopy PDE and blood culture results were negative. Two 2-hour postcolonoscopy PDE cultures from 2 nondiabetes patients undergoing continuous ambulatory PD (CAPD) were positive for coagulase-negative *Staphylococcus* (CoNS) and *Corynebacterium* spp. None of the participants had clinical signs or symptoms of peritonitis. One 2-hour postcolonoscopy PDE culture of the patient with ulcers at the terminal ileum and ileocecal (IC) valve was positive for *Mycobacterium tuberculosis*, whereas the precolonoscopy PDE culture for *Mycobacterium* was negative. The pathology of the terminal ileum, as well as ileocecal valve ulcers, was also compatible with *M. tuberculosis*–induced lesion (Table 2).

Among 306 blood-culture specimens, there were 3 specimens from different participants having positive results for bacterial organisms, including *Staphylococcus hominis*, *Staphylococcus anviculavis*, and *Microbacterium*. One of these was positive in the blood specimens obtained during the procedure, and the other 2 were from blood specimens collected 2 hours after the procedure. Of note, 1 of the participants with positive blood specimen (*S. hominis*) taken 2 hours postprocedure was the case with an incidental finding of colonic tuberculosis and positive PDE specimen with *M. tuberculosis*. None of the participants developed septicemia or septic shock after the procedure. Table 2 shows participants’ characteristics and colonoscopic details of those participants with positive PDE culture and blood culture results.

**Table 1.** Baseline characteristics (N = 51)

Characteristic	Value
Age, yr	62 ± 10
Diabetes	15 (29)
Automated PD	26 (51)
Dialysis vintage, mo	8 (5–28)
Residual renal function, ml/d	400 (85–875)
Exit site classification	
- Perfect/good	25 (88)
- Equivocal	5 (10)
- Acute exit site infection	1 (2)
Laboratories	
- Hemoglobin, g/dl	10.5 ± 1.9
- Creatinine, mg/dl	8.6 ± 3.0
- Potassium, mEq/l	4.1 ± 0.7
- Albumin, g/dl	3.5 ± 0.4
Total weekly Kt/V	2.1 ± 0.6
Colonoscopy findings	
- Normal	19 (37)
- Colonic polyp at different sites	29 (57)
- Diverticulum without diverticulitis	2 (4)
- Clean-based ulcer at terminal ileum and cecum	1 (2)
Colonoscopy procedure	
- None	22 (43)
- Polypectomy	28 (55)
- Tissue biopsy	1 (2)
Colonoscopic complication (e.g., peritonitis)	0 (0)

CAPD, continuous ambulatory peritoneal dialysis; CCPD, continuous cyclic peritoneal dialysis; NIPD, nightly intermittent peritoneal dialysis; PD, peritoneal dialysis. Data are presented as mean ± SD, median (interquartile range), or n (%) of patients.

## DISCUSSION

This interventional study demonstrated the existence of transmural migration of microorganisms during and immediately after elective colonoscopy in stable PD patients with “dry abdomen” condition and

postprocedural peritoneal lavage (Figure 1). However, none of the patients with the presence of microbial translocation developed peritonitis or septicemia within 1 week postprocedure, despite the lack of antibiotic prophylaxis.

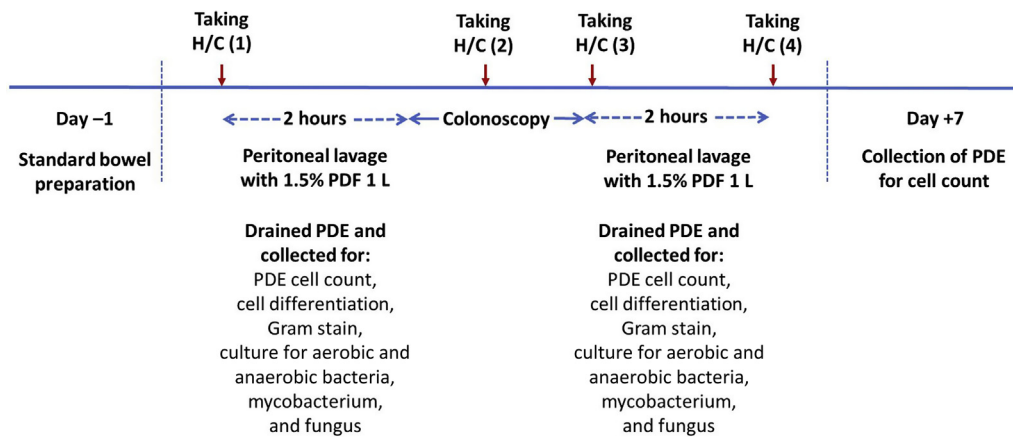
Although the incidences of postcolonoscopy bacterial peritonitis among patients without preprocedure administration of antibiotic prophylaxis are reported to range from 6.3% to 8.5% depending on patient condition and concomitant therapeutic procedure during colonoscopy, none of the studies actively performed a postprocedural PDE culture from every single studied case.<sup>8,9,S1</sup> All of these studies collected PDE cultures only when the patients had clinical features suggesting peritonitis. It is intriguing that there were no peritonitis/septicemia episodes (0%) in the present study, although 3 patients (5.9%) and 2 patients (3.9%) had transient bacterascites and bacteremia, respectively. The discrepancy in an incidence of postprocedural peritonitis might be explained by differences in indications of colonoscopy. The majority of the enrolled patients in the previous studies<sup>8,9</sup> had clinical suspicion of bowel pathology, whereas all of our participants were asymptomatic and underwent elective colonoscopy for colorectal cancer screening protocol without clinical suspicion of bowel pathology. All peritonitis patients in the Hong Kong study had clinical suspicions of bowel pathology, including iron deficiency anemia (n = 3), bleeding per rectum (n = 1), and bloody effluent (n = 1).<sup>9</sup>

In addition, our study performed postprocedural peritoneal lavage and was strict about a “dry abdomen” condition as mentioned by Chaudary *et al.*<sup>S2</sup> The U.S.

**Table 2.** Characteristics and colonoscopic details of participants with positive postprocedural PDE and blood culture

Characteristic	Case 1	Case 2	Case 3	Case 4	Case 5
Age, yr	65	61	55	59	55
Sex	Female	Female	Male	Male	Female
Diabetes mellitus	No	No	Yes	Yes	No
Mode of PD	CAPD	CAPD	CCPD	NIPD	CAPD
Colonoscopy findings	Colonic polyp	0.3-cm sessile polyp at sigmoid colon	0.5-cm round clean-based ulcer at ileocecal valve, 1.0-cm round clean-based ulcer at terminal ileum, and 0.3-cm sessile polyp at cecum	Normal	Normal
Procedure performed	Polypectomy	Polypectomy	Sampling lesion biopsy at ulcer and polypectomy	None	None
PDE culture					
- Before colonoscopy	NG	NG	NG	NG	NG
- 2 h after colonoscopy	CoNS	<i>Corynebacterium</i> spp.	<i>M. tuberculosis</i>	NG	NG
Hemoculture					
- Before colonoscopy	NG	NG	NG	NG	NG
- During cecal intubation	NG	NG	NG	NG	NG
- Immediately after colonoscopy	NG	NG	NG	<i>S. anviculavis</i>	NG
- 2 h after colonoscopy	NG	NG	<i>S. hominis</i>	NG	<i>Microbacterium</i> spp.
Clinical peritonitis (abdominal pain, fever, cloudy PDE)	No	No	No	No	No

CoNS, coagulase-negative *Staphylococcus*; NG, no growth; PD, peritoneal dialysis; PDE, peritoneal dialysis effluent.



**Figure 1.** Protocol for colonoscopy preparation, peritoneal dialysis fluid, and blood sampling. H/C, hemoculture; PDE, peritoneal dialysis effluent; PDF, peritoneal dialysis fluid.

group recently recommended keeping the abdomen dry for hours to days after colonoscopy as a means to improve host defenses.<sup>S2</sup> However, the present study showed that emptying the abdomen for a short period during colonoscopy might be enough. Peritoneal lavage after the procedure aiming to eliminate pathogen contamination and inflammatory cytokines in the peritoneal cavity is widely used in both abdominal laparotomy and laparoscopy, with favorable outcomes in the reduction of postprocedural peritonitis and peritonitis-related death.<sup>S3,S4</sup> However, the use of postprocedural peritoneal lavage has not been encouraged in PD patients. Our finding might support the potential benefit of peritoneal lavage in removing the spilled-out pathogen in the peritoneal cavity and preventing postprocedural peritonitis, although transmural migration of the pathogens during colonoscopy was documented.

Based on the findings of the present study, the concept of giving antibiotic prophylaxis in every PD patient undergoing colonoscopy was not firmly supported, at least in the patients undergoing colorectal cancer surveillance protocol with “dry abdomen” and postprocedural peritoneal lavage. Our result supports the finding from Al-Hwiesh *et al.* in which ceftazidime prophylaxis before colonoscopy was not beneficial in the reduction of peritonitis episodes after the procedure (3 in 46 patients [6.5%] vs. 4 in 47 patients [8.5%], respectively,  $P = 0.279$ ) in the prospective randomized controlled study.<sup>9</sup>

The strength of the present work is that the study collected both pre- and post-colonoscopy PDE and blood cultures from every patient. Of more importance, we could demonstrate the real evidence of bacterial translocation causing bacterascites after the intraluminal gastrointestinal procedure and also could demonstrate that all of the patients with bacterascites were asymptomatic and this bacterascites could resolve after

peritoneal lavage. However, the results in the present study may not be applicable to all clinical settings. First, our study excluded patients with higher risks of peritonitis, including immunocompromised patients (i.e., those taking glucocorticoid and immunosuppressive drugs), a recent history of peritonitis, active GI symptoms, and advanced GI cancer. Second, our study had relatively few outcomes, and larger-scale multicenter prospective controlled trials are essential. The effects of postprocedural peritoneal lavage on peritonitis prevention require confirmation in future studies.

In conclusion, the risk of postprocedural peritonitis is low in asymptomatic PD patients undergoing colonoscopy for colorectal cancer screening with “dry abdomen” during the procedure and immediately postprocedural peritoneal lavage, regardless of the presence of transient bacterascites/bacteremia. Therefore, the decision to routinely prescribe antibiotic prophylaxis in these patients should be individualized.

## DISCLOSURE

All the authors declared no competing interests.

## ACKNOWLEDGMENTS

This study was supported by Rachadaphiseksompot Endorsement Fund, Chulalongkorn University, Thailand (GCURS\_61\_06\_30\_1) and National Research Council of Thailand, Thailand (6/2562). The authors would like to acknowledge the contributions of the staff, nurses, and all investigators who take care of the participating patients in the study facilities, including King Chulalongkorn Memorial Hospital, Taksin Hospital, and Charoenkrung Pracharak Hospital, Thailand.

## SUPPLEMENTARY MATERIAL

[Supplementary File \(PDF\)](#)

[Supplementary Methods.](#)

[Supplementary References.](#)



## REFERENCES

1. Komaki Y, Komaki F, Micic D, et al. Risk of colorectal cancer in chronic kidney disease: a systematic review and meta-analysis. *J Clin Gastroenterol*. 2018;52:796–804.
2. Holley JL. Screening, diagnosis, and treatment of cancer in long-term dialysis patients. *Clin J Am Soc Nephrol*. 2007;2:604–610.
3. Li PK, Szeto CC, Piraino B, et al. ISPD peritonitis recommendations: 2016 update on prevention and treatment. *Perit Dial Int*. 2016;36:481–508.
4. ASGE Standards of Practice Committee, Khashab MA, Chithadi KV, et al. Antibiotic prophylaxis for gastrointestinal endoscopy. *Gastrointest Endosc*. 2015;81:81–89.
5. Allison MC, Sandoe JA, Tighe R, et al. Antibiotic prophylaxis in gastrointestinal endoscopy. *Gut*. 2009;58:869–880.
6. Rey JR, Axon A, Budzynska A, et al. Guidelines of the European Society of Gastrointestinal Endoscopy (E.S.G.E.) antibiotic prophylaxis for gastrointestinal endoscopy. *Endoscopy*. 1998;30:318–324.
7. Boudville N, Johnson DW, Zhao J, et al. Regional variation in the treatment and prevention of peritoneal dialysis-related infections in the Peritoneal Dialysis Outcomes and Practice Patterns Study. *Nephrol Dial Transplant*. 2019;34:2118–2126.
8. Al-Hwiesh AK, Abdul-Rahman IS, Hussameldeen MA, et al. Colonoscopy in automated peritoneal dialysis patients: value of prophylactic antibiotics: a prospective study on a single antibiotic. *Int J Artif Organs*. 2017;40:550–557.
9. Yip T, Tse KC, Lam MF, et al. Risks and outcomes of peritonitis after flexible colonoscopy in CAPD patients. *Perit Dial Int*. 2007;27:560–564.

## Acute Kidney Injury Associated With Lopinavir/Ritonavir Combined Therapy in Patients With COVID-19



Yannick Binois<sup>1</sup>, Hafsah Hachad<sup>1</sup>, Joe-Elie Salem<sup>2</sup>, Julien Charpentier<sup>1</sup>, Bénédicte Lebrun-Vignes<sup>2,3</sup>, Frédéric Pène<sup>1</sup>, Alain Cariou<sup>1</sup>, Jean-Daniel Chiche<sup>1</sup>, Jean-Paul Mira<sup>1</sup> and Lee S. Nguyen<sup>1,2,4</sup>

<sup>1</sup>Assistance Publique-Hôpitaux de Paris Centre, Cochin University Hospital, Intensive Care Medicine Department, Paris, France; <sup>2</sup>Sorbonne Université, Assistance Publique-Hopitaux de Paris Pitié-Salpêtrière, INSERM, Clinical Investigations Center Paris-Est, Paris, France; <sup>3</sup>Université Paris Est Créteil, EpiDermE, Créteil, France; and <sup>4</sup>Centres Médico Chirurgicals Ambroise Paré, Research and Innovation, Neuilly-sur-Seine, France

**Correspondence:** Lee S. Nguyen, Intensive Care Medicine Department, Cochin University Hospital, Assistance Publique-Hôpitaux de Paris, 75014 Paris, France. E-mail: [nguyen.lee@icloud.com](mailto:nguyen.lee@icloud.com)

**Received 21 June 2020; revised 22 July 2020; accepted 30 July 2020; published online 6 August 2020**

*Kidney Int Rep* (2020) 5, 1787–1790; <https://doi.org/10.1016/j.ekir.2020.07.035>

© 2020 International Society of Nephrology. Published by Elsevier Inc. This is an open access article under the CC BY-NC-ND license (<http://creativecommons.org/licenses/by-nc-nd/4.0/>).

Lopinavir and low-dose ritonavir (LPV/RTV) are associated in a fixed-dose combination protease inhibitor therapy used in patients with HIV and AIDS. The recent outbreak of severe acute respiratory syndrome coronavirus 2 infections causing coronavirus disease 2019 (COVID-19) has rekindled the interest in LPV/RTV after preclinical studies.<sup>1</sup> Although no benefit was observed with LPV/RTV treatment beyond standard care,<sup>2</sup> other randomized controlled trials, such as DisCoVeRY (NCT04315948), are currently enrolling. Like other antiretroviral therapies, LPV/RTV has been previously associated with acute kidney injuries (AKIs), even though no systematic pharmacovigilance analysis was ever performed.

We first describe a small case series of AKI associated with LPV/RTV in the course of COVID-19 treatment. We then performed a query in the World Health

Organization pharmacovigilance database, Vigibase, and extracted all AKIs associated with LPV/RTV. We then presented clinical characteristics of these events and performed a comparison between HIV and COVID-19 indication in Vigibase.

### METHODS

#### Study Design

This work combines a case series of all patients who presented with AKI under LPV/RTV in our intensive care medicine department and a worldwide pharmacovigilance observational case-control cross-sectional study focusing on AKI related to the usage of LPV/RTV. It relies on Vigibase, a database encompassing 22 million individual case safety reports worldwide.<sup>3</sup> Individual case safety reports include administrative