

Overall satisfaction, sexual function, and the durability of neophallus dimensions following staged female to male genital gender confirming surgery: the Institute of Urology, London U.K. experience

Maurice M. Garcia^{1,2}, Nim A. Christopher², Francesco De Luca², Marco Spilotros², David J. Ralph²

¹Department of Urology, University of California San Francisco, San Francisco, CA, USA; ²St. Peter's Andrology Centre and The Institute of Urology, University College London, London, UK

Correspondence to: Maurice M. Garcia, M.D., MAS. Department of Urology, University of California San Francisco; 400 Parnassus Avenue, San Francisco, California 94143, USA. Email: mgarcia@urology.ucsf.edu.

Background and purpose: What factors influence transgender men's decisions to undergo (and to not undergo) specific genital gender confirming surgeries (GCS) has not been described in the literature. Sexual function outcomes related to clitoral transposition and penile prosthesis placement is also not well described. Durability of neophallus dimensions after phalloplasty has not been described. A better understanding of these factors is necessary for pre-op counseling. We sought to assess patient genital-GCS related satisfaction, regret, pre/post-op sexual function, genital preferences, and genital measurements post-op.

Materials and methods: We evaluated ten female to male transgender patients who had previously undergone suprapubic pedicle-flap phalloplasty [suprapubic phalloplasty (SP); N=10] and 15 who had undergone radial artery forearm-flap phalloplasty [(RAP); N=15; 5/15 without and 10/15 with cutaneous nerve to clitoral nerve anastomosis] at our center (UK). We queried patients' surgery related preferences and concerns, satisfaction, and sexual function pre/post-surgery, and accounted for whether patients had undergone clitoral transposition and/or cutaneous-to-clitoral nerve anastomosis. We measured flaccid and (where applicable) erect length and girth using a smart-phone app we designed.

Results: Mean age at surgery and follow-up for those that underwent SP was 35.1 and 2.23 years, and 34 and 6.8 for those that underwent RAP. Mean satisfaction scores were 9.1/10 and 9/10 for those that underwent SP and RAP, respectively. No patient (0%) regretted starting genital-GCS surgery. All (100%) patients that could achieve orgasm before GCS with clitoral transposition could achieve orgasm after surgery, and the vast majority reported preserved quality of erogenous sensation by our transposition technique. All (100%) RAP and 9/10 SP patients reported masturbation with their phallus. Inflatable penile prosthesis placement was not associated with decreased erogenous sensation/orgasm. Penile dimensions were relatively stable through follow-up for both groups. Our App length measurements correlated with a ruler within $\pm < 4.5\%$.

Conclusions: Female-to-male genital-GCS offered in 3-stages was associated with high overall satisfaction and no regret among our sample. Sexual function appears to be preserved after both clitoral transposition and inflatable prosthesis placement, and consolidation of erogenous sensation to the phallus was described as important to all subjects. Discussion of patient's pre-op sexual function, as well as specific concerns and preferences related to specific genital-GCS surgeries is important.

Keywords: Transgender; genital gender confirming surgery (GCS); phalloplasty; clitoral nerve anastomosis; sexual function; penis size

Submitted Apr 02, 2014. Accepted for publication Apr 17, 2014.

doi: 10.3978/j.issn.2223-4683.2014.04.10

View this article at: <http://www.amepc.org/tau/article/view/3748/4674>

Background and purpose

Genital gender confirming surgery (GCS) has been shown to significantly decrease gender dysphoria and improve the quality of life of transgender patients (1,2). A fundamental goal of reconstructive genital GCS is to provide the patient with genitals whose appearance and function are consistent with those of members of the gender they identify with.

For the female to male transsexual, surgical options include creation of a neophallus (phalloplasty) using a vascularized free-flap or pedicle flap (with or without neourethra construction and anastomosis to the native urethra). At our centers and abroad, the most commonly used free-flap is the radial forearm-flap (3). At our center, the most common pedicle flap we use is harvested from the suprapubic area. At our centers and at Belgium's Ghent University Hospital (4), anastomosis of the dominant cutaneous nerve(s) to one of the clitoral nerve bundles is performed with free-flap phalloplasties (3,5,6). Additional procedures are also performed: glansplasty (to give the end of the phallus a natural glans-like appearance), transposition of the denuded clitoris to the neophallus base (to consolidate erogenous sensation to the neophallus), and vaginectomy. At other centers (4), these are performed at time of phalloplasty, whereas at our centers, these are performed at second-stage surgery. Placement of testicular and penile prostheses, for cosmesis and erectile function, respectively, are performed at second (4) or (at our centers) third stage surgery. Previous groups have reported that the majority of patients retain the ability to achieve orgasm following phalloplasty (3,7,8). However, the degree to which sexual function is preserved (i.e., quality; e.g., relative time to achieve orgasm) relative to specific GCS such as clitoral transposition and penile prosthesis placement has not been described.

Furthermore, what factors influence transgender men's decisions to undergo (and to not undergo) specific genital GCS has also not been described in the literature. Our experience among male transsexual patients seeking post-operative care at our tertiary-care medical center in the U.S. (UCSF) is that many did not undergo creation of a neourethra, clitoral transposition to the neophallus, or penile prosthesis placement. Even in our group's high-volume female to male GCS centers in the UK where we routinely perform clitoral transposition and prosthesis placement at second and third stage surgeries, respectively, a subset of patients still elect to forego these two procedures as well.

We hypothesized that a better understanding of key

factors, preferences and concerns that drive transgender men's decision-making related to genital surgery, and a better understanding of sexual function following specific genital GCS, would be useful to better counsel patients pre-operatively regarding surgery options.

In this work, we sought to assess satisfaction and regret associated with patients' own female-to-male genital GCS, pre and post-operative sexual function and neophallus dimensions among a divided subset of patients that did and did not undergo clitoral transposition and penile prosthesis placement.

Materials and methods

We evaluated a random selection of female-to-male transgender patients who had previously undergone pedicle-flap suprapubic phalloplasty [(SP); N=10] and radial artery forearm-flap phalloplasty [(RAP); N=15]. We included a cohort of patients from earlier in our center's series that had undergone surgery without cutaneous nerve to unilateral clitoral nerve anastomosis, and, for comparison, a more current cohort of patients who had undergone cutaneous nerve to clitoral nerve anastomosis, which is now standard practice for our group. The only criterion for eligibility was that the patient had to be able to present, in person, at our clinic for evaluation. All patients were evaluated by interview and physical exam by a single surgeon (MMG) in our clinic (Institute of Urology; London, UK).

Patient's surgical records were queried regarding patient age, date of surgery, and surgical data that included: phalloplasty type (suprapubic or radial forearm free-flap phalloplasty, flap length, whether or not the clitoris was transposed to the base of the neophallus at subsequent surgery, whether or not the patient had undergone penile prosthesis, and what type of prosthesis was used (inflatable or malleable).

During interviews, all patients were queried regarding the following domains: (I) overall satisfaction with the outcome of their genital GCS (likert scale, 1-10); (II) whether patient has sufficient overall regret for the outcome of their genital GCS to wish that they had never started genital GCS; and (III) overall satisfaction with final phallus length (likert scale, 1-10); (IV) which ideal is more "important" to the patient: "above average" penile length or girth, or neither/equal? and (V) which does the partner think is more "important" for his partner: "above average" penile length or girth, or neither/equal?

The following specific domains of sexual function, before

Table 1 Study subjects

	SP	RAP without cutaneous-clitoral nerve anastomosis	RAP with cutaneous-clitoral nerve anastomosis
Number of subjects [N]	10	5	10
Age [years]	35.1	34.0	39.2
Follow-up [years]	2.23	6.80	2.24

SP, suprapubic [pedicle] phalloplasty; RAP, radial artery forearm flap phalloplasty.

and after GCS, were queried: (I) whether they were able to achieve orgasm before GCS surgery, and afterwards; (II) whether after transposition of the clitoris to the neophallus, they were still able to achieve orgasm with direct stimulation of the buried clitoris site; (III) after clitoral transposition, did direct stimulation of the buried clitoris site yield equal or delayed time to orgasm? (IV) whether they masturbate with their phallus; and (V) whether, following penile prosthesis placement, they were still able to achieve orgasm with direct stimulation of the clitoris (native location or where buried).

All subjects were instructed regarding how to use the smart-phone App “MedMeasure!” (Android Google Play and Apple® iTunes: <https://itunes.apple.com/us/app/medmeasure!/id654898049?mt=8>) to measure their own phallus length and width by photographing their phallus in the flaccid or erect state. [subjects placed a British 1£ coin (whose diameter is known by the App) upon the dorsal surface of the mid-shaft].

Phallus measurements, from tip to the dorsal circumferential scar at the base, were then performed (flaccid, and if a prosthesis was present, also erect), using the MedMeasure! App and the coin as an internal reference object.

Results

Study subjects and follow-up

Mean age and follow-up of patients that underwent pedicle-flap SP was 35.1 and 2.23 years. For those who underwent RAP phalloplasty without and with cutaneous nerve to clitoral nerve anastomosis, it was 34 and 6.8 years, and 39.2 and 2.24 years, respectively (Table 1).

Surgical procedures: clitoral transposition and penile prosthesis placement

Over half of patients of all three groups underwent transposition of the clitoris to the neophallus. While only one of ten patients of the group that underwent SP had

undergone penile prosthesis placement (this device was already explanted due to malfunction by time of present evaluation), 2/3 of patients that underwent RAP had elected to proceed with penile prosthesis placement (Table 2).

Subject interview responses (Table 3)

Neophallus measurements

Neophallus flap length was measured intra-operatively; girth was not. Length and girth measurement values at follow-up are shown in Table 3.

Neophallus measurement App

Neophallus length measurements using the MedMeasure! App correlated to actual-lengths on the ruler within the image by $\pm 4.5\%$ of the value measured by a ruler (Figure 1).

Discussion

At our high volume female to male genital GCS center in London, UK, we now routinely stage phalloplasty and neourethra-urethral anastomosis +vaginectomy +clitoral transposition, over two separate surgeries, as compared to a single stage surgery as is performed at leading European centers (4). This is because our experience has been that doing so allows for more optimal wound healing of the neophallus and neo-urethra before additional pelvic surgery, and has resulted in fewer post-operative complications (e.g., infection, fistulae) and improved cosmesis of glansplasty. Furthermore, staging clitoral transposition surgery allows us to bury the denuded clitoris in a more superficial location just below the skin surface of the neophallus at the base (5). Other centers bury the denuded clitoris beneath the base of the neophallus [i.e., upon the surface of the pubic symphysis (3)]. It is not possible to compare outcomes between the two techniques, as quality of erogenous sensation has not been described by others (8), but, we believe that placing it more superficially renders it more accessible to direct stimulation, and so, may better facilitate and preserve erogenous

Table 2 Subject interview responses

	SP	RAP without cutaneous-clitoral nerve anastomosis	RAP with cutaneous-clitoral nerve anastomosis
Clitoris transposed	8/10	3/5	6/10
Penile prosthesis [Y/N]	1/10 [inflatibe]	5/5 [all inflatable]	5/10 [all inflatable]
Overall satisfaction with the final result of genital GCS surgeries [likert scale, 1-10]	9.1/10	9.4/10	8.7/10
Regret for patient's decision to undergo genital GCS [Y/N]	Yes: 0/10; No: 10/10	Yes: 0/5; No: 5/5	Yes: 0/10; No: 10/10
Overall satisfaction with final phallus length [likert scale, 1-10]	9.6/10	8.1/10	8.1/10
Which is more important to patient [penile length or girth?]	Length: 5/10; girth: 2/10; equal =3/10	Length: 3/5; girth: 2/5; equal =0/5	Length: 5/10; girth: 5/10; equal: 0/10
Which does patient think is more "important" to his female partner: penile length or girth?	Length: 2/10; girth: 8/10; equal: 0.10	Length: 1/5; girth: 4/5; equal =0/5	Length: 2/10; girth: 8/10; equal: 0/10
Ever achieved orgasm before genital GCS? [Y/N]	Yes: 9; No: 1	Yes: 4; No: 1	Yes: 7; No: 3
Ever achieved orgasm after genital GCS? [Y/N]	Yes: 10; No: 0	Yes: 5; No: 0	Yes: 8; No: 2*
After clitoral transposition to neophallus, able to achieve orgasm with direct stimulation of buried clitoris site?	Yes: 8/8	Yes: 3/3	Yes: 4/6 No: 2/6 [*]
After clitoral transposition, did direct stimulation of the buried clitoris site yield equal or delayed time to orgasm?	All 8/8 pts. reported equal time to orgasm	2/3 pts. reported equal time to orgasm; 1/3 reported "slight delay"	4/4 pts. that could achieve orgasm reported equal time to orgasm
Masturbate with phallus? [Y/N]	Yes: 9; No: 1	Yes: 5; No: 0	Yes: 9; No: 1
Any diminished ability to achieve orgasm after penile prosthesis placement?	No: 1/1	No: 5/5	No: 5/5

SP, suprapubic [pedicle] phalloplasty; RAP, radial artery forearm flap phalloplasty; *, No history of clitoral orgasm pre-op.

Table 3 Neophallus measurements

	Length					Girth		
	Mean intra-op tubularized flap length [range]	Mean flaccid phallus length at follow-up [range]	Mean δ length [post-op - intra-op] [range]	Mean erect length [range]	Mean δ length [erect-flaccid] [range]	Mean flaccid girth [range]	Mean erect girth [range]	Mean δ girth [erect-flaccid] [range]
SP	13.7 cm [12-16]	13.3 cm [11.75-16]	-0.5 cm [-0-2]	-	-	13.36 cm [13-16]	-	-
RAP	13.9 cm [13-16]	11.95 cm [9.9-16]	1.93 cm [-0-3.5]	11.52 cm [9.8-12.5]	-0.43 cm [-0-1]	11.46 cm [8.25-14]	11.89 cm [8.8-13]	+0.77cm [+0.5-1.25]

RAP, radial artery forearm flap phalloplasty; SP, suprapubic [pedicle] phalloplasty.

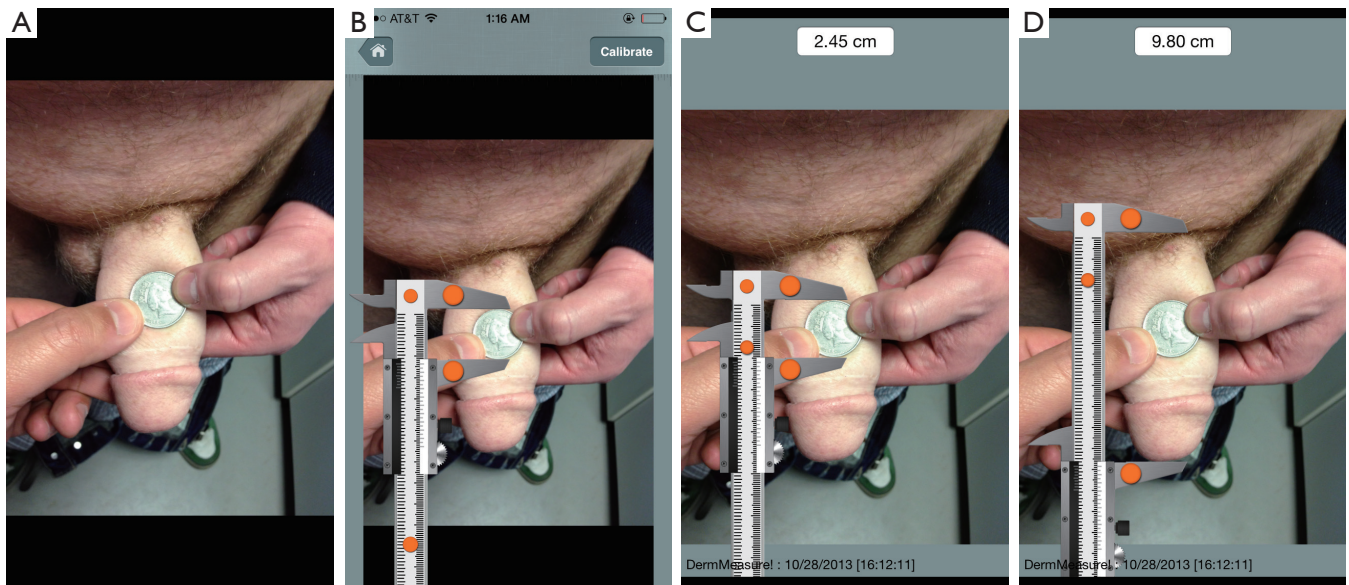


Figure 1 The MedMeasure Apple smartphone app (selected country: UK) was used to measure neophallus length. (A) “1£ coin” was selected from the App’s drop-down menu of Reference Objects. A U.K. 1£ coin was placed by the patient on the surface of the neophallus at time of image capture; (B) To calibrate MedMeasure’s scalable digital caliper, the caliper jaws are positioned (by finger pinch using the orange “finger pads” on the jaws, as shown) to encompass the diameter of the coin. When complete, the “calibrate” (top-right of screen; circled) button is pressed; (C) The actual length of the reference object (1£ coin) is immediately displayed (2.45 cm); (D) The caliper is then moved into position and the caliper jaws are opened to encompass the length of the neophallus. The actual length is displayed in the results window in the top-center of the screen (e.g., 9.80 cm). Note: each measurement is date and time stamped (bottom of screen).

sensation.

Staging genital surgery also presents patients with the opportunity to carefully consider any additional surgeries—such as vaginectomy, clitoral transposition to the neophallus, and penile prosthesis placement. In the U.S., the fact that very few surgeons offer F to M surgery overall, and an even fewer number offer phalloplasty combined with neourethra creation and/or vaginectomy and/or clitoral transposition and/or penile prosthesis. As more surgery is offered in the U.S. and abroad, patients will face greater choices regarding surgical options.

The results of our work show that while patients are, overall, quite satisfied with their decision to undergo genital GCS, those that did not undergo clitoral transposition to the neophallus or penile prosthesis placement related that the driving reason for foregoing surgery was a concern that they risked losing erogenous sensation and the ability to achieve orgasm. They also related regret—equally for perceived unfavorable cosmesis (likely related to underlying gender dysphoria), and, the fact that without clitoral transposition, erogenous sensation remains consolidated outside of their new phallus. Our present work suggests

that, provided that patients have experienced clitoral orgasm before surgery, clitoral transposition does not result in a subsequent loss of ability to achieve orgasm with direct stimulation of the clitoris site. Similarly, no patient that underwent penile prosthesis placement, and had experienced orgasm at least once before prosthesis placement surgery, reported diminished likelihood of achieving orgasm after prosthesis placement.

Querying patients about sexual function before surgery is exceedingly important, as pre-op function undoubtedly influences post-op sexual function, and, because doing so is an opportunity to prepare patients for surgery and manage expectations post-op. In our series, we found that almost all men report masturbating their neophallus [consistent with other reports (9)] regardless of whether they have undergone clitoral transposition and can achieve orgasm with stimulation of only the phallus. This suggests, and is echoed by comments from many of our patients, who relate the added “purely psychological” pleasure that self-stimulation of their phallus provides to them, and which “enhance” orgasm quality.

In our experience, many patient’s report lack of familiarity

with their genitals (e.g., use for sex, exploratory touching), and this may be likely attributable to their gender dysphoria. Such lack of familiarity may predict for poorer sexual function post-op: two of the three patients that had never experienced orgasm before surgery reported an inability to achieve orgasm after their surgery. For one of these men, religious beliefs precluded pre-marital sexual activity. The other man (also un-partnered) reported attempting masturbation, but an inability to achieve it due to “not knowing how to do it” or “what to look for”. Based on our experience from the present work, we now routinely query our patients pre-op regarding past sexual function, and encourage them to familiarize themselves, pre-op, with the location and stimulation of erogenous sensation of their genitals.

Our results related to neophallus measurements after surgery is reassuring in that it suggests that phallus length appears to not change significantly after surgery. The greater mean decrease in length among patients who underwent RAP versus those who underwent SP phalloplasty may reflect the greater incidence of subsequent local infections (related to the creation of a neourethra and/or penile prosthesis placement) in the former group, which likely leads to scarring of phallus tissues and decreased length. It is useful to be able to counsel patients that their phallus length will most likely shorten, though likely only by a small degree (mean 1-2 cm.) post-op, and, that with an inflatable penile prosthesis, only a modest increase in girth (mean 0.77 cm.) and, surprisingly, a very small decrease in length (mean -0.43 cm.) can be expected. Phallus length measured with the MedMeasure! App was highly accurate relative to use of a ruler, and it is reasonable to expect to be able to collect accurate phallus length and width measurement data from patients remotely using this App.

Similar to how some natal (CIS) men ascribe a significant degree of importance to achieving an ideal penis size, many trans men also request large neophallus dimensions. As our study shows, at least half of all trans men themselves valued above average penile length. Interestingly, despite this, 80% of these same trans men felt that their female partners would value above average girth over length. Patients can be reminded of well-powered national studies of erect penile length all show that mean flaccid and erect penile lengths are generally around 8.85 and 12.89 cm respectively (10), and that, depending on the type of phalloplasty they undergo, their neophallus may likely be well above average for flaccid length and within average ranges for erect length. Furthermore, patients who request a particularly long neophallus length can be reminded that an especially long

phallus may not adequately support the inflatable penile prosthesis cylinder(s), causing for example, cylinders to buckle more easily in the erect state and/or wear-out at an accelerated rate. Longer inflatable cylinders require longer filling (pumping) time, and longer malleable prostheses are more challenging to obscure with clothing. Furthermore, while the most common manufacturers' inflatable prostheses will accommodate an especially long phallus, patients should consider that, owing to the fact that the degree to which the proximal end of the inflatable prosthesis can be concealed is limited in a transgender man, when an especially long phallus requires use of prosthesis rear-tip extenders, it becomes much more likely that the patient will be able to feel the firm/pointed point of entry of the tubing into the cylinder—which many find uncomfortable and un-aesthetic. Lastly, patients should also be reminded that if they elect to undergo a urethral lengthening procedure post-phalloplasty, a longer phallus will require a longer neourethra, and the availability of an especially long non hair-bearing suitable segment of skin for this must be taken into account.

Limitations of our study include relatively small sample size for subgroups and that only subjects who presented to be able and inclined to present to our clinic were evaluated. These limitations could certainly result in sampling bias. Future studies, already underway by our group, should include a larger sample size with more balanced subgroups (e.g., inclusion of patients with malleable prostheses, etc.).

In conclusion, our study suggests that sexual function/ability to achieve orgasm related to the clitoris is not lost following clitoral transposition surgery or penile prosthesis placement following clitoral transposition surgery. Overall, F to M genital GCS is associated with exceedingly high overall satisfaction and, in our series, without any overall regret. Neophallus dimensions remain relatively stable over time after phalloplasty, and length and girth do not change significantly with penile prosthesis placement. We believe that the aforementioned data is useful to inform patients and help guide their expectations related to surgery.

Acknowledgements

Author (Maurice M. Garcia) and manuscript publication supported by National Institutes of Health (NIH) and National Institute of Child Health and Human Development (NICHD) K08 Mentored Clinician Scientist Grant Award, #10713482.

The authors (all) wish to thank Vera Henriques and Sara Richardson of St. Peter's Andrology Centre for administrative

assistance throughout the course of the study.

Footnote

Conflicts of Interest: The University of California has filed U.S. and International Patent applications for intellectual property (IP) related to the smartphone image-based measurement App, MedMeasure! Used in this work: U.S. Patent Number 61548750. This IP was licensed by author Maurice Garcia, as required by the University of California in order to proceed to program (create) the App and made it available—as no such App currently exists. This App is currently available on Apple iTunes Store and Android Google Play App store. The App is free, though upgrades that allow one to perform measurements similar to those described in this manuscript [e.g., use of a wide variety of coins or a ruler to calibrate the caliper, does require an in-app purchase (cost =0.99 cents)]. No other App currently available on iTunes or for Android smartphones affords the ability to measure actual distance on a 2-D camera image, and it is for this reason that the authors used the App designed by their group (M. Garcia). The authors have added “Patents Pending” to the text to reflect the patents-pending status of the App.

References

1. Byne W, Bradley SJ, Coleman E, et al. Report of the American Psychiatric Association Task Force on Treatment of Gender Identity Disorder. *Arch Sex Behav* 2012;41:759-96.
2. Wierckx K, Van Caenegem E, Elaut E, et al. Quality of life and sexual health after sex reassignment surgery in transsexual men. *J Sex Med* 2011;8:3379-88.
3. Monstrey S, Hoebeke P, Selvaggi G, et al. Penile reconstruction: is the radial forearm flap really the standard technique? *Plast Reconstr Surg* 2009;124:510-8.
4. Departments of Plastic Surgery, Urology, Gynecology, and Psychiatry and Gender Issues; Ghent University Hospital, Ghent, Belgium.
5. Garaffa G, Christopher NA, Ralph DJ. Total phallic reconstruction in female-to-male transsexuals. *Eur Urol* 2010;57:715-22.
6. Monstrey SJ, Ceulemans P, Hoebeke P. Sex Reassignment Surgery in the Female-to-Male Transsexual. *Semin Plast Surg* 2011;25:229-44.
7. Selvaggi G, Hoebeke P, Ceulemans P, et al. Scrotal reconstruction in female-to-male transsexuals: a novel scrotoplasty. *Plast Reconstr Surg* 2009;123:1710-8.
8. Selvaggi G, Monstrey S, Ceulemans P, et al. Genital sensitivity after sex reassignment surgery in transsexual patients. *Ann Plast Surg* 2007;58:427-33.
9. De Cuyper G, T'Sjoen G, Beerten R, et al. Sexual and physical health after sex reassignment surgery. *Arch Sex Behav* 2005;34:679-90.
10. Wessells H, Lue TF, McAninch JW. Penile length in the flaccid and erect states: guidelines for penile augmentation. *J Urol* 1996;156:995-7.

Cite this article as: Garcia MM, Christopher NA, De Luca F, Spilotros M, Ralph DJ. Overall satisfaction, sexual function, and the durability of neophallus dimensions following staged female to male genital gender confirming surgery: the Institute of Urology, London U.K. experience. *Transl Androl Urol* 2014;3(2):156-162. doi: 10.3978/j.issn.2223-4683.2014.04.10