

## Case Report

# Implant-based oral rehabilitation of a variant model of type I dentinal dysplasia: A rare case report

Sowmya Nettem<sup>1</sup>, Sunil Kumar Nettemu<sup>1</sup>, K. Basha<sup>2</sup>, Venkatachalapathi S<sup>3</sup>

<sup>1</sup>Departments of Periodontology and Oral Implantology, <sup>3</sup>Oral and Maxillofacial Surgery, Melaka – Manipal Medical College, Jalan Batu Hampar, Bukit Baru, 75150 Melaka, Malaysia, <sup>2</sup>Jas Dento Medico Center, Bangalore, Karnataka, India

## ABSTRACT

Dentin dysplasia is an exceptionally rare, autosomal-dominant, hereditary condition, primarily characterized by defective dentin formation affecting both the deciduous and permanent dentitions. The etiology remains imprecise to date, in spite of the numerous hypotheses put forward and the constant updates on this condition. This case report of type I dentin dysplasia exhibits radiographic findings that are unique and diverse from the classical findings of various subtypes of this disease reported to date. This article also depicts the implant-based oral rehabilitation of the young patient diagnosed with this variant model of dentin dysplasia type I. Early diagnosis and implementation of this preventive and curative therapy is vital for avoiding premature exfoliation of deciduous and permanent dentition and the associated residual ridge resorption, thereby overcoming functional and esthetic deficits and ensuring protection of the remaining dentition from further harm.

**Key Words:** Dentin dysplasia, implant placement, radiographic features

Received: December 2012

Accepted: July 2013

### Address for correspondence:

Dr. Sunil Kumar Nettemu,  
Department of  
Periodontology and Oral  
Implantology, Faculty of  
Dentistry, Melaka – Manipal  
Medical College, Jalan Batu  
Hampar, Bukit Baru, 75150,  
Melaka, Malaysia.  
E-mail: nettemsunil  
@gmail.com

## INTRODUCTION

Dentin dysplasia (DD) is an extremely rare, autosomal-dominant condition, primarily characterized by defective dentin formation affecting both the deciduous and permanent dentitions. This pathology was first described by Ballschmiede<sup>[1]</sup> and later the condition was termed as ‘dentinal dysplasia’.<sup>[2]</sup> Depending on the parts of the teeth affected, Witkop<sup>[3]</sup> has broadly classified DD into two categories, type I – radicular dentin dysplasia and type II – coronal dentin dysplasia, where type I DD is characterized by the presence of primary and permanent teeth with a normal appearance of the crown portions, but absent or rudimentary root development, incomplete or

total obliteration of the pulp chamber, and periapical radiolucent areas or cysts. Four subtypes of DD I were further identified by Neville *et al.*<sup>[4]</sup> Type 1a showed absence of the pulp chamber and root formation and frequent periradicular radiolucencies; type 1b exhibited a single, small, horizontally oriented, and crescent-shaped pulp with roots extending only a few millimeters in length, associated with frequent periapical radiolucencies; in type 1c, two horizontal or vertical crescent-shaped pulpal remnants surrounding a central island of dentin are seen, with significant, but shortened root length, and variable periapical radiolucencies; in type 1d, there is a visible pulp chamber and canal with near normal root length and large pulp stones that are located in the coronal portion of the canal, which create a localized bulging in the canal as well as root constriction of the pulp canal apical to the stone and few periapical radiolucencies.

O’Carroll *et al.*<sup>[5]</sup> presented another subclassification based on the radiographic findings. The first type presented with total pulp chamber obliteration, no root development, and multiple periapical

Access this article online



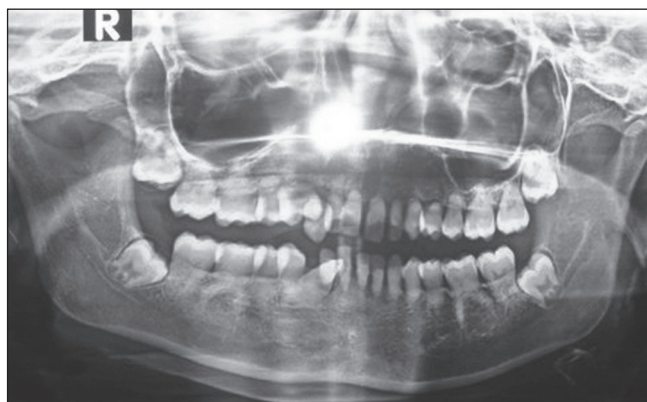Website: <http://drj.mui.ac.ir>

radiolucencies, the second and third types depicted less obliterated pulp chambers, crescent-shaped radiolucent areas, and minimal root formation, with less frequent periapical radiolucencies, and the fourth subtype presented radiographically visible and delimited chambers, with pulpal nodules found in the coronal third of the canal and the roots had significant development, but few or no radiolucencies.

This case report of type I dentin dysplasia highlights the radiographic findings that are unique and diverse from the classical findings of various subtypes of this disease reported to date. The article also presents the implant-based oral rehabilitation of this young patient diagnosed with the variant model of dentin dysplasia type I.

## CASE REPORT

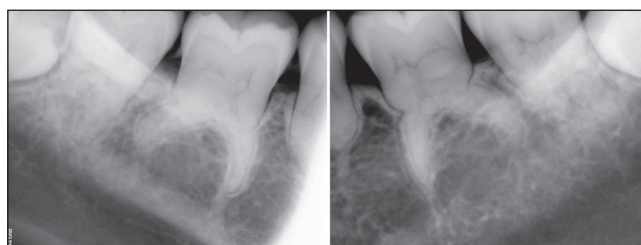
A 17-year-old female patient reported to the Department of Periodontology and Oral Implantology with a chief complaint of severe mobility of her upper and lower front teeth. She had started noticing the mobility since the past two years and it was noticed that the mobility had increased progressively over the years. This was the first dental visit for the patient and the past medical and social histories were noncontributory. There was no relevant familial history of the disease and hence the patient was considered to be a first generation sufferer. The clinical intraoral examination revealed the presence of normal color and morphology of the crowns of all teeth. Stable gingival and periodontal health was confirmed by a



**Figure 1:** Orthopantomogram revealing the pathological changes. Note the generalized rudimentary or nearly absent root structures. Also note the absence of periapical radiolucencies and osseous pathologies

thorough intraoral assessment, which demonstrated a clinical absence of gingival inflammatory changes, absence of bleeding on probing, as well as, loss of clinical attachment. However, assessment of mobility revealed grade III mobility of the upper and lower anterior teeth and all the four first premolars. The second premolar and molar teeth remained immobile. The patient demonstrated good oral hygiene and there were no other relevant intraoral findings noted. An orthopantomogram of the patient revealed rudimentary and nearly absent root structures in relation to the upper and lower anterior teeth, the premolars, and molars [Figure 1]. The intraoral periapical radiographs revealed a defective morphology with a strikingly flared, inverted, crescent-shaped appearance of the roots of the mandibular first molar teeth [Figure 2]. There was a generalized total obliteration of the pulp tissues within the pulp chambers and root canals [Figures 1-3]. An interesting feature was the absence of periapical radiolucencies and periradicular lesions. Also, there were no associated osseous changes or bone pathologies detected. Based on the clinical and radiographic findings of the disease, the diagnosis was established as dentin dysplasia type I. However, the findings of this case did not fit into any subtypes of the existing classification systems of the disease. The observations of an absence of familial hereditary pattern, the absence of periradicular radiolucent lesions and osseous pathologies, and the variant morphological defects of the molar roots were diverse from the classical findings of the various subtypes of dentin dysplasia type I reported to date.

The treatment plan was formulated based on the age of the patient, the expected esthetic outcome, and the long-term prognosis of the therapy. The patient had completed the craniofacial growth phase and



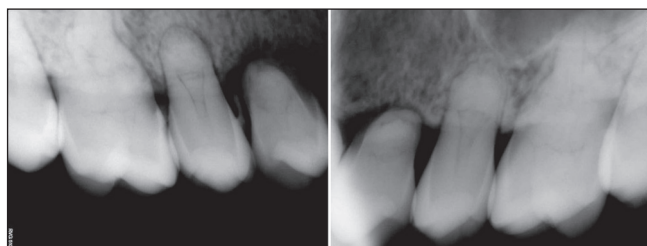
**Figure 2:** Intraoral periapical radiographs revealing the unusual morphology of the mandibular right and left first molar teeth. Note the strikingly flared, inverted, crescent-shaped appearance of the roots

was highly concerned about the esthetic outcome of the treatment. As the patient was 17 years old at the time of the visit to the dental office, a major period of growth and growth spurts was completed. Hence, no further changes in the craniofacial structure that might cause gross future occlusal derangement were deemed to occur and no further growth investigations were carried out. Taking all these multiple factors into consideration, an implant-based oral rehabilitation was finalized as the treatment for this patient. The treatment plan was explained in detail to the patient and her family and a written informed consent was obtained from the patient as well as the guardian of the patient.

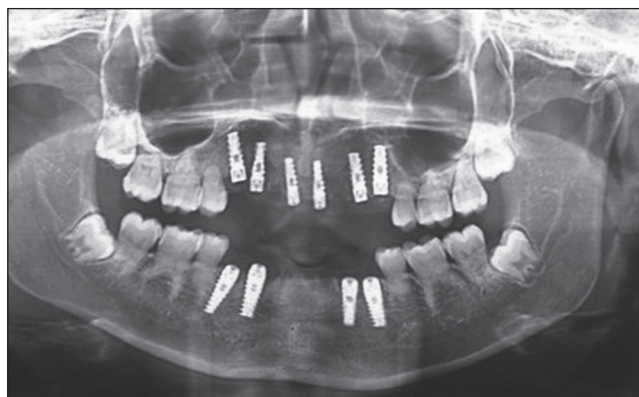### Surgical procedure

The surgical sites extending bilaterally between the first premolar regions in the maxilla and mandible were anesthetized using local administration of 2% lignocaine hydrochloride (LOX, Neon Laboratories Ltd., Mumbai, India) with 1: 200,000 adrenaline. All the Grade III mobile teeth were extracted and the osteotomy site preparations were carried out under copious irrigation with sterile isotonic saline solution. After establishing proper depth

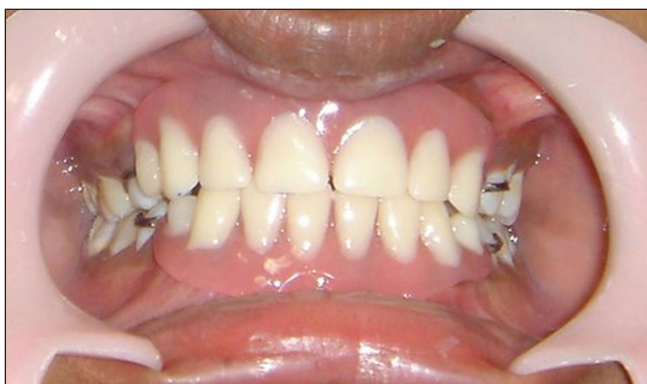and direction, a total of 10 self-threaded titanium implant fixtures, including six in the maxillary and four in the mandibular regions were placed [Figure 4]. Temporary maxillary and mandibular removable partial denture prostheses were delivered [Figure 5]. Postoperative care included a prescription of 8 mg of betamethasone and 2 g/ day dosage of amoxicillin, for 10 days. The patient was advised to rinse with warm saline solution for the first two weeks to promote flap healing without disturbing the surgical sites. The patient was also instructed to use 0.12% chlorhexidine gluconate mouthwash (Peridex, Zila Pharmaceuticals, Phoenix, AZ, USA), twice daily, to facilitate plaque control. The surgical sites were checked every two weeks for a period of two months. Following six months of healing, the second surgical procedure to uncover the implants was performed, the abutments were placed, and the final prostheses were delivered [Figures 6 and 7]. The patient and family members expressed a positive response toward the superior



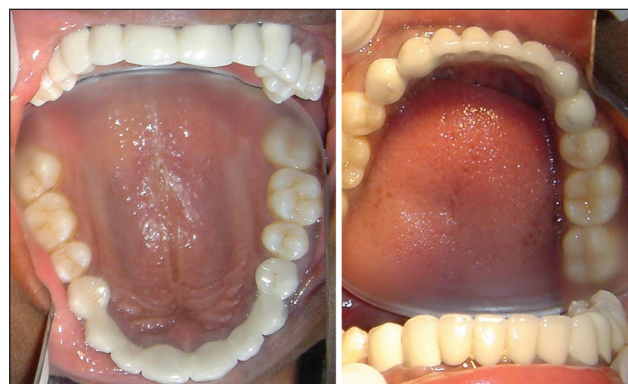**Figure 3:** Intraoral periapical radiographs revealing generalized complete obliteration of the pulp tissues within the pulp chambers and root canals of the teeth



**Figure 4:** Implants placed in position in the maxillary and mandibular arches

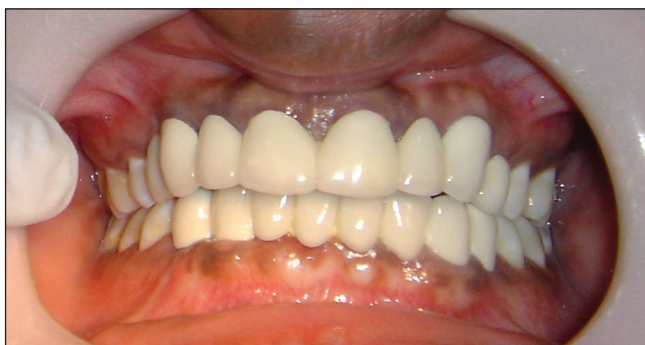

**Figure 5:** Maxillary and mandibular temporary partial removable prostheses in position



**Figure 6:** Maxillary and mandibular occlusal view of the final fixed prostheses





**Figure 7:** Frontal view after placement of final fixed restorations in the maxilla and mandible

esthetic and functional outcome of the treatment. The patient has been put on a strict maintenance program with a first year recall interval of three months, followed by a review once in six months to one year, based on the home care performance and assessment of the intraoral health status.

## DISCUSSION

The etiopathogenesis of dentinal dysplasia remains unknown despite the numerous hypotheses put forward by different authors. Logan *et al.*<sup>[6]</sup> hypothesized that abnormal degeneration and calcification would occur in the dental papilla, resulting in reduced growth and final obliteration of the pulpal space. It was also assumed that the occurrence of an earlier ingrowth of the radicular epithelial sheath resulted in ectopic dentin formation.<sup>[7]</sup> Witkop<sup>[3]</sup> proposed that the internal cells of the developing dental organ would be displaced and proliferate in the dental papilla producing ectopic dentin formation. According to Wesley *et al.*,<sup>[8]</sup> a failure in the interactions between odontoblasts and ameloblasts would occur, causing differentiation and / or abnormal function of the odontoblasts. However, to date, there is no consensus in the dental literature regarding the etiology of DD.

DD is an extremely rare autosomal-dominant hereditary disturbance, primarily characterized by defective dentin formation, affecting both the deciduous and permanent dentitions in approximately one in every 100,000 patients.<sup>[9]</sup> However, in the present case report, there are many variations from the typical features of type I DD. First, the patient showed no signs of family heritage and these findings are in concurrence with three

other reports.<sup>[10-12]</sup> Also, in this patient, there was no report of formation of any painful, spontaneous abscesses or cysts, and a radiograph confirmed the absence of periapical radiolucencies, which was consistent with the findings of only one other recent case report.<sup>[10]</sup> An association was also noted between dentin dysplasia and osseous changes including sclerotic bone deposition in a case report,<sup>[13]</sup> but the present case had no signs of any bone-related pathologies. All these diversities in the radiographic presentation make this case report a unique one, challenging the already existing classification systems of type I DD.

## CONCLUSION

Type I DD is an extremely rare disease, yet of high concern to dental practitioners, due to the tooth loss affecting patients at an early age on account of unknown and unidentified etiological factors leading to severe esthetic and functional deficits. Implant-based oral rehabilitation provides a long-term esthetic and fixed replacement therapy for young patients diagnosed with this disease condition. To date, there is no consensus in the dental literature regarding the etiology of DD. Also, considering the rarity of this disease, we can safely conclude that case reports can serve as useful tools to elucidate and understand the different aspects of this condition.

## REFERENCES

1. Ballschmiede G. Dissertation. Malformations of the jaws and teeth. In: Herbst E, Apffelstaedt M, editors. Berlin; New York: Oxford University Press; 1920. p. 930, 286.
2. Rushton MA. A case of dentinal dysplasia. *Guy's Hosp Rep* 1939;89:369-73.
3. Witkop CJ Jr. Hereditary defects of dentin. *Dent ClinNorth Am* 1975;19:25-45.
4. Neville B, Damm D, Allen C, Bouquot J. *Oral and Maxillofacial Pathology*. 3<sup>rd</sup> ed. Philadelphia: Saunders Elsevier; 2008.
5. O'Carroll MK, Duncan WK, Perkins TM. Dentin dysplasia: Review of the literature and a proposed subclassification based on radiographic findings. *Oral Surg Oral Med Oral Pathol* 1991;72:119-25.
6. Logan J, Becks H, Silverman S Jr, Pindborg JJ. Dentinal dysplasia. *Oral Surg Oral Med Oral Pathol* 1962;33:763-71.
7. Sauk JJ Jr, Lyon HW, Trowbridge HO, Witkop CJ Jr. An electron optic analysis and explanation for the etiology of dentinal dysplasia. *Oral Surg Oral Med Oral Pathol* 1972;33:763-71.

8. Wesley RK, Wysoki GP, Mintz SM, Jackson J. Dentin dysplasia type I. Clinical, morphologic, and genetic studies of a case. *Oral Surg Oral Med Oral Pathol* 1976;41:516-24.
9. Kim JW, Simmer JP. Hereditary dentin defects. *J Dent Res* 2007;86:392-9.
10. Rocha CT, Nelson-Filho P, Silva LA, Assed S, Queiroz AM. Variation of dentin dysplasia type I: Report of atypical findings in the permanent dentition. *Braz Dent J* 2011;22:74-8.
11. Vieira AR, Modesto A, Cabral MG. Dentinal dysplasia type I: Report of an atypical case in the primary dentition. *ASDC J Dent Child* 1998;65:141-4.
12. Toomarian L, Mashhadiabbas F, Mirkarimi M, Mehrdad L. Dentin dysplasia type I: A case report and review of the literature. *J Med Case Rep* 2010;4:1.
13. Morris ME, Augsburg RH. Dentin dysplasia with sclerotic bone and skeletal abnormalities inherited as an autosomal dominant trait. *Oral Surg Oral Med Oral Pathol* 1977;43:267-83.

**How to cite this article:** Nettem S, Nettemu SK, Basha K, Venkatachalapathi S. Implant-based oral rehabilitation of a variant model of type I dentinal dysplasia: A rare case report. *Dent Res J* 2014;11:513-7.

**Source of Support:** Nil, **Conflict of Interest:** None declared.