

Retroperitoneal Metastatic Adenocarcinoma Complicated with Necrotizing Fasciitis of the Thigh in a Patient with Advanced Rectal Colon Cancer

Jia-Hong Chen Ping-Ying Chang Ching-Liang Ho
Yeu-Chin Chen Wei-Yau Kao

Division of Hematology/Oncology, Department of Medicine, Tri-Service General Hospital, National Defense Medical Center, Taipei, Taiwan, ROC

Key Words

Retroperitoneal · Necrotizing fasciitis · Colon cancer

Abstract

Background: Necrotizing fasciitis of the thigh due to colon cancer has not been previously reported, especially during radiotherapy.

Case Presentation: A 73-year-old woman admitted to our hospital was diagnosed with sigmoid colon cancer that had spread to the left psoas muscle; radiotherapy was performed. Three months after the initiation of radiotherapy, the patient developed gait disturbance, poor appetite and high fever and was therefore admitted to the emergency department of our hospital. Blood examination revealed generalized inflammation with a high white blood cell count and C-reactive protein level. Computed tomography of the abdomen revealed fluid and gas tracking from the retroperitoneum into the intramuscular plane of the grossly enlarged right thigh. Consequently, emergent debridement was not performed and conservative therapy was done. The patient died.

Conclusion: Necrotizing fasciitis of the thigh due to the spread of rectal colon cancer is unusual, but this fatal complication should be considered during radiotherapy in patients with unresectable colorectal cancer.

Introduction

Necrotizing fasciitis (NF) is a rare and life-threatening soft-tissue infection. Aggressive surgical management is required in the early stage in order to reduce the associated high mortality rate, which ranges from 20 to 40% [1]; however, it is often difficult to diagnose

NF in its early stages. NF is usually caused not only by trauma to the skin, such as that induced by insect bites, scratches, and abrasion, but also by surgical wounds in the perineum and lower extremities [2]. Other less common causes include perforated or penetrated diverticulitis, ruptured appendix, and inflammatory bowel diseases [3].

Up to now, few reports of NF caused by rectal colon cancer have been published in the English literature. Herein, we presented a rare case of NF of the thigh during radiotherapy for a retroperitoneal metastatic lesion of rectal colon cancer.

Case Report

Our patient was a 73-year-old woman, who had a history of papillary serous adenocarcinoma of the ovary 4 years ago and received debulking operation with total abdominal hysterectomy, bilateral salpingo-oophorectomy, bilateral pelvic and para-aortic lymph nodes dissection, infracolic omentectomy, appendectomy, Hartmann's procedure (resection of S-D colon + end D-colostomy), resection of partial intestine with end to end anastomosis and 6 courses of adjuvant chemotherapy. Two years later, she was admitted to our hospital with a 2-months history of frequent passage of bloody discharge and anorexia. On the basis of the results of a digital rectal examination, a computed tomography (CT) scan and gastrointestinal endoscopy, she was diagnosed of having unresectable rectal colon cancer. Then, she received colostomy over the left lower quadrant of the abdomen and concurrent chemoradiotherapy (CCRT). One year later, a follow-up abdomen CT scan revealed disease progression with a metastatic lesion in the retroperitoneum (fig. 1). Subsequently, palliative radiotherapy was performed.

Three months after the initiation of palliative therapy, the patient was readmitted due to painful dyskinesia of the right lower extremity, poor appetite and high fever. Physical examinations revealed progressive erythematous, diffuse swelling, heat and tenderness over the right thigh and tenderness over the right lower quadrant of the abdomen. Pitting edema over the right lower limbs was significant. Blood examination revealed leukocytosis (white blood cell count, 41,000 cells/ μ l), and a high C-reactive protein (CRP) level (33.32 mg/dl). A CT scan revealed fluid and gas tracking from the retroperitoneum into the intramuscular plane of the grossly enlarged right thigh (fig. 2), and an infection caused by gas-producing anaerobic microorganisms was found. A presumptive diagnosis of NF of the right thigh was made.

Emergent surgical intervention was suggested, but her family refused the intervention due to the terminal stage of colon cancer. The patient then received intravenous antibiotics (carbapenem). Microbiological culture of the pus revealed the presence of *Klebsiella pneumoniae* and other anaerobic bacteria. The patient died.

Discussion

NF is a serious soft-tissue infection that causes secondary necrosis of the subcutaneous tissues. It can occur in any region of the body but most commonly occurs in the abdominal wall, extremities, and perineum. It has been reported that NF has a high morbidity and mortality rate because of its acute and rapidly progressive course. The outcome of NF is rendered poor most importantly by delays in its diagnosis and surgical debridement. Thus, early diagnosis of necrotizing soft-tissue infections followed by administration of intravenous antibiotics and surgical intervention is the best way of decreasing its mortality. Clinical features of NF include high fever with chills, tenderness over the affected area along with changes in skin color and palpable crepitus [1].

It is well known that perineal NF, termed 'Fournier's gangrene', is caused by rectal cancer or periproctal abscess [4], and there are several reports on NF due to colorectal cancer involving the abdominal wall [5, 6]. However, NF of the thigh due to the spread of colorectal cancer, as observed in the present case, is extremely rare.

A literature review reveals only 4 such cases [7–10]. Colon cancer usually spreads intraperitoneally, and its spread in the retroperitoneal direction is relatively rare. In the 3 reported cases, symptoms of NF preceded the diagnosis of colorectal cancer and 1 case developed during chemotherapy for the treatment of colorectal cancer. Thus, to our knowledge, this is the first reported case in which NF developed during radiotherapy for the treatment of colorectal cancer.

In the present case, the patient did not receive surgical intervention because her family thought that the patient, due to advanced colorectal cancer, might not tolerate the stress of radical surgery. However, we realized that NF, which was a serious complication, could have been avoided if the radical treatment had been initiated earlier.

Specifically, a high incidence of bowel perforation and delayed wound healing have been observed in patients treated with bevacizumab [11]. Therefore, adequate care should be taken to prevent perforation and penetration following NF in such patients.

Retroperitoneal abscess and NF are rare complications of colorectal cancer that can potentially be fatal, particularly in patients who are immunocompromised because of radiotherapy and CCRT. In the presence of these unclear risk factors, accurate and rapid clinical evaluation and a careful consideration of a balance between the risks and benefits are necessary before performing a palliative surgery.

Conclusion

Colon cancer could be a cause of unexpected retroperitoneal abscess followed by NF of the thigh, and NF should be considered during the diagnosis and treatment of colon cancer. Early diagnosis and treatment can help reduce the mortality rate associated with NF.

Fig. 1. CT scan with contrast of the abdomen showing a heterogeneous hypodense mass (size: about 6.0 cm) over the right lower quadrant of the abdomen.

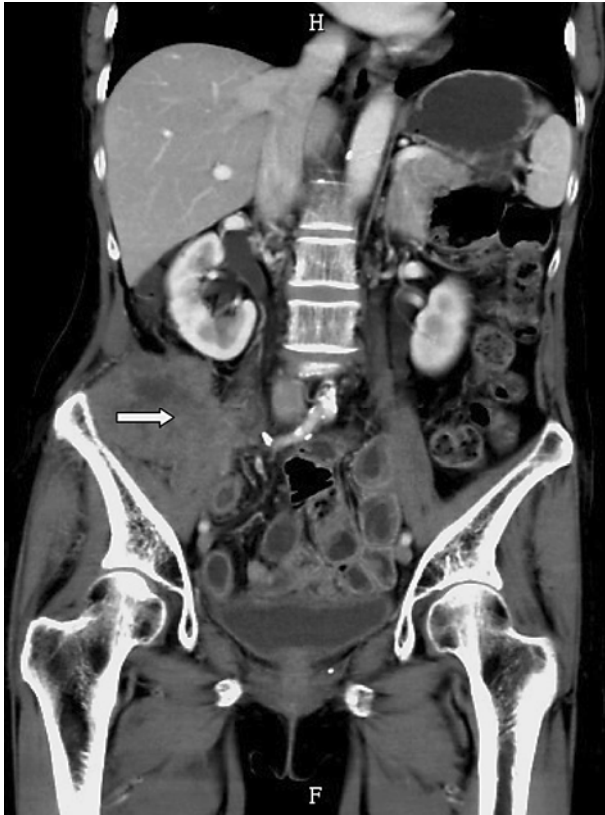
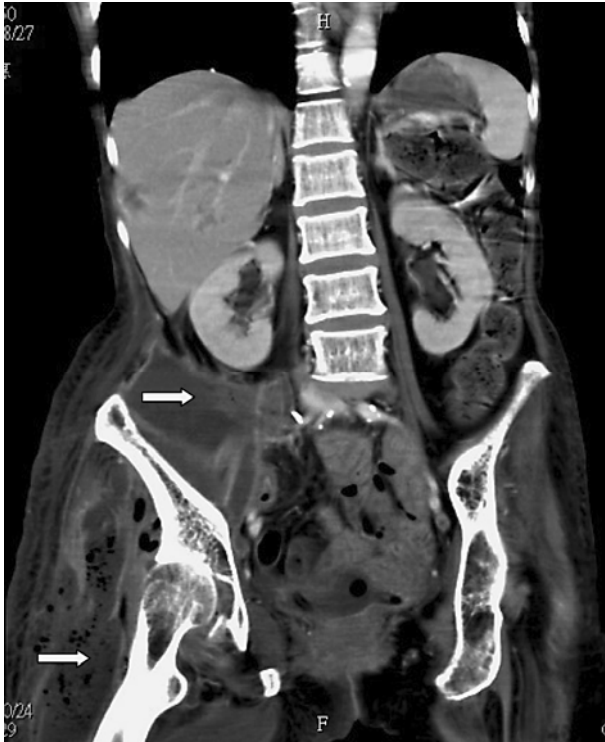

Fig. 2. CT scan with contrast of the abdomen showing fluid and gas tracking from the retroperitoneum into the intramuscular plane of the grossly enlarged right thigh.



References

- 1 Levine EG, Manders SM: Life-threatening necrotizing fasciitis. *Clin Dermatol* 2005;23:144–147.
- 2 Cunningham JD, Silver L, Rudikoff D: Necrotizing fasciitis: a plea for early diagnosis and treatment. *Mt Sinai J Med* 2001;68:253–261.
- 3 Groth D, Henderson SO: Necrotizing fasciitis due to appendicitis. *Am J Emerg Med* 1999;17:594–596.
- 4 Eke N: Fournier's gangrene: a review of 1,726 cases. *Br J Surg* 2000;87:718–728.
- 5 Ku HW, Chang KJ, Chen TY, Hsu CW, Chen SC: Abdominal necrotizing fasciitis due to perforated colon cancer. *J Emerg Med* 2006;30:95–96.
- 6 Marron CD, McArdle GT, Rao M, Sinclair S, Moorehead J: Perforated carcinoma of the caecum presenting as necrotising fasciitis of the abdominal wall, the key to early diagnosis and management. *BMC Surg* 2006;6:11.
- 7 Lam TP, Maffulli N, Chen EH, Cheng JC: Carcinomatous perforation of the sigmoid colon presenting as a thigh mass. *Bull Hosp Jt Dis* 1996;55:83–85.
- 8 Highton L, Clover J, Critchley P: Necrotising fasciitis of the thigh secondary to a perforated rectal cancer. *J Plast Reconstr Aesthet Surg* 2008;62:e17–e19.
- 9 Liu SY, Ng SS, Lee JF: Multi-limb necrotizing fasciitis in a patient with rectal cancer. *World J Gastroenterol* 2006;12:5256–5258.
- 10 Takakura Y, Ikeda S, Yoshimitsu M, Hinoi T, Sumitani D, Takeda H, Kawaguchi Y, Shimomura M, Tokunaga M, Okajima M, Ohdan H: Retroperitoneal abscess complicated with necrotizing fasciitis of the thigh in a patient with sigmoid colon cancer. *World J Surg Oncol* 2009;7:74.
- 11 Saif MW, Elfiky A, Salem RR: Gastrointestinal perforation due to bevacizumab in colorectal cancer. *Ann Surg Oncol* 2007;14:1860–1869.