



Received: 2014.11.11
Accepted: 2014.12.19
Published: 2015.04.01

Authors' Contribution:

- A** Study Design
- B** Data Collection
- C** Statistical Analysis
- D** Data Interpretation
- E** Manuscript Preparation
- F** Literature Search
- G** Funds Collection

Hemangioma of Rib: A Different Perspective

Hemant Deshmukh^{ABCDEF}, Kranti K. Rathod^{ABCDEF}, Priya Hira^{ABCDEF},
Shilpa Sankhe^{ABCDEF}, Nilesh Pandit^{ABCDEF}, Kartik Mittal^{ABCDEF}, Amit K. Dey^{ABCDEF}

Department of Radiology, Seth GS Medical College and KEM Hospital, Mumbai, India

Author's address: Kartik Mittal, Department of Radiology, Seth GS Medical College and KEM Hospital, Mumbai, India,
e-mail: amit3kem@gmail.com

	Summary
Background:	Hemangiomas are one of the common primary benign tumors of the intraosseous and soft tissue compartments in humans. Vertebral hemangiomas being the most common of all are seen in daily radiological practice. Hemangioma of the rib is rarely seen.
Case Report:	We reported on a case of a rib lesion which had a classic imaging pattern of hemangioma. We highlighted the use of pre-operative embolization of such a vascular rib lesion before surgically removing the lesion by thoracotomy to reduce the risk of bleeding.
Conclusions:	We also emphasized overt complications of overzealous needling of such a vascular lesion for histopathological diagnosis as in our case.
MeSH Keywords:	Embolization, Therapeutic • Hemangioma • Technology, Radiologic
PDF file:	http://www.polradiol.com/abstract/index/idArt/893011

Background

Intraosseous hemangioma is a radiological diagnosis and most of the lesions are asymptomatic and follow a benign course [1]. Rarely these lesions enlarge and then pose diagnostic difficulties. Rib hemangiomas are difficult to diagnose as they are down in lane in the differentials of rib lesions with very few case reports in the literature. But a fine knowledge in imaging can give a correct diagnosis as in our case.

Hemangiomas show multiple patterns of histological subtypes, but same treatment protocol for all subtypes and hence a preoperative biopsy of such a radiologically imaged vascular lesion can lead to mortifying results [2].

Pre-operative embolization of large rib hemangioma leads to reduction in size and vascularity with effortless excision of the lesion thereby [1,2].

We report this unusual case of symptomatic radiologically imaged classical rib hemangioma undergoing unnecessary biopsy rather than elective embolization and landing up in emergency embolization of the lesion, but finally underwent uncomplicated resection of the shriveled embolized hemangioma.

Case Report

An 18 yrs old female presented in the OPD with history of back pain since 2years which was non radiating and dull in nature with posterior chest wall swelling on the right side increasing in size since 6months. On examination the patient was afebrile with non-tender hard swelling on right side in the posterior chest wall. Blood investigation revealed hemoglobin value of 10 gm% with normal total and differential leucocyte count. ESR and CRP were a little raised. Chest x-ray was done which revealed a well-defined radio-opaque density arising from the 3rd rib (Figure 1). Further an unenhanced chest CT was advised which revealed a well-defined mass with sun burst calcifications causing expansion of the 3rd rib (Figure 2). The patient was then imaged further by MRI which unfolded the diagnosis of this rib lesion, which was T1 hypointense with scattered hyperintensity suggestive of fat, T2 hyperintense with expansion of the trabecular pattern with flow voids and showing intense enhancement and vascular channels within the lesion (Figure 3). The lesion was diagnosed as a benign vascular tumor of the 3rd rib representing hemangioma. Due to rarity of such a rib lesion confirmation by histopathology was insisted and USG guided FNAC was tried which failed due to calcification of the lesion and subsequently a biopsy was done which led

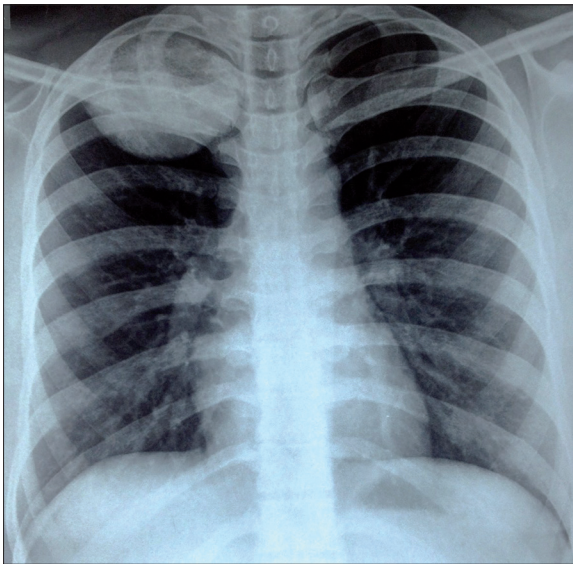


Figure 1. Chest X-ray shows a well-defined radio-opaque density in the right upper hemi thorax arising from the posterior part of the 3rd rib.

to profuse bleeding from the lesion and hemoglobin drop by 3gm% within 3 hrs. Patient was given fluids to make him stable. An emergency embolization of the bleeding hemangioma was planned. The main feeding artery of hemangioma was identified to be originating from the costo-cervical trunk of the second part of the subclavian artery which showed puddling and hold up of the contrast till delayed angiograms confirming hemangioma and further super-selective embolization was done through the costal branch of costo-cervical trunk using gel foam until stagnation was noted (Figure 4). Biopsy revealed the lesion to be consisting of extensive network of vessels lined by endothelial cell layer. Hence, the diagnosis was confirmed as a cavernous hemangioma. The patient was followed up with CT scan which showed decrease in the size of the hemangioma. One month later the patient was taken for thoracotomy with complete excision of the lesion, which was shrunken considerably with minimal blood loss in the

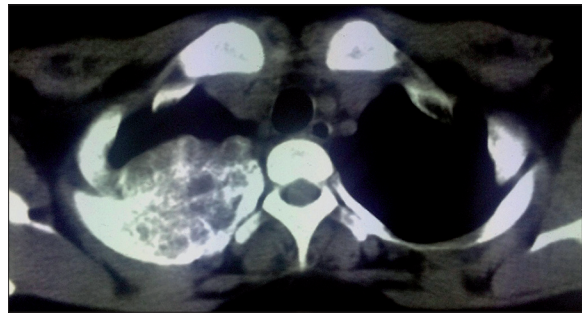


Figure 2. Axial NECT show lobulated heterogeneous mass causing expansion of the rib with sun burst calcification.

surgery. Postoperative course of the patient was uneventful with complete symptomatic, biochemical improvement and radiological improvement (Figure 5). Patient is doing well now and has completely recovered.

Discussion

Rib malignancy represents 5.9% of all the primary bone tumors and out of all rib lesions 89% of them are malignant with rarity of benign lesions [1,2]. A wide range of differential diagnosis of rib lesions ranging from metastasis, primary benign tumors (fibrous dysplasia, osteochondroma, aneurysmal bone cyst, eosinophilic granuloma, and hemangioma) and malignant tumors (chondrosarcoma, osteogenic sarcoma, myeloma, and ewings sarcoma) have been reported in literature with very few reports of “hemangioma of the rib and its management” [1,3], hemangiomas are benign tumors which represent persistent fetal capillary bed with multicentric hamartomous proliferation of the vessels of the dermal sub papillary plexuses [4,5].

Rib hemangiomas are usually asymptomatic being discovered incidentally on a radiologic study [1]. Large lesion cause pain and swelling and rarely hemangioma arising from the first rib may cause thoracic outlet syndrome [6]. CT or MRI can characterize and identify the size and extent of cortical destruction caused by the tumor [1]. Hemangiomas have a characteristic sunburst,

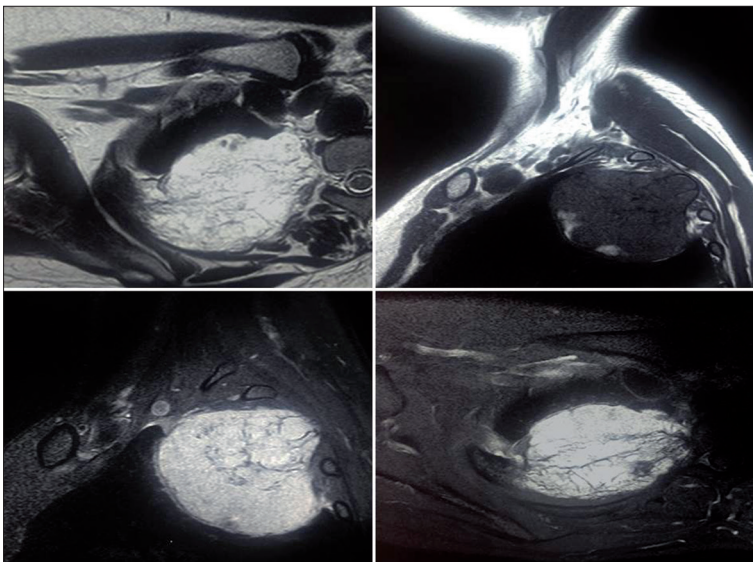


Figure 3. T2 W axial image show lobulated hyperintense lesion with multiple linear hypointensity scattered throughout the lesion suggestive of expanded trabecular pattern. Few flow voids are seen in the periphery of the lesion. T1 precontrast sagittal image show a well-defined isointense lesion arising from the 3rd rib with hyperintensities within suggestive of fat within the lesion. T1 post contrast sagittal and axial images show intense enhancement of the corresponding lesion.

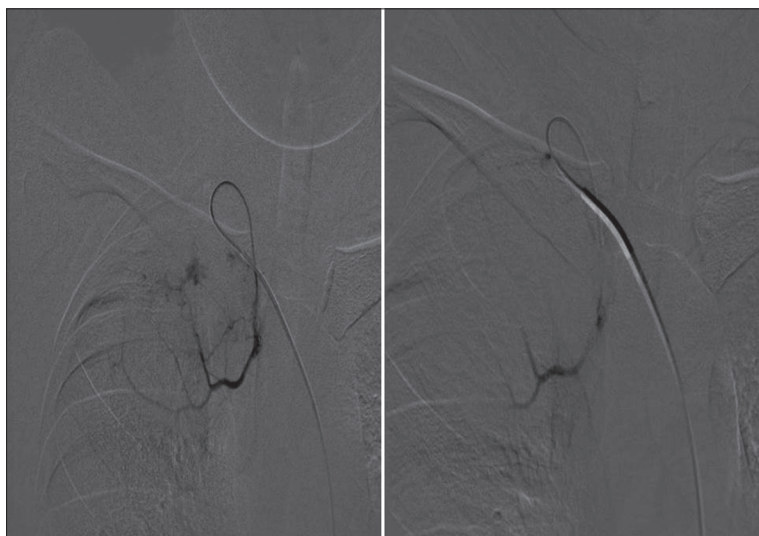


Figure 4. DSA with super selective catheterization of the costal branch of the costocervical trunk by micro catheter shows puddling of the contrast suggestive of hemangioma. Post embolization DSA show adequate stasis of the contrast which is suggestive of satisfactory embolization.

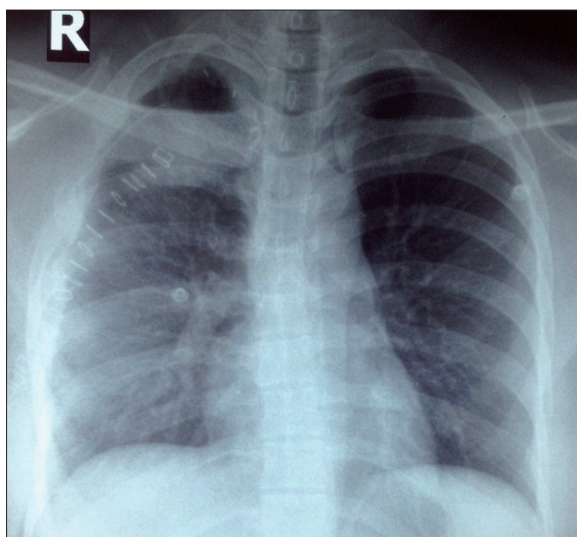


Figure 5. Post-operative chest X-ray showing complete excision of the 3rd rib and the lesion.

honeycombing or soap bubble appearance and present as a well-defined lytic lesion with a coarsened trabecular pattern on plain roentgenograms and computed tomographic images [7]. Presence of phleboliths may fetch the diagnosis straightaway. On MRI hemangioma are very characteristic with variation depending on the proportion of fat and vascular channels. T1 hyperintensity is due to fat containing hemangioma and T2 hyperintensity and flow voids are certainly due to vascular channels. MRI aids in characterization of the lesion for a final diagnosis and its extension [8].

The definitive diagnosis can only be given by histopathological examination of the lesion. But as the lesions are too

vascular with multiple arterial feeders they have tendency of bleeding [7]. Hence they are designated as “dangerous lesions”. Biopsy of such a lesion may be catastrophic as in our patient and as such a risk to benefit ratio should always be kept in mind. However, final diagnosis can be given after excisional biopsy [9].

There are four histological variants of hemangiomas. Cavernous and capillary hemangiomas form the major bulk. The cavernous type consists of large dilated vessels lined by a single layer of endothelial cells surrounded by a fibrous stroma layer. The capillary hemangioma, which is less common, shows numerous tortuous small vascular channels lined with epithelium [1,2].

The mainstay treatment of hemangiomas is surgical excision but large lesions always pose threat as they bleed profusely during surgery. Vertebral hemangiomas embolization is done by trans-arterial, percutaneous or direct intraoperatively by onyx and alcohol respectively [10]. Temporary embolization using gel foam in rib hemangioma causes shrinkage in size and vascularity of the lesion drastically further easing the excision of the lesion [11].

Conclusions

Rib hemangioma is an uncommon encountered primary benign tumor diagnosed radiologically by multi-modality imaging. Atypical lesion and its rarity cause uncertainty in its diagnosis. Our case highlights this rare entity diagnosed radiologically and the role of its pre-operative embolization rather than unneeded needling of such a vascular lesion for a diagnosis as the diagnosis may not swivel the treatment protocol.

References:

1. Abrão FC, Tamagno M, Canzian M et al: Hemangioma of the rib. *Ann Thorac Surg*, 2011; 91(2): 595-96
2. Ceberut K, Aksoy YM, Savas F, Müslehiddinoglu A: Cavernous hemangioma of the rib: a case report. *Asian Cardiovasc Thorac Ann*, 2008; 16: e25-27
3. Jain SK, Songra M, Malhotra A et al: Rib hemangioma: a rare differential for rib tumours. *Indian J Surg*, 2011; 73(6): 447-49
4. Kubo M, Moriyama S, Nogami T et al: Intercostal hemangioma. *JPN J Thorac Cardiovasc Surg*, 2004; 52(9): 435-38

5. Girard C, Graham JH, Johnson WC: Arteriovenous hemangioma (arteriovenous shunt). A clinicopathological and histochemical study. *J Cutan Pathol*, 1974; 1(2): 73–87
6. Yeow KM, Hsieh HC: Thoracic outlet syndrome caused by first rib haemangioma. *J Vasc Surg*, 2001; 33(5): 1118–21
7. Narayan P, Chakrabarthi S, Collins C, Morgan A: Rib haemangioma : a rarity and diagnostic dilemma. *IJTCVS*, 2008; 24: 212–14
8. Ly JQ, Sanders TG: Case 65: hemangioma of the chest wall. *Radiology*, 2003; 229(3): 726–29
9. Nakamura H, Kawasaki N, Taguchi M, Kitamura H: Cavernous hemangioma of the rib diagnosed preoperatively by percutaneous needle biopsy. *Gen Thorac Cardiovasc Surg*, 2007; 55(3): 134–37
10. Hurley MC, Gross A, Surdell D et al: Preoperative onyx embolization of aggressive vertebral hemangiomas. *Am J Neuroradiol*, 2008; 29: 1095–97
11. Mishra R, Rao A, Swamy L et al: Mixed intraosseous haemangioma of the rib – a rare entity. *Internet Journal of Thoracic and Cardiovascular Surgery*, 2014; 17(1)