

Trends of hip arthroscopy in the setting of acetabular dysplasia

Jacob A. Haynes¹, Cecilia Pascual-Garrido², Tonya W. An³, Jeffrey J. Nepple², ANCHOR Group² and John C. Clohisy^{2*}

¹Anderson Orthopaedic Clinic - Mount Vernon, 2501 Parker's Ln, 200, Alexandria, VA 22306, USA,

²Washington University School of Medicine, 660 S. Euclid Ave CB 8233, St. Louis, MO 63110, USA and

³Cedar Sinai Medical Center, 444 S. San Vicente Blvd, Ste 603, Los Angeles, CA 90048, USA

*Correspondence to: J. C. Clohisy, Washington University School of Medicine, 660 S. Euclid CB 8233, St. Louis, MO 63110, USA. E-mail: jclohisy@wustl.edu

Submitted 30 November 2017; Revised 30 May 2018; revised version accepted 8 July 2018

ABSTRACT

Hip arthroscopy is increasingly utilized in the treatment of symptomatic intra-articular hip pathology. Unaddressed development dysplasia of the hip (DDH) is thought to be associated with failure after hip arthroscopy. The aims of this study were (i) to identify the prevalence of previous failed hip arthroscopy in patients undergoing a periacetabular osteotomy (PAO) for the treatment of symptomatic acetabular dysplasia, (ii) report on the temporal trend of failed ipsilateral hip arthroscopy in patients undergoing PAO and (iii) to determine clinical and radiographic characteristics associated with utilization of isolated hip arthroscopy in patients with acetabular dysplasia. We identified 139 patients undergoing PAO who had a history of a prior ipsilateral hip arthroscopy. A comparison group of 1505 patients with a diagnosis of acetabular dysplasia, who underwent PAO alone without any prior ipsilateral surgery during the study period was used. Clinical characteristics, radiographic and intraoperative findings were compared between cohorts. From 2008 to 2015, the rate of previous failed hip arthroscopy in patients undergoing subsequent PAO increased steadily until 2013 with a maximum of 12%. Patients in the study group had mild dysplasia with significantly higher LCEA (17.2° versus 11.3° ; $P < 0.001$) and ACEA (15.6° versus 10.8° ; $P < 0.001$), a lower acetabular inclination (14.0° versus 19.0° ; $P < 0.001$). The findings illustrate a constant increase in the rate of failed hip arthroscopy in the setting of acetabular dysplasia from 2008 till 2013. Female sex and mild dysplasia were associated with use of isolated hip arthroscopy in the setting of acetabular dysplasia.

INTRODUCTION

Hip arthroscopy is increasingly utilized in the treatment of symptomatic intra-articular hip pathology [1]. Between 2006 and 2010, the overall incidence of arthroscopic hip surgery in the United States increased to 600%. It can be effective in relieving common sources of hip pain, including labral tears, articular cartilage lesions and femoroacetabular impingement [2–4]. These pathologic intra-articular conditions often are associated with acetabular dysplasia [5–7]. Classically, treatment of symptomatic acetabular dysplasia has varied from clinical observation to corrective osteotomy surgery.

The use of hip arthroscopy alone in the setting of symptomatic acetabular dysplasia remains controversial as it does not address the underlying structural deformity, for which

the natural history of disease progression has been well documented. In this regard, a recent review found that over 24% of patients with failed hip arthroscopy underwent subsequent corrective acetabular osteotomy for definitive treatment of the structural pathomechanics [8]. Limited evidence exists on patient and disease characteristics associated with failure of hip arthroscopy. It was reported that young female patients with mild to moderate dysplasia and major functional limitations as the population at most risk for requiring definitive PAO for treatment after of persisting symptoms after isolated hip arthroscopy [9]. Additionally, residual structural deformity (either femoral or acetabular side) and underlying osteoarthritis were factors associated with failure of hip arthroscopy as defined by a need for revision hip preservation surgery or arthroplasty [8].

Given the controversy of both its efficacy and the increasing incidence of isolated arthroscopic hip surgery performed in the setting of acetabular dysplasia, a contemporary evaluation of the prevalence and risk factors for failed arthroscopy in patients with hip dysplasia is imperative. The primary purposes of this study were (i) to utilize a large, prospective multi-center database to identify the prevalence of previous ipsilateral failed hip arthroscopy in patients undergoing a PAO for the treatment of symptomatic acetabular dysplasia; (ii) to report on the temporal trend (year by year report) of ipsilateral failed hip arthroscopy in patients undergoing a PAO for the treatment of acetabular dysplasia over the time interval of this study and (iii) to determine clinical and radiographic differences between a cohort of patients with acetabular dysplasia who underwent isolated hip arthroscopy and a matched group who had not undergone prior hip arthroscopy.

MATERIALS AND METHODS

Study design

A prospective multi-center longitudinal PAO cohort was searched to identify all patients who underwent PAO following a prior failed ipsilateral hip arthroscopy surgery from January 2009 to December 2015. This study received institutional board review approval at all participating sites. All patients had hip pain that persisted despite conservative treatment, typically consisting of physical therapy and activity modification, as well as clinical exam findings and radiographic signs of acetabular dysplasia [10]. Inclusion criteria were a preoperative diagnosis of acetabular dysplasia and prior ipsilateral failed arthroscopic hip surgery. Failed hip arthroscopy was diagnosed if the patient had

recurrent symptoms after hip arthroscopy to such a degree that they returned for a revision hip preservation surgical procedure. Exclusion criteria included a primary diagnosis other than acetabular dysplasia, and any prior ipsilateral hip surgery other than isolated hip arthroscopy. Hips with alternative etiologies of dysplasia including neuromuscular disorders, Legg-Calve-Perthe's and Charcot-Marie-Tooth disease were also excluded. A comparison group included all patients from the cohort with a diagnosis of acetabular dysplasia, who underwent PAO without any prior ipsilateral surgery (arthroscopic or open), during the study period.

Patient cohorts

Between January 2008 and December 2015, 1684 patients (1891 hips) were enrolled in the prospective multi-center PAO cohort. Of this group, 61 hips (3.6%) were excluded due to a preoperative diagnosis of FAI alone. Sixty-nine other cases (3.6%) were excluded for additional primary etiologies of disease, with neuromuscular disorders ($n = 18$), Legg-Calve-Perthes deformity ($n = 17$), and Charcot-Marie-Tooth disease ($n = 12$) being the most common exclusions. The remaining 1761 hips (1568 patients) carried a primary preoperative diagnosis of acetabular dysplasia. In this group of 1761 hips, 256 (14.5%) had a history of previous ipsilateral hip surgery. Of this subgroup, 139 hips (54.3%) had a prior isolated arthroscopic hip procedure. The final study group was comprised of 139 cases of PAO (93% females) following an isolated prior ipsilateral arthroscopic hip procedure (Fig. 1). The average age of the cohort was 24.3 (range: 14–44) years old at the time of the PAO.

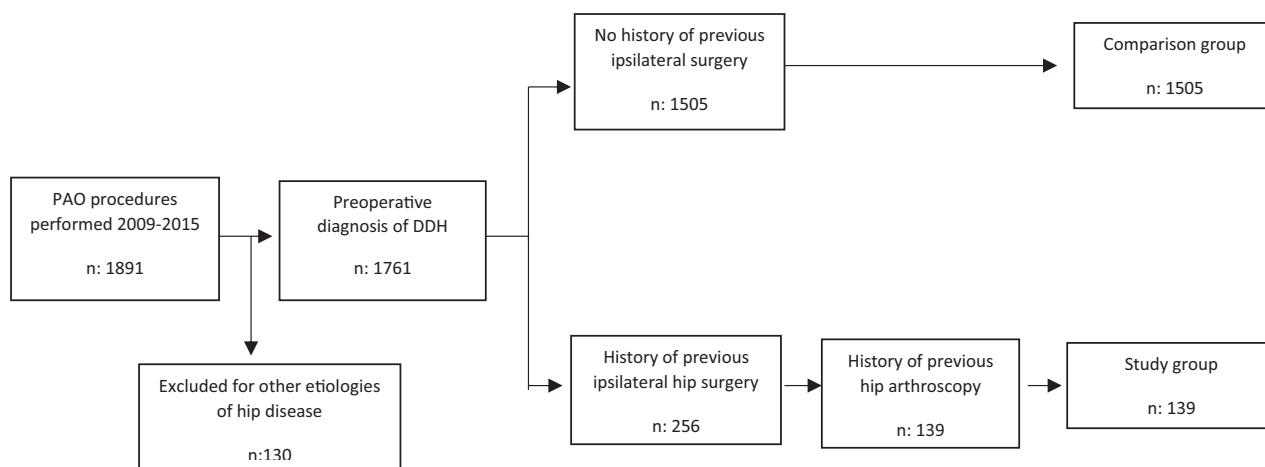


Fig. 1. Study cohort selection criteria.

Radiographic analysis

All included patients had preoperative radiographs, which included an antero-posterior pelvis (AP), frog-lateral or cross-table lateral, false profile, and a 45° or 90° Dunn lateral view [11–13]. From the radiographs, the lateral center edge angle (LCEA), anterior center edge angle (ACEA), acetabular inclination, minimum joint space width (JSW) and Tönnis grade of osteoarthritic change were determined [14]. Patients were classified as having mild acetabular dysplasia if the LCEA was 15–20° and acetabular inclination (AI) was 10–15° [15].

Intraoperative findings

Operative findings were recorded by the treating surgeon. Labral tears and chondral injury of the femoral head and acetabulum were classified using the modified Beck classification [16, 17]. For the study group, the time to failure, defined as time interval between surgical date of hip arthroscopy and surgical date of PAO, was calculated.

Statistical analysis

Descriptive statistics were generated to compare the demographic and clinical characteristics of both groups. Statistical methods included z-test for comparing proportions, Student *t*-test for means of continuous variables, chi-square analysis for categorical variables. The proportion of PAO after failed hip arthroscopy between the beginning and end of the study period was compared by means of a

z-test. All probability tests were two-tailed with $P < 0.05$ regarded as statistically significant.

RESULTS

Prevalence of previous failed hip arthroscopy

Forty (29.0%) initial arthroscopies were performed at one of the included sites, while 99 (71.0%) were performed at an outside institution. The average interval between initial hip arthroscopy and PAO was 29.8 months (range, 4 months–9.9 years). The comparison group consisted of the remaining 1505 hips (1436 patients) with a diagnosis of acetabular dysplasia who underwent PAO without any prior ipsilateral hip surgery. This group was comprised of 1192 females (83%) and 244 males (17%), with an average age of 25.5 years (range: 10–51). The study group had a significantly higher percentage of females and a significantly lower BMI when compared with the comparison group ($P = 0.01$). Those patients who underwent previous failed hip arthroscopy also demonstrated a longer clinical duration of hip pain symptoms prior to PAO ($P < 0.001$) (Table I).

Prevalence of PAO after a failed hip scope

Over the study period, the total number of PAO procedures increased at an average rate of 26% (range: 3–112%) per year. In comparison, the incidence of PAO after previous failed ipsilateral hip arthroscopy has grown, on average, by 41% (range: 0–143%) per year. The percentage of PAO

Table I. Comparison of demographic and clinical variables between the study and control groups

	PAO after previous failed hip arthroscopy	PAO without previous surgery	P-value
N	139	1505	
Demographics			
Age at time of surgery	24.3 (6.8) Range: 15–44	25.5 (9.2) Range: 10–51	0.20
Gender	129 F: 10 M	1192 F: 244 M	0.01
BMI	23.4 (3.9) Range: 17.6–40.7	24.6 (4.7) Range: 15.1–46.6	0.01
Pain chronicity			
Less than 6 months	1.0%	6.5%	0.03
6 months–1 year	10.1%	25.2%	<0.001
1–3 years	44.4%	41.3%	0.53
3–5 years	27.2%	10.9%	<0.001
5+ years	15.2%	14.8%	0.72

procedures following a prior failed hip arthroscopy ranged from 5% to 12% (Fig. 2). Hip arthroscopy comprised 100% of all surgeries prior to PAO in the final year of the study period, compared to 33% initially. The change in incidence of PAO following prior hip arthroscopy from 5.1% of all PAOs in 2008 to 10% of all PAOs in 2015 was statistically significant ($P = 0.004$) and represents a 192% increase.

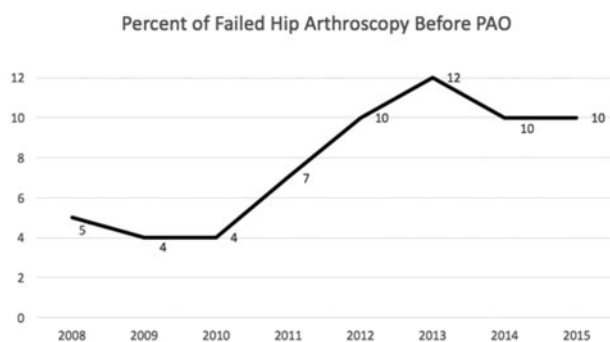


Fig. 2. Prevalence of failed hip arthroscopy prior to PAOs performed between 2008 and 2015.

Clinical and radiographic features of use of isolated hip arthroscopy in dysplastic patients

At the time of PAO, 38% ($n = 53$) of the study group versus 23% ($n = 346$) of the comparison group underwent a combined procedure including an arthroscopic hip procedure ($P < 0.001$). In the study patients undergoing a combined PAO/hip arthroscopy procedure, 71% ($n = 38$) underwent labral repair or debridement, 32% ($n = 17$) had an acetabular chondroplasty performed and 68% ($n = 36$) underwent femoral head/neck osteochondroplasty. In the study group patients undergoing PAO without concomitant arthroscopy, 6.9% ($n = 6$) underwent labral repair or debridement, 1.1% ($n = 1$) had an acetabular chondroplasty and 47.6% ($n = 41$) had a femoral head/neck osteochondroplasty completed through an arthrotomy. Overall, a statistically greater number of study group patients required a combined HS/PAO procedure for treatment of intraarticular pathology compared with the comparison group ($P < 0.001$) (Table II).

When comparing the radiographic measurements between the study and the comparison group, the patients in the study group had a significantly higher LCEA (17.2°

Table II. Operative procedure details comparing study and control groups

Operative results	PAO after failed HS (Study group)	PAO without previous surgery (Control group)	P-value
Hip arthroscopy details			
Performed at ANCHOR sites	40/139	N/A	
Performed at OSH	99/139	N/A	
Time to failure	29.8 months Range: 4 months–9.9 years	N/A	
Primary PAO details			
Combined arthroscopy/PAO	38%	23.3%	<0.001
With labral repair/refixation/resection	71%	63.8%	0.38
With acetabular chondroplasty	32%	31.1%	0.95
With femoral head/neck osteochondroplasty	68%	77.0%	0.25
PAO	62%	74.8%	<0.001
With labral repair/refixation/resection	6.9%	7.1%	0.42
With acetabular chondroplasty	1.1%	5%	0.33
With femoral head/neck osteochondroplasty	47.6%	4.2%	0.33
Intervention for labral pathology (all cases)	33%	20%	<0.001

Table III. Radiographic characteristics of study and control cohorts

Radiographic features	PAO after failed HS	PAO without previous surgery	P-value
Tonnis grade			0.70
Grade 0	61.6%	58.0%	
Grade 1	32.3%	35.4%	
Grade 2	3.0%	4.2%	
Grade 3	0%	0.2%	
Minimum joint space width, mm	4.0 SD: 1.2	4.4 SD: 1.0	0.001
Lateral center edge angle, degrees	17.2 SD: 10.8	11.3 SD: 10.0	<0.001
Acetabular inclination, degrees	14.0 SD: 7.2	19.0 SD: 8.5	<0.001
Anterior center-edge angle, degrees	15.6 SD: 14.3	19 SD: 12.2	<0.001

versus 11.3°; $P < 0.001$) and ACEA (15.6° versus 10.8°; $P < 0.001$), a lower acetabular inclination (14.0° versus 19.0°; $P < 0.001$) and smaller JSW (4.0 mm versus 4.4 mm; $P = 0.001$) when compared with the control population (Table III). Additionally, patients in the study group had a mean alpha angle of 48.9° (range 22–117 degrees) measured on an AP radiograph after their isolated arthroscopic surgery, but prior to their PAO procedure.

DISCUSSION

The main findings of this multi-center study were that the prevalence of a prior failed ipsilateral arthroscopic hip procedure in patients undergoing a subsequent PAO for the correction of symptomatic acetabular dysplasia has increased 192%, from 2008 to 2015 (5.1–10%). While the incidence of ipsilateral surgery, other than hip scope, prior to PAO remained constant over the duration of the study, the proportion of prior hip surgeries that are arthroscopic procedures has more than tripled, and in the final year of the study represented 100% of all surgeries prior to definitive PAO. Importantly, a lower BMI, female gender and radiographically mild acetabular dysplasia were associated with the utilization of isolated hip arthroscopy in the setting of acetabular dysplasia.

The use of hip arthroscopy, as a stand-alone procedure, to address labral pathology in the setting of acetabular dysplasia remains controversial. A recent systematic review, reported on 13 studies on the role of arthroscopy in the dysplastic hip [18]. The authors concluded that arthroscopic treatment of mild dysplasia could yield satisfactory results whereas treatment of more dysplastic hips is controversial, with no evidence of optimal results for hips with a center edge angle $< 20^\circ$. [18] Parvizi *et al.* reported on 34 patients

with a diagnosis of acetabular dysplasia who had undergone isolated hip arthroscopy for labral injury. Seventy percent failed to obtain pain relief, 79% progressed to OA and 47% required an additional open surgical treatment [7]. In two separate studies examining revision hip preservation surgery, Clohisy *et al.* and Ricciardi *et al.* found that inadequately corrected structural deformity (FAI and DDH) was the most common indication for revision hip preservation surgery [19, 20]. In both studies, hip arthroscopy represented over 80% of the prior surgeries, and PAO was utilized for acetabular reorientation at time of revision in all patients with underlying acetabular dysplasia.

Conversely, other authors have reported acceptable early clinical outcomes with arthroscopic hip surgery for labral pathology in the setting of acetabular dysplasia. Domb and colleagues reported good to excellent clinical outcomes, with significant improvement in post-operative outcome scores, at 3-year follow up in 17 of 26 patients with mild dysplasia, who underwent arthroscopic labral repair and concomitant inferior capsular shift [21]. It is worth noting that at 2 years after surgery, their patient population saw a decline in their Non-Arthritic Hip Score (NAHS), Hip Outcome Score-Sport-Specific Subscale (HOS-SSS) and Hip Outcome Score-Activity of Daily Living (HOS-ADL) scores, while the Modified Harris Hip Score (mHHS) continued to show improvement. Byrd *et al.*, in a study of 48 patients, showed equivalent clinical outcomes, as measured by the mHHS, at 27 months between dysplastic and non-dysplastic patients undergoing isolated hip arthroscopy [5]. Clinical outcomes were associated with intra-articular pathology, with patients being treated for loose bodies or ligamentum ruptures experiencing the best outcomes, while patients being treated for labral or chondral injuries did moderately well [5]. Patients

in their study cohort also demonstrated a decrease in their mHHS scores between 12 and 24 months post-operatively. Jayasekera *et al.* [6] examined a cohort of 66 patients (12 with acetabular dysplasia and 54 without) undergoing isolated hip arthroscopy, and found statistically significant improvement in the mHHS at 1 year follow-up in both groups, with no significant difference in clinical outcome between the dysplastic and non-dysplastic populations. Of note, both of these studies reported on findings at short-term follow-up. Additional data on hip arthroscopy in the setting of acetabular dysplasia is needed to determine the long-term clinical results of this patient population.

A concerning fact revealed by our present study was an exponential increase in the prevalence of dysplastic patients undergoing a PAO that had a prior failed arthroscopic hip procedure. Of note, a significantly increased number of patients (33% vs 20%) in this group required a concomitant procedure, in conjunction with the PAO, to treat labral pathology. This finding may represent the fact that, despite initial treatment of the labral injury via isolated arthroscopy, the residual pathomechanics associated with acetabular dysplasia resulted in persistent abnormal loading of the labrum, causing further injury. This is consistent with multiple prior studies highlighting that the abnormal load distribution seen in the dysplastic hip is associated with increased acetabular rim stress and shear forces at the chondral-labral junction [16, 22–24]. Our findings illustrate that younger age, female gender and mild radiographic dysplasia were associated with higher rates of utilization of isolated arthroscopic hip surgery in the presence of acetabular dysplasia. These results agree with the findings of a preliminary report by Ross *et al.* that found failed arthroscopy and the need for PAO was most commonly observed in young female patients with mild-to-moderate acetabular dysplasia [9]. In Ross's study, the average LCEA, ACEA and acetabular inclination in patients who required PAO after failed hip arthroscopy were 14.7°, 16.8° and 16.3°, respectively. These results are also similar to the findings of Kain *et al.*, who reported on a cohort of 17 patients who had failed prior arthroscopy and went on to PAO and compared them to a population of patients who underwent PAO alone [25]. The patients that tend to be misdiagnosed are those with mild dysplasia. This is important because while these patients have mild acetabular dysplasia, as determined by standard radiographic criteria, the early outcomes with isolated arthroscopy are variable. Thus, the appropriateness of isolated arthroscopy in this patient population must be questioned.

We acknowledge limitations to this study. First, because a number of the initial arthroscopic hip surgeries were performed at a site other than one of the included sites of our multi-center group, comprehensive data on the initial hip

arthroscopy, as well as the clinical decision-making process indicating the patient for arthroscopic surgery, was unable to be obtained for some patients. Second, there is a lack of information on those patients with dysplasia who underwent an isolated arthroscopic hip surgery and had good results. This possible referral bias may explain the rise in percentage of hip scope failure comprising the cohort. Unfortunately, this limitation is inherent to data collected at a tertiary referral practice. In addition, patients who failed arthroscopy and were subsequently treated with arthroplasty (rather than revision hip preservation) are not captured in this cohort. Finally, this article was not intended to address the clinical results of patients undergoing PAO after prior ipsilateral hip arthroscopy, as this has been investigated in other studies [25].

In conclusion, the findings of this study illustrate a substantial increase in the rate of PAO after previous failed hip arthroscopy over the past 6 years. While the rate of PAO following previous ipsilateral surgery has remained relatively constant, a growing proportion of those previous surgeries are unsuccessful hip arthroscopies. Additionally, we have identified female sex and mild dysplastic features as characteristics associated with use of isolated hip arthroscopy in the presence of acetabular dysplasia. Collectively, these data call into question the role of isolated hip arthroscopy for the treatment of patients with intra-articular hip disease associated with acetabular dysplasia.

ACKNOWLEDGMENTS

Members of the ANCHOR Group:

Paul Beaulé; Ottawa General Hospital, Ottawa, Ontario, Canada
 John Clohisy MD; Washington University School of Medicine, St. Louis, MO, USA
 Young-Jo Kim, MD, PhD; Boston Children's Hospital, Harvard Medical School, Boston, MA, USA
 Michael Millis, MD; Boston Children's Hospital, Harvard Medical School, Boston, MA, USA
 Jeffrey Nepple, MD; Washington University School of Medicine, St. Louis, MO, USA
 Eduardo Novais, MD; University of Colorado, CO, USA
 Christopher Peters, MD; University of Utah, UT, USA
 David Podeszwa, MD; Texas Scottish Rite Hospital, Dallas, TX, USA
 Perry L. Schoenecker; Washington University School of Medicine, St. Louis, MO, USA
 Rafael Sierra, MD; Mayo Clinic, Rochester, MN, USA
 Ernest Sink, MD; Hospital for Special Surgery, New York, NY, USA

Daniel Sucato, MD; Texas Scottish Rite Hospital, Dallas, TX, USA

Robert Trousdale, MD; Mayo Clinic, Rochester, MN, USA

Ira Zaltz, MD; William Beaumont Hospital–Royal Oak, Royal Oak, MI, USA

CONFLICT OF INTEREST STATEMENT

None declared.

FUNDING

This work was supported by: The Curing Hip Disease Fund [JCC] and The ANCHOR Research Fund [ANCHOR Investigators].

REFERENCES

- Dwyer MK, Lee JA, McCarthy JC. Cartilage status at time of arthroscopy predicts failure in patients with hip dysplasia. *J Arthroplasty* 2015; **30**: 121–24.
- Bozic KJ, Chan V, Valone FH *et al*. Trends in hip arthroscopy utilization in the United States. *J Arthroplasty* 2013; **28**: 140–3.
- Colvin AC, Harrast J, Harner C. Trends in hip arthroscopy. *J Bone Joint Surg Am Vol* 2012; **94**: e23.
- Maradit Kremers H, Schilz SR, Van Houten HK *et al*. Trends in utilization and outcomes of hip arthroscopy in the United States Between 2005 and 2013. *J Arthroplasty* 2016.
- Byrd JW, Jones KS. Hip arthroscopy in the presence of dysplasia. *Arthroscopy* 2003; **19**: 1055–60.
- Jayasekera N, Aprato A, Villar RN. Hip arthroscopy in the presence of acetabular dysplasia. *Open Orthopaedics J* 2015; **9**: 185–7.
- Parvizi J, Bican O, Bender B *et al*. Arthroscopy for labral tears in patients with developmental dysplasia of the hip: a cautionary note. *J Arthroplasty* 2009; **24**: 110–3.
- Bogunovic L, Gottlieb M, Pashos G *et al*. Why do hip arthroscopy procedures fail? *Clin Orthopaedics Relat Res* 2013; **471**: 2523–9.
- Ross JR, Clohisy JC, Baca G *et al*. Patient and disease characteristics associated with hip arthroscopy failure in acetabular dysplasia. *J Arthroplasty* 2014; **29**: 160–3.
- Clohisy JC, Ackerman J, Baca G *et al*. Patient-reported outcomes of periacetabular osteotomy from the prospective ANCHOR cohort study. *J Bone Joint Surg Am Vol* 2017; **99**: 33–41.
- Dunn DM. Anteversion of the neck of the femur; a method of measurement. *J Bone Joint Surg Br Vol* 1952; **34-B**: 181–6.
- Lequesne M, de S. False profile of the pelvis. A new radiographic incidence for the study of the hip. Its use in dysplasias and different coxopathies. *Rev Rhumat Malad Osteo-Articul* 1961; **28**: 643–52.
- Clohisy JC, Nunley RM, Otto RJ *et al*. The frog-leg lateral radiograph accurately visualized hip cam impingement abnormalities. *Clin Orthopaedics Relat Res* 2007; **462**: 115–21.
- Tonnis D. Letter: congenital hip dysplasia: clinical and radiological diagnosis (author's transl). *Z Orthopadie Ihre Grenzgebiete* 1976; **114**: 98–9.
- Grammatopoulos G, Beaulé PE, Pascual-Garrido C *et al*. Does severity of acetabular dysplasia influence clinical outcomes after periacetabular osteotomy? - a case-control study. *J Arthroplasty* 2018; **33**: S66–70.
- Beck M, Kalhor M, Leunig M *et al*. Hip morphology influences the pattern of damage to the acetabular cartilage: femoroacetabular impingement as a cause of early osteoarthritis of the hip. *J Bone Joint Surg Br Vol* 2005; **87**: 1012–8.
- Nepple JJ, Larson CM, Smith MV *et al*. The reliability of arthroscopic classification of acetabular rim labrochondral disease. *Am J Sports Med* 2012; **40**: 2224–9.
- Jo S, Lee SH, Wang SI *et al*. The role of arthroscopy in the dysplastic hip - a systematic review of the intra-articular findings, and the outcomes utilizing hip arthroscopic surgery. *J Hip Preserv Surg* 2016; **3**: 171–80.
- Clohisy JC, Nepple JJ, Larson CM *et al*. Academic network of conservation hip outcome research M. Persistent structural disease is the most common cause of repeat hip preservation surgery. *Clin Orthopaedics Relat Res* 2013; **471**: 3788–94.
- Ricciardi BF, Fields K, Kelly BT *et al*. Causes and risk factors for revision hip preservation surgery. *Am J Sports Med* 2014; **42**: 2627–33.
- Domb BG, Stake CE, Lindner D *et al*. Arthroscopic capsular plication and labral preservation in borderline hip dysplasia: two-year clinical outcomes of a surgical approach to a challenging problem. *Am J Sports Med* 2013; **41**: 2591–8.
- Klaue K, Durnin CW, Ganz R. The acetabular rim syndrome. A clinical presentation of dysplasia of the hip. *J Bone Joint Surg Br* 1991; **73**: 423–9.
- Chegini S, Beck M, Ferguson SJ. The effects of impingement and dysplasia on stress distributions in the hip joint during sitting and walking: a finite element analysis. *J Orthopaedic Res* 2009; **27**: 195–201.
- Nepple JJ, Carlisle JC, Nunley RM *et al*. Clinical and radiographic predictors of intra-articular hip disease in arthroscopy. *Am J Sports Med* 2011; **39**: 296–303.
- Kain MS, Novais EN, Vallim C *et al*. Periacetabular osteotomy after failed hip arthroscopy for labral tears in patients with acetabular dysplasia. *J Bone Joint Surg Am Vol* 2011; **93**: 57–61.