

Oral treatment with valacyclovir for HSV-2-associated eczema herpeticum in a 9-month-old infant

A case report

Kaiwen Zhuang, MD^a, Qiong Wu, MM^b, Xin Ran, MM^a, Yuping Ran, MD, PhD^{a,*}, Liu Ding, MM^c, Xiaoxi Xu, MM^a, Song Lei, MM^d, Jebina Lama, MM^a

Abstract

Background: Eczema herpeticum is a rare, severe, and disseminated infection of herpes simplex virus in the setting of eczematous skin diseases.

Methods: We experienced a case of this disease in a 9-month-old infant characterized by a sudden onset of monomorphic vesicles on the head, right lower leg, and two hands. The infant has a 7-month history of atopic dermatitis and his condition was initially regarded as a complication of atopic dermatitis and bacterial infection. After treatment of cefoperazone and dexamethasone, the eruptions got worse. The diagnosis of eczema herpeticum was made according to the clinical features and further confirmed by the findings of herpes simplex virus type 2.

Results: The infant was cured by oral treatment with valacyclovir.

Conclusion: The case highlights that the awareness for the sign of eczema herpeticum when diagnosing children with a sudden onset of disseminated vesicles in the setting of chronic skin disease should be increased. Oral valacyclovir may be an effective and convenient treatment option for pediatric outpatients with eczema herpeticum.

Abbreviations: AD = atopic dermatitis, EH = eczema herpeticum, HSV = herpes simplex virus, PCR = polymerase chain reaction, TEM = transmission electron microscopy.

Keywords: atopic dermatitis, eczema herpeticum, infant, transmission electron microscopy, valacyclovir

1. Introduction

Eczema herpeticum (EH), a form of Kaposi's varicelliform eruption, is a secondary disseminated infection of herpes simplex virus (HSV) in the setting of eczematous skin diseases, usually atopic dermatitis (AD). HSV-1 is more common in EH than HSV-2.^[1] EH occurs with an incidence of 3% to 6% of infants with AD.^[2] Children, <3 years of age, are reported to be at the highest risk of developing EH with an equal male–female ratio.^[3] We saw a case of this disease in an infant and related its clinical features.

Editor: Ken Rosenthal.

The authors have no conflicts of interest to disclose.

^a Department of Dermatovenereology, West China Hospital, Sichuan University,

^b Department of Diagnostic Ultrasound, Second University Hospital of Sichuan University, ^c Department of Lab Medicine, ^d Department of Pathology, West China Hospital, Sichuan University, Chengdu, Sichuan Province, China.

* Correspondence: Yuping Ran, NO. 37, Guo Xue Xiang, Wuhou District, Chengdu, Sichuan Province, China (e-mail: ranyuping@vip.sina.com).

Copyright © 2016 the Author(s). Published by Wolters Kluwer Health, Inc. All rights reserved.

This is an open access article distributed under the Creative Commons Attribution-No Derivatives License 4.0, which allows for redistribution, commercial and non-commercial, as long as it is passed along unchanged and in whole, with credit to the author.

Medicine (2016) 95:29(e4284)

Received: 15 March 2016 / Received in final form: 23 June 2016 / Accepted: 24 June 2016

<http://dx.doi.org/10.1097/MD.0000000000004284>

2. Case report

A 9-month-old boy, weighing 8 kg, was presented to our outpatient department of dermatology with a sudden onset of monomorphic vesicles on the head, right lower leg, and both hands 4 days earlier. The infant has a 7-month history of AD, which mainly involved in the areas of his head and face. The infant suddenly exhibited a fever (39–40°C) 7 days earlier and was treated with intravenous cefoperazone and dexamethasone (5 mg/d) on suspicion of AD complication and bacterial infection. A rash appeared on the third day of treatment and was considered by the infant's primary physician to be an exacerbation of AD and continued for 4 additional days of the former treatment until the eruption got worse. On physical examination, the infant had a temperature of 38.7°C and diffuse, erythematous, vesicles on the head, face, arms, and hands. The regions on the head and face had crusted. Some yellow crusts were noted on the top area of head as the residual sign of AD (Fig. 1A). Vesicles in multiple phases appeared on the back of both arms and hands (Fig. 1B). His serum HSV IgG antibody was positive, whereas IgM was negative. Based on the clinical features, the infant was initially diagnosed with EH and prescribed oral valacyclovir (Glaxo Wellcome, SA) 125 mg 2 times daily and compound glycyrrhizin capsules 1 tablet/d. Wet dressing (0.1% acyclovir eye drops) was applied to the region 2 times daily. The samples of vesicles and crusts were taken for further confirmation as we previously described.^[4] Observation of the blister wall with transmission electron microscopy (TEM) revealed numerous viral particles within the keratin fibers and the nucleus of keratinocyte (Fig. 2).

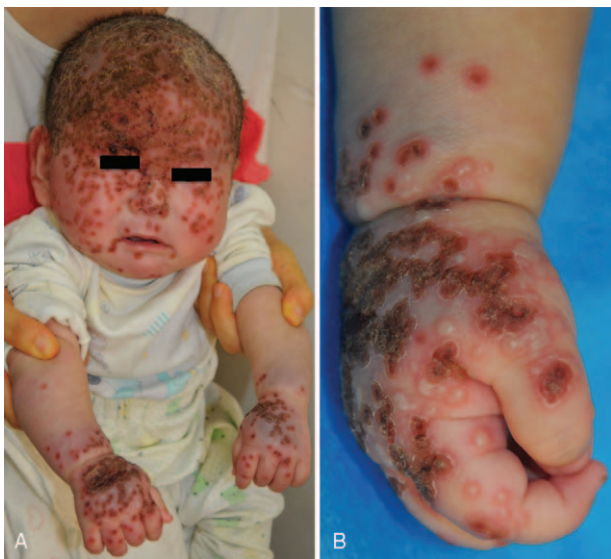

Figure 1. Clinical features before antiviral treatment. (A) Diffuse, erythematous, vesiculous, crusted, and eroded lesions in the areas of head, face, arms, and hands. (B) Vesicles in multiple phases on the back of right hand and right arm.

The vesicle fluid and crust were positive for HSV-2-specific DNA, whereas negative for HSV-1 on the real-time PCR (Light Cycler 2.0, Roche Diagnostics Corporation, USA) with HSV fluorescence assay kit (Da An gene Co., Ltd, China). After 4 days of treatment, the infant's condition had improved markedly with all vesicles crusted and his temperature returned to normal (Fig. 3A and B). Then the antiviral regimen was continued for another 5 days. The herpetic lesions had almost cleared by the seventh day of the start of the treatment (Fig. 4A and B). But the infant's parents reported that valacyclovir was only taken for the first 4 days as they worried about possible side effect of the antiviral agent. Meanwhile, they increased the frequency of wet dressing to 4 times daily without the occurrence of contact sensitization. In the follow up of 6 months later, there had been no recurrence.

3. Discussion

EH is characterized by the sudden onset of disseminated, monomorphic, and dome-shaped vesicles, generally associated

with fever, malaise, and lymphadenopathy. Very often, the herpetic eruptions start in the areas affected by AD, such as the head, hands, and the upper body regions and also can spread to involve the normal skin from 7 to 10 days.^[3] Within 2 weeks, the blisters begin to dry out, crust, and form erosive pits that heal without scarring during 2 to 6 weeks.^[2] The diagnosis of EH is made mainly based on clinical manifestations. Polymerase chain reaction (PCR) can rapidly identify the HSV with high sensitivity and specificity as well as type the herpes virus, whereas TEM can reveal the location and morphologic features of virus particles in the infected cells. The finding of viral type-specific DNA or viral particles respectively by the two methods from blister fluid and viral culture can confirm the disease. Immunofluorescence testing has diagnostic value as well.^[2]

Clinically, EH is easy to be misdiagnosed as an exacerbation of the patient's underlying chronic eczematous skin conditions with dire sequelae. Feye et al^[5] reported a 38-year-old man with EH in setting of long-standing AD was misdiagnosed as an exacerbation of his primary dermatitis. Systemic application of high-dose corticosteroids resulted in progression of his ocular HSV-1 infection to bilateral keratitis, which can result in scarring and blindness.^[5] Additionally, missing the diagnosis of EH, frequently seen in pediatric patients with AD, can lead to disseminated cutaneous and systemic infections of herpes simplex, which may be accompanied by bone marrow suppression and disseminated intravascular coagulation which resulted in the death of an infant.^[6] In our case, failure, at the earlier stage, to recognize the occurrence of EH in the setting of AD led to systemic steroid therapy for a week causing the spread of the herpes simplex. Therefore, it is imperative to improve the alertness to EH and recognize the link between chronic dermatitis and the potential herpetic infection.

In treatment, the introduction of effective antiviral agents is the paramount regime. Presently, acyclovir is the most potent drug for pediatric patients with EH. There are no clear guidelines outlining the management of those patients, specifically, which patients should be hospitalized to receive IV acyclovir therapy and which can be managed as outpatients using oral acyclovir.^[2] A retrospective cohort study involving 79 patients aged 0 to 18 years with EH revealed either oral acyclovir, IV and oral acyclovir, or IV acyclovir alone were effective to EH of various severities.^[2] In children, usually intravenous acyclovir (15–30 mg/kg/d, divided 3 times daily for 7–10 days) is applied to severe

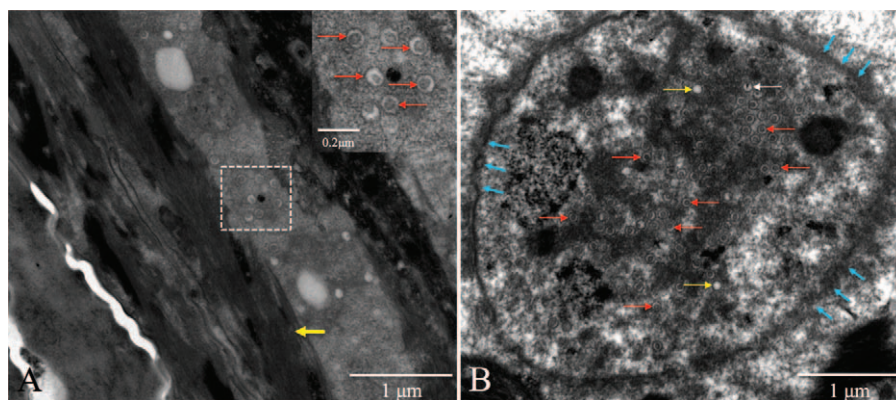


Figure 2. Observation of the EH's blister wall under TEM. (A) Many virus particles (red arrow) were noted inside the blister wall composed by keratin fibers (yellow arrow). (B) Numerous virus particles in multiple stages existed in the nucleus of infected epidermal cells: hollow nucleocapsid (yellow arrow), particle shape nucleocapsid (red arrow), and dense nucleocapsid (white arrow) of HSV, karyotheca of keratinocyte (blue arrow). EH=eczema herpeticum, HSV=herpes simplex virus, TEM=transmission electron microscopy.

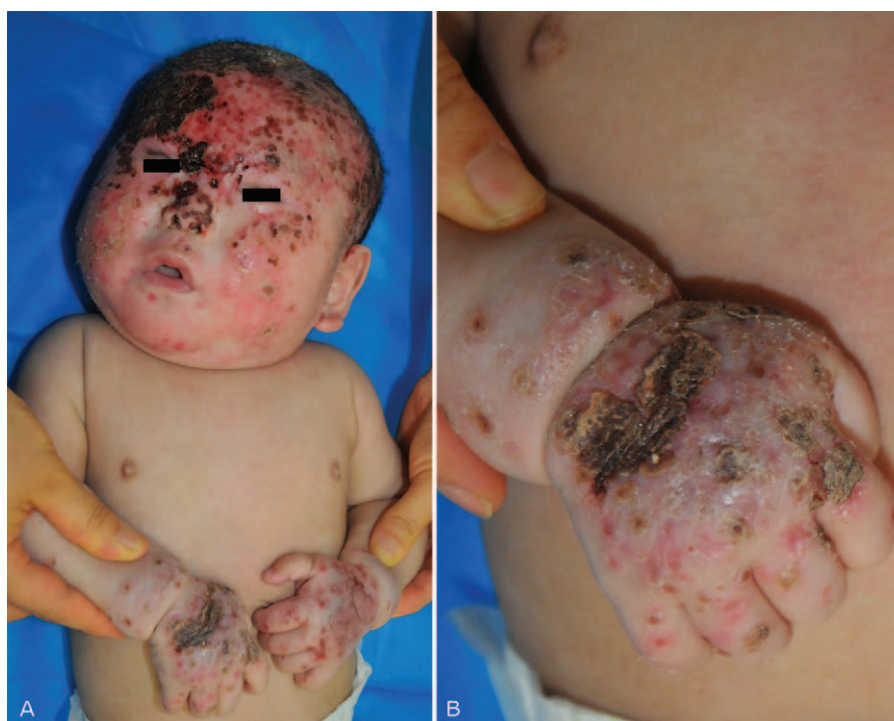

Figure 3. Change of the herpetic eruptions after 4 days of treatment. (A, B) The infant's condition had improved markedly with all vesicles crusted and his temperature returned to normal.

cases, whereas the oral acyclovir is administered in mild cases. The recommended dosage for oral acyclovir is 30 to 60 mg/kg/d, divided into 3 doses/d for 10 days.^[2] The clinical utility of acyclovir, however, is limited by its low oral bioavailability and need for frequent dosing.

Valacyclovir, an L-valyl ester prodrug of acyclovir, can be almost completely converted to acyclovir by liver and intestinal valacyclovirase after oral administration.^[7] Its mechanism of action, antiviral spectrum, and resistance are the same as acyclovir, whereas its oral bioavailability is superior to acyclovir.

With an oral bioavailability ~3- to 5-fold greater than oral acyclovir, valacyclovir can be administered less frequently and can achieve the plasma acyclovir concentrations similar to those seen with intravenous acyclovir in adults.^[7,8] Among children (3 months–11 years of age) with HSV infection, multicenter studies indicate that the 20 mg/kg dose of the formula of the oral valacyclovir can result in favorable acyclovir blood concentrations and is well tolerated.^[7] There are few reports on the efficacy of valacyclovir in the treatment of EH. In adults, Wollenberg et al^[3] recommend a 7-day course of oral valacyclovir (500 mg by mouth 3 times daily) for EH treatment, which can be prolonged according to the clinical course.^[9] In addition, glycyrrhizin, licorice root extract, has multiple pharmacologic effects like the anti-inflammatory activity and antiviral effect against *Herpesviridae* family viruses by inhibiting the replication of virus.^[10] Application of this extract in the acute phase of EH not only can reduce the inflammation at lesions, but also can strengthen the antiviral therapy.

In summary, EH is a rare entity and the awareness for the sign of this herpes infection when diagnosing children with chronic skin disease should be increased. An exacerbation of atopic disease with a fever and sudden onset of vesiculopapular eruptions in a pediatric patient should raise a high suspicion of EH. Oral valacyclovir may be an effective and convenient treatment option for pediatric outpatients with EH.

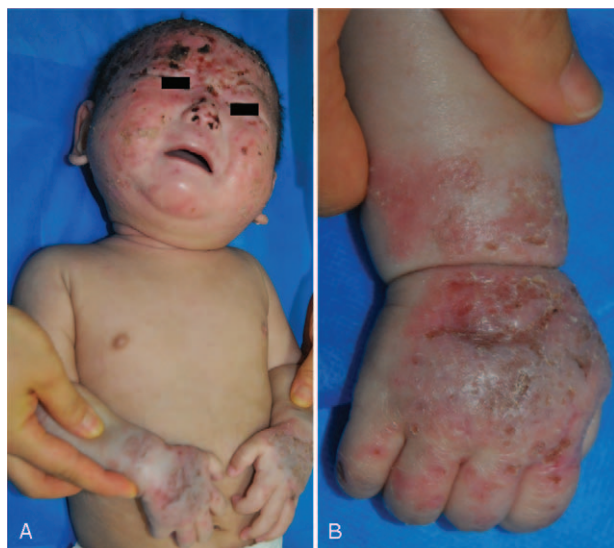

Figure 4. A complete remission was achieved. (A, B) The herpetic lesions had almost cleared by the seventh day from the start of treatment.

References

- [1] Gupta R, Warren T, Wald A. Genital herpes. *Lancet* 2007;22:2127–37.
- [2] Luca NJ, Lara-Corrales I, Pope E. Eczema herpeticum in children: clinical features and factors predictive of hospitalization. *J Pediatr* 2012;161:671–5.
- [3] Wollenberg A1, Zoch C, Wetzel S, et al. Predisposing factors and clinical features of eczema herpeticum: a retrospective analysis of 100 cases. *J Am Acad Dermatol* 2003;49:198–205.

- [4] Zhuang KW, Ran YP, Xu FN, et al. Atypical infantile genital molluscum contagiosum. *An Bras Dermatol* 2015;90:403–5.
- [5] Feye F, Halleux CD, Gillet J, et al. Exacerbation of atopic dermatitis in the emergency department. *Eur J Emerg Med* 2004;11:360–2.
- [6] Kosann MK, Fogelman JP, Stern RL. Kaposi's varicelliform eruption in a patient with Grover's disease. *J Am Acad Dermatol* 2003;49:914–5.
- [7] Kimberlin DW, Jacobs RF, Weller S, et al. Pharmacokinetics and safety of extemporaneously compounded valacyclovir oral suspension in pediatric patients from 1 month through 11 years of age. *Clin Infect Dis* 2010;50:221–8.
- [8] Shinkai II, Ohta Y. New drugs: reports of new drugs recently approved by the FDA. Valacyclovir. *Bioorg Med Chem* 1996;4:1–2.
- [9] Wollenberg A, Wetzel S, Burgdorf WH, et al. Viral infections in atopic dermatitis: Pathogenic aspects and clinical management. *J Allergy Clin Immunol* 2003;112:667–74.
- [10] Ashfaq UA, Masoud MS, Nawaz Z, et al. Glycyrrhizin as antiviral agent against hepatitis C virus. *J Transl Med* 2011;18:112–8.