

Identification of risk factors affecting bone formation in gradual ulnar lengthening in children with hereditary multiple exostoses

A retrospective study

Yuchan Li, MD^{a*}, Bingqiang Han, MD^a, Jingyan Tang, PhD^b, Mu Chen, MD^a, Zhigang Wang, MD^a

Abstract

The forearm deformity classified by Masada is a characteristic trait of patients with hereditary multiple exostoses (HME). Ulnar gradual lengthening, which was considered to be a safe and reliable procedure, was popular in treating these difficult deformities, however, delayed consolidation of the callus is uncommon but not rare in literature review. The purpose of this study was to try to identify the risk factors influencing bone healing in gradual ulnar lengthening in HME.

We retrospectively reviewed patients with HME-induced forearm deformity who underwent gradual ulnar lengthening at our hospital from 2010 to 2016. Patients' demographic data, forearm deformity of Masada type, surgical procedure, ulnar diameter of osteotomy site, and external fixator type were recorded. We also reviewed radiographical data included gained length, axis deviation, callus form. Clinical outcome was assessed by the bone healing index (HI). Multiple linear regression was used to analyze the relationships between different parameters and the HI, the level of significance was set $P < .05$.

Thirty-three patients were included in this study. The mean follow-up period was 1.5 (range 0.5–8) years. Circular external fixators were used in 5 patients and monolateral external fixators were used in 28 patients. The mean achieved length was 4.24 cm. The mean HI was 50.3 (range 26.6–99.3) days/cm. In patient with monolateral external fixator, patient's age was positively correlated with the bone HI ($P = .001$), while diameter and body mass index (BMI) were negatively correlated with the HI ($P = .040, .018$, respectively). Patient's sex, removal of distal ulnar exostoses, lengthening percentage, and axis deviation were non-significant in the regression model.

When using monolateral external fixator for ulnar lengthening, patient's age, diameter of osteotomy site, and BMI are the most important risk factors related to bone formation. Pediatric orthopedic surgeons should consider these variables in order to avoid delayed union.

Abbreviations: BMI = body mass index, HI = healing index, HME = hereditary multiple exostoses.

Keywords: healing index, hereditary multiple exostoses, ulnar lengthening

1. Introduction

Hereditary multiple exostoses (HME), also known as multiple osteochondromas, is an autosomal dominant condition characterized by multiple benign cartilage-capped tumors, which typically occur at the juxta-epiphyseal region of tubular bones.

Editor: Yan Li.

YL, BH, and JT contributed equally to this work and should be considered as co-first authors.

The authors have no conflicts of interest to disclose.

^a Department of Pediatric Orthopedics, ^b Department of Hematology and Oncology, Shanghai Children's Medical Center, Shanghai Jiaotong University School of Medicine, Shanghai, China.

* Correspondence: Yuchan Li, Shanghai Children's Medical Center, Shanghai Jiaotong University School of Medicine, 1678 Dongfang Road, Shanghai 200127, P.R. China (e-mail: karinelyc@hotmail.com).

Copyright © 2019 the Author(s). Published by Wolters Kluwer Health, Inc. This is an open access article distributed under the terms of the Creative Commons Attribution-Non Commercial License 4.0 (CCBY-NC), where it is permissible to download, share, remix, transform, and build up the work provided it is properly cited. The work cannot be used commercially without permission from the journal.

Medicine (2019) 98:5(e14280)

Received: 31 May 2018 / Received in final form: 12 December 2018 / Accepted: 7 January 2019

<http://dx.doi.org/10.1097/MD.0000000000014280>

As the exostoses are located near the growth plate, they can cause various deformities and functional impairment. Solomon reported that the distal ends of the radius and ulna are affected in 85% and 68% of cases, respectively.^[1] The main exostoses located at the distal end of forearm resulted in a relative shortening of the ulna; a secondary bowing of the radius, ulnar deviation, and dislocation of the radial head comprised the most commonly seen deformities on radiography and such deformities has been reported in 40% to 74% of patients with HME.^[2] Masada et al classified the forearm deformities into 3 types, patients with type I and type II were more common.^[3]

Although some authors suggest that forearm deformity in HME does not affect function in adults,^[4] Clement and Porter reported that a shorter proportional ulnar length was associated with a diminished range of motion of the forearm and radial head dislocation.^[2] Gradual lengthening of the ulna is popular for treating forearm deformities in HME and several studies have reported satisfactory results with this technique.^[5–11] However, absent callus formation in the distraction gap delayed consolidation and regenerate bone fracture may also occur in this procedure.^[4,12] This could prolong the external fixator time, increase the rate of complications,^[13] and lead to psychological or financial problems for patients and their families.

The risk factors affect bone healing were discussed by some authors, both intrinsic patient factors and technical factors are

associated with callus formation during lengthening,^[14–16] however, there is few literature reported the risk factors of delay consolidation in ulnar lengthening. The purpose of this study is to try to identify the risk factors of delayed consolidation in HME patients who underwent ulna gradual lengthening. We hypothesize that the patient factors including age, sex, nutrition status, ulnar diameter and surgical related factors including distal ulnar exostoses resection, stability of the external fixator, axis deviation, lengthening amount will affect the regenerate bone healing.

2. Materials and methods

This was a retrospective, nonrandomized study. We retrospectively reviewed all our patients with HME-induced forearm deformity who underwent gradual ulnar lengthening in Shanghai Children's Medical Center from March 2010 to October 2016. Forearm deformity was classified according to the Masada classification.^[3] Patients with Masada type I or type II deformity and with complete clinical and radiographic data were included. Patients with solitary exostoses or other pathological conditions were excluded. The written informed consent was obtained from all patients' parents and guardians and the research was conducted according to the principles of the Declaration of Helsinki declaration.

Patients' demographic data including age at surgery, sex, height, and weight were collected from medical record. The body mass index (BMI) was measured and indicated the nutritional status of the patients, a BMI lower than the mean for the same age was considered poor nutrition.^[17] We also reviewed the surgical data including the operative procedures, type of external fixator (monolateral and circular), ulnar diameter at the osteotomy site, and duration of external fixation. The gained length was measured on the lateral radiographic view. The real distraction speed was calculated as the distraction gap (mm) divided by the number of days of distraction. The bone healing index (HI), a

reference variable to evaluate the regenerate bone healing, was calculated as the number of days of external fixator treatment per centimeter length gained. The percentage of lengthening was calculated as the gained callus length divided by the primary length of the ulna. We standardized the measurement method, and 1 author did all measurement on the X-ray.

The 2 senior authors performed all surgical procedures. The operative technique consisted of gradual ulnar lengthening with or without exostoses removal, depending on whether large exostoses involved the distal ulna. The circular fixator (Fig. 1) or a monolateral (Fig. 2) fixator was used at the surgeon's discretion. Thus, the patients were divided into 2 groups, group A, distraction with a circular frame; and group B, distraction with a monolateral fixator. In all patients, an ulnar transverse mid-diaphyseal subperiosteal osteotomy was performed using a Gigli saw. The latency period was 5 days for circular fixator and 10 days for monolateral fixator. Lengthening was stopped once the elongation reached the desired length and the fixator was maintained for callus consolidation. All patients were evaluated clinically and radiologically every 2 weeks during the distraction phase and monthly during the consolidation phase. The callus forms on the radiograph of the early consolidation (first month of consolidation stage) were evaluated according to Li et al's classification.^[18] Delayed consolidation was defined as no callus or a sparse-density callus at the end of distraction.

2.1. Statistical methods

Statistical analyses were performed using the Statistical Package for the Social Sciences version 17.0 (IBM, Armonk, NY). Pearson's or Spearman's rho correlation analysis was used to assess the relationships between continuous variables or ordinal variables. For nonparametric data, the Mann–Whitney *U* test was used to check for significant differences between groups. Stepwise linear regression analysis was used to identify the influencing factors. The dependent variable was HI and the

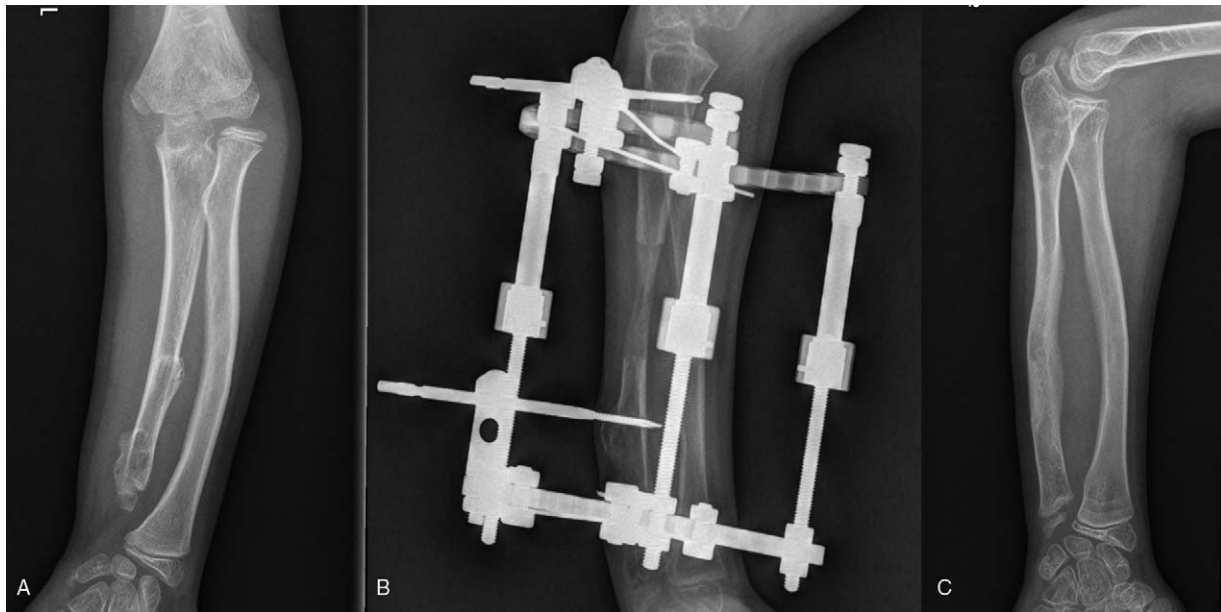

Figure 1. (a, b) The ulnar was gradual lengthened using a circular external frame, show a significant shorter bone healing index in this study, 3.8 cm were gained and the HI for this 10-year-old boy is 40.7 days/cm. (c) Radiograph of the forearm 14 months after external fixator removed, good relationship between the forearm bones and good remodelling of regenerate bone. HI=healing index

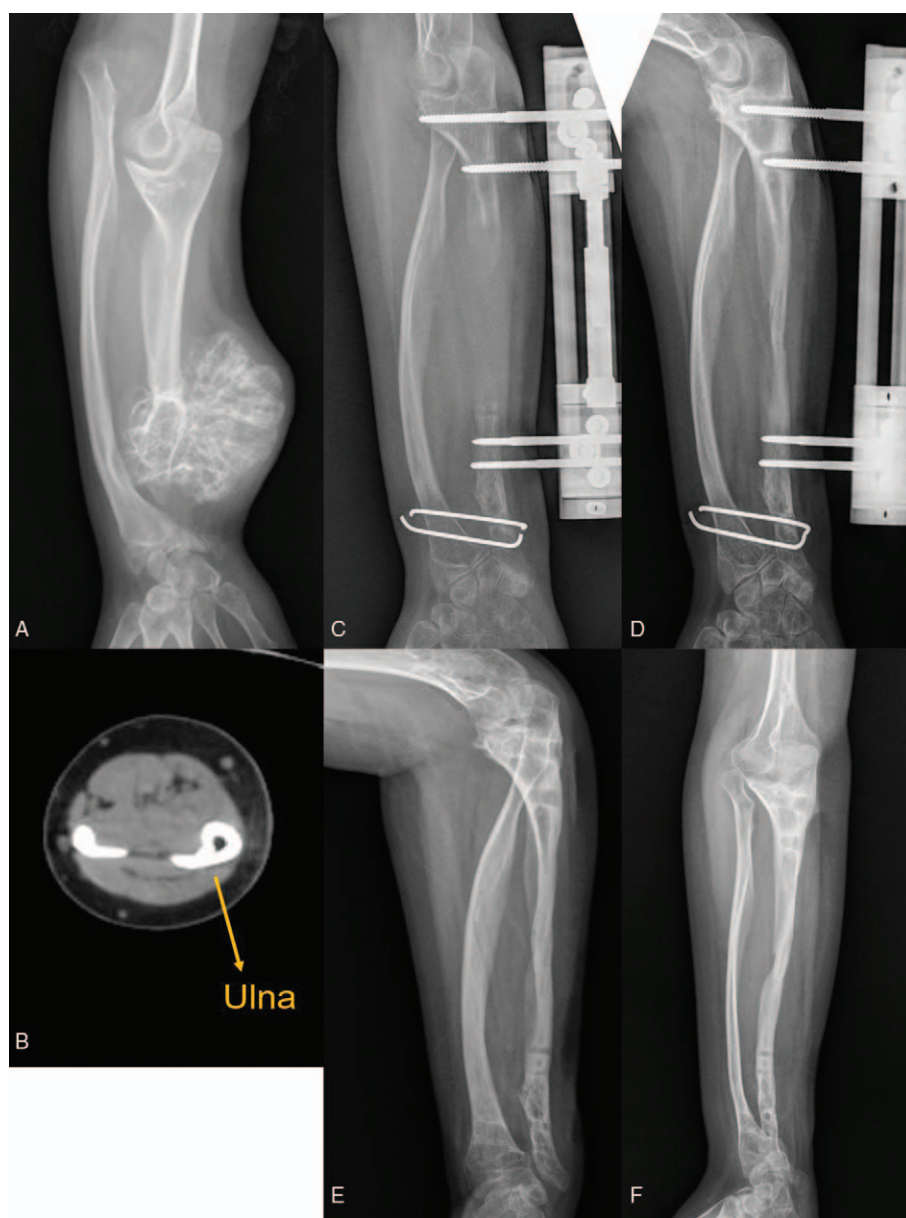


Figure 2. A 15-year-old boy was presented with Masada type IIb forearm deformity: (a) The growth of distal ulna epiphysis was disturbed by a huge exostosis. (b) Although the ulnar looks thick on the radiograph, CT scan showed a small diameter of the ulna. (c) The distal radioulnar joint was temporarily fixed by 2 k-wires in order to maintain the traction of the radius, the gained length of this boy was 8.6 cm and the lengthening percentage was 46.8%, however, the distraction callus could not be observed 365 days after the osteotomy. (d) This boy was treated with autologous iliac marrow cancellous bone grafting with BMP, the external fixator was kept to maintain the stability till the bone union. (e, f) One year follow-up after external fixator removal, although radial head was not reduced, the appearance and the function were much improved. BMP=bone morphogenetic protein.

independent variables were age, sex, BMI, ulnar diameter of osteotomy site, removal of distal ulnar exostoses, lengthening percentage, and axis deviation. Both the stability of external fixator and the distraction speed were not analyzed as independent variables because of a small size of circular fixator group and adjustable distraction speeding during lengthening. The level of significance was set $P < .05$.

3. Results

Thirty-three patients (20 boys, 13 girls) met the inclusion criteria, the mean age at surgery was 10.4 (range 5.7–15.1) years. The mean follow-up was 1.5 (range 0.5–8) years. All of patients were

unilateral forearm deformities, included 10 Masada type I and 23 type II. Seventeen patients' BMI was lower than the mean for the same age according to the Li et al's BMI growth charts.^[19] The circular external fixators were used in 5 patients (group A) and monolateral fixators were used in 28 patients (group B). Excisions of distal ulnar exostoses were performed simultaneously in 14 patients.

The mean ulnar diameter of the osteotomy site was 1.0 cm (range 0.5–1.8). The mean gain in length was 4.2 (range 2.5–8.6) cm and the mean lengthening percentage was 27.0% (range 13.3–46.8%). The mean distraction speed was 0.85 mm/day (range 0.57–1.13). The mean period of external fixator application was 212.3 (range 91–651) days and the mean HI

Table 1**Clinical data of group A and group B.**

	Group A	Group B
Number of cases	5	28
Age, yr	10.4 (6–12.6)	10.4 (5.7–15.1)
Mean ulnar diameter, cm	1.2 (0.8–1.8)	1.2 (0.5–1.4)
Mean gain in length, cm	4.1 (2.8–5.9)	4.2 (2.5–8.6)
Mean lengthening amount, %	26.4 (19.2–40.9)	27 (13.3–46.8)
Mean distraction speed, mm/days	0.9 (0.7–1.1)	0.8 (0.6–1.1)
Mean duration of external fixation, days	137 (99–157)	225 (91–651)
Mean healing index, days/cm	34.1 (26.6–40.7)	53.2 (26.8–99.3)
Exostoses removal, cases	0	14

Group A, distraction with a circular frame; group B, distraction with a monolateral fixator.

was 50.3 (range 26.6–99.3) days/cm, the results for both groups are shown in Table 1.

The mean HI of group A was 34.1 days/cm that showed a significantly shorter than group B ($P=.012$). In group B, regarding independent factors affecting HI, the data showed that patients' age was positively correlated with HI ($P=.001$), while ulnar diameter of osteotomy site and BMI were negatively correlated with HI ($P=.040$ and $.018$, respectively) (Table 2). Moreover, the HI of patients older than 12.5 years was 68.2 days/cm, which showed a significant longer HI compare to 48.2 days/cm of young patients ($P=.005$). Other factors including sex, lengthening percentage, axis deviation, and removal of the exostoses were not found to be significantly correlated with HI ($P>.05$).

Complications included pin-tract infection (21%) and transient neurological problems (6%). Mild axis deviations were found in 7 patients (21%) and all of them used monolateral fixators (Table 3). One patient presented with nonunion as the distraction callus could not be observed 365 days after the osteotomy (Fig. 2).

4. Discussion

In this study, we found that the patient's age, ulnar diameter of osteotomy site, and BMI were important parameters that can assist in predicting bone healing in patients who undergo ulnar lengthening. Although delayed consolidation or nonunion is uncommon complication in ulnar lengthening, it can prolong external fixation duration and affect clinical outcome. D'Amboise et al reported a case of ulna nonunion that was resolved by autografting and a locking compression plate (LCP) plate;^[5] however, they did not further discuss the risk factors for delayed union or nonunion. Peterson et al treated radial longitudinal deficiency by ulnar distraction lengthening and proposed that

Table 2
Independent factors affecting bone healing index on linear regression multivariate analysis with the use of a stepwise model in group B ($R^2=0.675$).

Predictors	B	95%CI		P value
		Lower	Upper	
Constant	51.094	27.305	85.342	.006
Age	4.637	2.188	7.085	.001
BMI	-13.579	-24.604	-2.553	.018
Diameter of ulna	-2.638	-5.230	-0.136	.040

In this regression model, the age, BMI and diameter of ulna were significantly correlated with the bone healing index.

Table 3**Complications noted in this study.**

Complications	Number of cases
Pin-tract infection	7
Transient neurological problems	2
Wrist joint contracture	5
Mild axis deviations	7
Delayed union	6
Nonunion	1
Fracture	6

extreme lengthening and pin infection might be associated with delayed union.^[20] Mader et al considered the osteotomy site might affect the callus stability and formation.^[21] Nevertheless, less published literature has concentrated on the risk factors of malunion.

The patient's age was an important factor influenced the bone healing which has been reported by other authors. Paley et al noted a significantly long healing time in the adult (age over 20 years),^[22] their further investigation found that young adults healed faster than adults above 30 years old.^[23] Castelein et al also observed more fracture complications in patients older than 18 years in a study of lower limb lengthening.^[24] Our results are consistent with these authors, we found a positive linear correlation ship between age and HI in patients with monolateral external fixator. Moreover, our data demonstrated that even in children, the younger children usually healed faster, the mean HI of patients older than 12.5 years was longer than young patients ($P=.005$).

The patient's nutritional status is crucial to bone metabolism, poor nutritional status might adversely affect callus consolidation. Lumpkin et al reported that good nutritional support in the distraction osteogenesis rat model led to the formation of mineralized regenerate bone in the distraction gap; the increased numbers of osteoclasts observed in the good nutritional support group indicated an accelerated entry into the remodeling phase of consolidation.^[25] Our research showed that BMI was negatively related with HI, which supported their results (Fig. 3). Patient in lower BMI may with low bone mineral density and bone mineral content lead to poor bone formation, which needs be verified in further study.

The mean HI of the ulna ranges from 41 to 64 days/cm, as reported in several studies, and is longer than that of the lower limb.^[5,11,12,20,26] The smaller diameter leads to more difficult in ulnar lengthening than lower limb. Our data show the diameter of ulnar osteotomy site was negatively correlated with HI, confirmed that a large cross-sectional diameter is beneficial to bone healing. Metaphyseal distraction, as opposed to diaphyseal distraction, was usually considered based on this the theory.

Some authors reported a larger amount of lengthening increased the risk of complications; the limitation of lengthening was set at 15% to 25% of the original length.^[26,27] Meanwhile, Villa et al proposed that a larger amount of lengthening leads to an hourglass-shape callus because of the push of the surrounding muscles and named it as "bubble gum effect".^[28] Although we did not find a significant relationship between the amount of lengthening and HI, our nonunion case seemed coincidence with this theory, the lengthening percentage was to 46.8%, which resulted poor callus formation in the distraction gap.

We once assumed that the distal ulnar exostoses resection may affect the regenerate bone healing by disturbing the local blood

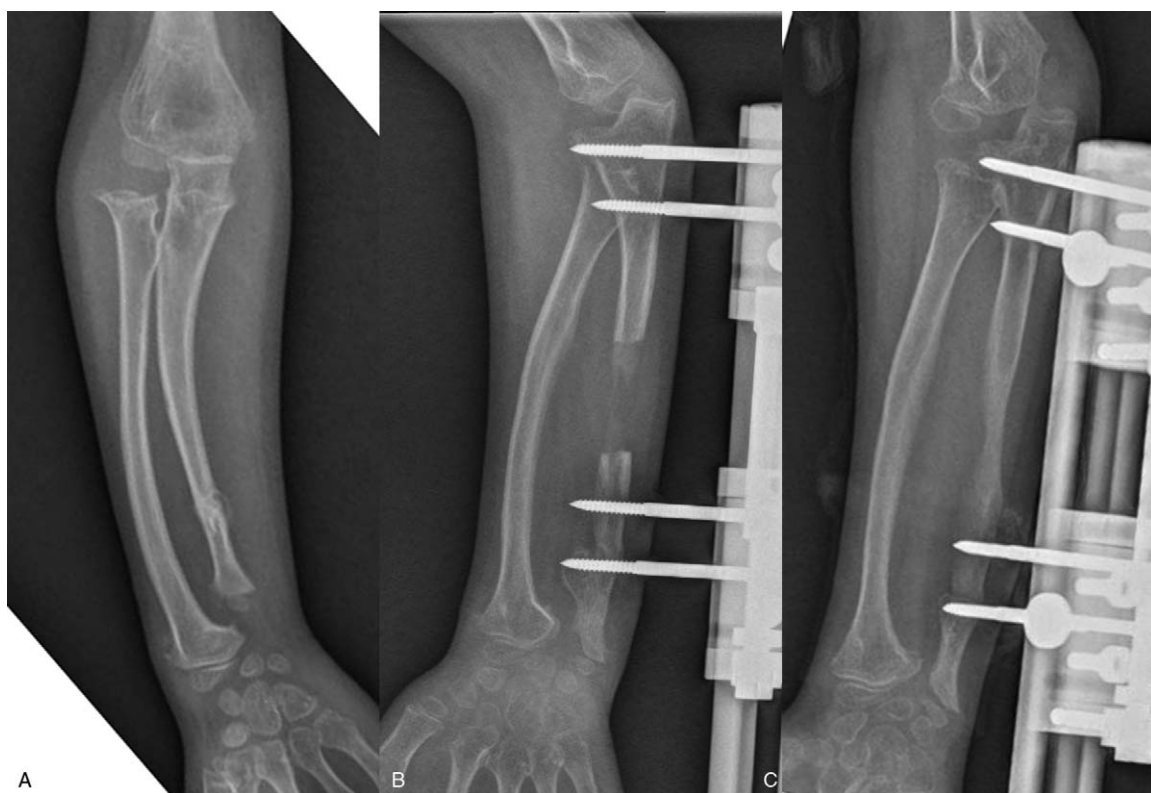


Figure 3. (a) A 9.7-year-old boy with Masada type I forearm deformity; he had a BMI of 14.1 kg/m^2 which was below the 50th percentile for children in his age range. (b) The ulna was gradual lengthened by a monolateral external fixator, radiograph showed lucent intermediate-density callus figure when 3.4 cm was gained. (c) Concave shape of regenerate bone was observed nearly 8 months after surgery; the bone healing index was 68.5 days/cm. BMI=body mass index.

supply, however, there was no correlation with the HI. Although axis deviation is regarded as a risk factor resulted in poor healing,^[14] our data could not demonstrate that the axis deviation leads to a longer HI. Further investigation in a larger sample size may provide new evidence.

We acknowledged several limitations of this study. First, the retrospective nature of our study is a major limitation. Second, the circular frame is more stable and can correct multi-planar deformity, the significant shorter HI with better callus formation and less axis deviation showed the reliable stability of the circular fixator. However, we could not compare the outcome of the 2 type external fixators, as a small sample size of 5 cases implies low statistical power and could not do further statistical analysis. Thus, most results of statistical analysis come from group B. Lack of control group is the third limitation, patients with other pathological conditions might have been a useful control group, while there were not enough data to form this group. These limitations restrict the generalizability of the results. Further investigation of these parameters in a large size sample is still needed. However, our study may be the first research to provide the information about the risk factors affecting bone healing in gradual ulnar lengthening in patients with HME.

5. Conclusions

Although successful clinical results of ulnar gradual lengthening were obtained in treating Masada type I or II deformity in HME, delayed consolidation was observed in this procedure. Based on our results, we recommended careful preoperative evaluation of patient in HME, special attention should be paid to patients with

older age (>12.5 years) and poor nutrition status when using monolateral fixator for ulnar lengthening, moreover, we also emphasize an ulnar metaphyseal osteotomy instead of diaphyseal for distraction.

Acknowledgment

We thank Haoqi Cai, Wanglin Zhang, and Kaiying Shen, for help with preparation of the manuscript, we also thank Shiyue Zhang for assisting with the statistical analysis in this study.

Author contributions

Data curation: Yuchan Li, Jingyan Tang, Zhigang Wang.
Formal analysis: Bingqiang Han, Jingyan Tang, Zhigang Wang.
Investigation: Bingqiang Han, Mu Chen.
Methodology: Yuchan Li, Jingyan Tang.
Project administration: Mu Chen.
Supervision: Yuchan Li, Mu Chen.
Writing – original draft: Yuchan Li, Bingqiang Han.
Writing – review & editing: Yuchan Li, Jingyan Tang, Zhigang Wang.
 Yuchan Li orcid: 0000-0002-2605-9727.

References

- [1] Solomon. Hereditary multiple exostosis. *J Bone Jt Surg Br Vol* 1963;45:292–304.
- [2] Clement ND, Porter DE. Forearm deformity in patients with hereditary multiple exostoses: factors associated with range of motion and radial head dislocation. *J Bone Jt Surg Am Vol* 2013;95:1586–92.

- [3] Masada K, Tsuyuguchi Y, Kawai H, et al. Operations for forearm deformity caused by multiple osteochondromas. *J Bone Jt Surg Br Vol* 1989;71:24–9.
- [4] Akita S, Murase T, Yonenobu K, et al. Long-term results of surgery for forearm deformities in patients with multiple cartilaginous exostoses. *J Bone Jt Surg Am Vol* 2007;89:1993–9.
- [5] D'Ambrosi R, Barbato A, Caldarini C, et al. Gradual ulnar lengthening in children with multiple exostoses and radial head dislocation: results at skeletal maturity. *J Child Orthop* 2016;10:127–33.
- [6] Refsland S, Kozin SH, Zlotolow DA. Ulnar distraction osteogenesis in the treatment of forearm deformities in children with multiple hereditary exostoses. *J Hand Surg* 2016;41:888–95.
- [7] Matsubara H, Tsuchiya H, Sakurakichi K, et al. Correction and lengthening for deformities of the forearm in multiple cartilaginous exostoses. *J Orthop Sci Off J Jpn Orthop Assoc* 2006;11:459–66.
- [8] Irani RN. Ulnar lengthening for negative ulnar variance in hereditary multiple osteochondromas. *J Pediatr Orthop B* 1992;1:143–7.
- [9] Pritchett JW. Lengthening the ulna in patients with hereditary multiple exostoses. *The Journal of bone and joint surgery British volume* 1986;68:561–5.
- [10] Ip D, Li YH, Chow W, et al. Reconstruction of forearm deformities in multiple cartilaginous exostoses. *J Pediatr Orthop Part B* 2003;12:17–21.
- [11] Cho YJ, Jung ST. Gradual lengthening of the ulna in patients with multiple hereditary exostoses with a dislocated radial head. *Yonsei Med J* 2014;55:178–84.
- [12] Hill RA, Ibrahim T, Mann HA, et al. Forearm lengthening by distraction osteogenesis in children: a report of 22 cases. *J Bone Jt Surg Br Vol* 2011;93:1550–5.
- [13] Liantis P, Mavrogenis AF, Stavropoulos NA, et al. Risk factors for and complications of distraction osteogenesis. *Eur J Orthop Surg Traumatol* 2014;24:693–8.
- [14] Sabharwal S. Enhancement of bone formation during distraction osteogenesis: pediatric applications. *J Am Acad Orthop Surg* 2011;19:101–11.
- [15] Mamada K, Nakamura K, Matsushita T, et al. The diameter of callus in leg lengthening: 28 tibial lengthenings in 14 patients with achondroplasia. *Acta Orthop Scand* 1998;69:306–10.
- [16] Tjernstrom B, Olerud S, Rehnberg L. Limb lengthening by callus distraction. Complications in 53 cases operated 1980-1991. *Acta Orthop Scand* 1994;65:447–55.
- [17] Jo AR, Jung ST, Kim MS, et al. An evaluation of forearm deformities in hereditary multiple exostoses: factors associated with radial head dislocation and comprehensive classification. *J Hand Surg* 2017;42:e1–8.
- [18] Li R, Saleh M, Yang L, et al. Radiographic classification of osteogenesis during bone distraction. *J Orthop Res Off Publ Orthop Res Soc* 2006;24:339–47.
- [19] Li H, Ji CY, Zong XN, et al. Body mass index growth curves for Chinese children and adolescents aged 0 to 18 years. *Zhonghua Er Ke Za Zhi = Chin J Pediatr* 2009;47:493–8.
- [20] Peterson BM, McCarroll HR Jr, James MA. Distraction lengthening of the ulna in children with radial longitudinal deficiency. *J Hand Surg* 2007;32:1402–7.
- [21] Mader K, Gausepohl T, Pennig D. Shortening and deformity of radius and ulna in children: correction of axis and length by callus distraction. *J Pediatr Orthop Part B* 2003;12:183–91.
- [22] Paley D. Problems, obstacles, and complications of limb lengthening by the Ilizarov technique. *Clin Orthop Relat Res* 1990;81–104.
- [23] Fischgrund J, Paley D, Suter C. Variables affecting time to bone healing during limb lengthening. *Clin Orthop Relat Res* 1994;31–7.
- [24] Castelein S, Docquier PL. Complications associated with bone lengthening of the lower limb by callotasis. *Acta Orthop Belgica* 2016;82:806–13.
- [25] Lumpkin CK Jr, Aronson J, Shen XC, et al. The impact of total enteral nutrition on distraction osteogenesis in a rat model. *J Bone Mineral Res Off J Am Soc Bone Mineral Res* 1996;11:962–9.
- [26] Vogt B, Tretow HL, Daniilidis K, et al. Reconstruction of forearm deformity by distraction osteogenesis in children with relative shortening of the ulna due to multiple cartilaginous exostosis. *J Pediatr Orthop* 2011;31:393–401.
- [27] Yun AG, Severino R, Reinker K. Attempted limb lengthenings beyond twenty percent of the initial bone length: results and complications. *J Pediatr Orthop* 2000;20:151–9.
- [28] Villa A, Paley D, Catagni MA, et al. Lengthening of the forearm by the Ilizarov technique. *Clin Orthop Relat Res* 1990;125–37.