

Spontaneous cerebellar hemorrhage with severe brainstem dysfunction through minimally invasive puncture treatment by locating the simple bedside

Jing Wang, MD^a, Qing-Yuan Wu, PhD^a, Cui-Ping Du, MD^a, Jin Liu, MD^a, Hua Zhang, MD^b, Jun-Yan Wang, MD^b, Wei Xue, MD^a, Sheng-Li Chen, MD^{a,*}

Abstract

This study aims to evaluate the feasibility and effectiveness of minimally invasive puncture treatment by positioning the simple bedside for spontaneous cerebellar hemorrhage.

From January 2017 to March 2018, the investigators applied simple bedside positioning to perform the intracranial hematoma minimally invasive surgery for 21 patients with cerebellar hemorrhage.

For these 21 patients, the bleeding amount and Glasgow Coma Scale (GCS) score before the operation were 18.5 ± 5.0 cc and 9.5 ± 3.3 , respectively; 24 hours after the operation, the GCS score was 11.0 ± 4.6 . Five patients died within 7 days of the operation and the head computed tomography (CT) was re-examined. It was found that the average bleeding amount was 3.4 ± 0.9 cc, the operation success rate was 76.2%, and the accurate puncture rate was 100%. Six months later, the Modified Rankin Scale (MRS) score was 2.5 ± 2.0 . The postoperative recovery was good. The situation shows that patients with favorable outcomes (MRS score 0–2) accounted for 38.1% (8/21), and the fatality rate was 33.3% (7/21).

The efficacy of the intracranial hematoma minimally invasive surgery by positioning the simple bedside for spontaneous cerebellar hemorrhage with severe brainstem dysfunction is good.

Abbreviations: CT = computed tomography, EVD = external ventricular drainage, GCS = Glasgow Coma Scale, MRS = Modified Rankin Scale.

Keywords: bedside, brainstem function injury, minimally invasive hematoma puncture, spontaneous cerebellar hemorrhage

1. Introduction

Spontaneous cerebellar hemorrhage accounts for 5% to 10% of overall cerebral hemorrhages,^[1] and the disability rate for cerebellar hemorrhage is 20% to 75% higher than that of the common cerebral hemorrhage. This can mainly be attributed to the obstructive hydrocephalus, which is caused by brainstem compression and bleeding in the ventricular system.^[2–4]

Editor: Bernhard Schaller.

The authors declare that there is no conflict of interest.

^aDepartment of Neurology, ^bDepartment of Radiology, Chongqing Three Gorges Central Hospital, Chongqing, China.

*Correspondence: Sheng-Li Chen, Department of Neurology, Chongqing Three Gorges Central Hospital, No. 165 Xin Cheng Street, Wanzhou District, Chongqing 404000, China (e-mail: shenglichendr@21cn.com).

Copyright © 2019 the Author(s). Published by Wolters Kluwer Health, Inc. This is an open access article distributed under the terms of the Creative Commons Attribution-Non Commercial-No Derivatives License 4.0 (CCBY-NC-ND), where it is permissible to download and share the work provided it is properly cited. The work cannot be changed in any way or used commercially without permission from the journal.

How to cite this article: Wang J, Wu QY, Du CP, Liu J, Zhang H, Wang JY, Xue W, Chen SL. Spontaneous cerebellar hemorrhage with severe brainstem dysfunction through minimally invasive puncture treatment by locating the simple bedside. *Medicine* 2019;98:38(e17211).

Received: 21 November 2018 / Received in final form: 30 July 2019 / Accepted: 23 August 2019

<http://dx.doi.org/10.1097/MD.00000000000017211>

Clinically, patients with cerebellar hemorrhage tend to be accompanied with severe brainstem injury and suffer from the respiratory failure and herniation of the brain. At present, these patients may not be able to tolerate general anesthesia or surgical craniotomy, nor will they be able to complete the head computed tomography (CT) to locate the hemorrhage; moreover, the families of the patients often refuse to accept surgical craniotomy for treatment. If we did not perform hematoma removal, however, the death rate would be 100%.^[5,6] Indeed, intracranial hematoma minimally invasive surgery is a simple and quick puncture method with relatively little trauma on the individual.^[7] Considering that the anatomical position of the cerebellum is relatively fixed, the present study envisages a simple bedside positioning method to complete the cerebellum puncture and hematoma drainage and observes the effectiveness of this method.

2. Methods

2.1. Patient selection

A total of 21 patients with the spontaneous cerebellar hemorrhage were accompanied by severe brainstem dysfunction. Patients with cerebral herniation or respiratory failure, who require endotracheal intubation and continuous ventilator-assisted breathing, were considered to have severe brainstem dysfunction. They were received and treated by our department from January 2017 to March 2018, and they were selected during

their admission. Furthermore, these patients suffered from respiratory dysfunction and needed to undergo tracheal intubation or herniation of the brain. Hence, cerebellum minimally invasive surgery by positioning the simple bedside was adopted to complete the hematoma drainage. All patients accepted the standard physical examination and the nervous-system examination. According to the laboratory examination and head CT examination in the Emergency Department, all patients were proven to have cerebellar hemorrhage. Hence, the maximum diameter of bleeding, hydrocephalus, brainstem compression, fourth ventricle oppression, and ventricular hemorrhage of the patients were evaluated. The cerebellar hemorrhage volume was calculated using the Coniglobus formula. Before the operation, the Glasgow Coma Scale (GCS) score of the qualified patients was calculated. External ventricular drainage (EVD) was required before the intracranial hematoma minimally invasive surgery was performed if the patient was accompanied by ventricular compression and obstructive hydrocephalus. The area of the puncture-needle point, which was located at the hematoma center, was 0.5 cm; it was taken as the target point. The distance from the puncture-needle point to the hematoma center was 0.5 to 1.0 cm, which was taken as the mild shift. The distance from the puncture-needle point to the hematoma center was 1.0 to 2.0 cm, which was taken as the moderate shift. Within 7 days of the operation, the head CT was conducted as a re-examination. Within 6 months of the operation, the Modified Rankin Scale (MRS) score was used to evaluate the prognosis and recovery of the patients. The present study passed through the review of the Chongqing Three Gorges Central Hospital Ethics Committee, and obtained informed consent from the families of the patients.

2.2. Surgery methods

When the patients were admitted to our hospital, 21 were scanned using a Somatom Emotion 16 multi-slice spiral CT scanner (Siemens), and the scanning range was from the skull base to the cranial roof. The voltage was 110 to 120 kv, the electricity was 180 to 250 ma, the collimation was 0.75 mm, the thickness was 6.0 mm, and the interval was 6.0 mm. The puncture level was selected based on the head CT image of the patients, and the DICOM data was imported to the 3D-slicer software (<https://www.slicer.org>). The 3D-slicer software was used to adjust the head CT scanning baseline to the standard OM line. Taking the OM line as the baseline, the maximum hematoma level line parallel to the OM line was drawn in the scalp. On the maximum hematoma level of the reconstructed CT image, a straight line was drawn—of which the included angle to the rear sagittal line was 45°—taking the central point of the hematoma as the reference line. Thereafter, the cross point between this straight line and the side occiput of the patient in the maximum hematoma level line was taken as the entry point, while the cross point with the opposite side tempus was taken as the locating point of the director. Meanwhile, the above 2 locating points were both marked in the scalp in order to measure the distance between the cross point with the side occiput of the patient and the central point of hematoma as the puncture depth. Furthermore, local anaesthesia was adopted, and the hematoma depth followed to select the appropriate YL-1 puncture needle (BeijingWanTeFu Medical Apparatus Co., Ltd). After the stereotaxic apparatus was fixed, the needle entered along the predesigned puncture direction, slowly withdrawing half the amount of the hematoma.

Thereafter, 50,000 units of urokinase was injected into the hematoma cavity and the tube was closed for 2 hours before being opened for drainage. We performed EVD through the Kocher point before the cerebral hemorrhage puncture of all patients. Figure 1 illustrates the operation process of the minimally invasive puncture by positioning the simple bedside.

2.3. Postoperative treatment

After the operation, the amount and character of the drainage liquid were observed every day. The respirator was removed when patient conditions were satisfactory and the daily drainage amount was considered “very good”. Seven days later, the head CT was conducted as a re-examination, coupled with urokinase being alternately injected into the hematoma cavity and the lateral ventricle once or twice on a daily basis. The number of needle retaining days was decided. Needle withdrawal indication according to the brain CT re-examination findings is as follows: The head CT examination revealed that the high-density shadows of the hematoma basically disappeared or completely disappeared, reflecting the needle withdrawal indication of the cerebellum puncture needle. If the high-density shadows in the ventricle disappeared, the tube could be closed for 24 to 48 hours.

The head CT examination demonstrated that no enlargement was found in various ventricles nor was clinical manifestation of the intracranial hypertension observed, indicating that the ventricular puncture needle could be withdrawn.

3. Results

In the present study, the subjects were comprised of 16 male and 5 female patients, ranging between the ages of 47 and 89. Among these patients, 19 had cerebellar hemisphere hemorrhage, 2 had vermis hemorrhage, and 11 were accompanied by intraventricular hemorrhage. Furthermore, 14 patients were accompanied by differing degrees of obstructive hydrocephalus. In addition, 18 patients had a history of hypertension, 3 of which had unknown causes. Moreover, 5 patients had light coma, 10 patients had middle coma, and 6 patients had deep coma.^[8] All the patients suffered from respiratory dysfunction. The time from the onset of cerebellar hemorrhage to the treatment was 4.3 ± 1.6 hours. The average operation time of the cerebellum minimally invasive surgery by positioning the simple bedside was 23.7 minutes. For the 21 patients, the bleeding amount and GCS score before the operation were 18.5 ± 5.0 cc and 9.5 ± 3.3 , respectively. However, 24 hours after the operation, the GCS score was 11.0 ± 4.6 . With 7 days of the operation, 5 patients died and the head CT was conducted as a re-examination, which revealed that the average bleeding amount was 3.4 ± 0.9 cc. The hematoma amount significantly decreased ($P < .05$) compared to the amount before the operation. Figure 2 shows that the hematoma of a patient with a typical cerebellar hemorrhage significantly decreased after the operation. The operation success rate was 76.2%, and the accurate puncture rate was 100%. The MRS score was 2.5 ± 2.0 6 months after the operation. In this group, there were 13 cases (81.3%) with target hit, and 3 cases (18.8%) with mild deviation, no moderate deviation, and misalignment. Two patients re-hemorrhaged during the operation. After the suction stopped, natural drainage was performed, and the bleeding automatically stopped. Through the head CT re-examination, no hematoma enlargement was found. However, 2 patients had cerebrospinal fluid leakage after the operation as

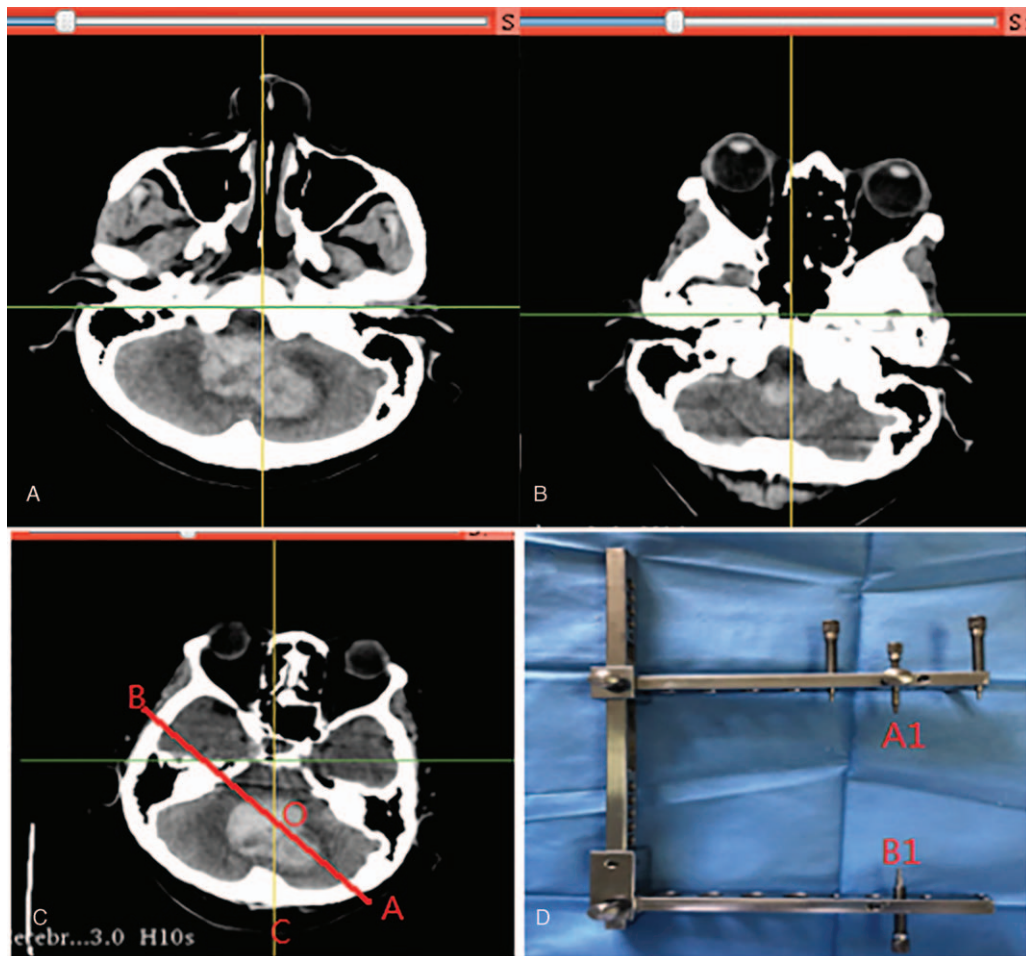


Figure 1. (A) A CT scan of a spontaneous cerebellar haemorrhage with a non-standard OM baseline. (B) The CT image was reconstructed using the 3D-Slicer software with standard OM baseline. (C) Select the largest hematoma level and determine the puncture point as point A, the contralateral fixed point as point B, and the angle between line AO and line CO ($\angle AOC$) as about 45 degrees. (D) Hematoma puncture is performed by a half-frame simple stereotactic instrument; point A1 and point A coincide, point B1 and point B coincide.

well as after the puncture point was sutured, which slowly disappeared. Upon postoperative follow-up 6 months later, 8 patients had good outcomes (MRS score 0–2), 8 had poor prognosis (MRS score 3–6) and 2 died due to pulmonary infection. Table 1 summarises the characteristics and operation results of the patients.

4. Discussion

Generally speaking, cerebellar hemorrhage either directly compresses the brainstem or causes an obstructive hydrocephalus. Furthermore, spontaneous cerebellar hemorrhaging has a severe fatality rate. Hence, cerebellar hemorrhage requires more surgical interventions relative to a supratentorial hemorrhage.^[9–11] According to the guidance on adult cerebral hemorrhaging in the 2015AHA/ASA, the diameter of the cerebellar hemorrhage should be larger than 3cm and some symptoms should be present, such as nerve dysfunction or brainstem compression. Hence, the above guidance can be used for surgical intervention with respect to cerebellar hemorrhage.^[12] For the massive cerebellar hematoma, an extensive occipital decompression (SOC) is often adopted; this operation has the exact decompression

effect of direct hematoma removal, which is advantageous. However, there are also some disadvantages to this operation, such as the long periods of time required for preoperative preparation as well as long operation times. Meanwhile, a severe secondary tissue injury was caused, and the hematoma removal under the occipital bone caused unstable conditions coupled with the cerebral injury, rehemorrhagia, pseudomeningocele, and postoperative secondary infection.^[7,13–15] For patients with severe central respiratory rhythm disturbance, when the cerebellar hemorrhage amount is large or when the conditions are further aggravated, the cerebellar tonsillar hernia can easily die. Therefore, the selection of treatment (operation) for this group of patients is urgent. The reason why the craniotomy operation is not frequently adopted is that the traditional surgical craniotomy to remove the hematoma requires a lot preoperative preparation time; moreover, the operation is relatively complex and the pathogenesis can be easily delayed. Meanwhile, the neurosurgeon considers whether the patient's vital signs are unstable and whether they can or cannot tolerate general anesthesia.

The application of YL-1 puncture needle in intracranial hematoma minimally invasive surgery has been widely applied in

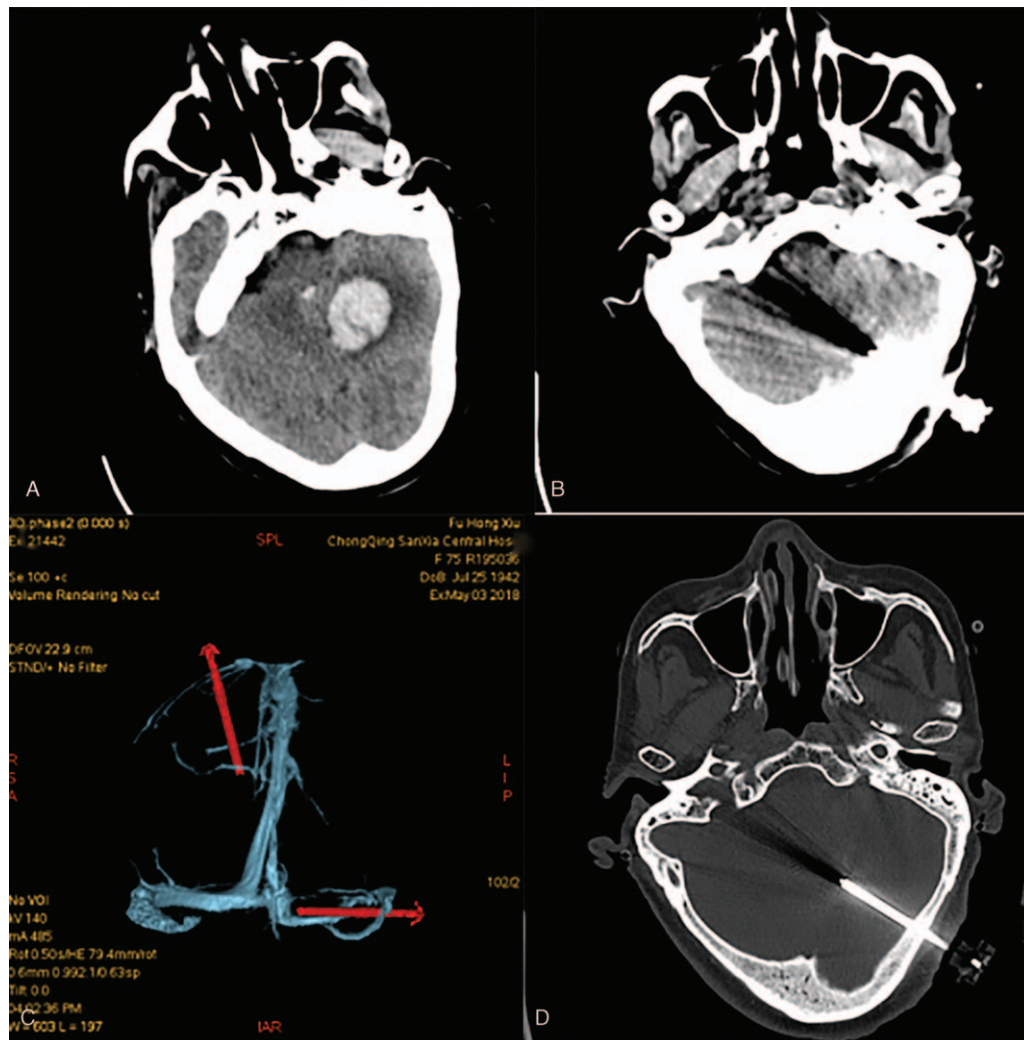


Figure 2. A 75-year-old female patient presented with a deep coma status. (A) Findings on brain CT at admission show spontaneous cerebellar hemorrhage with pons compression and obstruction of the fourth ventricle. The hematoma volume was 15 cc and maximal hematoma diameter was 30 mm. (B) Brain CT at 7 days after surgery shows residual hematoma with catheter after minimally invasive surgery. (C) The relative position of ventricular drainage needle and cerebellar puncture needle with venous sinus. (D) The direction, depth, and position of the puncture needle shown in the skull CT bone window.

the primary hospitals of China. Moreover, in the past, it has been used for the minimally invasive treatment of cerebral hemorrhage. Wang^[15] conducted a comparative analysis for 198 patients with spontaneous cerebral hemorrhage in the basal ganglia, with the bleeding amount of more than 30 mL, by using the YL-1 puncture needle and traditional surgical craniotomy. The results showed that the YL-1 puncture treatment was able to significantly reduce the degree of damage in the neurological function score 1 year after onset. For patients, the average age was ≤ 60 and if they had the National Institutes of Health Stroke Scale (NIHSS) score of < 15 , or if the ventricular hemorrhage was ≤ 60 mL, the mortality rate would significantly decrease. This operation adopted local anesthesia in the scalp. Hence, the systemic condition of the patient was slightly influenced, which greatly improved the patient's operation tolerance. Furthermore, the operation wound was minor and, during operation, the patient would only accept 3 mm of needle passage damage with respect to the puncture needle. In addition, operation time was short, lasting no more than 30 minutes. Moreover, the operation

cost was low, and the postoperative hospital stays were short, reducing the economic burden of the patients.^[16–20] The success of the intracranial hematoma minimally invasive surgery lies in the accurate importation of the puncture needle to the hematoma center.^[21] Determining how to select the puncture point (and puncture direction) is difficult for the intracranial hematoma puncture by positioning the simple bedside. If the patient with severe cerebellar hemorrhage suffered from respiratory failure, then said patient would not be able to carry out the head CT locating examination outside. Furthermore, due to the patient's failure to cooperate, the preoperative head CT image was often reflected as a non-OM baseline scanning image. At this time, the active 3D-slicer software can be used to accurately trace the maximum level of both the puncture and puncture site in the patient's scalp. Indeed, the routine minimally invasive intracranial hematoma drainage often adopts the closest point from the maximum hematoma level to the skull as the puncture point. The cerebellar hematoma puncture point is selected as the closest point to the hematoma beside the rear sagittal line, which is

Table 1**Characteristics of the 21 patients undergoing simple bedside surgery for treatment of spontaneous hypertensive cerebellar hemorrhage.**

Variables (n=21 patients)	Values
Age (years)	
Mean	66.7 ± 14.2
Sex	
Male	16 (76.2%)
Female	5 (23.8%)
Preoperative GCS score	
Mean	9.5 ± 3.3
Postoperative GCS score	
Mean	11.0 ± 4.6
CT finding	
Hematoma size, mm	45.5 ± 8.0
Hematoma volume, cc	18.5 ± 5.0
7 days hematoma volume, cc	3.4 ± 0.9
Hydrocephalus	14 (66.7%)
IVH	11 (52.3%)
Onset until the time of surgery, h	4.3 ± 1.6
Mean operation time, mins	23.7 ± 5.6
Extraventricular drainage (EVD)	21 (100.0%)
EVD placement time, mins	15.5 ± 5.1
MRS	
No symptoms	3 (18.8%)
No significant disability	3 (18.8%)
Slight disability	2 (12.5%)
Moderate disability	3 (18.8%)
Moderately severe disability	2 (12.5%)
Severe disability	1 (6.3%)
Dead	2 (12.5%)
rate of accuracy	
Hit the target	13 (81.3%)
Slight offset target	3 (18.8%)
Moderate offset target	0 (0%)
Off target	0 (0%)

CT = computed tomography, GCS = Glasgow Coma Scale, IVH = intravenous hemorrhage, MRS = Modified Rankin Scale, N = number.

attributed to that this point is located in the rear occiput, and the skull slope is relatively large and the soft tissue under the scalp is relatively thick. Hence, the entry direction could not be easily mastered. Conversely, the operator can easily slip into the base of the skull, by virtue of which operation failure may occur. In clinical practice, the investigators consider that the entry direction is easily fixed through the central point of the hematoma and the included angle to the sagittal line of 45°, when the skull in the cross point between this straight line, the maximum hematoma level line is relatively flat, and the scalp is relatively thin. Meanwhile, when the transverse sinus surface position has been marked before the operation, the transverse sinus will not be damaged. The length of the YL-1 cranial puncture needle has been measured and selected before operation. Hence, there will be no danger of damaging the brainstem due to an excessively deep puncture. At the same time, the half-frame stereotaxic apparatus was adopted to fix the puncture direction, which helps to the shift the puncture needle; thus, the puncture needle can be used to accurately position the puncture target point owing to unarmed puncture. Hence, the YL-1 minimally invasive intracranial hematoma crusting and aspirating operation can only be performed by the bedside due to easy operation. Furthermore, the ability to save lives in the shortest time possible is incomparable with other operation methods.^[16,22]

Early operation can help to improve the survival rate of patients with severe cerebellar hemorrhage. Yanaka et al^[6] reported that, among 20 patients with spontaneous cerebellar hemorrhage who had a GCS score of 3, 4 died due to the absence of operation, 10 survived due to immediate surgical craniotomy, and the survival rate was 50%. Furthermore, the most important factor influencing the prognosis is the time from the symptom occurrence to the start of the operation commencement. Generally, this time interval is 2 hours, showing good prognosis. Lee et al^[23] adopted stereotaxis to carry out the cerebellar hematoma removal, and the average operation time was controlled within 43.1 minutes. Hence, among the 26 patients with cerebellar hemorrhage, only 1 patient died. The present study adopted the modified minimally invasive surgery by positioning the simple bedside for operation, and the average operation time was controlled within 23.7 minutes. The operation puncture success rate was 76.2%, and the target point success rate was 100%, a good operation effect. The rate of patients with good outcomes was 38.1% (8/21), and the fatality rate was 33.3% (7/21). If we compare the survival rate of patients with traditional surgical craniotomy, no significant differences exist, indicating that the minimally invasive surgery by positioning the simple bedside had a good effect in saving a patient's life and promoting its functional rehabilitation. Notwithstanding, there were limitations to our study; for instance, the sample size was small, and the retrospective and non-random character of the study did not establish firm conclusions.

5. Conclusion

The investigators deem that the minimally invasive surgery by locating the simple bedside can decrease operation conditions and reduce the operation time compared with traditional surgery or stereotactic puncture drainage. Indeed, it improves the survival rate of patients with severe cerebellar hemorrhage, which is important and significant. Hence, it is a kind of alternative treatment scheme to treat spontaneous cerebellar hemorrhage, particularly in underdeveloped regions or countries with limited economic conditions. However, the present study had a small sample size. Thus, more high-quality random and multicenter clinical tests are needed to further prove this approach.

Author contributions

Conceptualization: Jing Wang, Sheng-Li Chen.

Data curation: Qing-Yuan Wu, Cui-Ping Du.

Formal analysis: Jin Liu, Hua Zhang, Jun-Yan Wang.

Resources: Wei Xue.

Writing – original draft: Jing Wang, Sheng-Li Chen.

Writing – review & editing: Jing Wang, Sheng-Li Chen.

References

- Satopää J, Meretoja A, Koivunen RJ, et al. Treatment of intracerebellar haemorrhage: poor outcome and high long-term mortality. *Surg Neurol Int* 2017;8:272.
- Hackenberg KA, Unterberg AW, Jung CS, et al. Does suboccipital decompression and evacuation of intraparenchymal hematoma improve neurological outcome in patients with spontaneous cerebellar hemorrhage. *Clin Neurol Neurosurg* 2017;155:22–9.
- Han J, Lee HK, Cho TG, et al. Management and outcome of spontaneous cerebellar hemorrhage. *J Cerebrovasc Endovasc Neurosurg* 2015;17:185–93.

- [4] Chang CY, Lin CY, Chen LC, et al. The predictor of mortality within six-months in patients with spontaneous cerebellar hemorrhage: a retrospective study. *PLoS One* 2015;10:e0132975.
- [5] Tsitsopoulos PP, Tobieson L, Enblad P, et al. Prognostic factors and long-term outcome following surgical treatment of 76 patients with spontaneous cerebellar haematoma. *Acta Neurochir (Wien)* 2012;154:1189–95.
- [6] Yanaka K, Meguro K, Fujita K, et al. Immediate surgery reduces mortality in deeply comatose patients with spontaneous cerebellar hemorrhage. *Neurol Med Chir (Tokyo)* 2000;40:295–300.
- [7] Zhou X, Chen J, Li Q, et al. Minimally invasive surgery for spontaneous supratentorial intracerebral hemorrhage: a meta-analysis of randomized controlled trials. *Stroke* 2012;43:2923–30.
- [8] Scott RT. Metabolic coma. *West J Med* 1974;120:131–42.
- [9] Brennan RW, Bergland RM. Acute cerebellar hemorrhage. Analysis of clinical findings and outcome in 12 cases. *Neurology* 1977;27:527–32.
- [10] Chin D, Carney P. Acute cerebellar hemorrhage with brainstem compression in contrast with benign cerebellar hemorrhage. *Surg Neurol* 1983;19:406–9.
- [11] Lui TN, Fairholm DJ, Shu TF, et al. Surgical treatment of spontaneous cerebellar hemorrhage. *Surg Neurol* 1985;23:555–8.
- [12] Hemphill JC3rd, Greenberg SM, Anderson CS, et al. American heart association stroke council; council on cardiovascular and stroke nursing; council on clinical cardiology. guidelines for the management of spontaneous intracerebral hemorrhage: a guideline for healthcare professionals from the American Heart Association/American Stroke Association. *Stroke* 2015;46:2032–60.
- [13] Norris JW, Eisen AA, Branch CL. Problems in cerebellar hemorrhage and infarction. *Neurology* 1969;19:1043–50.
- [14] Koziarski A, Frankiewicz E. Medical and surgical treatment of intracerebellar haematomas. *Acta Neurochirurgica* 1991;110:24–8.
- [15] Li L, Li Z, Li Y, et al. Surgical evacuation of spontaneous cerebellar hemorrhage: comparison of safety and efficacy of suboccipital craniotomy, stereotactic aspiration and thrombolysis and endoscopic surgery. *World Neurosurg* 2018;117:e90–8.
- [16] Wang GQ, Li SQ, Huang YH, et al. Can minimally invasive puncture and drainage for hypertensive spontaneous Basal Ganglia intracerebral hemorrhage improve patient outcome: a prospective non-randomized comparative study. *Mil Med Res* 2014;1:10–21.
- [17] Sun H, Liu H, Li D, et al. An effective treatment for cerebral hemorrhage: minimally invasive craniopuncture combined with urokinase infusion therapy. *Neurol Res* 2010;32:371–7.
- [18] Chen L, Dong L, She L, et al. Treatment of chronic subdural hematoma by novel YL-1 hollow needle aspiration drainage system (697 cases report). *Neurol Sci* 2017;38:109–13.
- [19] Fei X, Wan Y, Wang Z, et al. Application of YL-1 needle in chronic subdural hematoma treatment for super-aged patients. *J Craniofac Surg* 2018;29:e90–4.
- [20] Zhou H, Zhang Y, Liu L, et al. A prospective controlled study: minimally invasive stereotactic puncture therapy versus conventional craniotomy in the treatment of acute intracerebral hemorrhage. *BMC Neurol* 2011;11:76.
- [21] Dey M, Stadnik A, Awad IA. Spontaneous intracerebral and intraventricular hemorrhage: advances in minimally invasive surgery and thrombolytic evacuation, and lessons learned in recent trials. *Neurosurgery* 2014;74(suppl 1):S142–50.
- [22] Zhou H, Zhang Y, Liu L, et al. Minimally invasive stereotactic puncture and thrombolysis therapy improves long-term outcome after acute intracerebral hemorrhage. *J Neurol* 2011;258:661–9.
- [23] Lee JH, Kim DW, Kang SD. Stereotactic burr hole aspiration surgery for spontaneous hypertensive cerebellar hemorrhage. *J Cerebrovasc Endovasc Neurosurg* 2012;14:170–4.