

Thymoma Complicated by Situs Inversus Totalis

Kai-Lai Yang, Jian Li

Department of Thoracic Surgery, Peking University First Hospital, Peking University, Beijing 100034, China

To the Editor: A 46-year-old man was admitted complaining of chest congestion, shortness of breath, and dyspnea for 4 days. Four days ago, he suffered from chest pain after drinking and felt short of breath and dyspnea. He felt better after break, but the symptoms still returned periodically. He had night sweats and low-grade fever, with the highest temperature at 37.6°C. The patient denied any other discomforts such as palpitation, cough, expectoration, hemoptysis, or weakness. Chest radiograph showed that the mediastinum was slightly widened. Nonenhanced computed tomography (CT) scan showed as follows: situs inversus, a 7.5 cm × 5.3 cm soft-tissue mass at the right side of the anterior superior mediastinum; the right lung had been compressed. Positron emission tomography-CT was taken, and the results showed that the patient has situs inversus totalis. A 7.4 cm × 5.2 cm × 5.3 cm soft-tissue mass at the right side of the anterior superior mediastinum has been found as well, with smooth edges and nonuniform density. The mean CT value was 40 Hounsfield unit for solid parts, and fluorodeoxyglucose uptake increased, and the maximal standard uptake value was 2.6 [Figure 1]. The patient has no positive past medical history except hypertension. The patient's cigarette index was 1200 (30 years × 40/day), and his family history is negative. Physical examination (PE) revealed situs inversus in the chest and abdominal cavity. Electrocardiograph and routine laboratory studies were also negative.

Right side thoracotomy mediastinal tumor resection surgery was performed under general anesthesia. The surgery was successful. After conventional treatment, the patient recovered well and was discharged without any complications. Pathology report was: "Mediastinal mass, 7.0 cm × 5.5 cm × 5.0 cm, encapsulated tumor tissue hardening of fibrous tissue that was separated from the lymphocyte-rich region and lymphocyte scarce region. No clear vascular or capsular invasion was found. Tumor tissue was surrounded by normal thymus tissue". In sum, the mass is AB type thymoma with no lymph node metastasis found.

The annual incidence rate of thymoma is 0.15/100,000, and for situs inversus, it is about 1/10,000.^[1] The number of patients suffering from thymoma complicated by situs inversus totalis is extremely small, which causes difficulties for preoperative diagnosis and operation. Situs inversus can be classified into two types: total situs inversus and partial situs inversus. Situs inversus totalis, which is the most common type, is a kind of

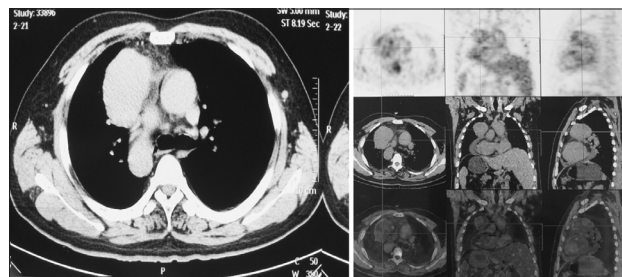


Figure 1: Nonenhanced computed tomography scan (left) and positron emission tomography/computed tomography scan (right) images in a patient diagnosed with thymoma complicated by situs inversus totalis.

congenital visceral ectopia that is caused by viscera malrotation in the embryonic stage.^[2] For situs inversus totalis patients, visceral positions have changed, but the relationship between them remains normal; the physiological functions are normal. The whole body remains pathological normal with no symptoms usually, and diagnoses are often confirmed by physical and imaging examinations.^[3] Situs inversus associated with other abnormalities may affect the diagnosis or even beset well-trained doctors, for examples, heart-spleen syndrome, Kartagener's syndrome, and multiple organ malrotation syndrome (MOMS). It is not a trifling matter, according to the previous studies, the misdiagnosis rate of MOMS is as high as 45% both before and during operations, causing 31% of operating mistakes.^[4] Therefore, when abnormalities are found, doctors should be vigilant in case the patient has additional malformations or abnormalities.^[5]

There are few researches concerning thymoma complicated by situs inversus totalis. Previous studies suggest that there is no need to pay special attention. Thorough PE and other auxiliary checks, especially imaging, are necessary for proper treatment. Furthermore seeking peers' help and communicating with the patient can help preventing side effects and misdiagnosis.

Address for correspondence: Dr. Kai-Lai Yang,

Department of Thoracic Surgery, Peking University First Hospital, Peking University, Beijing 100034, China
E-Mail: yangkailai2155@sina.com

Access this article online

Quick Response Code:



Website:
www.cmj.org

DOI:
10.4103/0366-6999.174499

This is an open access article distributed under the terms of the Creative Commons Attribution-NonCommercial-ShareAlike 3.0 License, which allows others to remix, tweak, and build upon the work non-commercially, as long as the author is credited and the new creations are licensed under the identical terms.

© 2016 Chinese Medical Journal | Produced by Wolters Kluwer - Medknow

Received: 11-10-2015 **Edited by:** Qiang Shi

How to cite this article: Yang KL, Li J. Thymoma Complicated by Situs Inversus Totalis. Chin Med J 2016;129:372-3.

Surgeons should adopt the unconventional surgical methods and incision manners when performing operations (including anesthesia); besides, they should clearly distinguish the anatomical structures and be aware of the spatial structure change thus prevent normal tissues from being injured. Moreover, considering that viscera transposition may be a part of some diseases or syndromes, and following the principles of monism, surgeons must be cautious in diagnosis and treatment, especially when other symptoms exist.

Financial support and sponsorship

Nil.

Conflicts of interest

There are no conflicts of interest.

REFERENCES

1. Fishman LN, Lavine JE. What's wrong when it isn't right: Situs inversus and genetic control of organ position. *Hepatology* 1994;19:257-8. doi: 10.1002/hep.1840190138.
2. Spoon JM. Situs inversus totalis. *Neonatal Netw* 2001;20:59-63. doi: 10.1891/0730-0832.20.1.63.
3. Shogan PJ, Folio L. Situs inversus totalis. *Mil Med* 2011;176:840-3. doi: 10.7205/MILMED-D-11-00039.
4. Hong QC, Yan GJ, editors. Neonatology. In: A Collection of Foreign and Chinese Essays on Paediatrics. 1st ed. Tianjin: Tianjin Science and Technology Translation Publishing Company; 1993. p. 134.
5. Cheikhelard A, De Lagausie P, Garel C, Maintenant J, Vuillard E, Blot P, *et al*. Situs inversus and bowel malrotation: Contribution of prenatal diagnosis and laparoscopy. *J Pediatr Surg* 2000;35:1217-9. doi: 10.1053/jpsu.2000.8730.