


CASE REPORT



Escherichia coli: a rare cause of meningitis in immuno-competent adult

Maryam Zafar^a, Abubakar Tauseef^a, Muhammad Sohaib Asghar ^a, Narmin Khan^a, Nabeeha Farooqui^a, Mustafa Dawood^a, Tanvir Alam^b and Durre Naman^a

^aInternal Medicine Department, Dow University Hospital, DUH, Karachi, Pakistan; ^bMedicine, Civil Hospital, Karachi, Pakistan

ABSTRACT

A 35-year-old male of Asian ethnicity presented with complaints of high-grade fever, severe headache, vomiting, generalized seizures, deteriorated conscious level and neck stiffness. After all baseline workup Computed Tomography (CT) scan of the brain was done, which turned out to be unremarkable. CT scan was then followed by lumbar puncture (LP) and Cerebrospinal fluid (CSF) detailed report was sent, which was highly suggestive of bacterial meningitis with the predominance of polymorphonuclear leukocytes. Later on, CSF culture and sensitivity report showed growth of Escherichia coli, which is one of the rare causes of meningitis in immunocompetent adults without any history of craniocerebral trauma, neurosurgical intervention, urinary or gastrointestinal tract infections, and an immunocompromised state.

Abbreviations: CSF: Cerebrospinal fluid; LP: Lumbar puncture; CT: Computerized tomography; E-coli: Escherichia coli; GCS: Glasgow coma scale; COPD: Chronic Obstructive Pulmonary Disease; HTLV1: Human T-Lymphotropic virus –1; PCR: Polymerase chain reaction

ARTICLE HISTORY

Received 13 September 2019
Accepted 26 November 2019

KEYWORDS

Escherichia coli; rare; meningitis; immuno-competent; adult

1. Introduction

Escherichia coli is one of the most common causative pathogens of neonatal meningitis but the presence of E-coli in an immunocompetent adult, causing meningitis is rare, with an annual incidence of less than 1 case per year [1]. Diabetes mellitus, alcoholism, cirrhosis, HIV infection, malignancies are some of the risk factors to develop E-coli meningitis. A distant source is usually identified, either from the urinary or digestive tract. In most of the cases, E-coli meningitis responds to ceftriaxone, gentamicin, ampicillin, penicillin G and amoxicillin, and meropenem [2]. The mortality rate is higher in E-coli meningitis patients as compared to other pathogens [3].

2. Case presentation

A 35-year-old male of Asian descent with no recent history of traveling but a significant family history of epilepsy in his paternal relative, and no preceding illness presented to us at Dow University Hospital from a very remote area of state of Sindh, Pakistan with sudden onset of complaints of vomiting, severe headache and altered level of consciousness. The patient had symptoms of high-grade fever, associated with neck stiffness and generalized seizures. He denied nausea, blurring of vision, severe muscle pain, red blotchy spots over the skin, chest pain, shortness of breath, cold hand and feet, irritability

with bright light exposure and any other active complaints. Empirically, the patient was started on ceftriaxone, paracetamol, and dimenhydrinate for his vomiting, fever and other signs of infection.

The physical examination was unremarkable except for neck stiffness and Kernig's sign positive with bilateral sluggish response of pupil and Glasgow Coma Scale (GCS) scoring of 8/15, Eye response was 4, Motor response was 3 and the verbal response was 1 (E4M3V1). The laboratory findings were: Hemoglobin: 16.3g/dL, Total Leukocyte Count: 15,000 white blood cells per microliter of blood with neutrophilia, platelets: 4,50,000 per microliter of blood, serum Total Bilirubin: 0.89umol/L with direct Bilirubin of 0.49 umol/L, Urea 71.9mg/dL, serum creatinine: 2.13mg/dL, serum sodium: 158mg/dL, serum potassium: 4.0mg/dL and International Normalization Ratio (INR): 2.13%, rest of the investigations were within normal limits. The differential considerations included meningitis, encephalitis, hydrocephalus, brain abscess, and metabolic encephalopathy. Computed Tomography (C.T) scan of the brain was done which was unremarkable (Figure 1). So, Lumbar Puncture was planned for cerebrospinal fluid (C.S.F) detailed report which showed an opening pressure: 178mm H₂O, glucose level: 14mg/dl, protein level: 240mg/dl, total leucocyte count: 379 cells/mm³ with neutrophils of 84% and red blood cell of 1 High Power Field (H.P.F). As the detailed report was suggested towards meningitis, cerebrospinal fluid was sent for culture and sensitivity and vancomycin was added

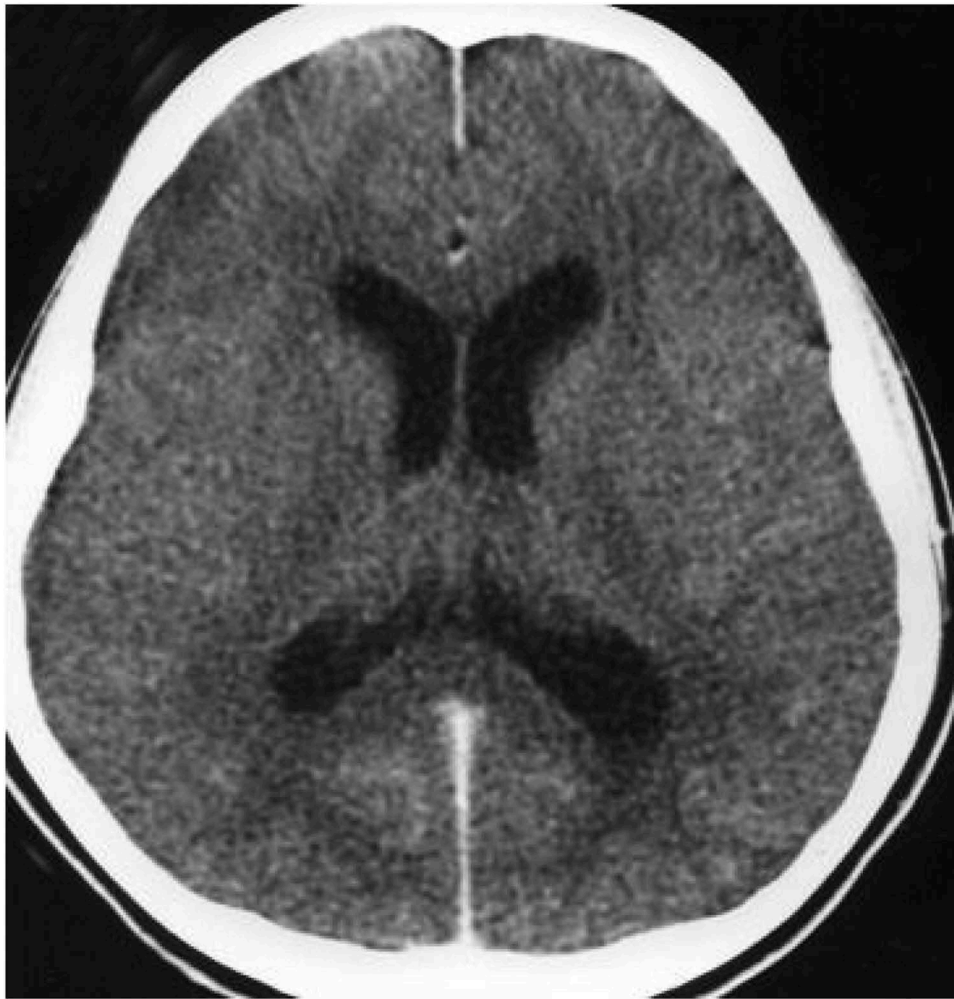

Figure 1. Computed tomography brain showed no signs of raised intracranial pressure or space-occupying lesion.

to the empiric antibiotic regimen. The culture showed a growth of *Escherichia Coli* in an immunocompetent adult, which is rare in immunocompetent as well as immunocompromised adults. The management of the patient was switched to meropenem and colistin based on the sensitivity of the organism and the patient has managed accordingly and was followed in ambulatory settings on a two-weekly basis.

3. Discussion

The incidence of idiopathic community-acquired *Escherichia Coli* (E-Coli) meningitis in immune-competent adults is rare across the globe and a total of forty-five cases have been reported so far since 1945, making an average of less than one case per year [1]. The risk factors identified to develop E-Coli meningitis include diabetes mellitus, alcoholism, cirrhosis, HIV infection, Chronic Obstructive Pulmonary Disease (COPD), chronic organ dysfunction in decreasing order of their associations [2,4]. Rarely, it is associated with human T-lymphotropic virus 1 (HTLV-1), Marfan Syndrome, Hemochromatosis, myelodysplasia, and B-cell lymphoma. Previously, reports have shown that the source of its spread is from blood, urine, joint

aspirate and ascitic fluid [2,4]. Retropharyngeal abscess [3,4] and neurosurgical intervention were also found to be the route of the entrance of E-Coli in few cases [4,5]. In 40% of the cases, the cause or source of its spread remained unknown as was shown in our patient [2]. E-Coli meningitis was found to be a disease in immunocompromised patients and the elderly age group [3]. E-coli being the most common pathogen in causing meningitis among the neonatal age group [6], It is one of the rare causes of meningitis in immune-competent adults as was seen in our patient.

The most common clinical manifestation of meningitis in adults includes fever, headache, nausea, vomiting, photophobia, neck stiffness and altered consciousness level. Symptoms like seizures, cranial nerve palsies, hemiparesis, and aphasia can also be found in patients with meningitis [7]. The classic triad of meningitis i.e., fever, neck stiffness and altered mental status is seen in 25% of the patients having E-coli meningitis [3,8]. Fever, in E-coli meningitis, was found in only 41% cases, grading is comparatively lower than seen with other pathogens of bacterial meningitis [3]. A prior study has shown that symptoms like seizures, altered mental status and hypotension are usually associated with poor outcomes [8].

Cerebrospinal fluid (CSF) examination via lumbar puncture (LP) is essential for diagnosing meningitis but a cranial Computed tomography Scan (CT) should be done prior to LP in cases where signs of altered mental status, focal neurological deficits, new-onset seizures or history of CNS lesion are present to rule out cerebral edema and space-occupying intracranial lesion which might result in cerebral herniation during LP [7,9]. Increased protein levels, low glucose concentration and pleocytosis (mainly of polymorphic leukocytes), are the three classic abnormalities of the CSF seen in bacterial meningitis [7]. CSF Gram staining is a rapid method to detect bacteria in the CSF [7,9]. The definitive diagnosis of bacterial meningitis is made on CSF culture, which is positive in 50–90% of patients (although the yield is lower when CSF is collected once antibiotic treatment has started) [7]. Polymerase Chain Reaction (PCR) on CSF is a useful test in patients who have given antibiotic treatment before lumbar puncture as CSF and blood culture might be falsely negative in such cases [7,9]. C-reactive protein and pro-calcitonin have been advocated as diagnostic serum markers, enabling differentiation between bacterial and viral meningitis [7].

Our case presents a 35-year-old male with a past medical history of hypertension and a significant family history of epilepsy, presented to us with complaints of vomiting, severe headache, altered level of consciousness, high-grade fever, associated with generalized seizures and neck stiffness. Examination revealed the Glasgow Coma Scale (GCS) scoring of 8/15 with the sluggish response of pupils, presence of neck stiffness and positive Kernig's Sign. Laboratory findings were suggestive of leukocytosis with predominant neutrophilia, with increased levels of creatinine, serum sodium and INR. Computed tomography (C.T) scan of the brain was performed which was insignificant and we proceeded for lumbar puncture. CSF's detailed report was highly suggestive of bacterial meningitis, so CSF culture and sensitivity were sent. The culture and sensitivity report of CSF showed growth of E-Coli which was sensitive to meropenem and colistin. Empirical treatment was started with ceftriaxone and vancomycin and then it was switched to meropenem and colistin according to the sensitivity report. There was no preceding history of any neurosurgical trauma, lack of immunity and urinary or gastrointestinal infections. The patient's urine and blood culture came out to be negative and no distant source of origin of E-coli was identified in our patient with our detailed work-up.

The differential diagnosis includes brain abscess, tuberculous meningitis, viral encephalitis or septic encephalopathy, cerebral malaria, arboviral infections and HIV-related infections of the CNS [7]. The

management should be initiated immediately with empirical antibiotics and adjunctive dexamethasone should be given shortly before or with the first dose of antibiotics, to reduce the risk of poor prognosis from 25 to 15% [9]. The standard empirical antibiotic regimen includes a combination therapy of a third-generation cephalosporin (either ceftriaxone or cefotaxime) with vancomycin. Management is further modified according to the CSF culture and sensitivity testing. The most widely used antibiotic drugs in E-coli meningitis included ceftriaxone (22%), gentamicin (13%), ampicillin (11%), penicillin G and amoxicillin (9%), and meropenem (7%) in decreasing pattern of the pecking order [2].

Pomar et al. [10] in his study concluded that patients having gram-negative bacillary meningitis had a mortality rate of 53%. In another study, Bodilsen et al [3] reported a mortality rate of 36% among patients with E. coli meningitis which is greater than 20% in the case of pneumococcal and 7% in case of meningococcal meningitis, which is maybe due to the virulent strains causing infection [11]. E-coli meningitis has multiple complications but among those, patients mostly die secondary to sepsis or multi-organ failure [3].

In conclusion, Meningitis is one of the common neurological condition which presents to the neurological ambulatory clinic worldwide. It is easily manageable if the cause is typical affecting specific age group of the patients but if its atypical, affecting an odd age group of the patient, as in E-coli pathogen causing meningitis in immune-competent adults, the progression of meningitis is usually unpredictable, so these patients should be managed promptly in order to prevent post-infectious complications including sepsis or multiple organ failure. In our patient, all the identifiable causes of E-coli meningitis were not identified but patient came to us from a remote area of Sindh with low literacy rate and poor health care services so speculation can be made that maybe patient had any intervention or procedure in the early part of his life involving CNS in the past which could have led him to be diagnosed with E-coli meningitis in an immune-competent adult. Up-to-date there is less than one case of E-coli meningitis presenting per year worldwide [1], so we would suggest that whenever the patient presents to us with atypical findings or cause, the treatment should not be delayed as this can lead to devastating consequences other than neurological complications like sepsis or multiple organ failure.

Disclosure statement

No potential conflict of interest was reported by the authors.

ORCID

Muhammad Sohaib Asghar  <http://orcid.org/0000-0001-6705-2030>

References

- [1] Kasimahanti R, Satish SK, Anand M. Community-acquired escherichia coli meningitis with ventriculitis in an adult—a rare case report. *J Intensive Care*. 2018;6(63):1–5.
- [2] Bichon A, Aubry C, Dubourg G, et al. Escherichia coli spontaneous community-acquired meningitis in adults: a case report and literature review. *Inter J Infect Dis*. 2018;67:70–74.
- [3] Bodilsen JB, Kjærgaard MC, Sirks N, et al. Community-acquired meningitis in adults caused by escherichia coli in Denmark and The Netherlands. *J Infect*. 2018;77(1):25–29.
- [4] Kohlmann R, Nefedev A, Kaase M, et al. Community-acquired adult escherichia coli meningitis leading to diagnosis of unrecognized retropharyngeal abscess and cervical spondylodiscitis: a case report. *BMC Infect Dis*. 2015;15:567. PMID:26654107.
- [5] Khan FY, Abu-khattab M, Anand D. Nosocomial escherichia coli meningitis in adults: report of four cases and literature review. *J Neurosci Rural Pract*. 2013;4(3):349–351. PMID:24250185.
- [6] Oordt-Speets AM, Bolijn R, van Hoorn RC, et al. Global etiology of bacterial meningitis: a systematic review and meta-analysis. *PLoS One*. 2018;13(6):e0198772.
- [7] Van de Beek D, Brouwer M, Hasbun R, et al. Community-acquired bacterial meningitis. *Nat Rev Dis Primers*. 2016;2:16074. PMID:27808261.
- [8] Pomar V, Benito N, López-Contreras J, et al. Spontaneous gram-negative bacillary meningitis in adult patients: characteristics and outcome. *BMC Infect Dis*. 2013;13(451):1–9.
- [9] Van de Beek D, de Gans J, Tunkel AR, et al. Community-acquired bacterial meningitis in adults. *N Engl J Med*. 2006;354:44–53. PMID:16394301.
- [10] Pomar V, Benito N, López-Contreras J, et al. Spontaneous gram-negative bacillary meningitis in adult patients: characteristics and outcome. *BMC Infect Dis*. 2013;13(1):451. PMID:24079517.
- [11] Algaba RA, Álvarez-Marín R, Praena J, et al. Escherichia coli causing meningitis in an adult: a case report and experimental characterization of its virulence. *Enfermedades Infecciosas y Microbiología Clínica*. 2019;37(6):418–419. PMID:30115543.