

Contents lists available at [ScienceDirect](https://www.sciencedirect.com)

American Journal of Ophthalmology Case Reports

journal homepage: www.ajocasereports.com/

Spontaneous macular hole closure after posterior vitreous detachment in an eye with hyperreflective OCT stress line

Rony C. Preti^{a,*}, Leandro C. Zacharias^a, Leonardo P. Cunha^a, Mario L.R. Monteiro^a, David Sarraf^{b,c}

^a Division of Ophthalmology, University of São Paulo Medical School, São Paulo, Brazil

^b Retina Disorders and Ophthalmic Genetics, Stein Eye Institute, University of California-Los Angeles, Los Angeles, CA, USA

^c Greater Los Angeles VA Healthcare Center, Los Angeles, CA, USA

ARTICLE INFO

Keywords:

Vitreomacular traction
Macular hole
Posterior vitreous detachment
Optical coherence tomography

ABSTRACT

Purpose: The aim of this report is to describe a patient who presented with a central hyper-reflective line (HRL) with spectral domain-optical coherence tomography (SD-OCT) after posterior vitreous detachment that evolved to full thickness macular hole (FTMH) with subsequent spontaneous resolution.

Observations: A 59-year-old patient presented with a history of photopsia and floaters followed by the development of a central scotoma in the right eye (OD). The left eye (OS) was normal. On examination, visual acuity (VA) was 20/20- OD and 20/20 OS. Retinal examination OD was remarkable for a retinal tear, and SD-OCT demonstrated a central HRL. The patient underwent laser retinopexy to barricade the retinal tear. Sequential SD-OCT of the macula was performed and the patient eventually developed a small FTMH 8 months after the baseline presentation. VA was correspondingly reduced to 20/80 OD. Upon return after 4 months, the hole was completely resolved with improvement of VA to 20/20 OD.

Conclusion: Vitreomacular traction (VMT) may lead to foveal dehiscence. This instability can be detected with SD-OCT as a vertical hyperreflective stress line that is a risk factor for progression to a FTMH. With release of VMT, FTMH can spontaneously close.

1. Introduction

The Muller Cell Cone (MCC) resides in the floor of the central fovea and acts as a plug or glue to prevent foveal dehiscence.^{1,2} During posterior vitreous detachment (PVD) or with vitreomacular traction, disruption of the MCC can lead to destabilization of the fovea centralis and the development of a vertical hyper-reflective stress or fault line through the central fovea with spectral domain optical coherence tomography (SD-OCT). These SD-OCT hyper-reflective lines can indicate active vitreomacular traction (VMT) and may be identified in 50% of cases prior to the development of a full thickness macular hole (FTMH).¹

This report will describe a patient who presented with a hyper-reflective stress line with SD-OCT after PVD that evolved to FTMH with subsequent spontaneous resolution.

2. Case report

A 59-year-old patient presented with a history of photopsia and floaters followed by the development of a central scotoma in the right eye. The left eye was normal.

On examination, visual acuity (VA) was 20/20- OD and 20/20 OS. Retinal examination of the right eye was remarkable for a retinal tear (Fig. 1 A) in the temporal peripheral quadrant. Retinal examination of the left eye was unremarkable.

SD-OCT of the left eye was within normal limits but demonstrated a central HRL in the symptomatic right eye (Fig. 1 A, green arrow). The macula was otherwise unremarkable OD throughout the entire volumetric OCT scan.

The patient underwent successful laser retinopexy to barricade the acute retinal tear in the right eye. Retinal detachment precautions were carefully reviewed with the patient.

Sequential SD-OCT of the macula was performed (Fig. 2) and the patient eventually developed a small (56 μ m in diameter) FTMH 8

* Corresponding author. University of Sao Paulo Av. Conselheiro Rodrigues Alves, 534 ap 261A – Vila Mariana São Paulo, São Paulo, 04014001, Brazil.

E-mail address: preti@usp.br (R.C. Preti).

<https://doi.org/10.1016/j.ajoc.2020.100950>

Received 13 April 2020; Received in revised form 5 July 2020; Accepted 26 September 2020

Available online 29 September 2020

2451-9936/© 2020 Published by Elsevier Inc. This is an open access article under the CC BY-NC-ND license (<http://creativecommons.org/licenses/by-nc-nd/4.0/>).

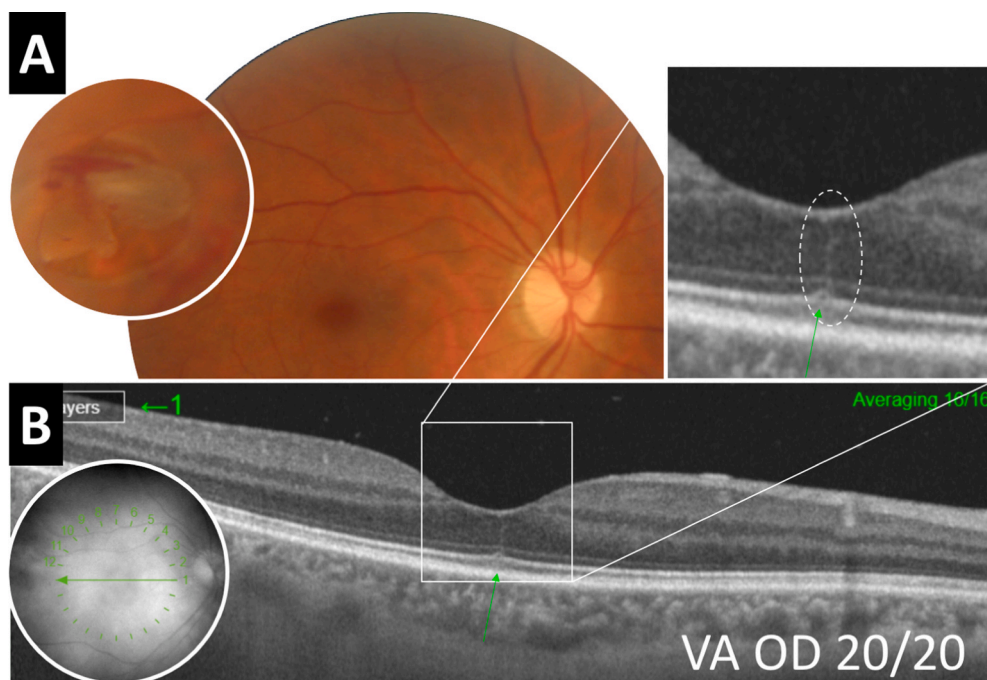


Fig. 1. A Color fundus photography illustrates an acute peripheral retinal flap tear temporal OD associated with retinal hemorrhage. B. Spectral domain optical coherence tomography shows a vertical hyper-reflective line in the central fovea (green arrow). The inset illustrates a higher magnified view of the stress or fault line. (For interpretation of the references to colour in this figure legend, the reader is referred to the Web version of this article.)

months after the baseline presentation (Fig. 2B). VA was correspondingly reduced to 20/80 OD. Surgery to repair the macular hole was discussed with the patient who preferred to monitor for progression. Upon return after 2 months, the hole was improved (Fig. 2C). Negligible intraretinal fluid was identified as the hole was very small with flat edges facilitating normal retinal pigment epithelial pump function.³ Four months later the hole was completely resolved (Fig. 2D) with improvement of VA to 20/20 OD.

3. Discussion

Centrifugal displacement of the inner and middle retina with centripetal movement of the outer retina during embryological development leads to creation of the foveal depression and foveal avascular zone.⁴ Muller Cells are consequently splayed in a radial configuration from the central fovea. The Muller Cell Cone, an independent cluster of central Muller Cells, acts like a plug to stabilize the fovea and prevent foveal dehiscence.⁵

With vitreomacular traction (VMT) as with an evolving PVD, foveal dehiscence may ensue and this may be indicated by a vertical hyper-reflective line with SD-OCT, similar to a central seam or fault or stress line, which can predate the development of FTMH and can be identified in other causes of VMT.⁶ Ishibashi et al.,⁷ identified the identical OCT finding predating the development of FTMH (albeit in eyes post vitrectomy) and referred to this feature as the foveal crack sign.

Bringmann et al.⁸ described spontaneous resolution of small FTMH and attributed this process to the dynamic response of the Muller Cell cone. The case described herein is unique in that the presence of the hyperreflective stress line is an indicator of prior VMT and a risk factor for foveal dehiscence.⁶ Spontaneous resolution of the small macular hole

may relate to both release of traction and recovery of Muller cell function and anatomy which is so important to central foveal stability.^{6,8}

4. Conclusion

Vitreomacular traction can cause Muller Cell Cone disruption leading to foveal dehiscence. This instability can be detected with SD-OCT as a vertical hyper-reflective stress line that can evolve to FTMH. With release of vitreoretinal traction, it is possible that MCC can act to close the macular hole (if small enough) and re-establish the correct foveal anatomy.

Patient consent

The patient consented to publication of the case in writing.

Funding

No funding or grant support.

Authorship

All authors attest that they meet the current ICMJE criteria for Authorship.

Declaration of competing interest

The following authors have no financial disclosures: RCP, LCZ, LPC, MRLM.

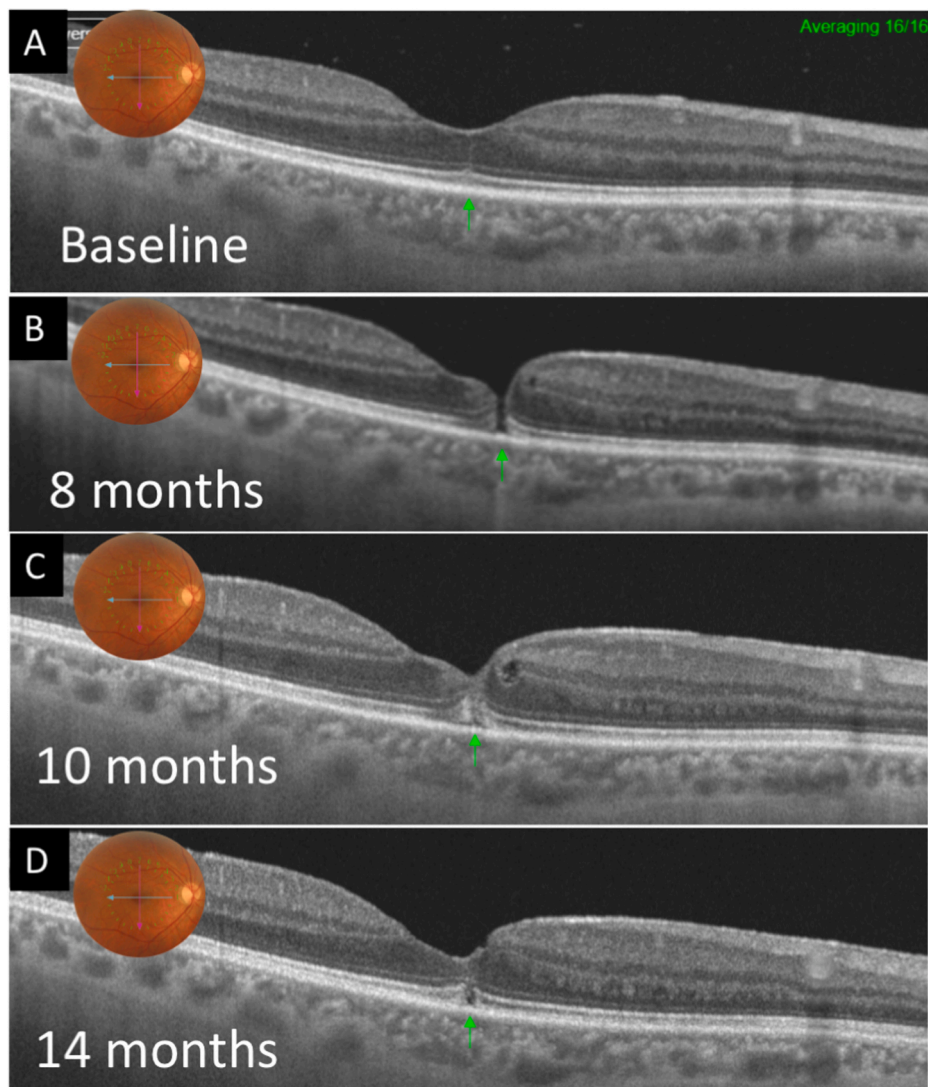


Fig. 2. A-D. Tracked spectral domain - optical coherence tomography (SD – OCT) illustrates progression from a central hyper-reflective line to a small full thickness macular hole with subsequent resolution of the FTMH.

References

1. Scharf JM, Hilely A, Preti RC, et al. Hyperreflective stress lines and macular holes. *Invest Ophthalmol Vis Sci.* 2020;61(4):50.
2. Gass JD. Idiopathic senile macular hole. Its early stages and pathogenesis. *Arch Ophthalmol.* 1988;106(5):629–639.
3. Govetto A, Sarraf D, Hubschman JP, et al. Distinctive mechanisms and patterns of exudative versus tractional intraretinal cystoid spaces as seen with multimodal imaging. *Am J Ophthalmol.* 2020;212:43–56.
4. Provis JM, Dubis AM, Maddess T, Carroll J. Adaptation of the central retina for high acuity vision: cones, the fovea and the avascular zone. *Prog Retin Eye Res.* 2013;35: 63–81.
5. Bringmann A, Syrbe S, Gorner K, et al. The primate fovea: structure, function and development. *Prog Retin Eye Res.* 2018;66:49–84.
6. Scharf JM, et al. *Hyperreflective Stress Lines and Macular Holes.* IOVS; 2020.
7. Ishibashi T, Iwama Y, Nakashima H, Ikeda T, Emi K. Foveal crack sign: an optical coherence tomography sign preceding macular hole after vitrectomy for rhegmatogenous retinal detachment. *Am J Ophthalmol.* 2020.
8. Bringmann A, Duncker T, Jochmann C, Barth T, Duncker GIW, Wiedemann P. Spontaneous closure of small full-thickness macular holes: presumed role of Muller cells. *Acta Ophthalmol.* 2019.