

## Strategy for salvage pedicle screw placement: A technical note

Shunsuke Fujibayashi, MD, PhD<sup>a,\*</sup>, Mitsuru Takemoto, MD, PhD<sup>a</sup>, Masashi Neo, MD, PhD<sup>b</sup>,  
Shuichi Matsuda, MD, PhD<sup>a</sup>

<sup>a</sup> Department of Orthopaedic Surgery, Graduate School of Medicine, Kyoto University, Kyoto, Japan

<sup>b</sup> Department of Orthopaedic Surgery, Osaka Medical College, Osaka, Japan

### Abstract

**Background:** Salvage surgery for failed lumbar spine fusion with a loosened pedicle screw is challenging. In general, the strategy includes replacement with larger and longer pedicle screws, augmentation with polymethylmethacrylate cement or hydroxyapatite granules, and extension of fused segments. The purpose of this study is to introduce a new technique for pedicle screw replacement after failed lumbar spine fusion.

**Methods:** Five salvage operations were performed using a different trajectory (DT) pedicle screw replacement technique based on 3-dimensional radiological information. Position of the alternative pedicle screws was planned carefully on the computer screen of a computed tomography-based navigation system before the operation. To obtain sufficient initial stability, 1 of 2 techniques was chosen, depending on the patient. One technique created a completely new route, which did not interfere with the existing screw hole, and the other involved penetration of the existing screw hole.

**Results:** DT pedicle screws were replaced successfully according to the preoperative plan. In all patients, bony union were achieved at the final follow-up period without any instrument failure. Extension of the fused segments could be avoided by using the DT pedicle screw replacement technique combined with transforaminal lumbar interbody fusion.

**Conclusions:** The DT pedicle screw replacement technique is a treatment option for salvage lumbar spine surgery.

**Clinical relevance:** The current technique is a treatment option for salvage operations that can both avoid extension of a fused segment and achieve successful bony union.

Published by Elsevier Inc. on behalf of ISASS – The International Society for the Advancement of Spine Surgery.

**Keywords:** Pedicle screw; Salvage surgery; Spinal fixation

Salvage surgery for failed lumbar fusion remains challenging. In cases involving pedicle screw loosening, replacement of the pedicle screw in an enlarged pedicle hole is controversial. In general, treatment options include replacement of the screw using a larger and longer pedicle screw in the existing pedicle hole,<sup>1</sup> augmentation with calcium phosphate cement or hydroxyapatite granules,<sup>2</sup> augmentation with polymethyl methacrylate cement,<sup>3</sup> and extension of the fused segments. In cases involving severe loosening in a large pedicle hole, neither replacement with a larger and longer screw nor augmentation with calcium phosphate cement or hydroxyapatite granules is insufficient to provide initial stability. Although augmentation with polymethyl methacrylate cement provides sufficient initial stability, this may be reduced by the subsequent loosening

between the cement and surrounding bone interface. Extension of the fused segments may be related to several comorbidities and may accelerate subsequent adjacent segment disease. Recently, 2 cases of successful replacement of customized large-diameter pedicle screw for severely loosened pedicle screw were reported.<sup>4</sup> Although the technique was easy and effective, manufacturing of customized screw adds to the cost and requires several weeks, and preoperative planning of screw diameter from CT is technically demanding. Also, the applications of large screw are limited only for the case without pedicle wall fracture. In the current study, we introduce a new technique for pedicle screw replacement, in which an alternative pedicle screw is placed into the same pedicle through a different route. We discuss the clinical and radiological results.

\* Corresponding author: Shunsuke Fujibayashi, MD, PhD, Department of Orthopedic Surgery, Graduate School of Medicine, Kyoto University, Kyoto 606-8507, Japan. Tel.: +81 757513362; fax: +81 757518409.

E-mail address: [shfujji@kuhp.kyoto-u.ac.jp](mailto:shfujji@kuhp.kyoto-u.ac.jp)

### Materials and Methods

Five patients with failed lumbar spine fusion with severe pedicle screw loosening were treated using our different

Table 1  
Patient's demographic data

	Age/Sex	Initial surgery	Preoperative JOA score	Salvage surgery	DT pedicle screw	Postoperative JOA score (Recovery rate)*	Follow-up period (M)	Bony union
1	38/Man	PLIF (L3-5)	11	TLIF (L3-5)	L3,5	26 (83.3)	18	+
2	70/Man	PLF (L4-5)	18	TLIF (L4-5)	L5	25 (63.6)	24	+
3	72/Woman	PLIF (L2-S)	15	TLIF (L4-S)	S1	20 (35.7)	29	+
4	82/Man	PLF (L4-S)	12	TLIF (L2-S)	S1	19 (41.2)	27	+
5	70/Man	PLF (L1-S)	8	TLIF (L1-S)	S1	19 (52.4)	18	+

Abbreviations: PLF, Lumbar posterolateral fusion; TLIF, Transforaminal lumbar interbody fusion; DT, Different trajectory; JOA Score, Japanese Orthopaedic Association Score.

Recovery rate = [Postoperative score–Preoperative score]/[29 (Full score)–Preoperative score] × 100).

\*At final follow-up.

trajectory pedicle screw replacement technique without extension of the fused segments.

*Preoperative planning and operative procedures*

The optimum pedicle screw position was assessed preoperatively using 3-dimensional computed tomography (3D CT) on a computer navigation system (StealthStation TRIA, Medtronic Sofamor Danek, Memphis, TN). Both the entry point and the target point of the pedicle screw were set on the computer screen, and the trajectory of the alternative pedicle screw was decided. Trajectory in the sagittal plane was considered when DT screws were not placed successfully in the axial plane on the preoperative assessments. Whenever possible, a completely new route that did not interfere with the existing screw hole was selected. In

patients where interference with the previous screw hole was unavoidable, penetration of the previous screw hole through the shortest distance was selected. In the operating theater, it is usually impossible to use a navigation system because of the lack of an anatomical structure to which to attach a reference frame and the difficulty in registration caused by metal artifacts. Therefore, we decided the planned entry point and the trajectory under the guidance of a fluoroscope. Meticulous preparation of screw hole is mandatory to avoid the fracture of pedicle during the placement of DT screws. The first step is making a new entry point and bony hole by hand using a narrow and sharp probe. The second step is a gradual and careful tapping. To avoid the pedicle fracture and penetration of the previous screw holes, relative small diameter screws are usually selected. And to achieve the sufficient initial stability,

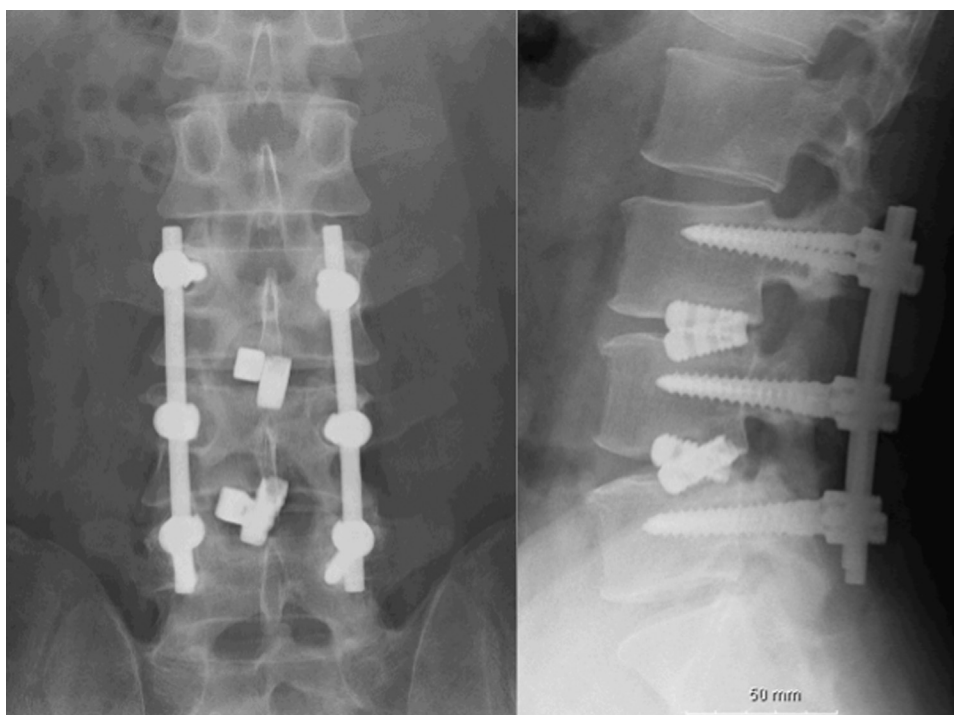


Fig. 1. Preoperative plain X-ray. Anteroposterior and lateral views of patient 1 showing L3-5 PLIF without autologous bone graft. Subsidence of the intervertebral spacer and loosening of the pedicle screws are evident.

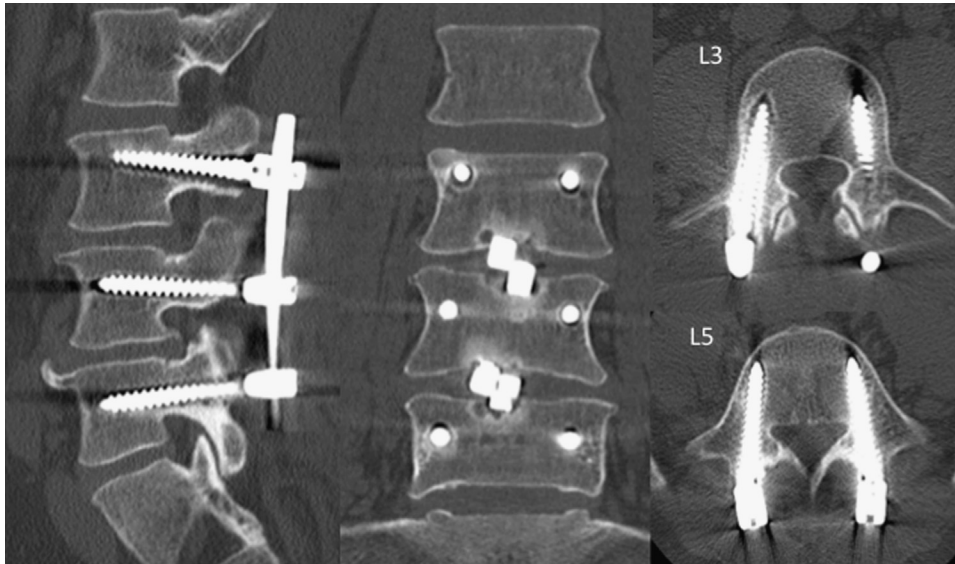


Fig. 2. Preoperative CT demonstrating severe loosening of the pedicle screws at L3 and L5.

engagement of the cortex by the diameter screw is more important than the placement of a large-diameter screw.

**Results**

In all the patients, alternative screws were placed successfully according to the preoperative plan. Intraoperative screw stability was confirmed manually and found to

be sufficient in all the patients. In all the patients, radiological bony union was achieved successfully at the final follow-up, and the clinical results were satisfactory. No implant breakage occurred during the follow-up (Table 1).

*Illustrative case*

A 38-year-old man presented at our institution complaining of severe low-back pain and a tingling sensation in both

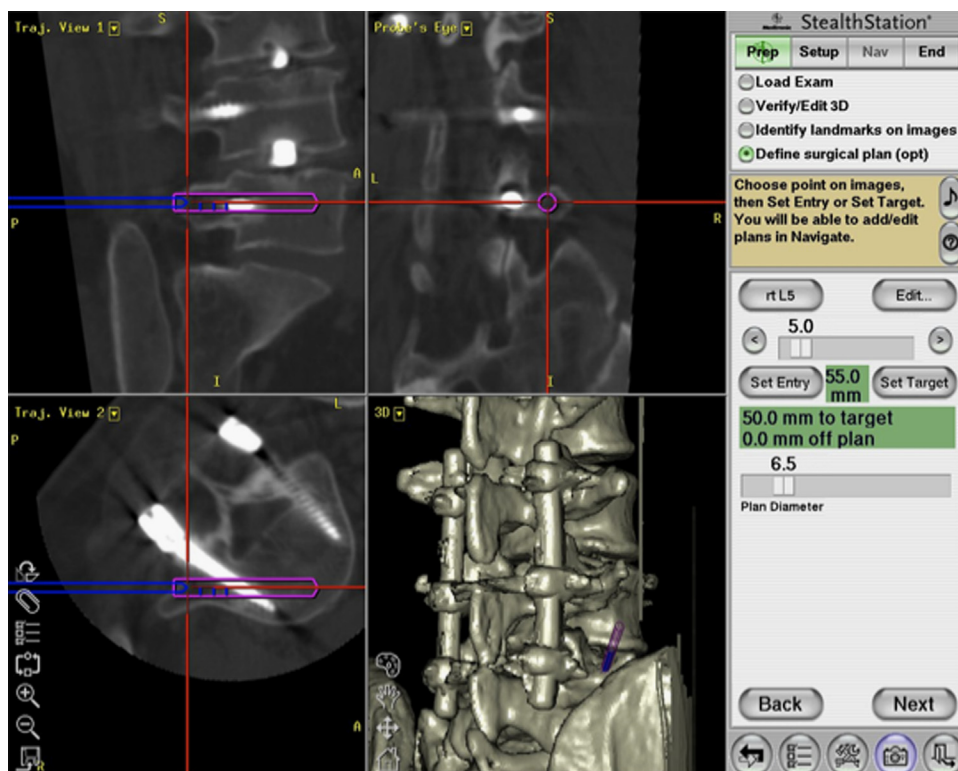


Fig. 3. The navigation system's views provide 3-dimensional, coronal, parasagittal, and axial images in conjunction with the different trajectory pedicle screw at L5. The alternative pedicle screw penetrating the existing pedicle hole is visible.

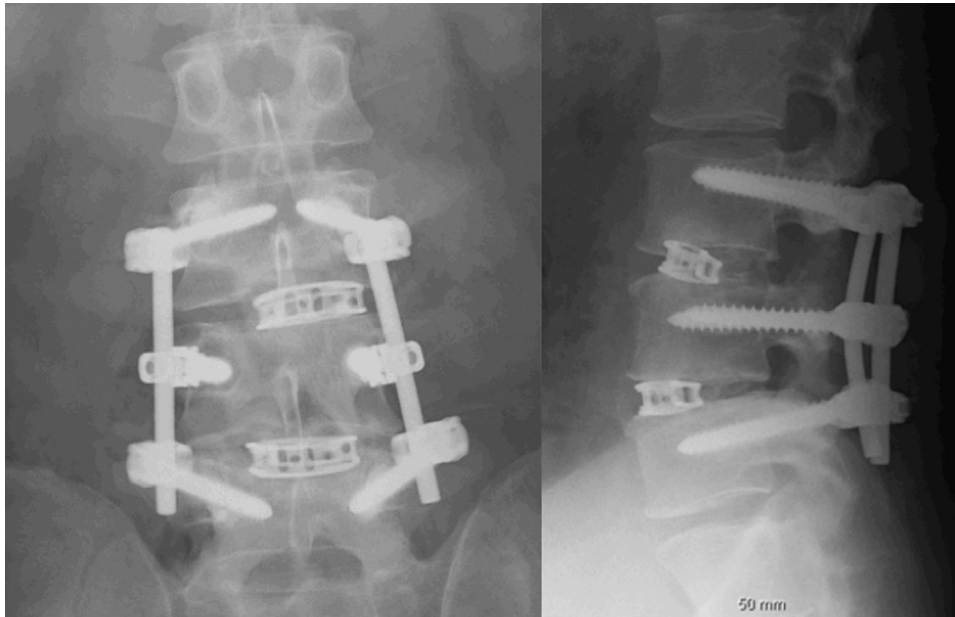


Fig. 4. Postoperative plain X-ray anteroposterior and lateral views of patient 1 showing transforaminal lumbar interbody fusion at the same segments.

legs because of nonunion of posterior lumbar interbody fusion (PLIF) at L3-5 (Figs. 1 and 2). PLIF had been performed previously using a titanium spacer without a bone graft. Preoperative CT showed spacer subsidence into the vertebral endplate and severe pedicle screw loosening. 3D assessment indicated that both the alternative L3 and L5 screws penetrated the existing screw hole from a far-lateral entry point at a high inversion angle (Fig. 3). The titanium intervertebral spacers were removed via the transforaminal route using a paraspinous muscle-splitting approach. A boomerang-type cage was inserted into the intervertebral space with a massive autologous iliac crest bone graft. According to the preoperative plan, the L3 and L5 pedicle screws were placed after packing the existing pedicle holes

with hydroxyapatite granules. Larger L4 pedicle screws were replaced using the same pedicle route. The initial stability was sufficient in all the screws (Fig. 4). Bony union was achieved at 6 months, the tingling sensation in both legs disappeared and low-back pain decreased (Fig. 5).

### Discussion

We successfully treated 5 complex cases of nonunion of the lumbar spine using a new technique involving DT pedicle screw replacement without extension of the fused segment.

There are several important points to consider when placing a DT pedicle screw to achieve bony union. To replace the pedicle screw precisely, meticulous preoperative

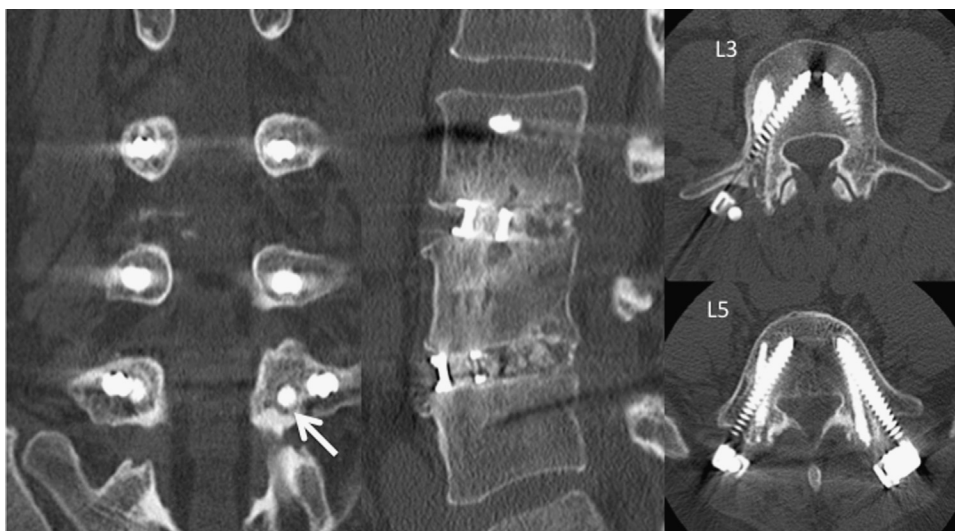


Fig. 5. Postoperative CT demonstrating different trajectory pedicle screw replacement at L3 and L5 according to the preoperative plan. The arrow indicates hydroxyapatite granules inserted into the existing pedicle hole.

surgical planning on 3D CT is mandatory. Although workstation of computer navigation system is useful for preoperative planning of optimum screw trajectory, other 3D computer software will be applicable. The surgeon must also use a wide exposure to reproduce the surgical plan in the operative field. To provide an optimal screw trajectory, the paraspinal muscle-splitting approach is useful for exposing a wide operative field needed to provide a far-lateral entry point and to avoid inference by soft tissue.<sup>5</sup> In our technique, assembly of the screw-rod construct can be difficult because the screw heads are not in line, especially in cases with multisegmental fusion. In such complex situations, a multiaxial pedicle screw system and various offset connectors are useful. We used a special screw-rod assembling technique in Patient 1: the rod was placed inside the pedicle screws at L3 and L5, and outside the pedicle screw at L4 to counteract the highly offset situation (Fig. 4). Augmentation of the existing pedicle hole with autologous bone or hydroxyapatite granules was important for increasing the stability of the alternative screw. To achieve definite bony union and to decrease the load on the pedicle screws, interbody fusion was necessary for the salvage operations. The transforaminal lumbar interbody fusion approach was safer and more useful than the PLIF approach for these patients with epidural adhesions caused by previous operations.<sup>6</sup>

Although sufficient intraoperative stability of all pedicle screws was confirmed manually, one limitation of the current study is the lack of biomechanical data for the DT pedicle screws that were placed near coexisting large bony holes. Biomechanical studies using cadavers show that adequate insertional torque is achieved when the alternative

screw is inserted into a violated pedicle after the failure of thoracic pedicle screw placement.<sup>7</sup> Alternative screw stability can be increased by augmentation with calcium-based cement.<sup>8</sup> These biomechanical results might be applicable to treating the lumbar spine.

The current technique is a treatment option for salvage operations that can both avoid extension of a fused segment and achieve successful bony union.

## References

1. Polly DW, Orchowski JR, Ellenbogen RG. Revision pedicle screws: bigger, longer shims—what is best? *Spine* 1998;23:1374–9.
2. Yerby SA, Toh E, McLain RF. Revision of failed pedicle screws using hydroxyapatite cement: a biomechanical analysis. *Spine* 1998;23:1657–61.
3. Ngu BB, Belkoff SM, Gelb DE, et al. A biomechanical comparison of sacral pedicle screw salvage techniques. *Spine* 2006;31:E166–8.
4. Huang RC, Meredith DS, Kepler CK, et al. Salvage of lumbar pseudarthrosis with customized large-diameter pedicle screws. *Spine* 2011;36:E1489–92.
5. Fujibayashi S, Neo M, Takemoto M, et al. Paraspinal-approach transforaminal lumbar interbody fusion for the treatment of lumbar foraminal stenosis. *J Neurosurg Spine* 2010;13:500–8.
6. Ota M, Neo M, Fujibayashi S, et al. Advantages of the paraspinal muscle splitting approach in comparison with conventional midline approach for S1 pedicle screw placement. *Spine* 2010;35:E452–7.
7. Lehman RA, Kuklo TR. Use of the anatomic trajectory for thoracic pedicle screw salvage after failure/violation using the straight-forward technique: a biomechanical analysis. *Spine* 2003;28:2072–7.
8. Derincek A, Wu C, Mehbod A, et al. Biomechanical comparison of anatomic trajectory pedicle screw versus injectable calcium sulfate graft-augmented pedicle screw for salvage in cadaveric thoracic bone. *J Spinal Disord Tech* 2006;19:286–91.