



BRIEF REPORT

Hereditary Papulotranslucent Acrokeratoderma: Prominent Clinical Presentation after Water Exposure

Beom Jun Kim, Jihee Kim¹, Sang Ho Oh¹*Department of Dermatology, Yonsei University Wonju College of Medicine, Wonju, ¹Department of Dermatology, Yonsei University College of Medicine, Seoul, Korea*

Dear Editor:

Hereditary papulotranslucent acrokeratoderma (HPA) was first described in 1973 by Onwukwe et al.¹ It is a rare autosomal dominant disease characterized by asymptomatic, persistent, white-yellow translucent papules on the palms and soles and is accentuated by aqueous exposure. HPA should be distinguished from aquagenic syringal acrokeratoderma (ASA), in which a palmar rash after water exposure is noted.

A 44-year-old female presented with lesions on her palms and soles. The lesions had first appeared 30 years prior, after swimming. The lesions were not painful or pruritic and did not regress spontaneously. Notably, she stated that the lesions became more prominent when her palms were exposed to water. She claimed that her teenage son recently developed similar lesions.

On physical examination, numerous tiny flesh-colored papules were seen on her palms and soles. For diagnosis, we asked her to soak her left hand in lukewarm water for 10 minutes. The lesions immediately became distinguishable. One-to-three-millimeter sized papules were diffusely scattered on the palm and ulnar edge of the left hand (Fig. 1A, B), and the dorsal aspect was partially in-

volved. Skin biopsy was performed on two lesions; center of the palm and ulnar edge of the left hand. Both specimens had hyperkeratosis, hypergranulosis, and acanthosis. There were no inflammations in the dermis or abnormality in adnexal structures (Fig. 1C, D).

HPA is a rare variant of punctate palmoplantar keratoderma (PPK)¹. However, unlike punctate PPK, HPA may involve some part of dorsum and volar aspect of hands and feet, and the papular lesion does not fall off or leaves depression. The pathogenesis remains uncertain². It usually manifests in adolescence to mid-adulthood. Water exposure exacerbates the lesions. Marked hyperkeratosis, hypergranulosis and acanthosis are typical histopathological characteristics. No significant inflammation or changes in elastic fiber and adnexal structure are observed¹.

HPA shares similar characteristics, including onset, distribution, and reaction to water exposure, with ASA³. However, ASA is reported as acquired and most significantly, it has transient symptomatic lesions⁴. ASA presents "hand-in-the-bucket" sign, burning sensation and edema after water exposure⁵. Dilated sweat ducts are a characteristic histopathological finding distinguishing ASA from HPA.

In this case, it is difficult to precisely describe heredity. However, autosomal dominance can be presumed. Based on the clinical presentation demonstrating asymptomatic papular lesions accentuated by aqueous exposure and family history based on similar lesions in her son, and no significant change of the dermis in histopathologic findings, the patient could be diagnosed with HPA. As she presented with no specific symptoms, we prescribed topical urea and salicylic acid mixed cream for hyperkeratosis.

Satisfactory treatments for HPA have not been established.

Received November 9, 2018, Revised February 26, 2019, Accepted for publication March 26, 2019

Corresponding author: Sang Ho Oh, Department of Dermatology, Yonsei University College of Medicine, 50-1 Yonsei-ro, Seodaemun-gu, Seoul 03722, Korea. Tel: 82-2-2228-2080, Fax: 82-2-393-9157, E-mail: oddung93@yuhs.ac

ORCID: <https://orcid.org/0000-0002-4477-1400>

This is an Open Access article distributed under the terms of the Creative Commons Attribution Non-Commercial License (<http://creativecommons.org/licenses/by-nc/4.0>) which permits unrestricted non-commercial use, distribution, and reproduction in any medium, provided the original work is properly cited.

Copyright © The Korean Dermatological Association and The Korean Society for Investigative Dermatology

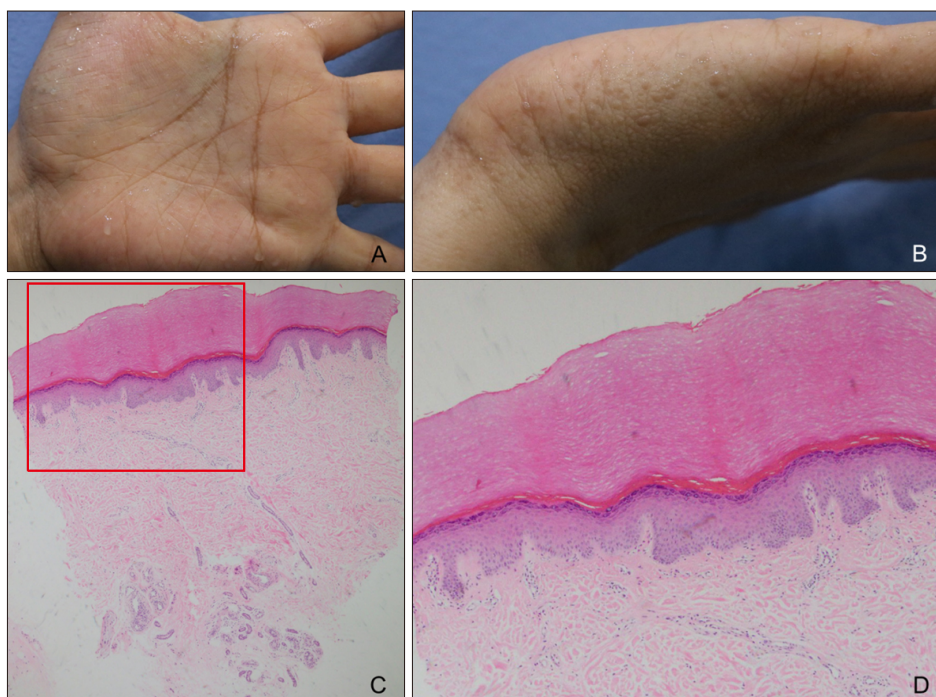


Fig. 1. Clinical and histopathologic photographs. Clinical photographs of left palm (A) and ulnar edge of the left hand (B) after water exposure for 10 minutes. For diagnosis, skin biopsy was performed on the center of the left palm and ulnar edge of the left hand. Both specimens showed epidermal hyperkeratosis, hypergranulosis, and acanthosis, without dermal inflammation or changes of adnexal structures. These findings were more prominent in specimen of the center of the palm (H&E: C, ×40; D, magnified view of the red box in C, ×100).

Due to its asymptomatic nature and no association with systemic diseases, it usually does not require treatment. Keratolytics including topical urea, salicylic acid, and ammonium can be used.

We report a case of HPA with a hereditary family history and characteristic lesions prominent after water exposure. We received the patient's consent form about publishing all photographic materials. We aim to create awareness among physicians regarding this rare, interesting, and distinctive disease.

CONFLICTS OF INTEREST

The authors have nothing to disclose.

ORCID

Beom Jun Kim, <https://orcid.org/0000-0003-1367-3274>

Jihee Kim, <https://orcid.org/0000-0002-0047-5941>

Sang Ho Oh, <https://orcid.org/0000-0002-4477-1400>

REFERENCES

1. Onwukwe MF, Mihm MC Jr, Toda K. Hereditary papulotranslucent acrokeratoderma. A new variant of familial punctate keratoderma? *Arch Dermatol* 1973;108:108-110.
2. Sun Y, Jia H. Hereditary papulotranslucent acrokeratoderma: a simultaneous presentation in daughter and mother. *Indian J Dermatol Venereol Leprol* 2013;79:555.
3. Luo DQ, Li Y, Huang YB, Wu LC, He DY. Aquagenic syringeal acrokeratoderma in an adult man: case report and review of the literature. *Clin Exp Dermatol* 2009;34:e907-e909.
4. Poletti ED, Muñoz-Sandoval R. Images in clinical medicine. Aquagenic keratoderma. *N Engl J Med* 2014;371:952.
5. Yan AC, Aasi SZ, Alms WJ, James WD, Heymann WR, Paller AS, et al. Aquagenic palmoplantar keratoderma. *J Am Acad Dermatol* 2001;44:696-699.