

How much safety is actually 'safe'? Commentary on 'Safety of the Apollo Onyx delivery microcatheter for embolization of brain arteriovenous malformations: results from a prospective post-market study' by Meyers *et al*

Alexander Sirakov,¹ Krasimir Minkin,² Stanimir Sirakov ¹

We read with great interest the recently published article in the journal entitled 'Safety of the Apollo Onyx delivery microcatheter for the embolization of brain arteriovenous malformations: results from a prospective post-market study'. This study yielded overall fantastic technical, angiographic results with low morbidity and mortality rates.¹ The primary endpoints for which the trial was powered were clearly defined as follows: unintentional catheter tip detachment with clinical sequelae, catheter rupture/break/fracture with clinical sequelae, or retained catheter body in the vasculature. Secondary endpoints, both acute (30 days) and long term (12 months), are also presented and specified. Patients not experiencing an adverse event and without any catheter retained were considered successfully concluded. The study failed to document any cases of migration of the retained microcatheter tip after embolization. The authors identified that the device-related complications or adverse events were lower in their study than in previously published literature.

The primary purpose of this commentary is to congratulate the authors for the well-conducted study and the results it yielded. However, we would like to use the opportunity to issue alarming attention to the *JNIS* readership over some worrying real-world and single-centre data regarding the safety of the Apollo microcatheter. Our institution is a perfect case example of a mid-volume cerebrovascular centre. For

8 years (January 2013 to January 2021) over 200 patients underwent endovascular embolization with detachable tip microcatheters and non-adhesive liquid embolic agents (LEAs). Our experience is generally limited to the Apollo Onyx delivery microcatheter or 323 catheters because it remains the only locally available detachable tip microcatheter. With the Apollo microcatheter, we successfully obtained experience with the most commercially available non-adhesive LEAs—Onyx 18, Squid 12, all formulations of PHIL and Menox 18.^{2,3} We acknowledge that gaining experience with various embolization techniques like pressure cooker and combined LEAs⁴ via the same delivery catheter and overcoming the learning curve of the notorious transvenous approach were thanks to the feasibility of the Apollo microcatheter. During that period, we experienced and reported in referred journals similar technical and clinical results regarding cerebral arteriovenous malformation (AVM) endovascular embolization.

Up until recently (May 2020) a retained catheter body into the vasculature was encountered only once. In this case, the microcatheter was intentionally dismantled at the puncture site without even attempting to mechanically detach the Apollo. The decision to leave the catheter body in the vasculature was based on the calibre of the feeding artery, the nature of the target nidal component, and the increased chance of traction-related cerebral vascular damage with unpredictable consequences. Long-term follow-up of this patient for almost 5 years after the endovascular embolization failed to document any device related complications—parent vessel occlusion or

peripheral and groin long-term vascular damage.

From May 2020 to May 2021, we observed eight consecutive detachment issues with the Apollo microcatheter. In these cases, we failed to successfully detach the tip of the catheter despite extensive pulling and the fact that the detachable portion of the catheter remained 'untouched' by the used non-adhesive LEA (online supplemental videos 1,2). All eight catheters had to be left in situ with a cut-off proximally at the femoral puncture site. Given the relative increase in thromboembolic complications from the retained microcatheters, all the patients commenced regular aspirin 100mg daily. Within 90 days of the embolization, two patients underwent emergent operative removal of the retained Apollos, resulting in limb amputation and stent-graft implantation. The bodies of the two catheters were found embedded within the distal thoracic abdominal aorta and stuck into the proximal posterior tibial artery (figure 1).

To avoid any bias, we performed a quantitative investigation of the applied embolic agents during all cases. Vials with Onyx 18 (eV3- Covidien, Irvine, CA) and Menox liquid embolic system (Meril Life

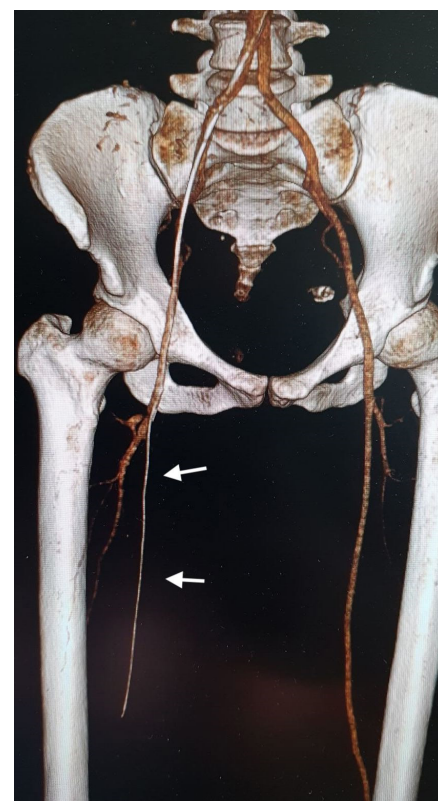


Figure 1 Computed tomography (CT) angiography with 3D volume rendering reconstructions of the lower limbs revealing a lengthy foreign body within the femoral/popliteal artery of the right leg.

¹Radiology department, University Hospital St Ivan Rilski, Sofia, Bulgaria

²Neurosurgery department, University Hospital St Ivan Rilski, Sofia, Bulgaria

Correspondence to Dr Stanimir Sirakov, Radiology department, University Hospital St Ivan Rilski, Sofia, Bulgaria; ssirakov@bsunivers.com

Sciences, India Pvt Ltd) were tested for various quality attributes, that is, viscosity measurement, solidification time, material expansion, tantalum suspension, dimethyl sulfoxide (DMSO) radiopacity, and fragmentation tests. All the conducted tests met standard requirements.

We reviewed results from the medical device reports submitted to MAUDE (Manufacturer and User Facility Device Experience) US Food and Drug Administration between May 2015 to May 2021 involving Apollo microcatheter entrapment. Although some of the encounters were not reported in detail, we identified 15 cases of retained microcatheters due to failed catheter retraction. Nine of those cases were reported during the period May 2015 to May 2018.

Similar device faults and catheter technical malfunctions have been reported.^{5,6} However, this is the backbone of technological progress and the driving force of innovation in our field. Enhanced technical properties and offspring devices were born due to collaboration between scientists, physicians, and regulatory authorities.^{7,8}

Sometimes, this kind of report draws attention before an alarming trend has occurred.⁹ Most recently, a rallying cry from our community pointed out some dangerous features of a specific distal access catheter, which led to immense and appropriate action from the manufacturer and the regulatory authorities.¹⁰⁻¹² These types of articles have the power to turn the neurovascular armamentarium into something better than it was before.

When it comes to detachable tip microcatheters, technical failures have been observed with Apollo's major competitor (Sonic, Balt).¹³

In conclusion, any human activity involves some risk to life or health. Although it is possible to reduce the absolute risk of a particular activity, it is impossible to reach 'zero risk' or 'absolute safety' that is often demanded. The failure of this microcatheter could potentially lead to severe complications; hence this information should be

shared with colleagues by putting 'safety' into perspective.

Contributors Please change contributors: Conceptualization: AS, SS. Investigation and clinical results assessment: AS, SS, KM. Writing - original draft: AS, SS. Critical review: KM, SS.

Funding The authors have not declared a specific grant for this research from any funding agency in the public, commercial or not-for-profit sectors.

Competing interests None declared.

Patient consent for publication Not required.

Provenance and peer review Not commissioned; externally peer reviewed.

Data availability statement All data relevant to the study are included in the article or uploaded as supplementary information. Not applicable.

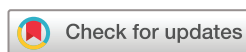

OPEN ACCESS

Open access This is an open access article distributed in accordance with the Creative Commons Attribution Non Commercial (CC BY-NC 4.0) license, which permits others to distribute, remix, adapt, build upon this work non-commercially, and license their derivative works on different terms, provided the original work is properly cited, appropriate credit is given, any changes made indicated, and the use is non-commercial. See: <http://creativecommons.org/licenses/by-nc/4.0/>.

© Author(s) (or their employer(s)) 2021. Re-use permitted under CC BY-NC. No commercial re-use. See rights and permissions. Published by BMJ.

► Additional supplemental material is published online only. To view, please visit the journal online (<http://dx.doi.org/10.1136/neurintsurg-2021-018052>).



To cite Sirakov A, Minkin K, Sirakov S. *J NeuroIntervent Surg* 2021;**13**:e22.

Accepted 18 August 2021
Published Online First 7 September 2021



► <http://dx.doi.org/10.1136/neurintsurg-2020-016830>

J NeuroIntervent Surg 2021;**13**:e22.
doi:10.1136/neurintsurg-2021-018052

ORCID iD

Stanimir Sirakov <http://orcid.org/0000-0001-6034-5340>

REFERENCES

- 1 Meyers PM, Fifi JT, Cockroft KM, *et al*. Safety of the Apollo Onyx delivery microcatheter for embolization of brain arteriovenous malformations: results from a prospective post-market study. *J Neurointerv Surg* 2021;**13**:935-41.
- 2 Sirakov S, Sirakov A, Minkin K, *et al*. Initial experience with the new ethylene vinyl alcohol copolymer based liquid embolic agent Menox in the endovascular treatment of cerebral arteriovenous malformations. *J Neurointerv Surg* 2019;**11**:1040-4.
- 3 Sirakov SS, Sirakov A, Minkin K, *et al*. Initial experience with precipitating hydrophobic injectable liquid in cerebral arteriovenous malformations. *Interv Neuroradiol* 2019;**25**:58-65.
- 4 Sirakov A, Minkin K, Sirakov S. Intermixed dimethyl-sulfoxide-based nonadhesive liquid embolic agents delivered serially via the same microcatheter for cerebral AVM treatment. *AJNR Am J Neuroradiol* 2020;**41**:681-6.
- 5 Newman CB, Park MS, Kerber CW, *et al*. Over-the-catheter retrieval of a retained microcatheter following Onyx embolization: a technical report. *J Neurointerv Surg* 2012;**4**:e13.
- 6 Maharaj MM, Biju R, Khashram M, *et al*. Delayed fragmentation and distal embolization of retained microcatheter causing lower limb ischemia: case report and review of the literature. *World Neurosurg* 2020;**140**:369-73.
- 7 Cortez GM, Turner RD, Monteiro A, *et al*. Walrus large bore guide catheter impact on recanalization first pass effect and outcomes: the WICKED study. *J Neurointerv Surg* 2021. doi:10.1136/neurintsurg-2021-017494. [Epub ahead of print: 15 Apr 2021].
- 8 Vollherbst DF, Berlis A, Maurer C, *et al*. Periprocedural safety and feasibility of the new LVIS EVO device for stent-assisted coiling of intracranial aneurysms: an observational multicenter study. *AJNR Am J Neuroradiol* 2021;**42**:319-26.
- 9 De Leacy R. The neurointerventional paradox: ensuring patient safety without restricting technological innovation. *J Neurointerv Surg* 2021;**13**:197-9.
- 10 Pearly Ti J, Yeo L, Anil G. Can a stent retriever damage the JET 7 reperfusion catheter? *AJNR Am J Neuroradiol* 2020;**41**:2317-9.
- 11 Majidi S, Bageac DV, Fayed I, *et al*. JET 7 XTRA flex reperfusion catheter related complications during endovascular thrombectomy. *J Neurointerv Surg* 2021;**13**:352-6.
- 12 Bageac D, Gershon B, DeLeacy R. P-014 Reperfusion catheter malfunction during stroke intervention: an analytical review of the FDA's Maude database. In: *Oral poster abstracts [Internet]*. BMJ Publishing Group Ltd, 2021.
- 13 Maimon S, Strauss I, Frolov V, *et al*. Brain arteriovenous malformation treatment using a combination of Onyx and a new detachable tip microcatheter, SONIC: short-term results. *AJNR Am J Neuroradiol* 2010;**31**:947-54.