

# Epidermal growth factor receptor expression in mice skin upon ultraviolet B exposure - Seborrheic Keratosis as a coincidental and unique finding

Azad K. Saeed, Nabil Salmo<sup>1</sup>Department of Pathology, College of Veterinary Medicine, <sup>1</sup>Department of Pathology and Forensic Pathology, School of Medicine-Sulaimani University/Kurdistan, Iraq

## Abstract

**Background:** Ultraviolet B (UVB) is the most damaging component of sunlight. It rapidly activates the epidermal growth factor receptor (EGFR) and generates reactive oxygen species (ROS) in excessive quantities that quickly overwhelm tissue antioxidants.

**Setting and Design:** To demonstrate the effects of UVB radiation on EGFR expression in mice skin and to evaluate the role of antioxidants in the exposed group.

**Materials and Methods:** After obtaining the approval of the ethical committee, forty mice from BALB/c strain were used in this experiment and were allocated into 3 groups; 10 (control group); 15 (exposure group); and 15 (exposed and treated with antioxidants). Antioxidants were administered through subcutaneous injection. Skin biopsies from all groups were stained with EGFR antibodies. Total antioxidant status (TAS) was evaluated in all groups.

**Statistical Analysis:** The data obtained were analyzed using ANOVA, Duncan's test, and Pearson's Correlation.

**Results:** The highest EGFR expression in exposure group was of score 3<sup>+</sup> (53%). The highest EGFR expression in treatment group was score 0 (40%). Apoptotic bodies and dermal mast cells increased in exposure group while decreased in treatment group. The mean values for TAS were measured for each group; control group = 1.2 mmol/l; exposure group = 0.87 mmol/l; treatment group = 1.3 mmol/l.

**Conclusions:** UVB led to Seborrheic Keratosis (SK) in mice through enhancement of *EGFR* expression. Antioxidants effectively reduced UVB-induced SK, reduced epidermal changes, apoptotic bodies, and decreased dermal mast cells. TAS measurement declined in exposure group, while it was within normal range in most treated cases.

**Key Words:** Apoptotic bodies, epidermal growth factor receptor, mast cells, seborrheic keratosis, total antioxidant status, Ultraviolet B

### Access this article online

#### Quick Response Code:



#### Website:

www.advbiores.net

#### DOI:

10.4103/2277-9175.100178

### Address for correspondence:

Dr. Nabil Salmo, Department of Pathology and Forensic Pathology, School of Medicine-, Sulaimani University/Kurdistan, Iraq.

E-mail: iraqnabil1954@gmail.com

Received: 02.04.2012, Accepted: 08.05.2012

Copyright: © 2012 Saeed. This is an open-access article distributed under the terms of the Creative Commons Attribution License, which permits unrestricted use, distribution, and reproduction in any medium, provided the original author and source are credited.

**How to cite this article:** Saeed AK, Salmo N. Epidermal growth factor receptor expression in mice skin upon ultraviolet B exposure - Seborrheic Keratosis as a coincidental and unique finding. Adv Biomed Res 2012;1:59.

## INTRODUCTION

Ultraviolet B (UVB) is a minor component of sunlight reaching to the earth surface, and is experimentally demonstrated to be the most effective light to induce skin cancer in animals.<sup>[1]</sup> UVB radiation is a complete carcinogen, being able to initiate, promote, and advance the development of skin cancer.<sup>[2,3]</sup> Indeed, murine skin cancers induced by repeated exposure to UV radiation provides an excellent model system for investigating the molecular mechanisms of ultraviolet carcinogenesis. Experiments with animal models, particularly mouse, have already yielded a lot of data on how skin tumor development depends on dose, time, and wavelength of the UV-radiation.<sup>[4]</sup>

Ultraviolet radiation causes both DNA damage and epigenetic effects in response to DNA damage.<sup>[5]</sup> The epigenetic effects of UV radiation include changes in signalling and gene expression that regulate cell proliferation and survival in the short-term and contribute to skin cancer development in the long-term.<sup>[6]</sup> Exposure to UV induces a number of pathological changes initiated in mammalian skin, including erythema, edema, epidermal hyperplasia, sunburn cell formation, immune suppression, and changes in expression of numerous genes associated with proliferation and differentiation and eventually skin cancer development.<sup>[7-9]</sup> Ultraviolet exposure results in the rapid activation of epidermal growth factor receptor (EGFR) by a reactive oxygen intermediate-mediated mechanism. In response to UV-induced activation, EGFR increases cell proliferation, suppresses cell death, and augments and accelerates epidermal hyperplasia. EGFR has been implicated previously in mouse skin carcinogenesis, because genetic ablation of the receptor reduces skin tumor growth.<sup>[5,6,10]</sup> Skin exposure to UV radiation generates reactive oxygen species (ROS) in excessive quantities that quickly overwhelm tissue antioxidants and other oxidant-degrading pathways. Parenteral administration of various antioxidants may reverse UVB-induced changes in cell cycle profile and cell cycle regulatory proteins.<sup>[11]</sup> Vitamin E and selenium appear to act synergistically, which function as a chain-breaking antioxidant and prevent the propagation of free radical reactions in all cells in the body.<sup>[11-13]</sup> Total antioxidant status (TAS) assays have been designed to determine overall antioxidant power of samples contributed by antioxidants and their interactions. Evaluation of TAS in body fluids has been used as one of the biological markers for monitoring oxidative stress in humans.<sup>[14]</sup> The aim of this study was to demonstrate the EGFR protein expression in keratinocytes after UVB exposure by application of immunohistochemistry (IHC), to see the effect of antioxidants on EGFR expression in mouse

skin upon UVB exposure and to compare the TAS in control, exposure, and treatment groups.

## MATERIALS AND METHODS

### Study area

This study was carried out from October 22, 2010 to February 30, 2011, in Veterinary Medicine Teaching Hospital, University of Sulaimani, Histopathology Laboratory and Chemical Laboratory of Shorsh Hospital in Sulaimani Governorate/Kurdistan-Iraq.

### Animal model

After obtaining the approval of ethical committee, forty Albino mice of *Mus musculus* species, BALB/c strain of both sexes, four-weeks old underwent this experiment. They were allocated into three groups; 10 of which were considered as control group (not exposed and not treated with antioxidants); 15 of which were considered as exposure group (exposed to UVB light only); and 15 of which were considered as treatment group (exposed to UVB light and treated with antioxidants).

### Treatment of mice with antioxidants

The antioxidants used in this study were as an injectable solution (Vitamin E as dl- $\alpha$ -tocopheryl acetate-50 mg/ml and Selenium as sodium selenite-0.5 mg/ml (ERFAN-DARW COMPANY LTD-IRAN) in a dose of 4  $\mu$ l/1gm of body weight through subcutaneous injection (100  $\mu$ l in a single dose). Mice were treated with antioxidants 3 days/week (at intervals-every other day) and exposed to UVB light 5 days/week throughout the whole experiment period (3 months).

### Ultraviolet B irradiation

The source of irradiation was a lamp of 312 nm wavelength, 15 watts; VILBER-LOURMAT-FRANCE, with a calculated power of 53 mj/sec. Mice from both groups (exposure and treatment groups) were exposed to UVB light for 20 minutes and 5 days/week. This was done after making a window by shaving the mouse's back skin (2\*5cm). At the end of the experiment, incisional biopsies were taken from the shaved areas of the three groups. All animals were anesthetized using general anaesthetic (Xylazine-Ketamine for mouse: 0.1 ml/10 gm of body weight (CEVA SANTE ANIMALE-FRANCE, HOLDEN MEDICA-INDIA) as recommended dose intraperitoneally (in a sterile 10 ml bottle with a rubber stopper, mix 1 ml of ketamine (100 mg/ml) + 0.1 ml of xylazine (100 mg/ml) + 8.9 ml of sterile water for injection). Biopsies were fixed in 10% neutral buffered formalin, processed, and embedded in paraffin blocks.

### Blood collection and storage

Before taking biopsies, 0.5 ml of blood sample was collected from each animal in the control, exposure

and treatment group via cardiac puncture. Each blood sample was collected into an eppendorf tube, incubated in an incubator at 37°C for 20 minutes. Serum was obtained after centrifugation at 5000 rpm for 5 minutes. The serum was collected into another eppendorf tube and used for TAS analysis.

### Total antioxidant status assay

Total antioxidants were measured by the ABTS method using kits from RANDOXLTD UK, as per manufacturer's instructions. As per the method, metmyoglobin (peroxidase) present in the chromogen provided in the kit reacts with H<sub>2</sub>O<sub>2</sub> to form ferrylmyoglobin, a free radical species. The chromogen also contains ABTS (2, 2'-Azino-di-[3-ethylbenzthiazoline sulphonate]) that reacts with ferrylmyoglobin to produce a radical cation, which has blue-green color and can be measured at 600 nm by spectrophotometer. Antioxidants present in the added serum cause suppression of this color production proportional to their concentration. Calibration of the assay was done using 6-hydroxy-2, 5, 7, 8-tetramethylchroman-2-carboxylic acid. The results were expressed in mmol/l. Twenty micro litre-sample and 1 ml of chromogen were required for the assay.

### Tissue biopsy preparation

Three sections of 5µm thickness were taken from each paraffin embedded tissue block. The first section was mounted on an ordinary slide for hematoxylin and Eosin staining for detection of any histological lesions. The second section was for Giemsa stain for mast cells counting, while the third section was mounted on a positively charged slide, then proceeding with the process of immunohistochemistry staining following the protocol that was supplied with the kit of anti-EGFR (SUPER SENSITIVE™ POLYMER-HRP IHC DETECTION SYSTEM, BIOGENEX-49026 MILMONT DRIVE | FREMONT CA 94538 | U.S.A.).

### Scoring of immunohistochemical staining

Membranous staining of EGFR was quantified according to positive cell percentage and intensity into 4-point scale: 0 = 0% negative for no staining, 1 + ; <25% positive cells for weak staining, 2 + ; 26-50% positive cells for moderate staining, 3 + ; > 50% positive cells for strong staining. This score system was adopted according to two previous researches.<sup>[15,16]</sup>

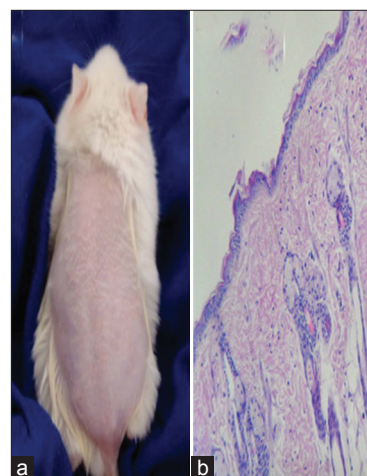
### Statistical analysis

The data obtained from our observations were analyzed using ANOVA, Duncan's test, and Pearson's correlation.

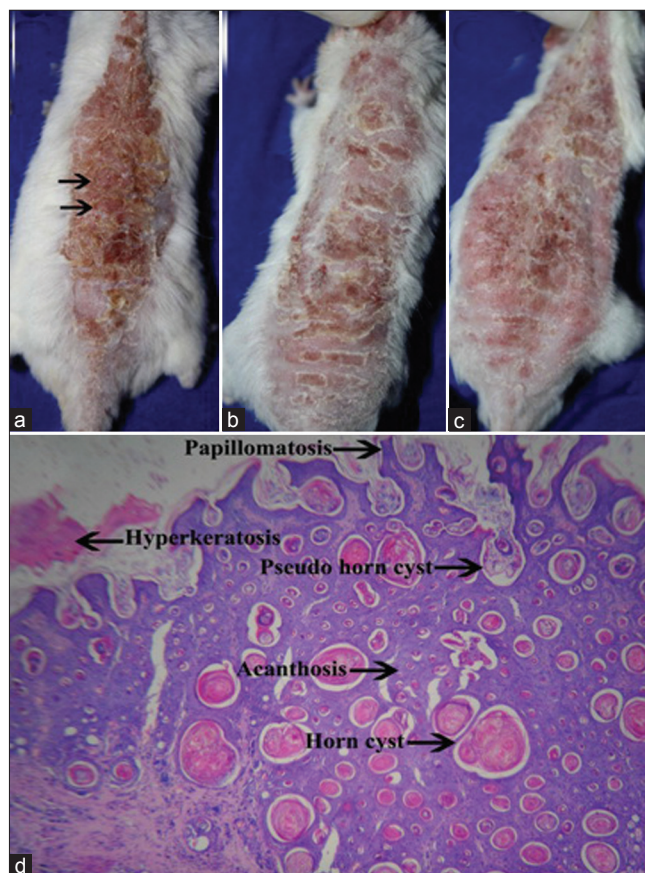
## RESULTS

### Control group

Grossly, skin of mice appeared normal. Histologically,



**Figure 1:** (a) Normal mouse skin appearance, after making a window. (b) Normal mouse skin histology, unexposed to radiation (H and E, x100)



**Figure 2:** (a) Skin was thickened, black arrows showing two small elevated masses, (b) Showing large numbers of friable crusts, (c) Crusts were sloughed, (d) Microscopical appearance of seborrheic keratosis, acanthotic type (H and E, x40)

skin sections revealed a normal epidermis which comprised of 2-3 layers and the dermis showed normal skin appendages except sweat glands [Figures 1a and b].

### Exposure group

The gross pathological examination of exposure group,



which appeared as slightly raised lesions, measured only a few mms in diameter, occasionally reaching a size of 2 centimeters with variable color, from light to black, most of them were tan or brown, rough, of friable consistency, some have smooth surface but characteristically show keratotic plugs [Figures 2a-c]. Irradiated group: UVB-induced epidermal tumor development, which was benign Seborrheic keratosis (SK), acanthotic type, in all cases with variable characteristics like acanthosis, hyperkeratosis and papillomatosis. Microscopical examination of acanthotic SK showed thickening of epidermal layers resulting from basaloid cell proliferation, presence of epidermal cysts filled with keratin (horn cyst) which is a common feature of SK. Some of these cysts resulted from enfolding of epidermis and are called pseudohorn cysts, with presence of squamous eddies [Figure 2d]. Epidermis contained cells with basophilic nuclei and deeply eosinophilic cytoplasm and regarded as sunburn cells (SBCs) or apoptotic bodies [Figure 3a]. The dermal changes showed infiltration of mononuclear inflammatory cells including macrophages and lymphocytes [Figure 3b]. In addition, the dermis showed increasing number of typical inflammatory mast cells, which had basophilic granules in lower and upper dermis but

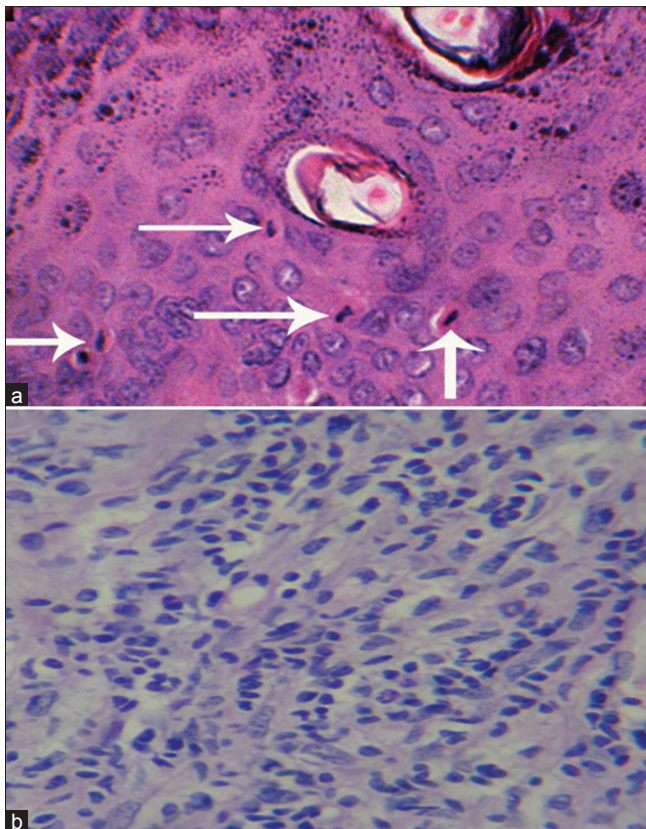
especially in upper dermis surrounding blood capillaries [Figures 4a and b].

#### Treatment group with antioxidants

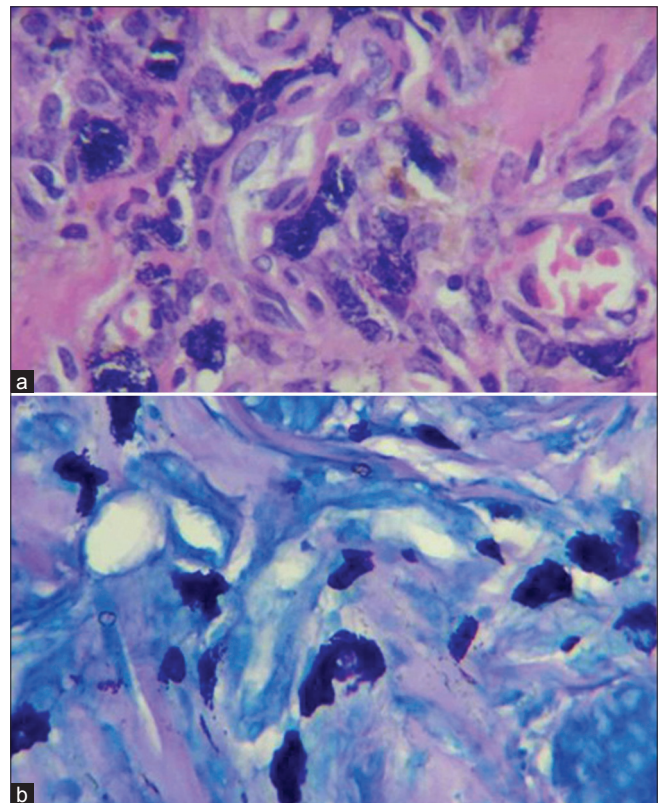
Gross lesions were also variable according to severity of lesions. Grossly UVB-induced hyperplasia had thickening of skin of two-three folds increase than normal skin and was examined by hand touching (palpation), with loss of hair in some regions particularly for those cases that had moderate and severe lesions [Figures 5a-c]. Microscopical examination showed increase number of epidermal layers and were classified according to the number of layers which led to thickening of the entire epidermis and regarded as; mild = 4-6 layers, moderate = 7-9 layers, severe = > 10 layers [Figures 5d-g]. In 15 cases of treatment group, 9 cases showed mild hyperplasia, 3 moderate hyperplasia, and 3 cases showed severe hyperplasia and in one of them acanthotic SK was observed. Epidermis also contained cells with basophilic nuclei and eosinophilic cytoplasm and regarded as SBCs or apoptotic bodies. The dermis showed decreasing number of inflammatory mast cells in comparison to exposure group [Figures 6a and b].

#### Total number of apoptotic bodies in 10 high power fields

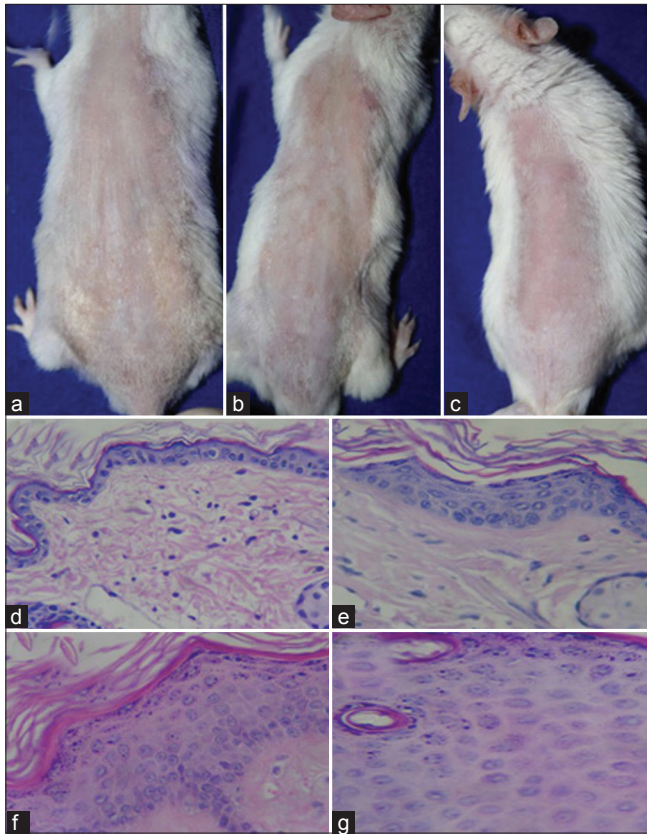
In the present study, the results revealed that there



**Figure 3:** (a) Epidermis contained cells with basophilic nuclei and eosinophilic cytoplasm and regarded as sunburn cells (SBCs) or apoptotic bodies (white arrows), (b) Severe dermal inflammation (H and E,  $\times 400$ )



**Figure 4:** (a) Dermal mast cells (H and E  $\times 400$ ), (b) Dermal mast cells (Giemsa stain,  $\times 400$ )

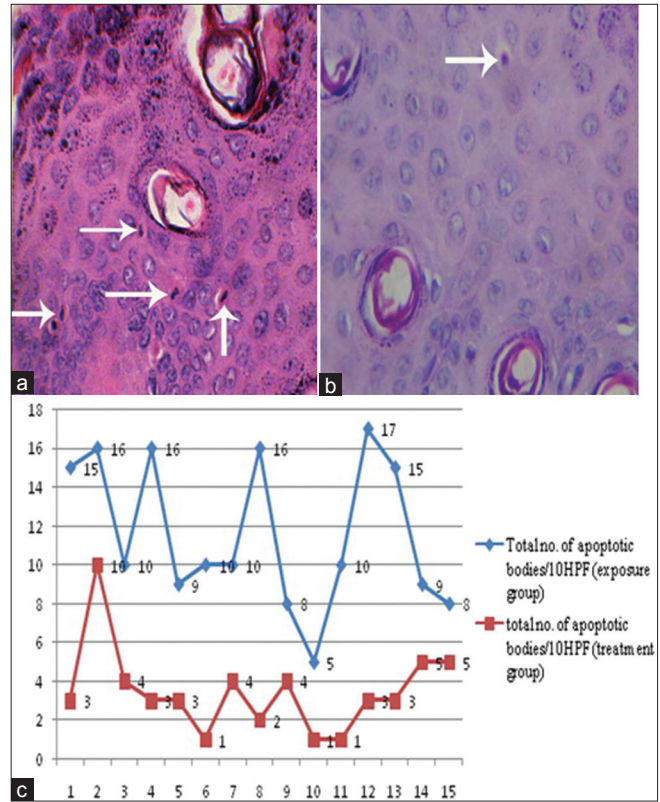


**Figure 5:** (a) Thin skin appeared as normal, while in (b) and (c) 2-3 folds skin thickness was felt through palpation, (d) Normal epidermis (2-3 layers), (e) Mild epidermal hyperplasia of 4-6 layers, (f) Moderate epidermal hyperplasia of 7-9 layers and (g) Severe epidermal hyperplasia more than 10 layers (H and E,  $\times 100$ )

was a strong effect of antioxidants in reducing the effect of chronic UVB irradiation of tumor development in treatment group by decreasing the numbers of cell damage. Thus, the apoptotic bodies were decreased with a range of 1-10/10 HPFs and mean number of 3.467/10 HPFs, while apoptotic bodies were increased in exposure group with a range of 5-17/10 HPFs and mean number of 11.6/10HPFs [Figures 6a-c], with a *P*-value of 0.0001 (according to F test), which indicated a highly significant difference of both groups, in mean number of apoptotic bodies and its role in reducing tumor development by antioxidants administration in treatment group and enhanced tumor development due to effect of chronic UVB irradiation in exposure group. Interestingly, the apoptotic bodies were highly expressed in areas of squamous differentiation of irritated SK but only slightly increased in other variants.

**Mean number of mast cells in 1 high power field**

When mast cells in 10 HPFs were counted in upper dermis in each case of exposure and treatment group, the results revealed that there was a strong effect of antioxidants in reducing the effect of chronic UVB irradiation in treatment group by decreasing number



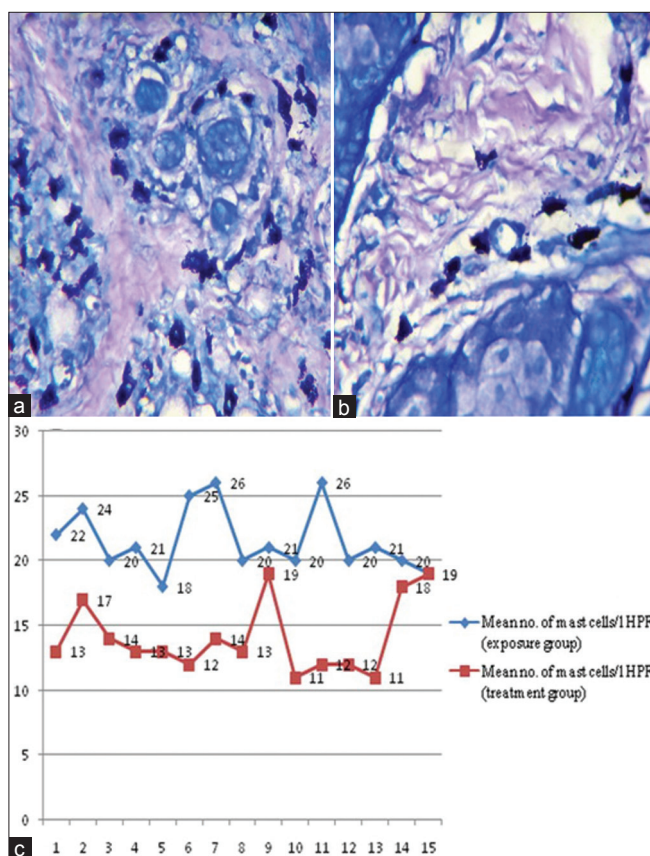
**Figure 6:** (a) Apoptotic bodies in exposure groups -White arrows-, (b) Apoptotic bodies in treated groups -White arrow- (H and E stain,  $\times 400$ ), (c) Line chart showing the total number of apoptotic bodies of both exposure and treatment groups

of mast cells and UVB enhancing immunosuppression by increasing number of mast cells in exposure group [Figures 7a and b]. For example, mast cells number was decreased in treatment group with a range of 11-19/1 HPF and a mean number of 14.067/1 HPF, while mast cells increased in exposure group with a range of 18-26/1 HPF and mean number of 21.533/1 HPF, with a *P*-value of 0.0001 (according to F test), which indicated a highly significant effect of antioxidants in reducing mast cells and UVB increased mast cells for exposure group [Figure 7c].

**Results of immunohistochemical scoring of EGFR expression**

Immunohistochemical staining of EGFR in exposure and treatment groups showed membranous stain accumulation of EGFR protein and recognized as brown discoloration of the keratinocytes membrane. The EGFR protein expression was classified into 4 point-scales: 0; no staining, 1+; <25% positive cells for weak staining, 2+; 26-50% positive cells for moderate staining, 3+; >50% positive cells for strong staining [Figures 8a-d]. Results showed a remarkable effect of UVB in the exposure group because the treated group was partially protected by antioxidants as shown in Table 1. This proved that antioxidants had





**Figure 7:** Differences in the number of mast cells between two different fields, (a) exposure group (b) treatment group (Giemsa stain,  $\times 400$ ), (c) Line chart showing difference in mean number of mast cells in exposure and treatment groups

**Table 1: Scores of EGFR protein expression in both exposure group and treatment groups**

Groups	Score 0	Score 1	Score 2	Score 3
Exposure group	0	0	7	8
Treatment group	6	3	6	

a highly effective role in reducing EGFR expression and reducing the effect of chronic UVB irradiation in the treatment group, while in the exposure group the EGFR expression was increased by UVB irradiation [Figure 8e].

#### Results of total antioxidant status measurement

Results revealed that there was a strong effect of antioxidants on TAS, which acted to reduce the effect of chronic UVB irradiation in treatment group, while in exposure group TAS was decreased due to the effect of chronic UVB irradiation. TAS mean value in control group was equal to 1.201mmol/l, which was used for comparison between exposure and treatment group [Figures 9a and b] with a  $P$ -value of 0.0001 (according to F test), thus indicating a highly significant difference between TAS value in exposure group and TAS value in control group, while there

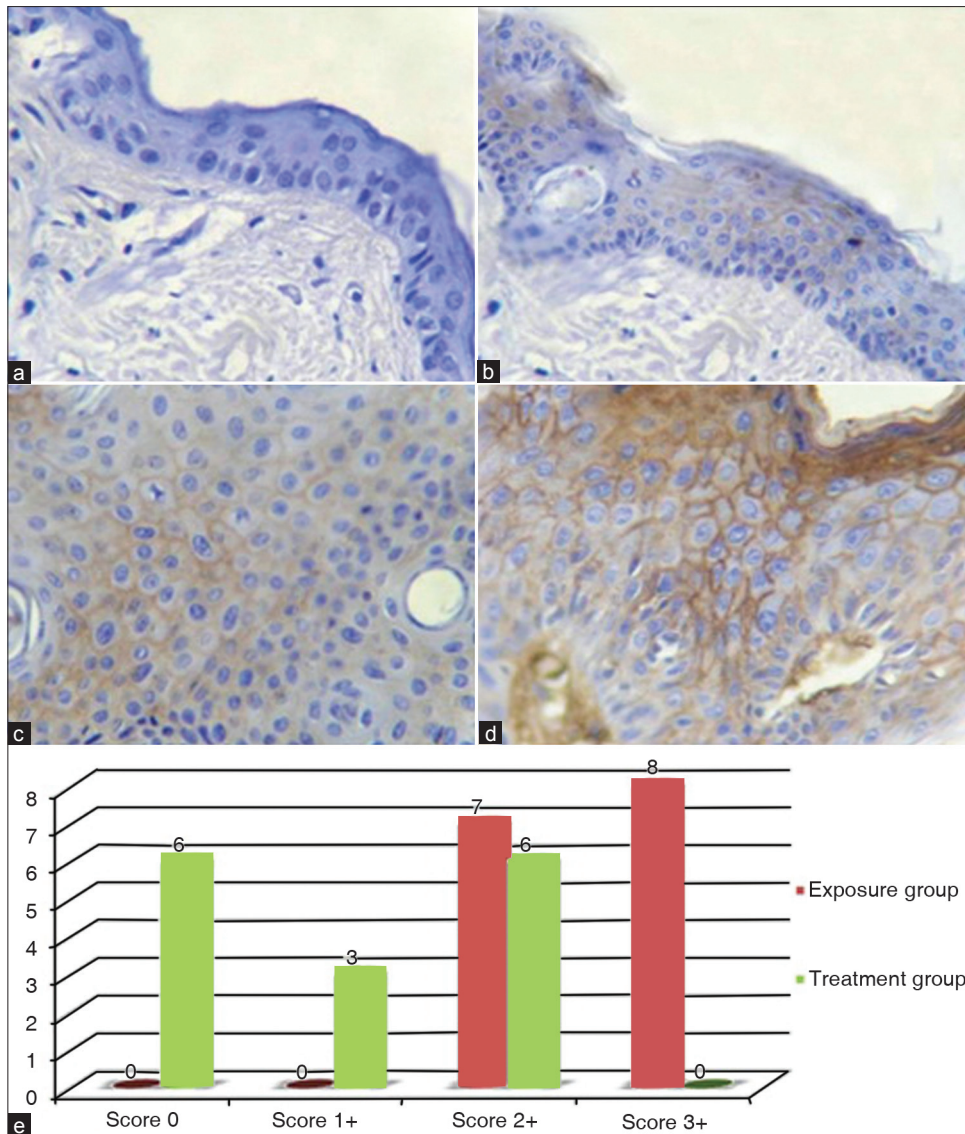
was no significant difference between TAS value in the treatment and control groups.

## DISCUSSION

One significant finding of this study showed that a highly significant association between chronic UVB irradiation and development of Seborrheic Keratosis (SK) in exposure group, which probably indicated that UVB with a long duration and low power initiated and promoted tumor growth and probably was a factor to induce benign SK. This however is in disagreement with previous studies in which they described the etiology of SK as unknown,<sup>[17-20]</sup> but it is in agreement with Haw *et al.*<sup>[21]</sup> This study was the only research on UVB as a causative agent in inducing SK. Therefore, our study was totally new in proving that UVB was an etiological factor in development of SK in mice. In our research work, EGFR expression increased in SK by chronic UVB irradiation in exposure group and this meant that EGFR had an important role in promoting SK development after initiation by UVB irradiation, which is in agreement with Cheng *et al.*<sup>[22]</sup>

Apoptosis was highly expressed in the areas of squamous differentiation of irritated SK, but only mildly increased in the other varieties of SK. These data support the hypothesis that apoptosis has a role in the squamous differentiation of irritated SK as studied by Pesce and Scalora.<sup>[23]</sup> In other studies a moderate increase was observed in the rates of apoptosis in all varieties of SK compared to normal skin<sup>[24]</sup> and rates of apoptosis in SK were not significantly different from normal skin.<sup>[25]</sup> Our findings revealed that apoptosis was increased in numbers in SK. This finding is in agreement with two previous researches<sup>[23,24]</sup> and is in disagreement with Bowen *et al.*<sup>[25]</sup> This finding is due to the generation of excess levels of ROS, which is important for activation of internal cell programs for cell suicide (apoptosis) that are important protection mechanisms that kill cancer cells.<sup>[26,27]</sup>

Mast cells have been found to play a critical role in the suppression of immune reactions, which is not only producing inhibitory cytokines. Thus, mast cell infiltration into tumor may possibly Remodel tumor microenvironment and profoundly influence tumor behaviour by participating and regulating inflammatory and immune reactions. However, although some studies have shown that mast cells promote tumor angiogenesis and tumor growth because of their properties as inflammatory cells, the roles of mast cells in tumor progression have been incompletely understood so far.<sup>[28-30]</sup> In this study we

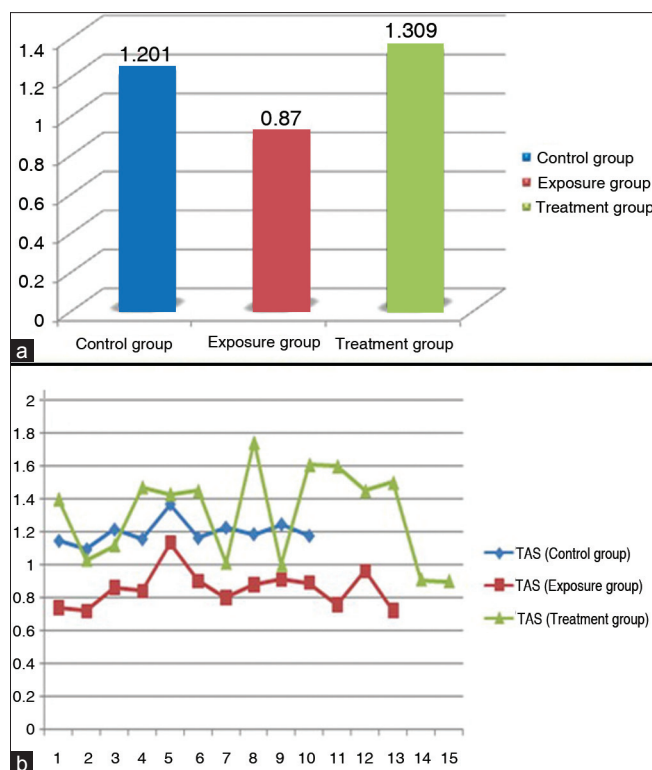


**Figure 8:** EGFR scores. (a) Score 0, (b) Score 1+, (c) Score 2+ and (d) Score + (x400), (e) Column chart showing the effects of UVB on frequencies of EGFR expression scores in exposure group and treatment group

revealed that there was increase mast cell number in exposure group due to the effect of chronic UVB radiation and this is in agreement with Kligman and Murphy, Chacón-Salinas *et al.*<sup>[31,32]</sup> This is an indicator to a great functional link between UVB-induced immunosuppression and the development of at least some forms of skin tumors.<sup>[33]</sup> UVB enhanced increase number of mast cells and development of SK in all mice in exposure group and this indicated a strong relationship between mast cells and SK development. No previous studies have mentioned increasing number of mast cells in SK in humans.

Total antioxidant status was measured in all groups and revealed that TAS values were decreased in exposure group, which was due to increased generation of free radicals and decreased antioxidant level in

the body and as a result SK was developed. This finding is in agreement with previous studies in which antioxidant molecules in the skin interact with ROS or their by-products to either eliminate them or to minimize their deleterious effects.<sup>[11,34-36]</sup> while in treatment group TAS level measurements in most cases were within normal range, which meant that administration of antioxidants reduced the effects of chronic UVB irradiation by neutralization of generated free radicals and antioxidants also reduced the development of SK (1 case out of 15). This meant supplementation of skin with antioxidants may compensate for UV radiation induced depletion and thereby preventing free radical damage. No previous studies mentioned anything about TAS analysis in mice and the effect of antioxidants on SK and up to our knowledge this study was first of its kind



**Figure 9:** (a) Difference of TAS mean values among different groups. (b) TAS value for each case within control, exposure and treatment groups

**Table 2: Pearson’s correlation between total antioxidant status and EGFR scores in treatment group**

Pearson’s correlation	Treatment group
TAS	1.00
Scores for EGFR expression	-0.790**

\*\*Correlation is significant at the 0.01 level (2-tailed)

**Table 3: Correlation between mast cells and apoptotic bodies in exposure group to mast cells and apoptotic bodies in treatment group**

Pearson’s correlation	Exposure group		Treatment group	
	Mast cells-exposure	Apoptotic bodies-exposure	Mast cells-treatment	Apoptotic bodies-treatment
Mast cells-exposure	1.00			
Apoptotic bodies-exposure	0.08	1.00		
Mast cells-treatment	-0.18	-0.25	1.00	
Apoptotic bodies-treatment	0.00	0.22	0.672**	1.00

\*\*Correlation is significant at the 0.01 level (2-tailed)

that showed the role of antioxidants in reducing SK development in mice. Vitamin E and selenium were effective in reducing tumor development in treatment group and showed reduction of activation of EGFR by antioxidants, reduced apoptosis and reduced mast cell

infiltration, which played a role in tumorigenesis. This is in agreement with other published studies.<sup>[37-41]</sup> This study showed a highly significant correlation between TAS and EGFR expression (according to Pearson test) as shown in Table 2. No studies mentioned any clue about effect of antioxidants (Vitamin E and Selenium) on SK development and thus our result was the first to show such a finding.

The decreased number of apoptotic bodies in treatment group was due to the action of antioxidants when compared to exposure group and showed a highly significant relationship ( $P = 0.0001$ ) with associated decline in tumor development. Decreased number of apoptotic bodies was one of antioxidants effect which also reduced tumorigenesis in treatment group despite chronic UVB irradiation. In this study, antioxidants reduced apoptosis and this is in agreement with previous published studies,<sup>[26,27,41-43]</sup> and up to our humble knowledge no previous studies had ever published or documented the effect of antioxidants on apoptotic bodies in SK.

A highly significant effect of antioxidants in reducing number of inflammatory mast cells was observed in treatment group when compared to exposure group and this was due to the effect of antioxidants against immunosuppression by mast cells in SK development. There was no previous research about the role of antioxidants in decreasing mast cells number and SK development. This present study was first to prove it.

Our study showed that there was a highly significant correlation between mast cells and apoptotic bodies in exposure group. The apoptotic bodies and mast cells were increased, but in treatment group apoptotic bodies and mast cells were decreased ( $P = 0.0001$ ) as shown in Table 3. This was related to effect of antioxidants in treatment group. No previous studies mentioned anything about this correlation, but in this study we succeeded to prove it.

## CONCLUSIONS

UVB seems to be a causative agent which induced SK in mice through generation of ROS and immunosuppression which played a significant role in the pathogenesis of UVB-induced epidermal SK. EGFR expression is related to UVB irradiation in mice and this expression was increased in SK. Antioxidants reduced epidermal changes, tumor development, apoptotic bodies, and mast cell proliferation. TAS measurement was declined in exposure group and administration of antioxidants kept TAS levels measurement within normal range in most cases in treatment group.



## REFERENCES

1. Ichihashi M, Ueda M, Budiayanto A, Bito T, Oka M, Fukunaga M, *et al.* UV-induced skin damage. *Toxicology* 2003;189:21-39.
2. Sluyter R, Halliday GM. Enhanced tumor growth in UV-irradiated skin is associated with an influx of inflammatory cells into the epidermis. *Carcinogenesis* 2000;21:1801-7.
3. Gottipati KR, Poulsen H, Starcher B. Passive cigarette smoke exposure inhibits ultraviolet light B-induced skin tumors in SKH-1 hairless mice by blocking the nuclear factor kappa B signalling pathway. *Exp Dermatol* 2008;17:780-7.
4. Dumaz N, van Kranen HJ, de Vries A, Berg RJ, Wester PW, van Kreijl CF, *et al.* The role of UV-B light in skin carcinogenesis through the analysis of p53 mutations in squamous cell carcinomas of hairless mice. *Carcinogenesis* 1997;18:897-904.
5. El-Abaseri TB, Fuhrman J, Trempus C, Shendrik I, Tennant RW, Hansen LA. Chemoprevention of UV light-induced skin tumorigenesis by inhibition of the epidermal growth factor receptor. *Cancer Res* 2005;65:3958-65.
6. El-Abaseri TB, Putta S, Hansen LA. Ultraviolet irradiation induces keratinocyte proliferation and epidermal hyperplasia through the activation of the epidermal growth factor receptor. *Carcinogenesis* 2006;27 :225-31.
7. Ley RD, Reeve VE. Chemoprevention of ultraviolet radiation-induced skin cancer. *Environ Health Perspect* 1997;105:981-4.
8. Fischer SM, Conti CJ, Viner J, Aldaz CM, Lubet RA. Celecoxib and difluoromethylornithine in combination have strong therapeutic activity against UV-induced skin tumors in mice. *Carcinogenesis* 2003;24:945-52.
9. Svobodová A, Psotová J, Walterová D. Natural phenolics in the prevention of UV-induced skin damage. A review. *Biomed Pap Med Fac Univ Palacky Olomouc Czech Repub.* 2003;147:137-45.
10. El-Abaseri TB, Hansen LA. EGFR activation and ultraviolet light-induced skin carcinogenesis. *J Biomed Biotechnol* 2007;2007:97939.
11. Bickers DR, Athar M. Oxidative stress in the pathogenesis of skin disease. *J Invest Dermatol* 2006;126:2565-75.
12. Devasagayam TP, Tilak JC, Boloor KK, Sane KS, Ghaskadbi SS, Lele RD. Free radicals and antioxidants in human health: Current status and future prospects. *J Assoc Physicians India* 2004;52:794-804.
13. Ramoutar RR, Brumaghim JL. Antioxidant and anticancer properties and mechanisms of inorganic selenium, oxo-sulfur, and oxo-selenium compounds. *Cell Biochem Biophys* 2010;58:1-23.
14. Kwak HK, Yoon S. Relation of serum total antioxidant status with metabolic risk factors in Korean adults. *Nutr Res Pract* 2007;1:335-40.
15. Schipping W, Dandachi N, Regitnig P, Hofmann G, Balic M, Neumann R, *et al.* The predictive value of EGFR and HER-2/neu in tumor tissue and serum for response to anthracycline-based neoadjuvant chemotherapy of breast cancer. *Am J Clin Pathol* 2007;128:630-7.
16. Gamboa-Dominguez A, Dominguez-Fonseca C, Quintanilla-Martinez L, Reyes-Gutierrez E, Green D, Angeles-Angeles A, *et al.* Epidermal growth factor receptor expression correlates with poor survival in gastric adenocarcinoma from Mexican patients: A multivariate analysis using a standardized immunohistochemical detection system. *Mod Pathol* 2004;17:579-87.
17. Lee ES, Whang MR, Kang WH. Absence of human Papillomavirus DNA in nongenital seborrheic keratosis. *J Korean Med Sci* 2001;16:619-22.
18. Rubin E. *Essential Pathology*. Philadelphia: Lippincott Williams & Wilkins; 2001.
19. Bhuiyan ZH. Seborrheic keratosis: A case report. *ORION Med J* 2007;26:441-2.
20. Rubin R, Strayer DS. *Rubin's Pathology: Clinicopathologic Foundations of medicine*. Baltimore: Lippincott Williams & Wilkins; 2008.
21. Haw S, Lee JW, Shin MK and Kim NI. The effects of poly-gamma glutamic acid on broad band ultraviolet B-induced skin tumors in a mice model. *Korean J Dermatol* 2009;47:1012-8.
22. Cheng LI, Hong Z, Xiao-meiet F, Yan-ping H, Jin-wen L. Expressions of EGF and EGFR in seborrheic keratosis. *J Clin Dermatol* 2001;4:10.
23. Pesce C, Scalora S. Apoptosis in the areas of squamous differentiation of irritated seborrheic keratosis. *J Cutan Pathol* 2000;27:121-3.
24. Balin AK. Seborrheic Keratosis, <http://emedicine.medscape.com/article/1059477-overview>, retrieved 2012.
25. Bowen AR, Hanks AN, Murphy KJ, Florell SR, Grossman D. Proliferation, apoptosis, and survivin expression in keratinocytic neoplasms and hyperplasias. *Am J Dermatopathol* 2004;26:177-81.
26. Weijl NI, Cleton FJ, Osanto S. Free radicals and antioxidants in chemotherapy-induced toxicity. *Cancer Treat Rev* 1997;23:209-40.
27. Kuipers GK, Lafleur MV. Characterization of DNA damage induced by gamma-radiation-derived water radicals, using DNA repair enzymes. *Int J Radiat Biol* 1998;74:511-9.
28. Soucek L, Lawlor ER, Soto D, Shchors K, Swigart LB, Evan GI. Mast cells are required for angiogenesis and macroscopic expansion of Myc-induced pancreatic islet tumors. *Nat Med* 2007;13:1211-8.
29. Starkey JR, Crowle PK, Taubenberger S. Mast cell-deficient W/W<sup>v</sup> mice exhibit a decreased rate of tumour angiogenesis. *Int J Cancer* 1988;42:48-52.
30. Huang B, Lei Z, Zhang GM, Li D, Song C, Li B, *et al.* SCF-mediated mast cell infiltration and activation exacerbate the inflammation and immunosuppression in tumor microenvironment. *Blood* 2008;112:1269-79.
31. Kligman LH, Murphy GF. Ultraviolet B radiation increases hairless mouse mast cells in a dose-dependent manner and alters distribution of UV-induced mast cell growth factor. *Photochem Photobiol* 1996;63:123-7.
32. Chacón-Salinas R, Limón-Flores AY, Chávez-Blanco AD, Gonzalez-Estrada A, Ullrich SE. Mast cell-derived IL-10 suppresses germinal center formation by affecting T follicular helper cell function. *J Immunol* 2011;186:25-31.
33. Hart PH, Grimbaldeston MA, Finlay-Jones JJ. Sunlight, immunosuppression and skin cancer: Role of histamine and mast cells. *Clin Exp Pharmacol Physiol* 2001;28:1-8.
34. Jurkiewicz BA. The role of free radicals, iron, and antioxidants in ultraviolet radiation-induced skin damage. PhD thesis, University of Iowa 1995.
35. Klaunig JE, Xu Y, Isenberg JS, Bachowski S, Kolaja KL, Jiang J, *et al.* The role of oxidative stress in chemical carcinogenesis. *Environ Health Perspect* 1998;106(Suppl 1):289-95.
36. Marlin DJ, Dunnett CE. *Oxidative stress, oxidative damage and antioxidants a beginners guide*. Newmarket, Suffolk, UK: David Marlin Consulting Ltd; 2007.
37. Gensler HL, Magdaleno M. Topical vitamin E inhibition of immunosuppression and tumorigenesis induced by Ultraviolet irradiation. *Nutr Cancer* 1991;15:97-106.
38. Yuen KS, Halliday GM. Alpha-Tocopherol, an inhibitor of epidermal lipid peroxidation, prevents ultraviolet radiation from suppressing the skin immune system. *Photochem Photobiol* 1997;65:587-92.
39. Steenvoorden DP, Beijersbergen van Henegouwen G. Protection against UV-induced systemic immunosuppression in mice by a single topical application of the antioxidant vitamins C and E. *Int J Radiat Biol* 1999;75: 747-55.
40. Burke KE, Clive J, Combs GF jr, Comisso J, Keen CL, Nakamura RM. Effects of topical and oral vitamin E on pigmentation and skin cancer induced by ultraviolet irradiation in Skh: 2 hairless mice. *Nutr Cancer* 2000;38:87-97.
41. Neeraj G, Sharad M, Tejram S, Abhinav M, Suresh V, Rajeev T. Evaluation of anti-apoptotic activity of different dietary antioxidants in renal cell carcinoma against hydrogen peroxide. *Asian Pac J Trop Biomed* 2011;1:57-63.
42. Zeisel SH. Antioxidants suppress apoptosis. *J Nutr* 2004;134:3179S-80S.
43. Blumenthal RD, Lew W, Reising A, Soyne D, Osorio L, Ying Z *et al.* Anti-oxidant vitamins reduce normal tissue toxicity induced by radio-immunotherapy. *Int J Cancer* 2000;86:276-80.

**Source of Support:** Nil, **Conflict of Interest:** None declared.