

# ASCOT: Autologous Bone Marrow Stem Cell Use for Osteoarthritis of the Thumb—First Carpometacarpal Joint

Matthew P. Murphy, MRCSI  
 Christina Buckley, MRCSI, MD  
 Conor Sugrue, MRCSI  
 Emma Carr, MAppSc, CHT  
 Aine O'Reilly, DipCOT  
 Shane O'Neill, ASPS, Dip Hand Surg, FRACS  
 Sean M. Carroll, FRCSI, FRCS, (Plast) MD

**Background:** The first carpometacarpal joint (CMCJ) in the hand is a commonly affected joint by osteoarthritis. It causes significant thumb base pain, limiting functional capacity. Microfracturing and application of autologous stem cells has been performed on large joints such as the knee but has never been evaluated for use in the smaller joints in the hand. Our aim was to determine the potential benefit of microfracturing and autologous bone marrow stem cells for treatment of osteoarthritis of the first CMCJ in the hand.

**Methods:** All inclusion criteria were satisfied. Preoperative assessment by the surgeon, physiotherapist, and occupational therapist was performed. The first CMCJ was microfractured and the Bone Marrow Stem Cells were applied directly. Postoperatively, the patients were followed up for 1 year.

**Results:** Fifteen patients met inclusion criteria; however, 2 patients were excluded due to postoperative cellulitis and diagnosis of De Quervain's tenosynovitis. The mean scores of the 13-patient preoperative and 1 year follow-up assessments are visual analog score at rest of 3.23–1.69 ( $P = 0.0292$ ), visual analog score on activity of 7.92–4.23 ( $P = 0.0019$ ), range of motion 45.77°–55.15° ( $P = 0.0195$ ), thumb opposition score 7.62–9.23 ( $P = 0.0154$ ), Disability of the Arm, Shoulder and Hand score of 51.67–23.08 ( $P = 0.0065$ ). Strength improved insignificantly from 4.7 kg preoperatively to 5.53 kg at 12 months ( $P = 0.1257$ ). All patients had a positive Grind test preoperatively and a negative test after 12 months.

**Conclusions:** This innovative pilot study is a new approach to osteoarthritis of the thumb. (*Plast Reconstr Surg Glob Open* 2017;5:e1486; doi: 10.1097/GOX.0000000000001486; Published online 19 September 2017.)

## INTRODUCTION

### Significance of Osteoarthritis of the Thumb

Musculoskeletal disorders are a significant global health burden.<sup>1</sup> Of these, the most common arthritis, osteoarthritis (OA) afflicts 15% of the adult population with a lifetime risk of 40%.<sup>2</sup> With 26.9 million Americans affected by OA in 2005, this number will likely increase due to our aging population. The joints most affected are hand, knee, and hip.<sup>3</sup> The cost burden of OA has been estimated to be as high as 2.5% of gross domestic product in the

United States.<sup>4</sup> OA can affect any joint; however, it most commonly affects joints of the hand leading to debilitating loss of function.<sup>5</sup> More specifically, OA of the hand is particularly challenging, given the complexity of the joints affected and the small surface area of the joints.<sup>6</sup>

### Management Options

Although aging is a major factor in disease progression, symptomatic OA often is detected clinically once irreversible damage to the hyaline cartilage lining the joints has occurred.<sup>7</sup> Resulting chondral defects have a low propensity to spontaneously heal and as a result may require surgical intervention, as is the case for OA of the first carpometacarpal joint (first CMCJ). First CMCJ OA has the highest association with hand pain of all joints of the hand.<sup>8</sup> Current therapies for first CMCJ include splinting with analgesia, steroid injections, surgical interventions (ligament repair with tendon interposition, implant arthroplasty, trapeziectomy-full/partial, and joint fusion). Although larger joints have been investigated

From the Department of Plastic Surgery, Saint Vincent's University Hospital, Dublin, Ireland.

Received for publication May 23, 2017; accepted July 19, 2017.

Drs. Buckley and Sugrue contributed equally as second authors.

Copyright © 2017 The Authors. Published by Wolters Kluwer Health, Inc. on behalf of The American Society of Plastic Surgeons.

This is an open-access article distributed under the terms of the Creative Commons Attribution-Non Commercial-No Derivatives License 4.0 (CCBY-NC-ND), where it is permissible to download and share the work provided it is properly cited. The work cannot be changed in any way or used commercially without permission from the journal.

DOI: 10.1097/GOX.0000000000001486

**Disclosure:** The authors have no financial interest to declare in relation to the content of this article. The Article Processing Charge was paid for by the authors.

with bone marrow stimulating techniques and stem cell therapies, the smaller, often more disabling OA joints of the hand have not been included in these new therapies.<sup>9</sup>

### Pathology of OA of the Thumb

The first CMCJ is a unique joint affording the early hominid the ability to oppose their thumbs.<sup>10</sup> OA of the first CMCJ is not well understood. Several hypotheses have been developed proposing various reasons behind disease development and progression. Joint laxity, ligamentous injury and degeneration, hormonal influences, and mechanical loading abnormalities have all been suggested as possible causes for disease progression.<sup>11-13</sup> The resulting damage of the articular surface, however, shares a similar characteristic to that of larger joints. However, as mentioned by Ladd et al.,<sup>14</sup> the thumb OA is not well understood and has a complex balance between stability and the unique dexterity afforded by opposition.

### Stem Cell Therapies

Over the last decade, the use of mesenchymal stem cells (MSC) to treat OA has progressed. MSC can be derived from blood, muscle, skin, synovium but most commonly bone marrow and adipose tissue.<sup>15</sup> Pittenger et al.<sup>16</sup> isolated MSC from BMAC in 1999 and since then BMAC has been used to treat chondral defects. MSC are multipotent and can differentiate into bone, cartilage, stromal progenitors.<sup>17</sup> They secrete paracrine factors that reduce inflammation and enhance healing.<sup>18</sup> The application of MSC in knee OA via injection has had an improvement in signs and symptoms of the disease 5 years following injection.<sup>19</sup> A recent meta-analysis has shown that the use of debridement with application of the MSC improved outcomes at 2 years.<sup>20</sup>

The 3 main categories of MSC application to defects include microfracturing (MF), cultured bone marrow stem cells (BMSCs) in scaffolds and the application of BMSC concentrates directly onto the defect.<sup>21,22</sup> MF has been used for the last 20 years to ameliorate the healing response of degenerative cartilage in osteoarthritic joints.<sup>23</sup> Hyaline cartilage lining joints has a low propensity for regeneration. MF is believed to encourage stem cells from the bone marrow to form new fibrocartilage.<sup>24-26</sup> By utilizing MF and adding BMSC to the joint, we believe that there will be an improvement in both function and symptoms of patients suffering from OA of the thumb.

### Hypothesis

We hypothesize that the application of bone marrow-derived stem cells to a micro fractured first CMCJ surface will improve functional and symptomatic control of OA.

## METHODS

### Pilot Study Design

#### Inclusion Criteria

1. Patients had a diagnosis of OA of the hand as per the American College of Rheumatology criteria for classification and reporting of OA of the hand (Table 1).
2. Failed medical intervention including analgesia, splints, and steroid injections.

3. Nota Bene: Patients with bilateral disease would have only 1 side operated on.

#### Exclusion Criteria

1. Previous surgery on the first CMCJ
2. 65 years and younger
3. Other arthritic/rheumatological comorbidities
4. Immunosuppression inc. systemic corticosteroids
5. Antimetabolite medications, for example, methotrexate
6. Stage I and IV OA (very early and very severe OA)
7. Prior surgery or significant trauma in the area (# distal radius)
8. Adjacent tendinopathies (eg., De Quervains)
9. Carpal tunnel syndrome
10. Smoking
11. Diabetes

### Surgical Procedure

The operation was performed under general anesthesia, as a single day case procedure (Fig. 1). All procedures were performed by the lead surgeon. The articular surfaces of the first CMCJ were accessed via an S-shaped incision. Care was taken to protect the superficial radial nerve. The articular surfaces of the first metacarpal and trapezium were exposed. The damaged articular cartilage was debrided by curettage, shaving, and burring and then microfractured using 4 separate drill holes. Isolated bone marrow-derived stem cells (as described below) were then injected into the joint. A layered closure with 3/0 and 4-0 monocryl was performed.

### Postoperative Protocol

All patients were reviewed day 3 postoperatively for wound review and application of a thermoplastic splint (the first CMCJ was immobilized for 2 weeks). Following this, they were placed in a neoprene soft splint for 4 weeks and a gentle mobilization was commenced under the guidance of the hand therapists. Patients were advised not use nonsteroidal anti-inflammatory drugs for 12 weeks following the procedure as these drugs are chondrotoxic. Alternate analgesia was suggested. Follow-up sessions at the hand clinic took place at 6 weeks, 3 months, 6 months, and 1 year.

### Bone Marrow Aspiration

The anterior iliac crest was located. A 2-mm incision in the skin overlying the iliac crest was incised. The trocar was inserted 6 cm into cancellous bone and aspirated. Once aspiration occurred, we continued through 360° at 45° increments and withdrawn 1 cm at a time and aspirated through 360° again in increments of 45°. Once enough bone marrow aspirate was obtained, we removed the trocar. All aspirates were pooled into syringes containing anticoagulant citrate dextrose-A.

### Isolation of Stem Cells: Using Neuro-Technics

#### AutoStemCell Kit

The bone marrow was extracted using the trocar and prepared syringes with anticoagulant: (10% ratio), for example, 1 ml of ACD-A for 10 ml of bone marrow. The

**Table 1. Outline of the Pilot Study Including Preoperative and Postoperative Assessments**

Assessments	Tick
Preoperative assessment (discussion with Mr. Carroll and consent by senior plastic surgeon)	
6 Physio/OT assessments	
Pain (VAS)	
Range of motion test (palmar abduction)	
Function (DASH)	
Strength test (lateral pinch)	
Kapandji opposition score	
Grind test	
Date for surgery arranged	
6 Weeks postoperative (discussion with Mr. Carroll/other plastic surgeon)	
5 Physio/OT assessments	
Pain (VAS at rest and on activity)	
Range of motion test (palmar abduction)	
Function (DASH)	
Strength test (lateral pinch)	
Kapandji opposition score	
Neoprene support removed	
Exercise can now be gradually increased to allow for full use of thumb	
3 months postoperative (discussion with Mr. Carroll/other plastic surgeon)	
5 Physio/OT assessments	
Pain (VAS—at rest and on activity)	
Range of motion test (palmar abduction)	
Function (DASH)	
Strength test (lateral pinch)	
Kapandji opposition score	
6 months postoperative (discussion with Mr. Carroll/other plastic surgeon)	
6 Physio/OT assessments	
Pain (VAS—at rest and on activity)	
Range of motion test (palmar abduction)	
Function (DASH)	
Strength test (lateral pinch)	
Kapandji opposition score	
Grind test	
12 months postoperative (discussion with Mr. Carroll/other plastic surgeon)	
6 Physio/OT assessments	
Pain (VAS—at rest and on activity)	
Range of motion test (palmar abduction)	
Function (DASH)	
Strength test (lateral pinch)	
Kapandji opposition score	
Grind test	

mix was then added into the separation kit. The granulation level was adjusted depending on the volume of sample taken to the correct granulated level.

### Centrifugation

Before each centrifugation (total = 2), the sample was correctly counter balanced with sample weights. After 2 centrifugations, the sample was split into 3 colored layers. (plasma, buffy coat/platelets and red blood cells). The buffy layer rich in BMSC was extracted and mixed with Tisseel. The ratio depended on the surface area needed to cover. The Tisseel acted as an adhesive.

### Application

The surgical field was prepared. An incision was made over first CMCJ under traction. The diseased cartilage was debrided and microfractured articular surface. The BMSC and Tisseel was applied, and the surgical site was closed in layers.

### Outcome Quantification

Postoperative outcomes were assessed by a single hand therapy team in a single unit (Fig. 2). Patients attended postoperative hand clinic and were assessed by the hand surgeon and hand therapists (including an occupational therapist and physiotherapist). Interobserver variability was reduced by ensuring that the same hand therapist followed up each patient.

Before commencing the trial, it was determined that patient outcomes should include a visual analog score (VAS) for pain at rest and after activity, assessment of range of motion (ROM) for palmar abduction, a functional score using the Disability of the Arm, Shoulder and Hand (DASH) scoring system, an assessment of strength test using the lateral pinch test, an assessment of opposition using the Kapandji opposition score and finally an assessment of clinical CMCJ arthritis using the Grind Test. Table 1 shows the timing of each test performed.

### Statistical Analysis

A paired *t* test was used to determine statistical significance. GraphPad Prism 7 Software was used.

### Ethical Approval

The pilot study was reviewed and approved by the Ethical Committee of St Vincent's University Hospital Dublin. The pilot study was reviewed by the Irish Medicines Board and was approved for use.

## RESULTS

Fifteen patients were included in the trial. Two patients were excluded due to cellulitis and development of De Quervain's tenosynovitis. Thirteen met inclusion criteria with an average age of 58.92 years. Of the 13 patients, 2 were male and 11 were female. Twelve were right hand dominant. Seven patients had their dominant thumb operated. All patients were employed in professions requiring manual dexterity. All patients were assessed at regular intervals (Table 1). Results at 12 months postoperatively were used to assess the efficacy of the procedure (Fig. 2).

### VAS (Rest/Activity)

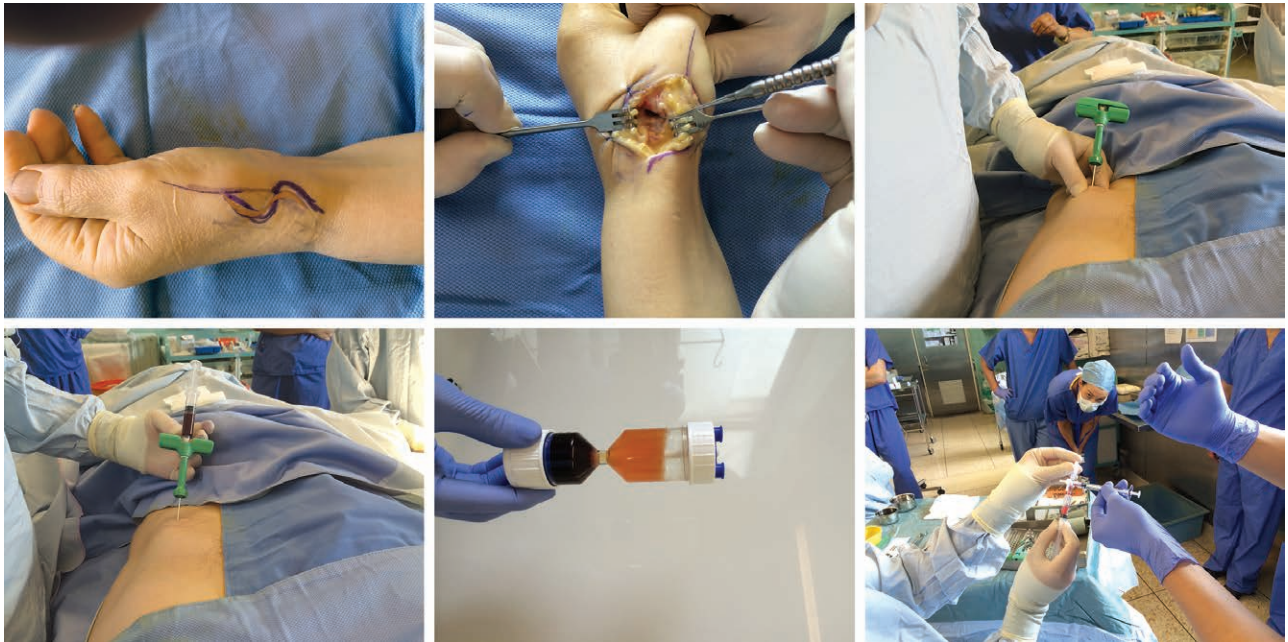
A statistically significant improvement in pain both at rest and after activity was seen. VAS at rest preoperatively was 3.23 improving to 1.69 after 12 months ( $P = 0.0292$ ). VAS on activity preoperatively was 7.92 improving to 4.23 after 12 months ( $P = 0.0019$ ).

### Range of Motion

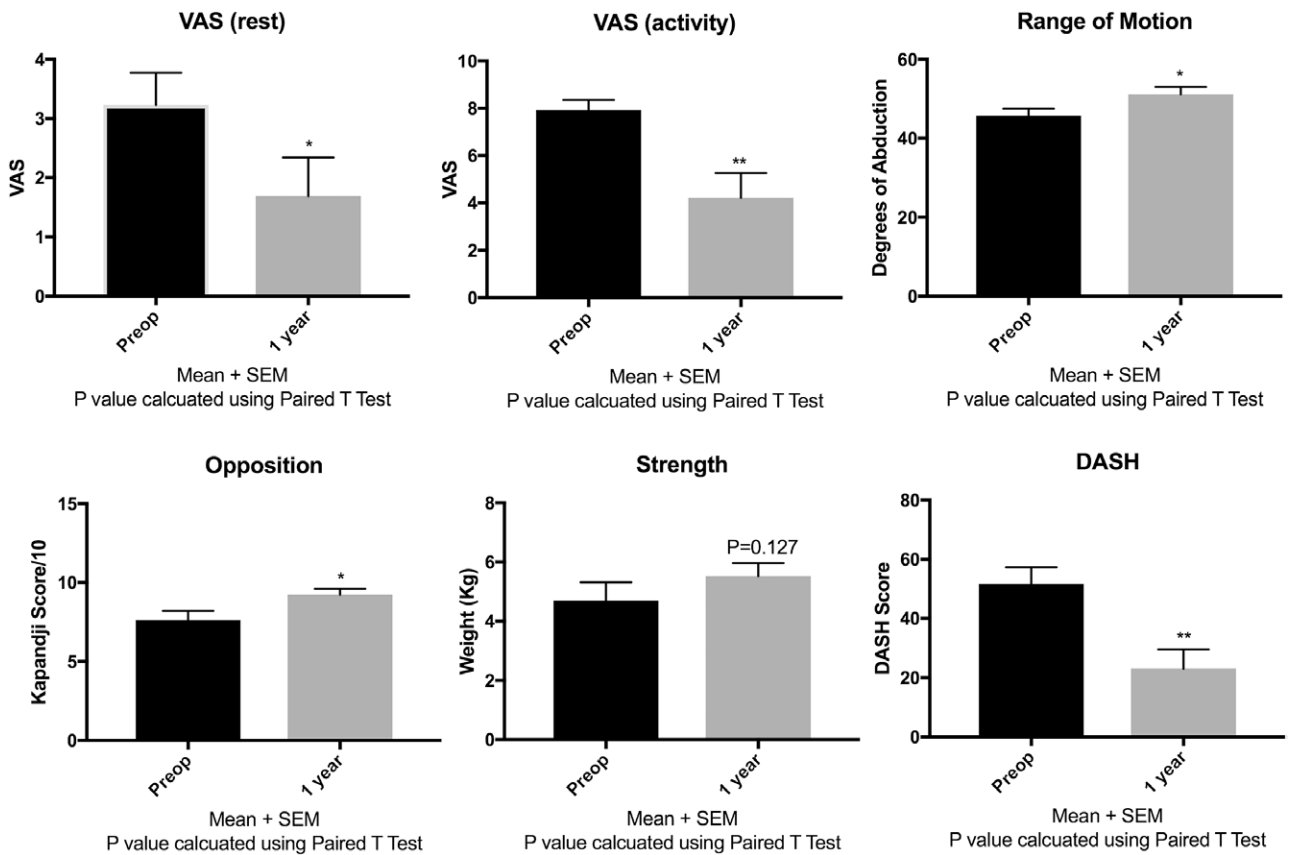
The range of motion in abduction of the thumb improved significantly from 45.77° preoperatively to 55.15° at 12 months postoperatively ( $P = 0.0195$ ).

### Thumb Opposition

Kapandji score improved significantly from 7.62/10 preoperatively to 9.23/10 at 12 months postoperatively ( $P = 0.0154$ ).



**Fig. 1.** A, S-shaped incision over first CMCJ of the thumb. B, Accessing the joint surface and debridement of the diseased joint surface. C, Trocar used to aspirate the bone marrow from the iliac crest. D, Bone marrow aspirate shown in syringe. E, Three layers after first centrifugation. F, Mixing of bone marrow aspirate with Tisseel glue. G, Application of mix to joint surface.



**Fig. 2.** A–F, Graphs showing statistically significant improvements in VAS at rest and after activity, ROM, opposition and function (DASH score). N = 13. \*P < 0.05; \*\*P < 0.01. P value calculated using paired t test. ROM, range of motion.

**Strength**

Strength assessed with pinch test improved insignificantly from 4.7 kg preoperatively to 5.53 kg at 12 months postoperatively ( $P = 0.1257$ ).

**DASH**

Functionality of the hand improved significantly with a preoperative DASH score of 51.69 improving to 23.08 at 12 months postoperatively ( $P = 0.0065$ ).

**Grind Test**

All patients had a positive grind test preoperatively and a negative grind test at 12 months postoperatively. Individual scores for each patient (preoperative and 1 year time-points) can be seen in Table 2.

**DISCUSSION**

MF and the application BMSC to an injured joint surface has been shown to improve functional outcomes in OA of larger joints.<sup>19</sup> Histological and radiological outcomes in animal studies have been used as the basis of our understanding in both techniques in joint resurfacing.<sup>22,27</sup> Although most of these animal and human studies have investigated the effects of MF and application of BMSC to large joints such as the knee, none have looked at these techniques in the smaller, often more debilitating joints of the hand.

Our findings of improved symptomatic relief and improved functionality of the joint mimic similar clinical trials in both the hip and the knee.<sup>28,29</sup> Although little is known about the exact effects of MF on the native skeletal stem cell population, it is believed that MF may activate a population of resident skeletal stem cells from the underlying subchondral bone marrow. This “activation” of skeletal stem cell progenitor populations is seen after bone injury in the mouse model.<sup>30</sup>

The recent identification and characterization of mouse skeletal stem cells will allow researchers to examine the effects of OA on resident stem cell populations.<sup>31</sup> Clinicians have been using stem cell therapies to assist in tissue regeneration in diseases such as OA. Stem cells with the potential to differentiate into bone and cartilage have been isolated from adipose tissue, bone marrow, and muscle.<sup>32–34</sup> The exact fate of BMSC when used in OA of the knee is not fully understood.<sup>35</sup> The current belief is that via paracrine effects they secrete growth factors that will aid in cartilage regeneration and ameliorate articular repair.<sup>36</sup> BMAC, which contains BMSC, has been shown to have beneficial clinical effects on patients with OA of the knee.<sup>37,38</sup>

We have shown for the first time in this pilot study that the 2 principles of MF and application of BMSC can be used safely in treating OA of the thumb. Although it is a safe procedure without major complications, there is also statistically significant functional and symptomatic relief for the patient. All patients were preoperatively positive for clinical OA of the first CMCJ with a positive Grind test, whereas all patients remained negative for signs of clinical

**Table 2. Table Showing the Raw Data for All 13 Patients Included**

Patient	VAS (Rest)		VAS (Activity)		ROM		Opposition		Strength		DASH		Grind	
	Preoperative	12 mo	Preoperative	12 mo	Preoperative	12 mo	Preoperative	12 mo	Preoperative	12 mo	Preoperative	12 mo	Preoperative	12 mo
1	3	0	7	0	45	60	10	6	6	21	0	Positive	Positive	
2	1	0	8	3	40	50	7	4	3	45	28	Positive	Negative	
3	3	1	8	1	40	60	10	4	7	74	2	Positive	Negative	
4	6	8	10	9	40	50	6	7	8 at 6 mo	50	45 at 6 mo	Positive	Negative	
5	0	0	5	5	55	60	5	5	6	31	25	Negative	Negative	
6	4	0	8	0	50	55	5	2	8 at 6 mo	78	0	Positive	Negative	
7	4	0	9	0	45	50	9	4	6	33	13	Positive	Negative	
8	5	0	9	0	45	50	10	8	8	55	5	Positive	Negative	
9	4	3	9	7	60	55	9	8	7	35	24	Positive	Negative	
10	4	1	10	6	40	45	5	4	5	50	42	Positive	Negative	
11	4	3	8	10	45	40	9	4	5	62	71	Positive	Negative	
12	6	4	8	6	40	40	5	4	Missing	56	52	Positive	Negative	
13	0	2	10	8	50	50	9	2	5	80	15	Positive	Positive	

OA 12 months postoperatively with a ubiquitous negative Grind test.

### LIMITATIONS

Although the pilot study was meticulously implemented and showed promising results, we must now determine the exact effect of the MSC and MF individually to the joint. We are currently implementing ASCOT2 to assess MF + placebo versus MF + BMSC. MF with placebo will act as the control for the experiment.

### CONCLUSIONS

Although microfracturing and application of bone marrow-derived stem cells has been used in treating OA of larger joints in the body such as the knee, this is the first pilot study to perform these procedures on the thumb. This pilot study shows that the effects of MF and application of BMSC to the first CMCJ are positive with improved symptoms and function. This innovative pilot study provides a new therapeutic option to hand surgeons when treating patients with OA of the first CMCJ, providing an exciting new opportunity for plastic surgery within regenerative medicine.<sup>39</sup>

**Matthew P. Murphy, MRCSI**

Department of Plastic Surgery  
St Vincents University Hospital  
Elm Park  
Dublin 4  
Ireland

E-mail: matthew.murphy@ucdconnect.ie

### REFERENCES

- Vos T, Flaxman AD, Naghavi M, et al. Years lived with disability (YLDs) for 1160 sequelae of 289 diseases and injuries 1990–2010: a systematic analysis for the Global Burden of Disease Study 2010. *Lancet*. 2012;380:2163–2196.
- Johnson VL, Hunter DJ. The epidemiology of osteoarthritis. *Best Pract Res Clin Rheumatol*. 2014;28:5–15.
- Lawrence RC, Felson DT, Helmick CG, et al.; National Arthritis Data Workgroup. Estimates of the prevalence of arthritis and other rheumatic conditions in the United States. Part II. *Arthritis Rheum*. 2008;58:26–35.
- March LM, Bachmeier CJ. Economics of osteoarthritis: a global perspective. *Baillieres Clin Rheumatol*. 1997;11:817–834.
- Creamer P, Lethbridge-Cejku M, Hochberg MC. Factors associated with functional impairment in symptomatic knee osteoarthritis. *Rheumatology (Oxford)*. 2000;39:490–496.
- Kloppenborg M, Kwok WY. Hand osteoarthritis—a heterogeneous disorder. *Nat Rev Rheumatol*. 2011;8:22–31.
- Loeser RF, Collins JA, Diekmann BO. Ageing and the pathogenesis of osteoarthritis. *Nat Rev Rheumatol*. 2016;12:412–420.
- Dahaghin S, Bierma-Zeinstra SM, Ginai AZ, et al. Prevalence and pattern of radiographic hand osteoarthritis and association with pain and disability (the Rotterdam study). *Ann Rheum Dis*. 2005;64:682–687.
- Berger AJ, Meals RA. Management of osteoarthrosis of the thumb joints. *J Hand Surg Am*. 2015;40:843–850.
- Ladd AL. Upper-limb evolution and development: skeletons in the closet. Congenital anomalies and evolution's template. *J Bone Joint Surg Am*. 2009;91:19–25.
- Zancolli EA, Zadenberg C, Zancolli E, Jr. Biomechanics of the trapeziometacarpal joint. *Clin Orthop Relat Res*. 1987;220:14–26.
- Zhang AY, Van Nortwick S, Hagert E, et al. Thumb carpometacarpal ligaments inside and out: a comparative study of arthroscopic and gross anatomy from the Robert A. Chase hand and upper limb center at Stanford University. *J Wrist Surg*. 2013;2:55–62.
- Pellegrini VD, Jr. The ABJS 2005 Nicolas Andry Award: osteoarthritis and injury at the base of the human thumb: survival of the fittest? *Clin Orthop Relat Res*. 2005;438:266–276.
- Ladd AL, Crisco JJ, Hagert E, et al. The 2014 ABJS Nicolas Andry Award: the puzzle of the thumb: mobility, stability, and demands in opposition. *Clin Orthop Relat Res*. 2014;472:3605–3622.
- Phinney DG, Prockop DJ. Concise review: mesenchymal stem/multipotent stromal cells: the state of transdifferentiation and modes of tissue repair—current views. *Stem Cells*. 2007;25:2896–2902.
- Pittenger MF, Mackay AM, Beck SC, et al. Multilineage potential of adult human mesenchymal stem cells. *Science*. 1999;284:143–147.
- Oreffo RO, Cooper C, Mason C, et al. Mesenchymal stem cells: lineage, plasticity, and skeletal therapeutic potential. *Stem Cell Rev*. 2005;1:169–178.
- Barry F, Murphy M. Mesenchymal stem cells in joint disease and repair. *Nat Rev Rheumatol*. 2013;9:584–594.
- Davatchi F, Sadeghi Abdollahi B, Mohyeddin M, et al. Mesenchymal stem cell therapy for knee osteoarthritis: 5 years follow-up of three patients. *Int J Rheum Dis*. 2016;19:219–225.
- Cui GH, Wang YY, Li CJ, et al. Efficacy of mesenchymal stem cells in treating patients with osteoarthritis of the knee: a meta-analysis. *Exp Ther Med*. 2016;12:3390–3400.
- Kristjánsson B, Honsawek S. Current perspectives in mesenchymal stem cell therapies for osteoarthritis. *Stem Cells Int*. 2014;2014:194318.
- Wei B, Jin C, Xu Y, et al. Chondrogenic differentiation of marrow clots after microfracture with BMSC-derived ECM scaffold *in vitro*. *Tissue Eng Part A*. 2014;20:2646–2655.
- Steadman JR, Rodkey WG, Briggs KK, et al. [The microfracture technique in the management of complete cartilage defects in the knee joint]. *Orthopade*. 1999;28:26–32.
- Chen H, Sun J, Hoemann CD, et al. Drilling and microfracture lead to different bone structure and necrosis during bone-marrow stimulation for cartilage repair. *J Orthop Res*. 2009;27:1432–1438.
- Jakobsen RB, Engebretsen L, Slaughterbeck JR. An analysis of the quality of cartilage repair studies. *J Bone Joint Surg Am*. 2005;87:2232–2239.
- Mithoefer K, McAdams T, Williams RJ, et al. Clinical efficacy of the microfracture technique for articular cartilage repair in the knee: an evidence-based systematic analysis. *Am J Sports Med*. 2009;37:2053–2063.
- Ceylan HH, Bilsel K, Buyukpinarbasili N, et al. Can chondral healing be improved following microfracture? The effect of adipocyte tissue derived stem cell therapy. *Knee*. 2016;23:442–449.
- Nguyen PD, Tran TD, Nguyen HT, et al. Comparative clinical observation of arthroscopic microfracture in the presence and absence of a stromal vascular fraction injection for osteoarthritis. *Stem Cells Transl Med*. 2017;6:187–195.
- MacDonald AE, Bedi A, Horner NS, et al. Indications and outcomes for microfracture as an adjunct to hip arthroscopy for treatment of chondral defects in patients with femoroacetabular impingement: a systematic review. *Arthroscopy*. 2016;32:190–200.e2.
- Marecic O, Tevlin R, McArdle A, et al. Identification and characterization of an injury-induced skeletal progenitor. *Proc Natl Acad Sci U S A*. 2015;112:9920–9925.
- Chan CK, Seo EY, Chen JY, et al. Identification and specification of the mouse skeletal stem cell. *Cell*. 2015;160:285–298.
- Bianco P, Robey PG. Skeletal stem cells. *Development*. 2015;142:1023–1027.

33. Gao X, Usas A, Lu A, et al. BMP2 is superior to BMP4 for promoting human muscle-derived stem cell-mediated bone regeneration in a critical-sized calvarial defect model. *Cell Transplant*. 2013;22:2393–2408.
34. Levi B, Nelson ER, Li S, et al. Dura mater stimulates human adipose-derived stromal cells to undergo bone formation in mouse calvarial defects. *Stem Cells*. 2011;29:1241–1255.
35. Pas HI, Winters M, Haisma HJ, et al. Stem cell injections in knee osteoarthritis: a systematic review of the literature. *Br J Sports Med*. 2017;51:1125–1133.
36. Holton J, Imam M, Ward J, et al. The basic science of bone marrow aspirate concentrate in chondral injuries. *Orthop Rev (Pavia)*. 2016;8:6659.
37. Kim JD, Lee GW, Jung GH, et al. Clinical outcome of autologous bone marrow aspirates concentrate (BMAC) injection in degenerative arthritis of the knee. *Eur J Orthop Surg Traumatol*. 2014;24:1505–1511.
38. Martin DR, Cox NR, Hathcock TL, et al. Isolation and characterization of multipotential mesenchymal stem cells from feline bone marrow. *Exp Hematol*. 2002;30:879–886.
39. D'Amico RA, Rubin JP, Neumeister MW, et al.; American Society of Plastic Surgeons/Plastic Surgery Foundation Regenerative Medicine Task Force. A report of the ASPS Task Force on regenerative medicine: opportunities for plastic surgery. *Plast Reconstr Surg*. 2013;131:393–399.