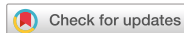

## Review Article



# Buerger's Disease May be a Chronic Rickettsial Infection with Superimposed Thrombosis: Literature Review and Efficacy of Doxycycline in Three Patients

Moon-Hyun Chung <sup>1</sup>, Jin-Soo Lee <sup>2</sup>, and Jae-Seung Kang <sup>3</sup>

<sup>1</sup>Division of Infectious Diseases, Department of Internal Medicine, Seogwipo Medical Center, Jeju, Korea

<sup>2</sup>Division of Infectious Diseases, Department of Internal Medicine, Inha University, Incheon, Korea

<sup>3</sup>Department of Microbiology, Inha University, Incheon, Korea

## OPEN ACCESS

Received: Dec 30, 2021

Accepted: Feb 26, 2022

Published online: Mar 13, 2022

### Corresponding Author:

Jae-Seung Kang, MD

Department of Microbiology, Inha University  
College of Medicine, 100 Inha-ro, Michuhol-gu,  
Incheon 22212, Korea.

Tel: +82-32-860-9821


Email: jaeskang@inha.ac.kr

Most parts of the article were presented at the Annual Conference of the Korean Society for Antimicrobial Therapy, held in 2018.


Copyright © 2022 by The Korean Society of Infectious Diseases, Korean Society for Antimicrobial Therapy, and The Korean Society for AIDS

This is an Open Access article distributed under the terms of the Creative Commons Attribution Non-Commercial License (<https://creativecommons.org/licenses/by-nc/4.0/>) which permits unrestricted non-commercial use, distribution, and reproduction in any medium, provided the original work is properly cited.


### ORCID iDs

Moon-Hyun Chung 

<https://orcid.org/0000-0003-2905-3459>

Jin-Soo Lee 

<https://orcid.org/0000-0001-7862-5519>

Jae-Seung Kang 

<https://orcid.org/0000-0003-2730-3709>

## ABSTRACT

Buerger's disease (BD) is a chronic inflammatory vasculitis of unknown etiology. The infectious etiology of BD was proposed by Buerger in 1914. Furthermore, there are scattered reports insisting that BD may be related to rickettsial infection, first asserted by Goodman since 1916, followed by Giroud and other French investigators from the 1940s through the 1960s, Nicolau in the 1960s, Bartolo (1980s), and Fazeli (2010s). However, their causal relationship has hardly been accepted because rickettsial infections are known to be acute febrile, vector-borne illnesses, whereas BD is a chronic afebrile illness. In this article we review the relevant literature on the chronic nature of *Rickettsia* and *Orientia* infections and on the rickettsial etiology of BD. Excellent initial responses to doxycycline in three patients with BD are briefly described. Based on these findings, we hypothesize that BD patients acquired a rickettsial infection far before the onset of BD. Over years, the infected area expands to become a segment of the infected vessel. Subsequently, thrombus develops on the luminal surface of the infected endothelial cells, which produces the vascular obstructive manifestations of BD. Collectively, it is postulated that BD is a chronic infection with a member of the family *Rickettsiaceae* with superimposed thrombosis.

**Keywords:** Buerger's disease; *Orientia tsutsugamushi*; Rickettsia; Thromboangiitis obliterans; Thrombosis

## OVERVIEW OF BUERGER'S DISEASE

Buerger's disease (BD), or thromboangiitis obliterans, is an occlusive vascular disease that usually affects small- and medium-sized blood vessels of the upper and lower extremities [1-3]. Minute vessels like the vasa vasorum and vasa nervorum are also involved. Pathologically, the vessels are occluded by highly cellular thrombi. The vessel wall, particularly the intima, and perivascular space are infiltrated by inflammatory cells. The internal elastic lamina and all three layers of the vessel walls are relatively well preserved in contrast to arteriosclerosis obliterans [4, 5]. The immunophenotypes of the infiltrating cells in the intima include CD3<sup>+</sup>

**Funding**

None.

**Conflict of Interest**

No conflict of interest.

**Author Contributions**

Conceptualization: MHC, JSL, JSK. Data curation: MHC, JSL. Investigation: MHC, JSL, JSK. Methodology: JSL, JSK. Project administration: MHC. Resources: MHC. Supervision: JSK. Validation: MHC. Visualization: JSL, JSK. Writing - original draft: JSL, MHC. Writing - review & editing: MHC, JSK.

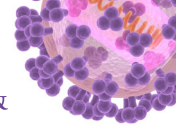
T lymphocytes (pan-T cells), of which CD8<sup>+</sup> (cytotoxic/suppressor) and CD4<sup>+</sup> (helper) T cells are observed. CD20<sup>+</sup> lymphocytes (pan-B cells) are also noticed but fewer than T cells. CD68<sup>+</sup> monocytes/macrophages, mostly S-100<sup>+</sup> dendritic cells, are present in the thrombus and intima [6-8]. Immunoglobulins, complement factors, and T lymphocytes are deposited along the internal elastic lamina [5-7]. From these findings, Kobayashi proposed that BD is an endarteritis that is introduced by T cell-mediated cellular immunity and B cell-mediated humoral immunity associated with the activation of macrophages or dendritic cells in the intima [6]. During the acute phase, infiltration of the inflammatory cells, in addition to disintegrated leukocytes and pyknotic nuclei, is found in the thrombus. Occasionally, “microabscesses” and multinucleated giant cells in the periphery of the thrombus usually adjacent to the inner wall of the vessel are observed, which is a characteristic of BD but is noticed mainly in biopsies or excised tissues of acutely involved superficial veins. Neutrophils are also observed in the media initially, but rarely in the adventitia [3]. Following the acute phase, the occluding thrombus undergoes organization and recanalization. Gradually, the intima is thickened due to endothelial hyperplasia. The internal elastic lamina undergoes undulation and reduplication, and the lumen is occluded by connective tissue and contains several minute blood vessels and sinuses. New vessels develop in the media, and periarterial fibrosis becomes evident. Thus, in its end stage, the vessel changes to a fibrous cord adherent to its surroundings. Because recent articles on the histopathology of BD always examined amputated limbs or digits, the pathognomonic features of the early lesion were uncommonly described. Possibly for this reason, Allen et al. disputed the presence of multinucleated giant cells and infiltration of neutrophils in BD [9]. For the same reason, Kurata et al. described that the early inflammatory stage was rarely observed in clinical specimens (*i.e.*, one of 31 BD patients), and thus this finding was seldom helpful in differentiating BD from arteriosclerotic obliterans and other vascular diseases. They underscored the presence of periarteritis as a key feature for this purpose [10]. Another limitation of the pathological investigations of BD is that specimens submitted for pathological examination always have thrombotic occlusion. Therefore, it is uncertain whether thrombosis is secondary to angiitis, and it is unknown which pathological findings are the result of thrombosis. Atherosclerotic plaque or fibrinoid necrosis is seldom observed in the arterial wall. However, as BD is increasingly diagnosed in elderly patients, atherosclerotic lesions are often observed in these patients [3, 11, 12]. The disease usually originates in the smaller vessels, such as the dorsalis pedis artery; subsequently, it ascends to the arteries above, sometimes with intervening normal segments. Therefore, various stages of occlusion are observed in different segments of the same vessel or in different vessels. Occasionally, a new clot superimposes the original thrombus [3]. Based on the above pathological findings, this illness was named “arteritis obliterans” and “endarteritis obliterans” by Carl Friedländer in 1876 [13], “endarteritis and endophlebitis” by Felix von Winiwarter in 1879 [14], and “thrombo-angiitis obliterans” by Leo Buerger in 1908 [1].

The affected extremities clinically display superficial migratory thrombophlebitis (migrating phlebitis) initially, if present, followed by claudication, rest pain, ischemic ulceration, or gangrene according to the severity of illness, which slowly progresses with a remitting and relapsing course until the sixth decade of life [11]. Migratory thrombophlebitis presents as a tender nodule or a segment of the erythematous cord, and spontaneously resolves to leave a hard fibrous cord. Sometimes it recurs at different sites of the same vein or different veins simultaneously or serially after a variable period. Although it usually presents as an initial clinical manifestation of BD, it also occurs after the development of arterial ischemic symptoms. Infrequently, it is incidentally found on pathological examination in clinically silent veins [3]. Systemic symptoms are usually absent even in the presence of gangrene;

however, mild systemic symptoms may be present during the occurrence of migratory thrombophlebitis [15] and non-erosive inflammatory arthritis sometimes precedes ischemic vascular symptoms [16]. Mortality is very low or absent within the initial few years after onset. For these reasons, autopsy has seldom been performed; therefore, systemic involvement has rarely been investigated. Buerger described four autopsied cases—three deaths due to BD and one accidental death—among 500 patients with BD [3]. A recent review article disclosed that, as the disease progresses, the vessels of other organs, including gastrointestinal, coronary, cerebral, ocular, renal, urogenital, mucocutaneous, articular, lymphohematopoietic, and auricular vessels, are sometimes affected. Multiple organs are often involved concurrently, and the implication of the viscus occasionally precedes the extremity [17], suggesting that BD is a systemic disease [17, 18].

This malady typically affects young to middle-aged men who are current smokers and are heavier in many cases; they started smoking at an earlier age than non-BD smokers. Before the 1930s, BD in the United States occurred most commonly in foreign-born Jews and was rare in non-Jewish immigrants or US-born Jews. Most of them developed BD first after an extended stay in the United States [19]. It was once thought that the incidence of BD in Israel was higher among the Ashkenazim than among non-Ashkenazi Jews; however, it turned out to be an error [20, 21]. BD was thought to be rare in people of African descent [22]; however, it was also identified not to differ from non-African Americans [23]. Although the worldwide occurrence of BD has not been investigated thoroughly, it has been known that this illness is more common in Eastern Europe, Middle East, and the Far East and Southeast Asia. BD seems to aggravate more frequently during the cold season because hospital admissions are more common during the winter months in Iran and Thailand [24, 25], which was also mentioned in China and in the United States in the 1920s [3, 15, 26, 27]. In Thailand, the jobs of BD patients were changed from farmers and fishermen in the past to industrial workers nowadays, which exposed the patients less to coldness and might be the cause of the decrease in BD, whereas the smoking rates have not changed much in the last 20 years [25]. In Indonesia, working with feet immersed in water over long periods of time, namely trench foot, preceded the first attack of BD in 22.0% of the patients [28]. A low socioeconomic status is an important contributing factor for BD in Iran, Nepal, and Indonesia [24, 28, 29, 30], which was also mentioned in Jewish immigrants in the United States in the past and recently in Japan [31, 32]. This condition may be related to poor personal hygiene and body lice (accordingly epidemic typhus), to rural environment or farming (spotted fever rickettsioses or tsutsugamushi disease), to their jobs requiring prolonged standing in cold environments, to exposure to rat fleas (murine typhus and possibly *Rickettsia felis* infection) and house mouse mites (rickettsialpox), or to poor housing and heating systems.

Regarding functional abnormalities in BD, Makita et al. reported that endothelium-dependent vasodilatation of peripheral arteries is impaired in unaffected limbs of BD patients, while nitroprusside, the endothelium-independent vasodilator, produces no difference in responses between the BD group and the control group [33]. Brodmann et al. reported that impaired endothelium-dependent and endothelium-independent vasodilatation are involved in BD [34]. Halacheva et al. reported that the expression of intracellular adhesion molecule-1, vascular cell adhesion molecule-1, and E-selectin is increased in endothelial cells and some mononuclear inflammatory cells in the affected intima in all patients with BD [35]. These results suggest that vascular dysfunction in BD is present in the endothelium of non-affected vessels and that other dysregulation such as non-occluding thrombosis may be superimposed in the vessels, besides endothelial dysfunction.



Although several hypotheses on the cause of BD have been proposed, including tobacco smoking, hypersensitivity to tobacco ingredients, ergotism, immune mechanism, infection, familial or heredity, race, hypercoagulability, endocrine abnormality, exposure to cold, trauma, and stress, its exact etiology is still not yet established [36]. The clinical manifestations of BD improve markedly after smoking cessation; therefore, cigarette smoking has been mentioned as a cause of or an important contributing factor for BD [31]. However, BD sometimes develops in non-smokers [37-39]. Additionally, a nationwide survey in Japan reported that seven of 89 newly registered patients with BD were non-smokers [40]. The incidence of BD in developed countries has markedly decreased, possibly as the smoking rates have reduced; however, the occurrence of BD already decreased before the decline in smoking rates, and the magnitude of the decrease in BD was not parallel to that of smoking rates. For example, Lie reported the hospital data of Mayo Clinic in Rochester, Minnesota, that the percentage of diagnosed BD cases declined from 104.3/100,000 patients in 1947, rapidly in the early 1950s to late 1960s, to 12.6/100,000 patients in 1986 [41, 42], whereas the smoking rates in American men declined from 53.0% in 1950 to 38.0% in 1980 [43]. The mass media campaign on smoking cessation in the United States began in the 1970s [44]. Wessler et al. at Beth Israel Hospital in New York in 1960 and Eisen at Mount Sinai Hospital in New York in 1966 mentioned that they could no longer observe BD patients and therefore questioned whether BD was an entity separate from atherosclerosis and thrombosis [45, 46]. Hospital data from 1985 to 1996 of Nagoya University Hospital also disclosed the decreasing trends of both new-onset and recurrent patients diagnosed with BD [47]. In addition, the effect of tobacco use on the survival rate and limb salvage seemed to decrease as BD patients lived longer. Within 10 years after diagnosis, there was no marked difference in the survival rates between the control and BD patients [48]; however, limb salvage was higher in ex-smokers [49]. At 20 years of follow-up, the survival rate of BD patients was significantly lower than the expected survival of the matched US population, but did not differ among BD patients between continuous smokers and ex-smokers, whereas limb salvage was more frequent in ex-smokers [50]. Further, beyond 20 years after the diagnosis of BD, continuous smokers had slightly higher but not statistically significant disadvantages in limb salvage over ex-smokers [51]. Similarly, Ohta et al. reported that patients with BD who were stable did not show recurrence of ulceration even though they smoked continuously, and new occurrence of ischemic ulceration or gangrene was not noticed in patients over 60 years of age [52, 53]. These findings on the survival rates are understandable, because the current standard therapy of BD—abstinence from tobacco, prostacyclin analogs, platelet inhibitors, vasodilators, and various surgical techniques—alleviates only vascular narrowing of the limbs and may not ameliorate the systemic cause(s). BD in women was rare in the past [3]; however, since the 1970s, women have been observed to suffer from BD increasingly in the United States (23.0%) and France (24.0%) [54, 55], which seems to be related to their increased use of tobacco (26.2% in men *vs.* 15.7% in women in the United States) [56]. Recently, BD is occasionally diagnosed first in the elderly population, which may be related to the increased number of nonsmoking men. Upper limb involvement is also more commonly observed [54, 55]. Furthermore, various doses of nicotine when administered orally or intravenously to experimental rabbits induce no pathological or necrotic changes of the aorta rather than the inflammatory changes. Therefore, nicotine cannot explain the pathological changes of BD in humans [57], whereas BD occasionally occurs with the use of smokeless tobacco or nicotine chewing gum, which suggests that tobacco ingredients, particularly nicotine, are causally related to BD [58]. The reason for this conflicting result has not been clearly explained. Additionally, a BD-like illness comes about in individuals consuming Marijuana (“cannabis arteritis”) with an upsurge in its use over the past decade [59], which indicates

that this illness and BD may share the same pathogenic mechanism, although most of these individuals smoke tobacco concomitantly, and the pathological features of affected limbs have been scarcely reported.

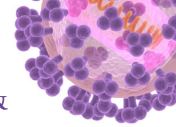
## BUERGER'S DISEASE AND INFECTIOUS DISEASES

As for the infectious etiology of BD, Buerger [60] and Allen and Brown [27] proposed that BD might be an infectious disease, mainly based on pathological findings; however, no specific organism was identified at that time [61]. Bernstein performed microbiological investigations in a large number of BD patients, but did not find any organisms of the spirochete, acid-fast bacilli, or ordinary pyogenic bacteria [cited from 19]. Brown et al. believed that the infectious agent of a low grade is involved in the pathogenesis of BD, if BD is an infectious disease [15]. Buerger reported a series of experiments involving humans and monkeys. Blood clots taken from acutely affected veins of BD patients were implanted adjacent to apparently healthy vessels of individuals who had previously suffered migrating phlebitis, atherosclerosis, or no vascular disease and of two monkeys. He doubly ligated and longitudinally incised the veins of the recipients before implantation. This experiment produced bland thrombosis in all instances, but the typical pathological features of BD, namely acute inflammation with multinucleated giant cells, was observed only in the individuals who had previously suffered BD [61].

Rabinowitz reported the isolation of a specific organism from the blood of patients with BD; the bacterium was culturable in conventional culture media. The author allowed leeches to feed from a patient with BD, inoculated the blood obtained from the leeches into the patient's skin, and subsequently produced gangrenous areas in the patient. The organisms were motile gram-negative bacilli with a bipolar appearance and contained metachromatic granules. In addition, the patient's blood was inoculated into rabbits to produce gangrenous lesions. Inoculation of a pure culture of the bacteria into other rabbits also produced gangrenous lesions. The pathological findings were similar to those found in patients with BD [62]. However, Jablons could not confirm the organism described by Rabinowitz [19]. Horton and Dorsey reported that gram-positive pleomorphic streptococci were isolated from biopsy specimens or amputated tissues of the extremities in patients with BD, as well as in patients with atherosclerosis. Moreover, they inoculated these streptococci into rabbits and reproduced intimal proliferation and thrombosis in some of them. They also implanted segments of vessels from BD patients to rabbits and obtained the same pathological result [63].

Allen and Lauderdale reported a case of BD possibly transmitted from human to human. A surgeon, who was a heavy smoking Scottish man, presented with discoloration of the third, fourth, and fifth fingers 1 month after a piercing injury that occurred while amputating the toe of a patient with BD [64]. This case suggested that the surgeon acquired responsible agent(s) from the patient. However, because the surgeon was a heavy smoker, there was a possibility that he would have suffered from latent BD and its manifestation was triggered by the trauma. Scotland was once a well-known endemic country of typhus, secondary to the mass immigration of Irish individuals during the Irish Potato Famine. A trauma-related BD similar to this case was mentioned by Weber. A Jewish man was hospitalized due to nocturnal pain, discoloration, and gangrene of the left foot, and had a history of a cab running over the foot. On admission, pulsation in the left dorsalis artery was absent. The patient had a long history of pain in the left leg, and slight atrophy of the left calf muscle had been noticed three months precedent to the accident [65].





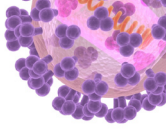
As for the other infectious diseases that may be related to BD, syphilitic endarteritis obliterans is pathologically similar to BD [65]. In 1928, Orr [66] and Brown et al. [15] described that oral cavity infections were common in patients with BD. Recently, Iwai et al. reported a relationship between periodontal infections and BD. They detected elevated IgG antibodies to periodontal bacteria and confirmed the presence of oral bacterial DNA in thrombi obtained from BD patients [67, 68]. Thrombus formation was induced by injection of oral bacteria into rats [69]. From these results, they proposed a hypothesis that oral bacteria form microemboli with platelet aggregates, deposit in smaller vessels, and form thrombi [70]. In 1941, Thompson and Naide reported that dermatophytosis was common in BD patients; therefore, this fungal skin infection might play a causative or aggravating role in BD [71, 72]. Several investigators insisted that BD was not an infectious disease because BD was rare in women and there was no infectious disease showing such male predominance; however, this hypothesis is proven faulty as the prevalence of smoking and BD in women was observed to increase.

## RICKETTSIA AND ORIENTIA

Before commencing on a description of the relationship between BD and rickettsiosis, some basic knowledge on the taxonomy and biological properties of rickettsia will be briefly mentioned. In particular, with the development of molecular techniques, Didier Raoult and his colleagues fundamentally changed the classification of the genus *Rickettsia*, and detailed descriptions of these are beyond the scope of this review [73-75].

The family *Rickettsiaceae* consisted of one genus, *Rickettsia*, in the past (currently, two genera, *Rickettsia* and *Orientia*), which was traditionally divided into three groups based on phenotypic features: typhus group, spotted fever group, and tsutsugamushi disease (scrub typhus) group. Typhus group rickettsiae include *Rickettsia prowazekii*, which causes epidemic typhus, its recrudescence form, namely Brill's disease (Brill-Zinsser disease), and sylvatic epidemic typhus, and *Rickettsia mooseri* (currently *Rickettsia typhi*, which causes murine typhus, also known as endemic typhus). The spotted fever group rickettsiae include *Rickettsia rickettsii*, the etiologic agent of Rocky Mountain spotted fever (RMSF), *Rickettsia conorii* and its four subspecies (Mediterranean spotted fever, Indian tick typhus, Israeli spotted fever, and Astrakhan fever), *Rickettsia sibirica* (Siberian tick typhus or North Asian tick typhus), *Rickettsia japonica* (Japanese spotted fever), *Rickettsia africae* (African tick typhus), *Rickettsia slovaca* (tick-borne lymphadenopathy, Dermacentor-borne necrosis erythema lymphadenopathy, or scalp eschar and neck lymphadenopathy after tick bite), *Rickettsia helvetica*, and so on. Some investigators have added the "ancestral group" (*Rickettsia bellii* and *Rickettsia canadensis*) and "transitional group" (*Rickettsia akari*, *Rickettsia australis*, and *R. felis*) to the family *Rickettsiaceae*. Tsutsugamushi disease is caused by *Orientia tsutsugamushi*, reclassified as a new genus by Akira Tamura and his colleagues in 1995 from *Rickettsia tsutsugamushi* and further formerly *Rickettsia orientalis* [76]. Recently, phylogenetically distinct strains, such as *Candidatus Orientia chuto* and *Candidatus Orientia chiloensis* were reported from Dubai and Chile, respectively.

In addition to the above-mentioned organisms, various related bacteria were once classified as *Rickettsia* or rickettsia-like organism. *Coxiella burnetii* (formerly *Rickettsia burnetii*) is currently classified as a member of the family *Coxiellaceae*. This bacterium causes acute and chronic Q fever; the latter includes disease spectrum of endocarditis and infections of aneurysms and vascular grafts. Pararickettsia is now classified as *Chlamydia*, which includes *Chlamydia*



*trachomatis*, *Chlamydia psittaci*, and *Chlamydia pneumoniae* (*Chlamydophila pneumoniae*). Because *C. pneumoniae* was first isolated in 1986 [77], in the 1960s, pararickettsia meant only *C. trachomatis* and *C. psittaci*. In the 1990s, *C. pneumoniae* was in the spotlight as a putative cause of atherosclerosis. Neorickettsia in the past, particularly in France, indicated *Chlamydia* species. Currently, this term denotes a different bacterium, *Neorickettsia sennetsu* (formerly *Rickettsia sennetsu* and *Ehrlichia sennetsu*), which is included in the family *Anaplasmataceae* alongside *Anaplasma*, *Ehrlichia*, and *Wolbachia*. The term Bedsonia was sometimes used to indicate *Chlamydia* (more specifically, *C. psittaci*). *Coxiella*, *Chlamydia*, *Anaplasma*, *Neorickettsia*, and *Ehrlichia* are spherical and replicate in cytoplasmic inclusion bodies, whereas *Rickettsia* and *Orientia* species are short rods and replicate freely in the cytosol. Despite these differences, most of these organisms have a tropism for vascular endothelial cells; however, *Anaplasma*, *C. trachomatis*, and *C. psittaci* do not. Additionally, these organisms can survive persistently in animals or the human body and occasionally induce chronic symptomatic infections.

*Rickettsia* is a pleomorphic Gram-negative bacterium that possesses typical bacterial cell walls containing peptidoglycan, and is poorly stained by ordinary staining methods, including hematoxylin and eosin staining. *Orientia* species possesses a minute amount of peptidoglycan-like structures. *Rickettsia* and *Orientia* are obligatory intracellular bacteria and require eukaryotic host cells for replication. They are released extracellularly when some defects are created on the surface of the host cells [78].

The main target of *Rickettsia* and *Orientia* is vascular endothelial cells, and rickettsiae are observed within these cells. Vasculitis and perivasculitis are the main pathological findings [79, 80]. Necrotizing arteritis and thrombo-arteritis of smaller vessels are observed in epidemic typhus and RMSF. Endothelial hyperplasia, thrombus, and focal mononuclear cell infiltration around vessels, namely, typhus nodules, are observed in epidemic typhus. The infiltration of polymorphonuclear leukocytes into the arterial walls and perivascular space in rash lesions is observed more frequently in spotted fever rickettsioses and epidemic typhus compared with tsutsugamushi disease [81]. In tsutsugamushi disease the overall pathological features are similar to epidemic typhus [82]; however, overt thrombosis is somewhat uncommon and typhus nodules are seldom observed. In biopsy specimens of eschars and erythematous rashes in tsutsugamushi disease, the immunophenotypes of infiltrating cells are predominantly CD8<sup>+</sup> T lymphocytes and CD68<sup>+</sup> monocytes/macrophages; CD4<sup>+</sup> T cells are present in smaller numbers than CD8<sup>+</sup> T cells; CD30<sup>+</sup>-positive large atypical cells were observed in approximately half of the patients; CD20<sup>+</sup> B lymphocytes were infrequent [83, 84]. Kawamura described in his monograph that giant cells were observed in the eschar, primary lymph nodes, spleen, and bone marrow in tsutsugamushi disease [85]. Allen and Spitz also described that giant cells were present in the myocardium and that the pathological changes around the vasa vasorum in the aorta in epidemic typhus, spotted fever, and tsutsugamushi disease were remotely similar to the mesaortitis of syphilis [81]. David H. Walker et al. reported that CD68<sup>+</sup> macrophages/dendritic cells that contained *R. akari* within the cytoplasm were observed in biopsy specimens of eschars [86]; a similar finding was also observed in tsutsugamushi disease [87]. In Mediterranean spotted fever, rickettsialpox, and *R. slovaca* infection, the infiltration of lymphocytes and macrophages are the main findings in eschars [88-90]. Thus, the early lesions of tsutsugamushi disease, rickettsial infections, and BD share similar histopathological features. This suggestion is further supported by previous reports that syphilitic endarteritis was similar to BD [65] and that typhus was somewhat similar to mesaortitis of syphilis pathologically [81].

T cell-mediated cellular immunity plays a major role in the defense against *Orientia* and *Rickettsia* infections [91-93]. In addition, in an experimental animal model activated macrophages can suppress the proliferation of *O. tsutsugamushi*, particularly during the early phase of infection [94]. Humoral immunity is also involved, based on the evidence of variably elevated relevant cytokines, such as IL-6 and IL-10, as well as elevated specific antibodies. However, Howard T. Ricketts reported in 1908 that the therapy of RMSF with immune serum in experimental animals showed no discernable therapeutic efficacy [95]; thus, rickettsia-specific antibodies are thought to be ancillary in the defense against rickettsial infections.

Historical typhus (epidemic typhus) was once endemic throughout Europe, usually related to war and famine, until the late 18th century and then decreased with improvement in general hygienic conditions. Finally, it was controlled with delousing measures after the discovery of louse-borne transmission of epidemic typhus by Charles Nicolle in 1909 and the identification of "*Rickettsia prowazekii*" by Henrique da Rocha-Lima in 1916 [96, 97]. Meanwhile, typhus became highly prevalent during and immediately after World War I in Eastern Europe and Russia. In Far East Asia, this illness was endemic to China and Korea, but rare in Japan [98], whereas BD was common in all these countries [26, 99, 100]. Since 2000, epidemic typhus has become rare worldwide and occurs only in a few African countries. Murine typhus occurs globally, but more frequently in developing countries. Spotted fever group rickettsioses occur sporadically worldwide. *Tsutsugamushi* disease is known to occur only in Southeast and Far East Asia and Oceania; however, cases have been noticed in far wider areas than previously thought—Africa (Congo, Cameroon, Kenya, and Tanzania), Middle East (Dubai and Djibouti), Central America (Honduras), and South America (Chile and Peru).

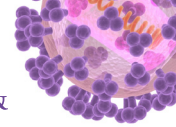
## PERSISTENT INFECTIONS OF RICKETTSIA AND ORIENTIA

Although many studies insist that BD may be related to rickettsial infection, as described below, the first objection to accept its rickettsial hypothesis is the lack of convincing evidence, that is, the direct visualization and isolation of rickettsia consistently from the diseased vessels of patients with BD or reproduction of the same disease in experimental animals after the inoculation of vascular specimens obtained from BD patients. However, because this illness becomes rare and is a neglected disease in developed countries, demonstration of the infectious agent in this manner is rarely performed. The second objection to this hypothesis is that these organisms have been known to cause acute febrile illnesses that are usually related to exposure to arthropod vectors; however, no such history was reported in BD patients and therefore vector-borne rickettsiosis could not be considered. Contrary to the general belief, *R. prowazekii*, *R. typhi*, *R. rickettsii*, and *O. tsutsugamushi* all cause chronic persistent infections in humans as well as in animals, as described below. Therefore, it is difficult to identify the history of exposure to arthropod vectors in chronic *Rickettsia* and *Orientia* infections. The last objection is a common knowledge that antibiotic therapy can cure rickettsial infection; however, this is not true, as described below.

### Chronic *R. prowazekii* infection:

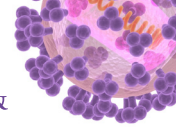
1) Regarding persistent rickettsial infection, *R. prowazekii* is well established to persist asymptotically for several decades in humans and can recur to present as Brill-Zinsser disease. Since the first suggestion of rickettsial recrudescence by Hans Zinsser in 1934 [101], this hypothesis has been studied by several investigators. In the 1950s, immigrants from





Eastern Europe showed higher complement-fixing (CF) antibody-positive rates to *R. prowazekii* than America-born individuals (17.0% – 40.0% vs. 0%) [102, 103]. Price et al. confirmed the presence of *R. prowazekii* in humans during the interepidemic period by isolating *R. prowazekii* from the lymph nodes of two out of 31 patients who were asymptomatic immigrants from Europe and whose CF antibody tests were positive for *R. prowazekii*. The lymph nodes were excised from the 31 patients during abdominal operations for unrelated reasons and were cultivated [104]. It is noteworthy that it is not easy to identify the history of typhus in patients with Brill-Zinsser disease. For example, Brill reported 272 patients with Brill's disease, but there was no description on their previous typhus [105-107]. Additionally, Zinsser also did not mention the history of typhus in 538 patients with Brill's disease [101]. These facts indicate that the relationship between the history of typhus and Brill-Zinsser disease cannot be detected in routine clinical practice. In 1952, when the relationship between Brill-Zinsser disease and previous typhus was nearly established, Murray reported that only five (16.0%) of 31 patients with Brill-Zinsser disease recalled their previous typhus despite his purposeful inquiry about the previous illness [108]. The reason for the absence of a history of typhus in recrudescent rickettsial infections is manifold. First, it is well known that epidemic typhus and tsutsugamushi disease present benign clinical features in children, and mild rickettsial infections might be misdiagnosed as different diseases. For example, mild tsutsugamushi disease ("new type tsutsugamushi disease") in Japan was diagnosed as upper respiratory infection, bronchopneumonia, hepatitis, neurosis, or murine typhus [109]. Second, sero-epidemiologic studies in endemic areas revealed that many seropositive individuals have no history of rickettsial infections [110], and the reason of which might be exemplified by the report in Peru that asymptomatic *R. prowazekii* reinfection occurred frequently in poor hygienic environments and therefore seropositive rates increased with age [111]. Mansueto et al. reported a patient with spotted fever group rickettsiosis who showed a tache noire only, not accompanied by fever, rash, and lymphadenopathy, and the diagnosis was made by direct immunofluorescence staining of a biopsy specimen from the inoculation eschar. As the patient had an antibody response of the reinfection type (*i.e.*, anti-*R. conorii* IgG titer of 1:320 and IgM 1:80), partial immunity might contain the infection at the inoculation site [112]. Asymptomatic infection is also observed in tsutsugamushi disease. A serosurvey among healthy forestry workers in national park offices in Korea showed a 4.9% (35/718) seropositive rate [113]. Further, patients with tsutsugamushi disease in endemic areas, despite having no history of tsutsugamushi disease, frequently (*i.e.*, 24.3% in young Taiwanese soldiers and 63.6% in elderly Korean civilians) disclosed the serologic reaction of reinfection type, namely IgG antibody appeared earlier before IgM and showed higher titers than IgM [92, 114]. Lastly, avirulent or less-virulent species of rickettsia or strains of *O. tsutsugamushi* are frequently isolated from arthropod vectors or humans [115, 116]. Although these isolates are avirulent with respect to inducing acute febrile rickettsioses, their potential for inducing chronic rickettsial disease is unknown. For the above reasons, patients with chronic rickettsial infections do not remember their past rickettsial infections. Furthermore, laboratory confirmation of *R. prowazekii* infections in both initial and recrudescent infections is exceptional [117], which implies that the diagnosis of recrudescent rickettsial infection by laboratory methods is also rather difficult. Therefore, epidemiological methods are still valuable tools for investigating recrudescent rickettsial infections.

2) Regarding recrudescent *R. prowazekii* infection, Brill-Zinsser disease is a relapse of epidemic typhus. In contrast to the severe nature of epidemic typhus, this illness is benign, lasts about two weeks, and improves spontaneously. The mortality rate is low—one (0.4%) out of 272 patients in a series of articles by Brill even in the absence of antibiotic therapy



[105-107]. Dramatic improvement follows appropriate antibiotic therapy. As for localized recrudescence *R. prowazekii* infection, Turiaf and Battesti reported two cases of pneumonia that were thought to be recrudescence typhus: one patient was due to epidemic typhus and the other due to murine typhus. The former patient was a Moroccan man who had resided as a worker in France and was hospitalized with mild pneumonia of 4 days' duration. His serum showed a positive microagglutination reaction to *R. prowazekii* and negative results for murine typhus, Mediterranean spotted fever, and Q fever. The patient improved with symptomatic treatment alone [118].

3) As for chronic localized *R. prowazekii* infection, cases of rickettsial endocarditis have been reported, although the evidence of its rickettsial etiology was not sufficient. Donzelot et al. described two forms of infective endocarditis: one was positive on ordinary blood culture and responded to penicillin, and the other was culture-negative and penicillin-ineffective. The former also showed a constant existence of pre-existing endocardial alteration and preponderant localization on the mitral valve. The culture-negative form showed different features compared with the former: no pre-existing cardiac disease, predilection for the aortic valve, greater severity (*i.e.*, higher mortality and delayed resolution of systemic symptoms), and frequent involvement of the viscera, namely the central nervous system, kidney, spleen, and liver [119]. Camelin et al. reported clinically similar cases of culture-negative, penicillin-resistant, primary malignant infective aortic sigmoiditis (*i.e.*, infective endocarditis localized at the sigmoid cusp of the aorta) [120]. Donzelot et al. reported 24 cases of rickettsial endocarditis among 200 cases of endocarditis and summarized its features: predominance of male over female patients; no history of any cardiac disease; history of former prisoners or deportees, living in typhus-endemic areas, or suffering epidemic typhus; cardiac murmur suggesting valvular abnormality; splenomegaly; predominant affection of the aortic valves; reactive sero-protection and intradermal tests for typhus antigen, which indicates past infection; exclusion of Q fever by serology or culture; the duration of illness for more than 3 months; no response to penicillin and/or streptomycin, but dramatic improvement with tetracycline therapy [121, 122]. Worms et al. reported a case of endocarditis in a man who had suffered epidemic typhus 5 years previously. At the time of death, a Giroud's intradermal sero-protection test was positive for typhus and agglutination tests for other rickettsiae were negative [123]. Cattani et al. reported two cases of endocarditis. One patient was a 38-year-old man who had been in prison from 1941 to 1944 and received typhus vaccines. On admission, he had fever of 4 weeks' duration, a diastolic murmur, hepatosplenomegaly, high erythrocyte sedimentation rates, normal leukocyte counts, hematuria, and pyuria. Penicillin and streptomycin were administered without noticeable improvement; subsequently, tetracycline for 19 days markedly improved his condition, but recurred 12 days after discontinuation of the antibiotic. A Giroud intradermal sero-protection test was strongly positive; however, agglutination and Weil-Felix tests were negative. Tetracycline was administered again for 15 days, and his condition improved to be maintained for 6 months. The other patient was a 30-year-old woman who had grown in Poland, a typhus-endemic area at that time. She had a mitral valve disease, which was first detected 1 year prior to hospitalization. On admission, fever of 2 months' duration, dyspnea, pedal edema, hepatosplenomegaly, and arrhythmia were noted. Penicillin therapy improved her condition over a period of 6 days; however, from the day 7, the fever was observed to return. Giroud sero-protection and Weil-Felix tests were negative; however, the intradermal test was strongly positive. The patient improved with tetracycline therapy, but it had to be discontinued due to severe gastrointestinal upset. Thereafter, her condition deteriorated, and she finally died due to heart failure [124]. Faure reported a case of infective endocarditis

in a 39-year-old man. He had suffered a typhus-like illness 5 years previously. Thereafter, the patient complained of exertional dyspnea and precordial pain for 3 years, and experienced intermittent fever and arthralgia for 1 year. At the time of hospitalization, a combination therapy with penicillin and streptomycin was administered with slight improvement; however, the fever recurred after discontinuation of the antibiotic therapy. Reinstitution of the antibiotics improved his condition slightly, and he was discharged from the hospital. Five weeks later, the patient was readmitted to the hospital because of heart failure and pulmonary congestion. All supportive care was in vain, and he died 9 days later. At autopsy, ulcerations and vegetation were observed at the aortic orifice. A rickettsial agglutination test was positive for *R. prowazekii* at a titer of 1:160. Faure heard from Giroud that it was first for a patient with endocarditis to show a positive rickettsial agglutination test [125]. Baylon et al. reported a patient with arteritis and infective endocarditis whose serology was positive for both *R. prowazekii* and *C. burnetii*. The patient had a long history of staying in North Africa, but did not contract typhus fever. At presentation, congestive heart failure due to mitral stenosis, digital clubbing, and vascular insufficiency of the right foot possibly due to obliterating arteritis were observed; fever, splenomegaly, or urinary abnormality was not present. A Giroud intradermal sero-protection test was strongly positive for historical typhus. His condition improved with cardiotoxic therapy alone. Two months later, he was readmitted because of a flare-up of the arteritis of the right radial artery. At this time, an agglutination test was positive for *C. burnetii* at a titer of 1:1,280, and chlortetracycline was administered with marked improvement. Two months later, fever and aggravated general condition were noted, and tetracycline and chloramphenicol were administered. He was discharged from the hospital with an improved status. A follow-up agglutination test for *C. burnetii* decreased to 1:20 [126]. Cauvin et al. reported a case of infective endocarditis of the aortic valve with a positive serologic result for spotted fever group rickettsiosis but negative for other rickettsiae, Q fever, and chlamydia, and the patient was cured with spiramycin (a macrolide antibiotic) therapy [127]. Michon described two patients with infective endocarditis of the aortic valve; one was positive for *R. mooseri* (1:160) and the other for both *R. mooseri* (1:320) and *R. prowazekii* (1:320) [128].

4) As for other chronic rickettsial diseases, a case of recurrent intestinal hemorrhage and abdominal pain was reported in 1951 [129].

#### **Chronic *R. typhi* infection:**

1) Persistence of *R. typhi* is investigated mostly in animals [130].

2) Recrudescence murine typhus was reported in individuals from Morocco or Algeria (*i.e.*, endemic area) who developed murine typhus in France (non-endemic area) after the maximum incubation period of murine typhus, as described below. Benoist et al. reported a case of fever and meningeal signs with a positive rickettsial agglutination reaction to *R. typhi*. The patient contracted typhus 2 years previously in North Africa, and his mother suffered the same condition and died at that time [131]. Benoist et al. reported two cases of murine typhus, which were considered recrudescence. A 22-year-old woman arrived in France from Algeria 1 month previously. She developed fever for 3 days, rash, splenomegaly, and leukopenia. Treatment with chloramphenicol improved her condition 3 days later. Serologic tests revealed slightly positive results initially and later strongly positive reactions for murine typhus. The other patient was a 30-year-old Algerian man who had resided in France for 5 years, who presented with fever, headache, and leukopenia. Tetracycline therapy improved his condition. Agglutination tests were positive for murine typhus initially and became

negative two months later. He had a febrile illness and rash 9 years previously in Algeria, which might have been murine typhus [132]. Ledru et al. described several patients with benign rickettsial infections, of which four might be due to true rickettsial recrudescence or serologic relapse: one case of recrudescence of *R. typhi* infection, one case of possible Brill-Zinsser disease, and two cases of *R. conorii* infection including one case of possible endocarditis [133]. In 1964, a case of recrudescence pneumonia due to murine typhus was reported. The patient was an Algerian man, who had a history of prolonged febrile illness in Algeria, and had stayed in France for 26 months. At the time of hospitalization, he presented with a high fever, intense headache, and no respiratory symptoms but chest radiography confirmed the presence of pneumonic infiltrates. Treatment with penicillin improved the patient's condition. A rickettsial microagglutination test showed positive reactions to both *R. typhi* (1:160 initially and then rose to 1:640) and *R. conorii* (from 1:160 to 1:320) [118]. Lamotte et al. reported a case of myopericarditis that was possibly caused by recrudescence murine typhus. The patient was a 38-year-old Algerian man who had worked in France since a year ago. He was hospitalized due to fever of 10 days' duration, cough, and mucous sputum. There was no history of typhus vaccination or typhus fever. Bronchopneumonia was initially considered; however, pericarditis was diagnosed later and the prolongation of the PR interval was identified. Acute rheumatic fever was suspected; however, anti-streptolysin was negative. Therefore, the patient was managed with penicillin, cortisone, and tetracycline initially. The response was good; however, relapses were observed as the dose of cortisone was reduced. A slide microagglutination test was positive for *R. mooseri* at a titer of 1:640, which increased to 1:1280. Tetracycline and cortisone were used, with clinical improvement and descent of the antibody titer [134].

3) As for chronic localized *R. typhi* infection, Rauber et al. reported two cases of infective endocarditis with positive agglutination results to *R. typhi*. One patient was once in prison prior to hospitalization. He presented with mild fever, asthenia, hepatomegaly, and mild splenomegaly. After the diagnosis of endocarditis, he died suddenly before the start of tetracycline therapy. An autopsy revealed a bicuspid aortic valve and ulcerations and vegetation on the entire surface of the valve. The pathology showed acellular amorphous tissue in the vegetation and thickened vascular walls in the spleen. The other patient presented with subacute infective endocarditis of the aortic valve. Blood cultures were sterile, and therapy with penicillin and streptomycin was ineffective. A rickettsial agglutination test was positive, and tetracycline was used [135]. Austin et al. reported a case of culture-negative endocarditis with serological evidence of murine typhus. The mitral and aortic valves were replaced, and the pathological examination of the excised valves showed an inflammatory change with neutrophilic infiltration; Giemsa staining revealed numerous intracellular coccobacilli within the cytoplasm of neutrophils and mononuclear cells. However, immunohistochemical (IHC) staining for rickettsiae revealed no organisms. Anti-*R. typhi* antibody titers decreased with doxycycline therapy for 6 weeks [136]. Buchs et al. reported a case of culture-negative endocarditis with positive serologic results for murine typhus. The patient improved with tetracycline therapy for 1 year [137].

4) A case of bilateral optic atrophy with persistent visual loss has been reported [138].

#### Chronic spotted fever group rickettsioses:

1) A persistent *R. rickettsii* infection was documented in a patient 1 year after recovery from RMSF. A 49-year-old man suffered a severe attack of RMSF, which was successfully managed with chlortetracycline and chloramphenicol. One year later, an inguinal lymph

node was excised and intraperitoneally inoculated into guinea pigs. The splenic and hepatic suspensions from one of the guinea pigs were passaged into another guinea pig. The latter guinea pig exhibited fever and positive CF antibodies to *R. rickettsii*. Additionally, the macerated splenic and hepatic suspensions from the guinea pigs were transferred to yolk sacs. Rickettsia-like organisms were observed in smears of the yolk sac material and showed cross protection to the Bitter Root strain of *R. rickettsii* [139]. Hove and Walker reported a case of RMSF. A 34-year-old man was affected by RMSF, complicated by multi-organ failure and bilateral gangrene of the feet. With chloramphenicol for 3 weeks and subsequently doxycycline for 2 weeks, his general condition improved, and subsequently the gangrenous feet were amputated. Rickettsiae were identified using IHC staining of the partially viable gangrenous margins of the amputated feet [140].

2) As for recrudescent spotted fever rickettsioses, cases of possibly recrudescent *R. conorii* pneumonia have been reported. Cartagenova and Agnese reported seven cases of pneumonia out of 17 cases of Mediterranean spotted fever. The seven patients presented with fever, cough, and radiologically confirmed pneumonia, followed by rash. They showed evidence of tick-borne infection, that is, tache noir, and positive Weil-Felix reactions. Because it is rare that the occurrence of pneumonia preceded the occurrence of rash, it could be hypothesized that the pneumonia occurred as recrudescence of dormant *R. conorii* and that the rash and tache noire occurred secondary to Mediterranean spotted fever acquired at this time [141]. In 1956, there was a report of recrudescent *R. conorii* pneumonia. A 27-year-old Algerian man had worked as a factory worker in France for 9 months and presented with chest pain, cough, and mucopurulent sputum for 8 days. The leukocyte count was normal and a radiograph confirmed pneumonia. Penicillin was administered without any beneficial effects. Neither an eruption nor a tache noire was observed. An agglutination test for *R. conorii* was positive at a titer of 1:160 [142].

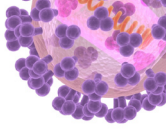
### Chronic *O. tsutsugamushi* infection:

1) The persistence of *O. tsutsugamushi* was documented several times in experimental animals [143, 144]; however, its persistence in humans has been scarcely investigated. In 1947, Rinya Kawamura first documented the persistence of *O. tsutsugamushi* in a human being. A 50-year-old patient with general paresis had been treated with malariotherapy and “Salvarsan” (arsphenamine) without improvement. The Pescadores strain of *O. tsutsugamushi*, as an alternative agent for inducing fever, was inoculated into the patient and could induce fever for 18 days. The fever pattern was compatible with that of the inoculated strain. A lymph node was extirpated 145 days after the fever therapy, inoculated into Mongolian hamsters, passaged in mice, and the strain was finally isolated. Lymph nodes from the other patient showed similar pathological findings; however, the culture was negative [145]. This result was recapitulated by Smadel [146]. At that time, when penicillin was not available in clinical practice, Kawamura and other Japanese investigators used this strain for fever therapy of chronic psychiatric diseases, including general paresis, and for a live attenuated vaccine [147, 148]. Hayashi and Watanabe inoculated the Pescadores strain into a patient with neurosyphilis; subsequently, the patient's blood was inoculated into a second patient 34 days after the fall of the fever in the first patient. The blood of the second patient was inoculated into a field rat and then the rat tissue emulsions were serially passaged in mice. One mouse of the third generation showed symptoms compatible with rickettsial infection, and rickettsiae were identified. This study documented the presence of *O. tsutsugamushi* in the blood during the convalescent phase of tsutsugamushi disease [149]. At that time, the blood of patients who had been treated with the Pescadores strain were infrequently injected



into other patients with general paresis and successfully induced fever. Thus, *O. tsutsugamushi* bacteremia is a rule during convalescence from tsutsugamushi disease, although the documentation of rickettsia in the recipients was seldom performed [147]. Joseph E. Smadel et al. reported that lymph node emulsions obtained from 12 asymptomatic persons who were 12 to 25 months after recovery from tsutsugamushi disease were inoculated into mice. One of the 12 individuals revealed a positive culture, and the isolate showed the same pathogenicity for mice compared with the original isolate [146]. Chung et al. collected blood specimens during both the acute phase and follow-up periods from six patients with tsutsugamushi disease who were successfully managed with antibiotics, cultured the specimens, and amplified and then sequenced the 56-kDa type-specific antigen genes of *O. tsutsugamushi* from the isolates. The isolates obtained during the follow-up showed nucleotide sequences identical to those of matched isolates obtained during the acute phase, thereby affirming the persistence of *O. tsutsugamushi* in humans [150].

2) Studies on recrudescent *O. tsutsugamushi* infection are more complicated, because this entity was reported only in endemic areas; therefore, mite-borne tsutsugamushi disease should be excluded. For example, Korea is a well-known endemic country of tsutsugamushi disease; however, this illness occurs only in a subpopulation and during a specific season. Most of the patients are exposed to scrub areas (*i.e.*, rural areas, mountains, city parks, or riversides), occur between October and December (97.0% of the patients notified to the Korea Disease Control and Prevention Agency occurred during these two months) [151], and have eschar. In particular, because the outbreak season in humans is related to the seasonal abundance of chigger mites [152, 153], occurrence of tsutsugamushi disease beyond the outbreak season is strong evidence against chigger-borne transmission. Eschar is uncommonly observed in tropical countries; however, it is common in temperate countries, such as Korea (79.0% – 93.0%) and Japan (85.0% – 87.0%) [154-157]. Residence in urban areas and no history of exposure to scrub areas lower the possibility of chigger-borne tsutsugamushi disease further. Thus, recrudescent *O. tsutsugamushi* infection can be differentiated from chigger-borne one even in endemic areas. In 1991, a case of recrudescent *O. tsutsugamushi* myocarditis was reported in Japan. A 34-year-old man presented with fever for 1 week, an erythematous papule (eschar), and regional lymphadenopathy. An immunofluorescent antibody to the Karp strain of *O. tsutsugamushi* was positive at a titer of 1:512. Tetracycline therapy improved the patient's illness. One and a half months after discharge from the hospital, precordial pain and exertional dyspnea developed, and was not accompanied by fever; subsequently, acute heart failure was diagnosed. Right ventricular endomyocardial biopsy revealed rickettsia-like bodies in the cytoplasm of the capillary endothelial cells of the myocardium; however, the exact nature of the organisms was not evaluated further. Tetracycline improved the symptoms of acute heart failure [158]. Another form of localized recrudescent *O. tsutsugamushi* infection is pneumonia, which was first reported in 2008 in Korea. The patient was a 15-year-old male adolescent who presented with fever for 1 day, headache, no cough, and multiple enlarged cervical lymph nodes. Chest auscultation and radiography identified pneumonia. Eschar and rash were not noticed. *O. tsutsugamushi* infection was confirmed by the isolation of *O. tsutsugamushi* and positive polymerase chain reactions in a blood specimen obtained on day 2. This case occurred during the non-outbreak season in Korea (July). The patient resided in a large city and had no history of exposure to scrub area. At that time, the possibility of recrudescent *O. tsutsugamushi* pneumonia was not considered [159]. In 2014, two additional cases of recrudescent *O. tsutsugamushi* pneumonia were reported by the same authors, and were summarized as follows. All three patients had fever and pulmonary infiltrates on day 2 or 3, not accompanied



with respiratory symptoms until that time. No eschar, residence in an urban area, and no exposure to scrub area were observed. Two of the three cases occurred during the non-outbreak season, that is, July and April. Both IgG and IgM antibodies to *O. tsutsugamushi* were examined in one patient, which showed higher IgG titers than IgM titers, that is, the serologically reinfection type, which was compatible with recrudescence *O. tsutsugamushi* infection [160].

3) A chronic disease that may be related to tsutsugamushi disease is accelerated coronary atherosclerosis. Many pathological studies of autopsied cases of tsutsugamushi disease usually emphasize interstitial myocarditis as a major cause of death, and have paid little attention to coronary arterial involvement [161], and soldiers during convalescence from tsutsugamushi disease also did not show persistent cardiovascular abnormalities [162]. Despite this general knowledge, a possible relationship between tsutsugamushi disease and coronary arterial involvement was first suggested in 1945. A 33-year-old man contracted tsutsugamushi disease in a Burma theater during World War II and suffered a prolonged course of illness. Six months following tsutsugamushi disease, the patient had a convalescent furlough. At home in the United States, he intermittently complained of chest tightness, and 2 days later the patient died suddenly. At autopsy, acute coronary thrombosis in underlying coronary sclerosis and no evidence of myocarditis were observed; therefore, it was concluded that this finding seemed to be not the changes produced by tsutsugamushi disease [163]. Allen and Spitz reported the pathology of tsutsugamushi disease in which a small non-occlusive thrombus was present in one of the coronary arteries. Another fatal case of tsutsugamushi disease revealed pronounced endothelial changes in the coronary arteries and vaso vasorum of the aorta [164]. Elsom et al. reported the sequelae and mortality 11 – 13 years after getting affected. The tsutsugamushi disease group included 524 patients who acquired it in the Indo-Burma Theater of operations and were compared with 521 soldiers who served in the Southwest Pacific Theater as the control group. After the war, all the individuals had resided in the United States; therefore, reinfection of tsutsugamushi disease could be excluded. Thus, a long-term consequence of a single attack of clinically definite tsutsugamushi disease could be investigated. Among the tsutsugamushi disease group, two out of 16 persons who underwent a more detailed examination displayed cold sweaty feet and pulses of reduced volume, suggesting a mild vasospastic illness in the lower extremities; in six patients, abnormal electroencephalogram was noticed. A total of 23 patients died, of whom 11 patients were disease-related (cardiovascular, 3; liver disease, 3; malignancy, 2; pneumonia, 1; pulmonary tuberculosis, 1; glomerulonephritis, 1), which showed no difference in the disease mortality between the two groups [165]. One limitation of this study was that Southwest Pacific Asia is an endemic area of tsutsugamushi disease; therefore, the control group might include persons with previous asymptomatic or atypical *O. tsutsugamushi* infection. Another limitation was that the patients were young healthy soldiers at the time of affection; therefore, they were 31 to 51 years of age at the time of the investigation. At these ages, clinically overt cardiac disease might be not apparent. Chung et al. mentioned aggravation of previous coronary syndrome (one case) and of cerebrovascular narrowing (one case), which occurred 6 and 8 months later, respectively [150]. In 2014, a study conducted in Taiwan, using the Taiwan National Health Insurance Research Database, indicated that the incidence of acute coronary syndrome increased by 37.0% within 1 year after suffering tsutsugamushi disease [166]. In Korea, 204 patients with tsutsugamushi disease diagnosed between 2001 and 2005 were followed up, using data from the Korea National Health Insurance Service, until 2015 or a diagnosis of stroke or acute myocardial infarction (AMI). The patients had no underlying cerebro- or cardiovascular disease at enrollment. At the end

of the study, the tsutsugamushi disease group showed that the incidence rate of AMI was 1.6 times higher than the control group; however, there was no difference in the incidence of stroke between the two groups [167].

4) Several studies have reported that a single organ abnormality persisted following tsutsugamushi disease: persistent atrial standstill [168], prolonged course of interstitial pneumonitis [169], and persistent renal failure after recovery from tsutsugamushi disease [170]. Irreversible destruction of the responsible organs might be the most plausible mechanism, while persistence of viable organisms or suboptimal development of immune defense, that is, chronic localized infection, might be another cause in certain cases. Alternatively, unrelated causes might be superimposed in the patients.

### Rickettsial infection and Buerger's disease

In this section, we briefly introduce and summarize the studies on cases affected by both BD and rickettsial infection and on therapy that may be related to rickettsial infection. In Europe, this illness has been described as spontaneous gangrene, arteritis obliterans, endarteritis obliterans, endangiitis obliterans, obliterating arteriopathy, juvenile arteritis, or thromboangiitis obliterans and Buerger's disease. Some of the reported cases did not meet the current diagnostic features of BD because unanimous diagnostic criteria were not established until 1996 (Papa) and 1998 (Shionoya) [171, 172].

Charles Goodman had convinced since 1916 that BD and typhus were etiologically related, based on epidemiologic findings and rickettsial serologic and skin tests. Goodman sent 21 sera of typical BD patients to Bernstein, who detected agglutinating and CF antibodies to *R. prowazekii* in three out of the 21 patients [173]. The skin test, using formaldehyde-inactivated *R. prowazekii*, revealed 96.0% – 100% positive rates in BD, 89.0% – 93.0% in persons with Brill-Zinsser disease, and 0% – 7.0% in the control group [174]. Goodman mentioned that microscopically BD-like vascular lesions were reproduced in guinea pigs with injections of blood from patients with typhus. He also mentioned that two pathologists, Klein and Seecof, independently noticed rickettsia-like organisms in the blood vessels of amputated materials from patients with BD [175]. At that time in the United States, the predominance of Jewish immigrants in BD was similar to the situation in Brill-Zinsser disease, in which 87.0% of the patients were foreign-born Jews [101]. Brill also described that races of patients with Brill's disease were Russian (30), Austria (12), United States (2), Ireland (2), Germany (1), and not noted (1) [106]. In fact, Brill and Buerger investigated their subjects at the Mount Sinai Hospital. Goodman further affirmed that BD was a late manifestation of an epidemic or endemic typhus [176]. Perla noted that four patients had a history of typhus fever among 41 cases of BD [177]. Meleney and Gavin Miller reported that two of 25 patients with BD had a history of typhus fever and 11 patients had a history of malaria [178]. Plotz examined typhus-specific antibody in 16 BD patients of whom four had the antibodies and the other 12 cases had no typhus-specific antibody [cited from 179]. Because these frequencies were not so high to relate typhus to BD, most investigators thought that typhus was not a cause of BD [9,19].

Goodman and Gottesman first used fever therapy in the treatment of BD. Initially, various foreign proteins were used to induce fever; however, later a typhoid vaccine (TAB, *i.e.*, typhoid and paratyphoid A and B) was identified to be more efficacious. The vaccine was administered weekly to five BD patients, which relieved narcotic-refractory pain in all cases [180]. Subsequently, Brown and Allen at the Mayo Clinic had investigated this method since 1926 [15, 181, 182]. Brown mentioned that fever therapy was the most effective medical

measure for relieving pain and increasing the blood flow to the affected extremity [15]. Barker reviewed his experience with fever therapy in 150 BD patients. This therapy tended to relieve rest pain and accelerate healing of ulcers, but showed little effect on claudication and extensive gangrene. The rationale behind this therapy was that fever induced vasodilatation and might strengthen non-specific immunity [183]. Allen described that the intravenous injection of the vaccine induced mild fever for 6 to 7 hours, whereas it relieved pain for days and improved the vascular insufficiency lesions for a much longer period [184]. Ball and Wright reported a patient with BD who had been treated in 1937 with fever therapy and abstinence of smoking. Thereafter, the patient remained symptom-free for 27 years [185]. Haragus et al. reported the results of fever therapy in 10 patients with BD. Necrosis, exercise tolerance, skin temperature, and laboratory findings improved after this therapy [186]. From 1958 Italian investigators reported a series of studies on the effectiveness of malariotherapy in BD. Corelli summarized his experience with this therapy in BD [187, 188]. He thought that BD was caused by hypersensitivity to ingredients in tobacco smoke, thereby explaining the rarity of BD in smokers. The occurrence of BD in ex-smokers was explained to be caused by indirect smoking, and thus he recommended strict avoidance of tobacco smoke even in public places where smoking was allowed. He used malariotherapy as an anti-inflammatory tool for desensitization. He mentioned that one patient who had received a course of malariotherapy improved dramatically, and thereafter remained healthy for a long period. Margini described the results of malariotherapy in eight patients with BD and three patients with arteriosclerosis obliterans. Two months after the malariotherapy, all patients responded favorably subjectively and objectively; however, oscillometric abnormalities did not improve. He mentioned that chloroquine was administered to three patients prior to the malariotherapy and did not modify the clinical course of BD; thus, the beneficial efficacy of malariotherapy in BD was not attributed to chloroquine [189].

Troisier and Horowitz suggested that BD was a late manifestation of benign typhus. The rationale for this suggestion was that all patients with BD occurred in residents of or coming from typhus endemic areas, rickettsia had a vasculotropic property, and gangrene was a well-known complication of typhus. They cited Alquier's experience in Algeria that a large number of dry gangrenes were observed among 420 cases of typhus and gangrene could occur even 2 years after the disease. The study by Ramsine et al. was cited that individuals with inapparent *R. prowazekii* infection also had viable rickettsiae in their blood [190]. Based on this evidence, they hypothesized that if severe typhus could give rise to severe acute vascular complications, attenuated typhus might cause relatively mild and slowly evolving arteritis. They presented one case of BD of 2 years' duration and positive Weil-Felix reactions [191].

Mandl reported eight patients with BD who were treated with penicillin (100,000 units/day for 8–12 days) and seven of the eight patients responded favorably. Pain, edema, thrombophlebitis, and ulcers improved, while oscillometric findings did not change. Curiously, seven patients with advanced BD responded favorably, whereas one patient with thrombophlebitis did not respond to penicillin [192]. Dreyfus et al. reported a case of arteritis obliterans preceded by epidemic typhus. The initial febrile illness showed features of epidemic typhus; however, no confirmatory test was performed. After the fever subsided, severe pain in the entire length of the right lower limb and swelling of the leg and back of the foot developed. He was referred to a large hospital where the illness was diagnosed as arteritis obliterans [193]. Ferey described a patient with diabetes and BD. He underwent several surgical procedures because of gangrenous lesions at multiple sites. Subsequently, gangrene of the left index finger and mild lymphangitis occurred, and penicillin relieved

the pain immediately and completely resolved the small gangrene 3 days later. Later, he was hospitalized because of pain recurrence. Penicillin (1,500,000 units) was injected again and thereafter pain was relieved for 14 days [194].

During World War II, epidemic typhus was not a main problem in military personnel; however, a large number of civilians were affected mainly in Eastern Europe, Russia, and North Africa. North America was little affected, because at that time most immigrants came from Asia and Mexico. For this reason, studies on BD in the United States have decreased since the 1950s. Effective antibiotics against rickettsia, such as chloramphenicol and tetracycline, have been available from the 1950s. Between the 1950s and early 1970s, French, Romanian, Italian, German, and Russian investigators published many articles on BD, including the causative role of rickettsia, particularly *R. prowazekii*.

Marty et al. reported a case of arteritis with rickettsial infection that was affected in Indochina. The patient presented with fever, right hemiplegia due to cerebral thrombosis, unequal radial arterial pulses, and a positive OXK reaction. Four months later, he returned to France and showed the findings of arteritis in four extremities. In France, a typhus infection was diagnosed by positive CF and agglutination tests for epidemic typhus, which was tested at the Pasteur Institute [195]. Neel reported a patient with BD who had a history of epidemic typhus. He suffered recurrent attacks of superficial thrombophlebitis and intermittent claudication following epidemic typhus. Nine years after recovery from typhus, a distal gangrene of the fifth toe and an absent posterior tibial arterial pulse were observed. Arteriography revealed obstruction of the vessel and abundant collateral vessels. No microbiological or serological test was performed [196]. Worms reviewed the cardiovascular manifestations and complications of historical typhus, BD, and rickettsial endocarditis [197].

Michon et al. described four cases of vasculitis with positive rickettsial serologic reactions: two patients for *C. burnetii*, one for *R. typhi*, and one for *R. conorii*. Tetracycline was administered to two patients who improved favorably [198]. They also described eight patients with various vascular diseases with positive serology for *C. burnetii*, *R. conorii*, *R. typhi*, and *R. prowazekii* [199]. Michon et al. described that 15 out of 27 patients with various cardiovascular diseases had BD. The BD patients displayed positive reactions in four patients for *R. prowazekii*, three patients for *R. typhi* (one of them was also positive for Proteus OX19), three patients for *C. burnetii*, one patient for both *R. prowazekii* and *R. typhi*, one patient for *R. conorii*, one patient for both *R. prowazekii* and *R. conorii*, one patient for both *R. prowazekii* and neorickettsia, and one patient for both *R. conorii* and neorickettsia. All 15 patients showed clinical improvement following antibiotic treatment [128].

In 1958, Bernard, Giroud, and Masbernard reviewed the relationship between juvenile arteritis and rickettsiosis at the Congress of Angiology [200, 201]. Bernard et al. presented seven patients with BD; three patients were seropositive for epidemic typhus, two patients for murine typhus, and two patients for Mediterranean spotted fever. The first case, previously reported separately [202], had no history of typhus, but had served the Foreign Legion for 5 years in Indochina and Algeria. After returning from Algeria, he suffered from superficial phlebitis and intermittent claudication. Trophic changes of both limbs and weak pulsation of the left radial artery were observed at presentation. Agglutinating antibody tests to *R. prowazekii* revealed high titers during a flare-up of BD, decreased after antibiotic treatment, and finally became negative with clearance of the symptoms. Biopsy of the affected vein revealed a typical pathological feature of BD. Rickettsial culture was attempted using mice to



reveal rickettsia-like organisms in lung tissue, but failed to cultivate them. The patient had been treated with chloramphenicol or chlortetracycline for 10 – 15 days for each course, seven courses over 2.5 years; sympathectomy, unilateral adrenalectomy, and excision of gangrenous lesions were also performed. The second case had resided in the Far East and Africa. In Morocco, he presented with phlebitis, claudication, and a positive agglutination to *R. mooseri*, which became negative after tetracycline treatment. The sixth patient was a Corsican who presented with vascular insufficiency in the lower extremity with a positive serologic reaction to *R. prowazekii*, followed by the involvement of the upper extremity. Five years later, myocardial infarction and minor cerebral symptoms occurred. A follow-up serological test was positive [203].

Ouradou and Comte suggested that typhus and juvenile arteritis were causally related, based on their experience in a Moroccan hospital. During the years between 1940 and 1956, when the hospital managed only Europeans, they observed only one case of juvenile arteritis, whereas from 1957-the hospital managed both Moroccans and Europeans and observed nine juvenile arteritis within a year. Arteritis occurred in Muslims rather than in Jews. Because Morocco was an endemic area of typhus, acute arteritis was a well-known complication of epidemic typhus, and typhus in endemic areas was often mild, they asserted that juvenile arteritis was a late manifestation of mild or inapparent typhus. The authors described seven cases of juvenile arteritis presenting with typical features of BD, although the patients had not suffered typhus-like illness and were not examined with any serologic tests [204]. Comte et al. reported the results of rickettsial agglutination tests in 36 patients with chronic thromboangiitis: 31 patients were reactive to rickettsiae, while only two of 26 sera of non-arterial diseases were reactive. Of the 31 seropositive patients, 13 patients were reactive to *R. prowazekii*, five to *R. typhi*, 13 to *C. burnetii*, and no case to *R. conorii* [205]. In 1961, they reviewed the cardiovascular characteristics of rickettsial infections and described various diagnostic methods. The Giroud's microagglutination test was interpreted as positive if it showed +1 or more agglutination to *R. prowazekii* at a titer of 1:320, to *R. typhi* and *R. conorii* at 1:160, to *C. burnetii* and neorickettsia (Q18) at 1:20. It was mentioned that children frequently showed asymptomatic seropositivity during the typhus epidemic, persistence of rickettsia in the body, recrudescence might occur in such subjects, and Brill's disease was a typical form of recrudescence. They also described that both Brill's disease and BD shared many features; therefore, these two diseases might be etiologically related. Therapy with antibiotics or possibly malariotherapy proposed by Corelli was emphasized [206].

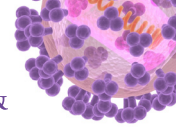
Chevat et al. reported a case of thrombophlebitis, in which a strain of neorickettsia was isolated. Giemsa staining of biopsy specimens from the vein showed clusters of rickettsia-like bodies at the junction of the media and the intima, and an antibody to Q18 was strongly positive. The patient was a 23-year-old man who had a history of varicose veins for 5 years, had served his military service in North Africa, and suffered recurrent phlebitis in the left leg and two episodes of pulmonary embolism four months after arrival in North Africa. As an agglutination test for neorickettsia was positive, chloramphenicol was added to anticoagulant therapy; his condition generally improved; however, edema and leg pain were partially attenuated [207, 208]. Rollier reported six cases of vascular diseases with positive rickettsial serologic results. The patients showed spontaneous mutilation of digits due to arteriolitis or migratory thrombophlebitis. Three patients were positive for Q fever, and the other three were positive for epidemic typhus. One patient with migratory thrombophlebitis showed a positive microagglutination test for historical typhus and was successfully treated with chloramphenicol and tetracycline [209]. Delanoe described 13 cases of various cardiovascular

diseases with positive serologic results for rickettsiosis. Two patients had arteritis—one who had myocardial infarction concomitantly was positive for *R. conorii* (1:320) and *R. prowazekii* (1:160), and the other patient for *R. prowazekii* (1:320) and *R. mooseri* (1:160) [210].

In 1959, Paul Giroud reviewed the vascular complications of rickettsiosis and neorickettsiosis. He mentioned a patient with BD who showed a high titer of agglutinating antibody to *R. prowazekii*. The skin test for epidemic typhus was also positive. Cultivation using yolk sac and intranasal mouse inoculation was attempted: rickettsia-like organisms were noticed until the third passage, but disappeared thereafter [211]. Giroud and Capponi presented their experiences of vascular complications in typhus fever and highlighted the possible relationship between arteritis and typhus. At the end of WWII, out of 1,592 sera from subjects with arteritis, 57 patients were positive for *R. prowazekii*, 58 patients for *R. mooseri*, 58 patients for *R. conorii*, 68 patients for *C. burnetii*, and 11 patients for neorickettsia (Bedsonia). In non-sick subjects, the percentage of positive results did not exceed 5.0% [212]. Giroud developed several diagnostic methods for rickettsiosis: sero-protection (serum neutralization), intradermal sero-protection, intradermal or skin, and rickettsial agglutination or slide microagglutination tests. The former three tests could detect past rickettsial infection, but had several limitations, whereas the last one detected the recent infection only and was used more widely. He also stressed the importance of serial measurement of rickettsial antibodies for differentiating true recrudescence from cross-reaction or simple serologic reactivation. Le Gag emphasized that one important factor in the diagnosis of chronic rickettsial and pararickettsial infections was “reactivation”. When a chronic rickettsial infection was suspected on clinical grounds, but the initial antibody test was negative, treatment with tetracycline for 4 days and a follow-up serum was tested 10 days later, which became positive in 65.0% – 80.0% of tested cases [213].

Martin and Cabanes reported a case of tsutsugamushi disease with coldness, walking difficulty, and no arterial pulsation of the left foot. A febrile illness occurred briefly and improved 1 month before the presentation. At the time of presentation, he was hospitalized because of fever, and dark gangrenous lesions developed a few days later. His serum was reactive to *Proteus OXK* at a titer of 1:600. He was treated with chloramphenicol, heparin, and cortisone, which improved the signs of vascular insufficiency over 1 month. One and a half months later, the arterial pulse became normal, and no residual gangrene was noticed. No arteriography or pathological examination was done [214]. Chippaux et al. reported six patients with thromboangiitis, who all had resided once in a rickettsia-endemic country (North Africa, Congo, or Indochina), and four of them were reactive to *C. burnetii* (2 patients), *Proteus OXK* (1 patient), or neorickettsia (1 patient) [215]. Bureau et al. reported a case of vasculitis that presented serially as digital ulcers and necroses at multiple sites, Raynaud's phenomenon, and purpura that progressed into bullous lesions followed by ulceration and necrosis. An agglutination test was positive for *R. typhi* at a titer of 1:320 and neorickettsia. A biopsy of the bullous lesion showed that the vessels revealed endothelial proliferation, thrombosis, laminated dissociation of the media, and infiltration of inflammatory cells in the media. The patient took tetracycline for 15 days; subsequently, flare-ups of the purpura ceased and the post-bullous ulcerations healed; however, the gangrene progressed to the entire toe [216].

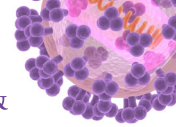
Several studies have investigated the efficacy of intraarterial infusion of tetracycline in BD and other obliterating vascular diseases. This method can achieve higher concentrations of the antibiotic at a local site and minimize the systemic toxicity. Bugar-Meszaros reported his experience with intraarterial administration of oxytetracycline in patients with gangrene



of the extremities. Out of eight patients with BD, seven patients improved markedly and one patient slightly; seven of 13 patients with arteriosclerosis and four of five patients with diabetic angiopathy improved markedly [217]. Lojacono reported the efficacy of this therapy in two patients with BD and 18 patients with arteriosclerosis; all the patients responded favorably to the therapy [218]. House reported that the intraarterial injection of tetracycline markedly improved digital gangrene in two patients with BD. One patient presented with paronychia and gangrenous changes in the fingers of both hands and toes. Initially, these abnormalities were managed with local dressing and injection of reserpine, but did not improve. Six months later, the intraarterial injection of tetracycline for 10 days, two times 4 weeks apart, improved the ischemic changes progressively. The removal or amputation of the necrotic bone was performed. The other patient presented with paronychia and gangrenous changes of the fingers and the left second toe. The injection of reserpine did not result in any improvement. One month later, tetracycline was injected intraarterially for 10 days, and this therapy resolved the gangrenous lesions. Six months later, the toe infection recurred and improved with an additional course of tetracycline therapy, but relapsed [219]. In 1990 and 1993, Gervaziev et al. reported the therapeutic efficacy of intraarterial infusion using microcrystal suspensions of heparin, oxytetracycline, and hydrocortisone in BD patients with excellent results [220, 221].

Bazex et al. reported a case of BD with a positive agglutination reaction to *R. prowazekii*. The patient was a 49-year-old man who had resided for 24 years in Alsace, France, where epidemic typhus occurred once. At the time of presentation, he complained of Raynaud's phenomenon and gangrenous lesions of the fingers and toes. An indurated venous cord and an arteriographic stenotic lesion in the left posterior tibial artery were observed. A microagglutination reaction to *R. prowazekii* was positive at a titer of 1:640. After tetracycline therapy, the symptoms worsened, and therefore, sympathectomy was performed. A follow-up antibody titer increased to 1:2,560, possibly by therapeutic "reactivation". Even after a third course of tetracycline therapy, the symptoms did not improve, and amputation of the forefoot was decided. The authors mentioned that antibiotic therapy was unable to remedy the anatomical and functional consequences of irreversible obliterating lesions [222]. Sassolas reported a case of Brill's disease complicated with pneumonia and vascular insufficiency of the feet that displayed violet color initially and progressed to dark necrosis later. Rickettsial agglutination reactions were positive for historical typhus. Penicillin, heparin, and a vasodilator rapidly improved the systemic, pulmonary, and toe signs [223].

Stefan S. Nicolau, a Romanian investigator, studied the presence of rickettsia and pararickettsia in several cardiovascular diseases, including BD. In 1961, he and colleagues reported that *C. burnetii* was isolated from a patient with DB [224]. In 1963, they investigated rickettsial infections (including *Coxiella* and *Chlamydia*) in patients with various cardiovascular diseases using serology, isolation of organisms, and histopathologic methods. Most isolates were *Coxiella* and pararickettsia [225]. Surdan et al. investigated rickettsial and pararickettsial antibodies in patients with various diseases including obliterating arteritis in Romania. Among 190 patients with obliterating arteritis, antibody positivity rates were 4.7% for *R. prowazekii*, 9.5% for *R. mooseri*, 18.4% for *R. conorii*, 10.0% for *C. burnetii*, and 8.9% for neorickettsia (Q18). Biopsy samples from the arteries and veins showed rickettsia-like bodies within the cytoplasm of reticulohistiocytes. Antibiotic therapy for 10 days, repeated at an interval of 15 to 30 days, showed favorable clinical responses and declining antibody titers [226]. Surdan and Sorodoc reviewed and summarized the results of investigations carried out by Nicolau and his colleagues [227].



Erel et al. described that a 45-year-old Turkish man, who was a non-smoker, had fever that lasted several days. Two months later, he felt coldness in his left hand and right foot; both left radial and right dorsalis pedis pulses were not palpated. A blood specimen, which was tested at the Pasteur Institute, showed a positive reaction to *R. prowazekii* at a titer of 1:320. Tetracycline and heparin were administered, and the arterial pulses became nearly normal after three weeks. The treatment was continued for additional three weeks. One month after discharge, the arterial pulses were normal [228]. Charmot et al. reported that five out of 69 military officers who had coronary heart disease or lower limb vasculitis showed positive microagglutination reactions to rickettsiae—two patients for scrub typhus, two for Q fever, and one for murine typhus. Regarding the patients with scrub typhus and vasculitis, one patient acquired scrub typhus in Far East Asia, and developed intermittent claudication 2 months later; 8 years after this infection, a microagglutination reaction was positive at a titer of 1:160 for scrub typhus. The other patient also showed a similar course, but the obstruction of the dorsalis pedis artery was observed. Giroud commented that the antigen used for the test might not be specific for use in the microagglutination test [229].

Constantinescu et al. reported that they experienced 1,760 typhus patients during the years 1944 to 1946, and 28 (1.6%) patients suffered thrombo-arteritis obliterans as a vascular complication during the illness. In addition, during follow-up of the patients for an extended period (15 – 19 years after suffering typhus), four patients developed thrombo-arteritis syndrome. Rickettsial infections were proven by increasing CF antibody titers after “reactivation” and by inoculation of the blood into guinea pigs whose CF tests became positive for *R. prowazekii* [230]. Florian reported patients with migratory thrombophlebitis or with thromboangiitis obliterans, all of whom showed positive rickettsial serologic results and good therapeutic responses to tetracycline. Of two patients with migratory phlebitis, one patient showed a positive antibody to *R. conorii* at a titer of 1:160 and a positive rickettsial culture of a biopsy specimen from the vein; the other patient showed a positive serology test for pararickettsia at a titer of 1:20. Each of three BD patients was positive for *C. burnetii* at 1:20, for *R. prowazekii* at 1:320, and for *R. typhi* and *R. conorii*, each at a titer of 1:160. Of two patients with both migratory phlebitis and BD, one patient was positive for *R. prowazekii* at 1:320, and the other patient was positive for *C. burnetii* at 1:20. Each of three patients with both myocardial infarction and BD was positive for *C. burnetii* at a titer of 1:20, for both *R. typhi* at 1:160 and pararickettsia at 1:20, and for *C. burnetii* at 1:20 [231]. Bologa and Lustig reported a girl aged 10 years who suffered vascular insufficiency of the right leg. Intermittent claudication and nocturnal pain developed 5 months prior to hospitalization. Arteriography revealed typical BD findings. Sera were examined by an agglutination method at the Institute of Virology in Bucharest, which were observed to be positive for *R. typhi* at 1:160, for pararickettsia at 1:20, and dubiously for *R. conorii* at 1:160. Tetracycline was administered in a cyclic manner, and the serologic test was repeated to be negative one year later. Additionally, her condition was normal and did not relapse at the check-up 1.5 years after onset [232].

Vlaicu conducted an investigation on rickettsial infections in 373 patients with chronic arteriopathies, including atherosclerotic (53.3%), BD (14.2%), and rickettsial (19 patients, 5.1%). Of 19 patients with chronic arteriopathy of rickettsial origin, five patients were positive for *R. conorii*, four patients were positive for *R. mooseri*, three patients were positive for both *R. conorii* and *R. mooseri*, five patients were positive for pararickettsia, one patient was positive for *C. burnetii*, and one patient was positive for *C. psittaci*. These 19 patients showed the following findings and shared many features of BD: young, male predominance, lower limb involvement, arterial obstruction with thrombosis, preceding or concomitant phlebitis, segmental vascular involvement, and pathologically endarteritis and periarteritis;

therapy with tetracycline improved clinical and oscillometric abnormalities and decreased the agglutination titers [233]. Dugois et al. reported ulceration of the toe and necrosis of the fingers in a patient with chronic psychosis and pulmonary tuberculosis. Microagglutination reactions showed positive results for *R. conorii* at titers of 1:320 to 1:5,120. Antibacterial therapy with cycline did not improve the ischemic lesions; therefore, sympathectomy and amputation of the toe were performed [234].

Schneider reported two patients with phlebitis migrans: one patient was reactive to *R. typhi* and the other patient to *R. conorii*. After tetracycline treatment, their illnesses improved and the serologic status became negative [235]. Benyahia et al. reported that no cases out of eight patients with BD were positive for *R. typhi* and *C. burnetii*. The serologic tests for other rickettsiae were not performed [236].

Michelangelo Bartolo insisted on the relationship between BD and rickettsial infection. In 1981, they used the modified Giroud's agglutination method to examine rickettsial antibodies in various vasculitides: in 31 cases of BD, this test showed positive results to *R. conorii* (3.2%), *C. burnetii* (41.9%), and *R. mooseri* (6.4%). They cited the Zardi's study result as a control, in which the antibody positivity rates were 1.1% for *C. burnetii* and 0.7% for *R. conorii* in 558 healthy persons, 4.6% for *C. burnetii*, 6.1% for *R. conorii*, 2.3% for neorickettsia, 0.5% for *R. typhi*, and 0.5% for *R. prowazekii* in 346 hospitalized patients in a psychiatric hospital [237,238]. In 1987, they performed a serological investigation in 70 patients with BD. Positive reactions to neorickettsia (Q18) (25.7%), *C. burnetii* (20.0%), *R. typhi* (18.6%), *R. conorii* (7.1%), and *R. prowazekii* (4.3%) were observed [239]. Allegra, who had co-worked with Bartolo and convinced the rickettsial etiology of BD, briefly summarized the antibiotic therapy of BD [240].

During the 2010s, Bahare Fazeli et al. published a series of articles on the various aspects of BD. In 2012, they identified rickettsial DNA in an amputated tissue obtained from a patient with BD [241], and demonstrated a high positive antibody rate (92.9%) to *R. rickettsii* in patients with BD in 2017 [242].

## BUERGER'S DISEASE AND SMOKING

If BD is a chronic rickettsial infection, the close relationship between BD and tobacco use can be easily explained by the fact that nicotine causes reversible vasoconstriction and therefore can aggravate vascular narrowing [243], as already stated by Allen et al. [9]. Ergotism is an example in which vasoconstriction alone can induce digital gangrene; however, this is not accompanied by inflammatory changes in the blood vessels. Cannabis appears to constrict the small vessels in fingers and toes and therefore is similar to nicotine and ergot alkaloids [244]. The pathological findings of "cannabis arteritis" were reported in only a few reports in which no inflammatory reaction was observed in one report and inflammatory one in the others [245-247]. This feature, as well as the following findings, suggests that "cannabis arteritis" is closer to ergotism on the one hand: frequent occurrence in women, bilateral involvement of the lower extremities, rapid progression to gangrene, and frequent visceral involvement (*i.e.*, myocardial infarction and cerebral stroke). On the other hand, the presence of migratory thrombophlebitis in a patient [247], which cannot be explained by vasoconstriction alone, suggests the presence of early BD in certain patients with "cannabis arteritis". The relationship between exposure to a cold environment and the aggravation of BD is likewise explainable as cold-induced vasoconstriction.

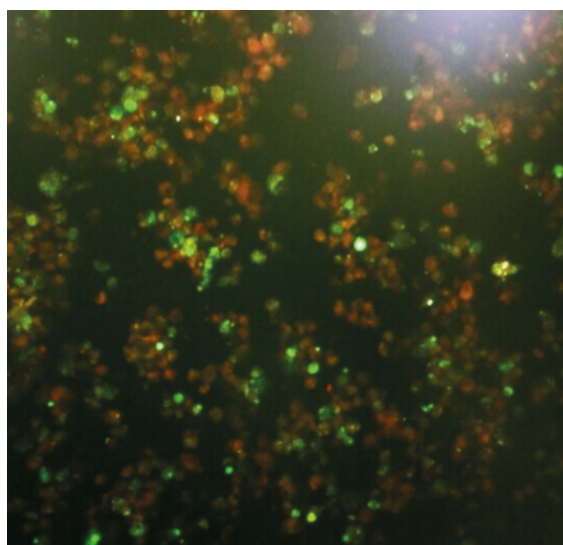
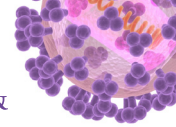


## ANTIBIOTIC THERAPY FOR BUERGER'S DISEASE

It is not our intention to describe in details antibiotic treatment of rickettsial infection, and we simply want to mention how efficacious its therapy is and why antibiotic therapy cannot cure BD. Chloramphenicol and tetracycline shorten the duration of fever and reduce the mortality rate in human rickettsial infection and tsutsugamushi disease, but cannot eradicate the organisms from animals and humans [146, 150]. Smadel et al. demonstrated the bacteriostatic effect of chloramphenicol in an experiment in which chloramphenicol was administered to three groups of experimentally infected mice, that is, none as a control, for 20 days, and for 100 days. Most mice in the control group died, whereas all mice in the chloramphenicol-treated groups survived; however, there was no difference between the latter two groups in the frequency of isolation and magnitude of *O. tsutsugamushi* in their blood and splenic tissues 30 to 100 days after the inoculation [248].

Antibiotic efficacy in BD has not been studied in a controlled manner; however, several cases, including our cases described below, showed good to excellent responses to chloramphenicol, tetracycline derivatives, and even penicillin in some patients. These responses in BD seem to be similar to those in rickettsial infection. Allen described that sulfanilamide, a sulfonamide antibiotic, was of value in the treatment of a subset of BD (*i.e.*, rapidly progressing one) [185]. Although penicillin is generally thought to be ineffective for the treatment of acute rickettsial infections, an *in vitro* experiment showed that penicillin G concentration of equal to or greater than 20 µg/mL is rapidly rickettsiacidal against intracellular *R. prowazekii*, whereas its concentration 50 times higher is ineffective against *O. tsutsugamushi* [249]. Penicillin reduces the mortality in experimental murine typhus in mice, and its efficacy is particularly marked when the amount of inoculum is relatively small [250]. Miyamura et al. reported an *in vitro* antibiotic susceptibility test in which *R. prowazekii*, *R. rickettsii*, and *R. sibirica* are susceptible to penicillin (1.0 mg/mL); however, *R. tsutsugamushi* is not [251]. Using cell culture and measurement of bacterial amounts by quantitative polymerase chain reaction, Rolain et al. reported that the minimal inhibitory concentrations of *R. conorii*, *R. typhi*, and *R. felis* to amoxicillin range from 128 – 256 µg/mL, which are similar to their previous reports using a plaque assay and Gimenez staining method [252]. Although there are some variations in the above results, considering that the method for antimicrobial susceptibility testing for *Rickettsia* and *Orientia* is still not standardized, it can be stated that penicillin may have an inhibitory effect against rickettsia. Furthermore, antimicrobial effects in experimental infection are better when the host cells are infected with a lower inoculum of *Rickettsia* or *Orientia* [250, 253]. If chronic rickettsial infections have a lower bacterial burden than acute infections, it can be hypothesized that penicillin has therapeutic efficacy against chronic rickettsial infections in humans. The following three cases are presented to illustrate the efficacy of doxycycline in BD.

Case 1 was a 42-year-old man who was first diagnosed with BD 7 years previously when an arteriogram showed a narrowed segment along the left femoral artery and occlusion of the proximal popliteal artery. He underwent a bypass graft operation at a university hospital. Thereafter, he was followed up by a surgeon with regular medication of pentoxifylline and a calcium-channel blocker. We saw him first in January 2015 when he had continued smoking, felt mild cold sensation in both feet only while working outdoors in winter, and showed no signs of vascular insufficiency. A blood specimen was taken, inoculated into a cell culture using the ECV304 cell line, and examined with NT-14, a monoclonal antibody directed against an epitope of the polysaccharide antigen of *O. tsutsugamushi* [254], which showed intracellular fluorescent foci 3 weeks after inoculation (Fig. 1). Because our laboratory was renovated



**Figure 1.** Immunofluorescence staining of culture cells three weeks after the inoculation of a blood specimen of case 1, which reacted with a monoclonal antibody against the polysaccharide antigen of *Orientia tsutsugamushi*, NT-14. Multiple fluorescence-positive foci are observed only within the cells ( $\times 200$ ).

at that time, the culture was discarded, and no further characterization of the cultured organism was possible. Therefore, it can be said that some intracellular bodies were present in the culture and possibly in the blood. Doxycycline (200 mg/day) was prescribed for 1 week, and the pain was completely reduced from day 3 after the initiation of antibiotic therapy. At the second visit, he had no pain and strongly wanted to use it again. Five months later, the patient returned to the hospital for a repeat prescription of doxycycline.

Case 2 was first observed in December 2015. The patient was a 46-year-old man who had lost his right lower leg due to a car accident when he was young. He had undergone sympathectomy for BD 15 years previously at a university hospital. He had smoked one pack daily and did not regularly take medications for BD. Six years previously, he complained of claudication of the left leg, and an angiogram revealed bilateral occlusions of the popliteal arteries. At the time of presentation to us in 2015, the patient complained of severe pain, diffuse swelling, coldness, and dusky discoloration of both hands. He refused further examinations or hospitalization. We prescribed doxycycline for 7 days; however, he did not return to the clinic. Hence, 3 days later we called him to ascertain whether any improvement occurred with the doxycycline therapy. He replied, "I am cured and have no pain." He might suffer from erythromelalgia and rest pain due to BD, which improved promptly with doxycycline therapy. Four years later he revisited the hospital because of the aforementioned symptoms.

Case 3 was a 44-year-old man whose BD was first diagnosed on admission in January 2017. He smoked 30 cigarettes per day and was a construction worker. Three weeks prior to hospitalization, he complained of pain in the right second finger, and subsequently in the right first and third fingers. On admission, superficial dark necrosis was observed in the second and third fingers. Angiography revealed absent tracing of the peripheral vessels of the right second and third fingers. The therapy with limaprost (an oral prostaglandin E1 analog), a calcium channel blocker, and analgesics began, cigarette smoking was discontinued, and doxycycline was added subsequently. Three days after the addition of doxycycline, the superficial necrosis remained stable, the pain was absent, and he was discharged from the hospital.

Based on the above findings, it can be said that the efficacy of doxycycline for the treatment of BD was excellent, at least in controlling the rest pain. Because rest pain refractory to narcotics is an indication for limb amputation, doxycycline may be used in this condition. As for its efficacy for vascular insufficiency, based on the literature, it may take a longer period until the abnormal signs improve, and the antibiotic should be administered for a more prolonged period. One caution is that acute vascular insufficiency may be resulted from the thrombotic or thrombo-fibrotic obstruction of the vessel and therefore cannot be improved with antibiotic therapy alone [222], and therefore thrombolytic or anticoagulation therapy should be considered in addition to antibiotic therapy.

## CONCLUSIONS

Several important articles are summarized as follows. Historical typhus and BD are related geographically [1, 101, 106, 173, 191, 204, 206]. Many patients with typhus in endemic areas are asymptomatic or experience only mild symptoms. Therefore, they cannot recognize their illness [92, 109-114, 206]. *Rickettsia* and *Orientia* infect vascular endothelial cells, causing thrombosis and gangrene [79]. These pathogens persist in humans [104, 139, 145, 146, 149, 150, 190]. BD can occur several years after recovery from typhus [191, 230]. The intradermal test to *R. prowazekii* is positive in most of the patients with BD [174]. Rickettsia DNA is identified in amputated limb tissues obtained from a BD patient [241]. Ligation of the veins in individuals who have a history of migratory thrombophlebitis produces bland thrombosis and triggers the acute characteristic inflammation of BD [61]. Antibiotic therapy improves ischemic manifestations of BD in many patients [128, 192, 194, 198, 203, 209, 217-219, 226, 231-233, 235] with a few exceptions [203, 216, 222, 234]. The addition of heparin to antibiotic therapy improves clinical features of acute vascular insufficiency [207, 214, 220, 221, 228].

Based on the above findings, we hypothesize the pathogenesis of BD as follows. BD patients acquired a rickettsial infection far before the onset of BD, and the rickettsiae infected endothelial cells of systemic vasculature in a scattered localized pattern, proliferated slowly, and were released to infect neighboring endothelial cells. The infected area expands circumferentially as well as longitudinally to become a segment of the infected vessel over years. As the number of endothelial cells with defects on their cell surfaces increases, these cells are predisposed to thrombosis. Subsequently, thrombus develops on and adhere to the luminal surface of the infected endothelial cells, and then is infected with the rickettsiae through its adherent part from these cells. As previous investigations suggest, the vessel with the infected thrombus evolves into a fibrous non-occluding or occluding vessel by cell-mediated immunity and other inflammatory reactions, in contrast to the resolution of vascular obstruction by thrombolysis in bland thrombosis. In conclusion, it is postulated that the aforementioned two-stage process, *i.e.*, *Rickettsia* or *Orientia* endangiitis and superimposed thrombosis, produces the major clinical manifestations of BD.

This hypothesis can explain the following findings: the close relationship of tobacco use and BD; occurrence of BD in non-smokers and its rarity among smokers; the relations of BD to cold, trauma, low socioeconomic status, and cannabis use; no relation of race, hypersensitivity, ergotism, and heredity to BD; the temporal trends and geographic concordance of BD and epidemic typhus; reported cases showing the relationship between BD and rickettsiosis; the systemic and benign natures of BD; the clinical courses of migratory thrombophlebitis, neuralgic pain, and ischemic vascular manifestations; pathologically,

the inflammatory thrombi, segmental involvement, endarteritis and periarteritis, and immunophenotypes of the infiltrating cells; the evidence of T cell-mediated immune reaction; failure of observing and isolating the causative bacteria in the studies hitherto that used staining and culture methods for ordinary bacteria; inconsistent results of all the diagnostic tests for rickettsiosis but the intradermal test; therapeutic efficacies of typhoid vaccination and malariotherapy possibly by enhanced non-specific immunity; excellent therapeutic responses to tetracycline, chloramphenicol, spiramycin, and doxycycline.

## ACKNOWLEDGMENT

We wish to thank Hyun-Dong Lee, M.D., Hanmaeum Hospital, and professor Kwang Sig Kim and assistant professor Woo Seong Jeong, Jeju National University Hospital, Jeju, for referral of and advices about the patients; associate professor Ji Hyeon Baek and assistant professor Jae-Hyeong Im, Inha University Hospital, Incheon, for conceptualization of recrudescence of *O. tsutsugamushi* infection; Hea Yoon Kwon, M.D. for preparation of the manuscript; members of the Research Information Sharing Service, of the National Diet Library, and of the Tohoku University Medical Library for reference service.

## REFERENCES

1. Buerger L. Thrombo-angiitis obliterans: a study of the vascular lesions leading to presenile spontaneous gangrene. *Am J Med Sci* 1908;136:567-80.  
[PUBMED](#) | [CROSSREF](#)
2. Buerger L. Recent studies in the pathology of thrombo-angiitis obliterans. *J Med Res* 1914;31:181-94.  
[PUBMED](#)
3. Buerger L. The circulatory disturbance of the extremities: including gangrene, vasomotor, and trophic disorders. Philadelphia: W.B. Saunders Co.; 1924;213-385.
4. Tanaka K. Pathology and pathogenesis of Buerger's disease. *Int J Cardiol* 1998;66 (Suppl 1):S237-42.  
[PUBMED](#) | [CROSSREF](#)
5. Kim EJ, Cho BS, Lee TS, Kim SJ, Seo JW. Morphologic change of the internal elastic lamina in Buerger's disease. *J Korean Med Sci* 2000;15:44-8.  
[PUBMED](#) | [CROSSREF](#)
6. Kobayashi M, Ito M, Nakagawa A, Nishikimi N, Nimura Y. Immunohistochemical analysis of arterial wall cellular infiltration in Buerger's disease (endarteritis obliterans). *J Vasc Surg* 1999;29:451-8.  
[PUBMED](#) | [CROSSREF](#)
7. Kurata A, Machinami R, Schulz A, Fukayama M, Franke FE. Different immunophenotypes in Buerger's disease. *Pathol Int* 2003;53:608-15.  
[PUBMED](#) | [CROSSREF](#)
8. Lee T, Seo JW, Sumpio BE, Kim SJ. Immunobiologic analysis of arterial tissue in Buerger's disease. *Eur J Vasc Endovasc Surg* 2003;25:451-7.  
[PUBMED](#) | [CROSSREF](#)
9. Allen EV, Barker NW, Hines EA Jr. *Peripheral vascular diseases*. 3rd ed. Philadelphia: W.B. Saunders Co.; 1962;343-85.
10. Kurata A, Schulz A, Franke FE. Reappraisal of thromboangiitis obliterans--a pathological contribution. *Verh Dtsch Ges Pathol* 2004;88:231-6.  
[PUBMED](#)
11. Kröger K. Buerger's disease: What has the last decade taught us? *Eur J Intern Med* 2006;17:227-34.  
[PUBMED](#) | [CROSSREF](#)
12. Iwai T, Kume H, Koizumi S, Sakurazawa K, Honma K, Ogasawara H, Takemura T, Kishino M, Kagayama T. [Buerger disease: pathological changes in elderly patients] (in Japanese). *J Jpn Coll Angiol* 2021;61:107-13.  
[CROSSREF](#)

13. Friedländer C. [On arteritis obliterans]. *Centralblatt für die medicinischen Wissenschaften* 1876;14:65-9. German.
14. von Winiwarter F. [On a peculiar form of endarteritis and endophlebitis with gangrene of the foot]. *Archiv für klinische]. Chirurgie* 1879;23:202-26. German.
15. Brown GE, Allen EV, Mahorner HR. *Thrombo-angiitis obliterans. Clinical, physiologic and pathologic studies.* Philadelphia: W.B. Sanders Co.; 1928.
16. Puéchal X, Fiessinger JN. Thromboangiitis obliterans or Buerger's disease: challenges for the rheumatologist. *Rheumatology (Oxford)* 2007;46:192-9.  
[PUBMED](#) | [CROSSREF](#)
17. Fakour F, Fazeli B. Visceral bed involvement in thromboangiitis obliterans: a systematic review. *Vasc Health Risk Manag* 2019;15:317-53.  
[PUBMED](#) | [CROSSREF](#)
18. Iwai T. Buerger's disease with intestinal involvement. *Int J Cardiol* 1998;66 (Suppl 1):S257-63; discussion S265.  
[PUBMED](#) | [CROSSREF](#)
19. Jablons B. Thrombo-angiitis obliterans. *International Clinics* 1925;3:193-232.
20. Kjeldsen K, Mozes M. Buerger's disease in Israel. Investigations on carboxyhemoglobin and serum cholesterol levels after smoking. *Acta Chir Scand* 1969;135:495-8.  
[PUBMED](#)
21. Adar R. Epidemiology of TAO--correction of an error. *Atherosclerosis* 2010;211:24.  
[PUBMED](#) | [CROSSREF](#)
22. Breidenbach WC Jr, Palmer DM. Thromboangitis obliterans in the Negro; report of a case and review of the literature. *Am Heart J* 1947;33:849-55.  
[PUBMED](#) | [CROSSREF](#)
23. Davis HA, King LD. A comparative study of thromboangiitis obliterans in white and Negro patients. *Surg Gynecol Obstet* 1947;85:597-603.  
[PUBMED](#)
24. Tavakoli H, Rezaii J, Esfandiari K, Salimi J, Rashidi A. Buerger's disease: a 10-year experience in Tehran, Iran. *Clin Rheumatol* 2008;27:369-71.  
[PUBMED](#) | [CROSSREF](#)
25. Laohapensang K, Rerkasem K, Kattipattanapong V. Seasonal variation of Buerger's disease in Northern part of Thailand. *Eur J Vasc Endovasc Surg* 2004;28:418-20.  
[PUBMED](#) | [CROSSREF](#)
26. Whyte GD. Thrombo-angiitis obliterans. *China Med J* 1917;31:371-8.
27. Allen EV, Brown GE. Thrombo-angiitis obliterans: a clinical study of 200 cases. I. etiology, pathology, symptoms, diagnosis. *Ann Intern Med* 1928;1:535-49.  
[CROSSREF](#)
28. Hill GL, Moeliono J, Tumewu F, Brataamadja D, Tohardi A. The Buerger syndrome in Java. A description of the clinical syndrome and some aspects of its aetiology. *Br J Surg* 1973;60:606-13.  
[PUBMED](#) | [CROSSREF](#)
29. Fazeli B. Buerger's disease as an indicator of socioeconomic development in different societies, a cross-sectional descriptive study in the North-East of Iran. *Arch Med Sci* 2010;6:343-7.  
[PUBMED](#) | [CROSSREF](#)
30. Fleshman K. Buerger's disease in Nepal. *Trop Doct* 1998;28:203-6.  
[PUBMED](#) | [CROSSREF](#)
31. Meyer W. Etiology of thrombo-angiitis obliterans (Buerger). *JAMA* 1918;71:1268-72.  
[CROSSREF](#)
32. Ohta T, Ishioashi H, Hosaka M, Sugimoto I. Clinical and social consequences of Buerger disease. *J Vasc Surg* 2004;39:176-80.  
[PUBMED](#) | [CROSSREF](#)
33. Makita S, Nakamura M, Murakami H, Komoda K, Kawazoe K, Hiramori K. Impaired endothelium-dependent vasorelaxation in peripheral vasculature of patients with thromboangiitis obliterans (Buerger's disease). *Circulation* 1996;94 (9 Suppl):II211-5.  
[PUBMED](#)
34. Brodmann M, Hafner F, Gary T, Seinost G, Pilger E. Impaired endothelial-dependent and endothelium-independent vasodilatation in patients with thromboangiitis obliterans. *Clin Appl Thromb Hemost* 2013;19:33-6.  
[PUBMED](#) | [CROSSREF](#)



35. Halacheva K, Gulubova MV, Manolova I, Petkov D. Expression of ICAM-1, VCAM-1, E-selectin and TNF-alpha on the endothelium of femoral and iliac arteries in thromboangiitis obliterans. *Acta Histochem* 2002;104:177-84.  
[PUBMED](#) | [CROSSREF](#)
36. Diehm C, Schäfer M. *Das Buerger-syndrom (Thromboangiitis obliterans): Geschichte, epidemiologie, pathologie, klinik, diagnostik und therapie*. Berlin: Springer; 1993.
37. Heper G, Kose S, Akkoc O, Amasyali B, Kilic A. Two female nonsmoker Buerger's disease cases with anticardiolipin autoantibodies and a poor prognosis. *Int Heart J* 2005;46:563-9.  
[PUBMED](#) | [CROSSREF](#)
38. Lie JT. Thromboangiitis obliterans (Buerger's disease) in an elderly man after cessation of cigarette smoking--a case report. *Angiology* 1987;38:864-7.  
[PUBMED](#) | [CROSSREF](#)
39. Stojanovic VK, Marcovic A, Arsov V, Bujanic J, Lotina S. Clinical course and therapy of Buerger's disease. *J Cardiovasc Surg (Torino)* 1973;14:5-8.  
[PUBMED](#)
40. Watanabe Y, Miyata T, Shigematsu K, Tanemoto K, Nakaoka Y, Harigai M; Japan Research Committee of the Ministry of Health, Labour, and Welfare for Intractable Vasculitis (JPVAS). Current trends in epidemiology and clinical features of thromboangiitis obliterans in Japan - A nationwide survey using the medical support system database. *Circ J* 2020;84:1786-96.  
[PUBMED](#) | [CROSSREF](#)
41. Lie JT. Thromboangiitis obliterans (Buerger's disease) revisited. *Pathol Annu* 1988;23:257-91.  
[PUBMED](#)
42. Lie JT. The rise and fall and resurgence of thromboangiitis obliterans (Buerger's disease). *Acta Pathol Jpn* 1989;39:153-8.  
[PUBMED](#) | [CROSSREF](#)
43. Enstrom JE. Trends in mortality among California physicians after giving up smoking: 1950-79. *Br Med J (Clin Res Ed)* 1983;286:1101-5.  
[PUBMED](#) | [CROSSREF](#)
44. Durkin S, Brennan E, Wakefield M. Mass media campaigns to promote smoking cessation among adults: an integrative review. *Tob Control* 2012;21:127-38.  
[PUBMED](#) | [CROSSREF](#)
45. Wessler S, Ming SC, Gurewich V, Freiman DG. A critical evaluation of thromboangiitis obliterans. The case against Buerger's disease. *N Engl J Med* 1960;262:1149-60.  
[PUBMED](#) | [CROSSREF](#)
46. Eisen ME. Coexistence of thromboangiitis obliterans and arteriosclerosis: relationship to smoking. *J Am Geriatr Soc* 1966;14:846-58.  
[PUBMED](#) | [CROSSREF](#)
47. Matsushita M, Nishikimi N, Sakurai T, Nimura Y. Decrease in prevalence of Buerger's disease in Japan. *Surgery* 1998;124:498-502.  
[PUBMED](#) | [CROSSREF](#)
48. McPherson JR, Juergens JL, Gifford RW Jr. Thromboangiitis obliterans and arteriosclerosis obliterans. Clinical and prognostic differences. *Ann Intern Med* 1963;59:288-96.  
[PUBMED](#) | [CROSSREF](#)
49. Le Joncour A, Soudet S, Dupont A, Espitia O, Koskas F, Cluzel P, Hatron PY, Emmerich J, Cacoub P, Resche-Rigon M, Lambert M, Saadoun D; French Buerger's Network. French Buerger's Network. Long-term outcome and prognostic factors of complications in thromboangiitis obliterans (Buerger's Disease): A multicenter study of 224 patients. *J Am Heart Assoc* 2018;7:e010677.  
[PUBMED](#) | [CROSSREF](#)
50. Cooper LT, Tse TS, Mikhail MA, McBane RD, Stanson AW, Ballman KV. Long-term survival and amputation risk in thromboangiitis obliterans (Buerger's disease). *J Am Coll Cardiol* 2004;44:2410-1.  
[PUBMED](#) | [CROSSREF](#)
51. Sugimoto M, Miyachi H, Morimae H, Kodama A, Narita H, Banno H, Yamamoto K, Komori K. Fate of ischemic limbs in patients with Buerger's disease based on our 30-year experience: does smoking have a definitive impact on the late loss of limbs? *Surg Today* 2015;45:466-70.  
[PUBMED](#) | [CROSSREF](#)
52. Ohta T, Shionoya S. Fate of the ischaemic limb in Buerger's disease. *Br J Surg* 1988;75:259-62.  
[PUBMED](#) | [CROSSREF](#)
53. Ohta T, Ishibashi H, Sugimoto I, Iwata H, Kawanishi J, Yamada T, Tadakoshi M, Hida N. The clinical course of buerger's disease. *Ann Vasc Dis* 2008;1:85-90.  
[PUBMED](#) | [CROSSREF](#)

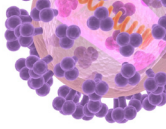
54. Soudet S, Le Joncour A, Quemeneur T, Maillard H, Koskas F, Hachulla E, Cacoub P, Yelnik CM, Saadoun D, Lambert M. Did the clinical spectrum of thromboangiitis obliterans change in the past 40 years? *Angiology* 2020;71:621-5.  
[PUBMED](#) | [CROSSREF](#)
55. Olin JW, Young JR, Graor RA, Ruschhaupt WF, Bartholomew JR. The changing clinical spectrum of thromboangiitis obliterans (Buerger's disease). *Circulation* 1990;82 (5 Suppl):IV3-8.  
[PUBMED](#)
56. Cornelius ME, Wang TW, Jamal A, Loretan CG, Neff LJ. Tobacco product use among adults - United States, 2019. *MMWR Morb Mortal Wkly Rep* 2020;69:1736-42.  
[PUBMED](#) | [CROSSREF](#)
57. Adler I, Hensel O. Intravenous injections of nicotine and their effects upon the aorta of rabbits. *J Med Res* 1906;15:229-40.  
[PUBMED](#)
58. Lawrence PF, Lund OI, Jimenez JC, Muttalib R. Substitution of smokeless tobacco for cigarettes in Buerger's disease does not prevent limb loss. *J Vasc Surg* 2008;48:210-2.  
[PUBMED](#) | [CROSSREF](#)
59. Grotenhermen F. Cannabis-associated arteritis. *Vasa* 2010;39:43-53.  
[PUBMED](#) | [CROSSREF](#)
60. Berger L. Is thrombo-angiitis obliterans an infectious disease? *Surg Gynecol Obstet* 1914;19:582-8.
61. Buerger L. Thrombo-angiitis obliterans. *Arch Pathol* 1929;7:381-90.
62. Rabinowitz HM. Experiments on the infectious origin of thrombo-angiitis obliterans and the isolation of a specific organism from the blood stream. *Surg Gynecol Obstet* 1923;37:350-60.
63. Horton BT, Dorsey AHE. Experimental thrombo-angiitis obliterans: bacteriologic and pathologic studies. *Arch Pathol Lab Med* 1932;13:910-25.
64. Lake CF, Logan GB, Peters GA. Treatment of ragweed hay fever with powdered hydrocortisone applied intranasally. *Proc Staff Meet Mayo Clin* 1957;32:641-4.  
[PUBMED](#)
65. Weber FP. Non-syphilitic arteritis obliterans ("Thrombo-angiitis" of Leo Buerger), with gangrene of toes. Remarks on the occasional connexion with traumata. *Proc R Soc Med* 1915;8:49-52.  
[PUBMED](#) | [CROSSREF](#)
66. Orr TG. Thrombo-angiitis obliterans. *South Med J* 1928;21:563-8.  
[CROSSREF](#)
67. Chen YW, Iwai T, Umeda M, Nagasawa T, Huang Y, Takeuchi Y, Ishikawa I. Elevated IgG titers to periodontal pathogens related to Buerger disease. *Int J Cardiol* 2007;122:79-81.  
[PUBMED](#) | [CROSSREF](#)
68. Iwai T, Inoue Y, Umeda M, Huang Y, Kurihara N, Koike M, Ishikawa I. Oral bacteria in the occluded arteries of patients with Buerger disease. *J Vasc Surg* 2005;42:107-15.  
[PUBMED](#) | [CROSSREF](#)
69. Igari K, Inoue Y, Iwai T. An experimental model of peripheral vascular disease involving the intravenous injection of oral bacteria. *Ann Vasc Dis* 2016;9:267-71.  
[PUBMED](#) | [CROSSREF](#)
70. Iwai T, Umeda M, Inoue Y. Are there any objections against our hypothesis that Buerger disease is an infectious disease? *Ann Vasc Dis* 2012;5:300-9.  
[PUBMED](#) | [CROSSREF](#)
71. Thompson KW. The relationship of dermatomycoses to certain peripheral vascular infections. *International Clinics* 1941;2:156-70.
72. Naide M. The causative relationship of dermatophytosis to thromboangiitis obliterans. *Am J Med Sci* 1941;202:822-31.  
[CROSSREF](#)
73. Raoult D, Fournier PE, Eremeeva M, Graves S, Kelly PJ, Oteo JA, Sekeyova Z, Tamura A, Tarasevich I, Zhang L. Naming of rickettsiae and rickettsial diseases. *Ann N Y Acad Sci* 2005;1063:1-12.  
[PUBMED](#) | [CROSSREF](#)
74. Parola P, Paddock CD, Socolovschi C, Labruna MB, Mediannikov O, Kernif T, Abdad MY, Stenos J, Bitam I, Fournier PE, Raoult D. Update on tick-borne rickettsioses around the world: a geographic approach. *Clin Microbiol Rev* 2013;26:657-702.  
[PUBMED](#) | [CROSSREF](#)
75. Diop A, El Karkouri K, Raoult D, Fournier PE. Genome sequence-based criteria for demarcation and definition of species in the genus *Rickettsia*. *Int J Syst Evol Microbiol* 2020;70:1738-50.  
[PUBMED](#) | [CROSSREF](#)

76. Tamura A, Ohashi N, Urakami H, Miyamura S. Classification of *Rickettsia tsutsugamushi* in a new genus, *Orientia* gen. nov., as *Orientia tsutsugamushi* comb. nov. Int J Syst Bacteriol 1995;45:589-91.  
[PUBMED](#) | [CROSSREF](#)
77. Grayston JT, Kuo CC, Wang SP, Altman J. A new Chlamydia psittaci strain, TWAR, isolated in acute respiratory tract infections. N Engl J Med 1986;315:161-8.  
[PUBMED](#) | [CROSSREF](#)
78. Osterloh A. Immune response against rickettsiae: lessons from murine infection models. Med Microbiol Immunol 2017;206:403-17.  
[PUBMED](#) | [CROSSREF](#)
79. Wolbach SB, Todd JL, Palfrey FW, and League of Red Cross Societies. Typhus Research Commission to Poland. The etiology and pathology of typhus: being the main report of the Typhus Research Commission of the League of Red Cross Societies to Poland. Cambridge, Massachusetts: the League of Red Cross Societies at the Harvard University Press; 1922.
80. Moron CG, Popov VL, Feng HM, Wear D, Walker DH. Identification of the target cells of *Orientia tsutsugamushi* in human cases of scrub typhus. Mod Pathol 2001;14:752-9.  
[PUBMED](#) | [CROSSREF](#)
81. Allen AC, Spitz S. A comparative study of the pathology of scrub typhus (*Tsutsugamushi* disease) and other rickettsial diseases. Am J Pathol 1945;21:603-81.  
[PUBMED](#)
82. Mendell TH. Scrub typhus fever (*Tsutsugamushi* disease) in New Guinea; report of 75 cases. Am J Med Sci 1946;211:9-22.  
[PUBMED](#) | [CROSSREF](#)
83. Lee JS, Park MY, Kim YJ, Kil HI, Choi YH, Kim YC. Histopathological features in both the eschar and erythematous lesions of *Tsutsugamushi* disease: identification of CD30+ cell infiltration in *Tsutsugamushi* disease. Am J Dermatopathol 2009;31:551-6.  
[PUBMED](#) | [CROSSREF](#)
84. Jang MS, Park JB, Lee KH, Jang JY, Yang MH, Kim JH, Hwangbo H, Lee TG, Suh KS. Histopathologic finding of perieschar lesions in *Tsutsugamushi* disease shows lymphocytic vasculitis mimicking angiocentric lymphoma. Ann Dermatol 2018;30:29-35.  
[PUBMED](#) | [CROSSREF](#)
85. Kawamura R. Studies on tsutsugamushi disease (Japanese flood fever). Cincinnati: Spokesman Printing Co; 1926.
86. Jang MS, Park JB, Lee KH, Jang JY, Yang MH, Kim JH, Hwangbo H, Lee TG, Suh KS. Histopathologic finding of perieschar lesions in *Tsutsugamushi* disease shows lymphocytic vasculitis mimicking angiocentric lymphoma. Ann Dermatol 2018;30:29-35.  
[PUBMED](#) | [CROSSREF](#)
87. Paris DH, Phetsouvanh R, Tanganuchitcharnchai A, Jones M, Jenjaroen K, Vongsouvat M, Ferguson DP, Blacksell SD, Newton PN, Day NP, Turner GD. *Orientia tsutsugamushi* in human scrub typhus eschars shows tropism for dendritic cells and monocytes rather than endothelium. PLoS Negl Trop Dis 2012;6:e1466.  
[PUBMED](#) | [CROSSREF](#)
88. Walker DH, Occhino C, Tringali GR, Di Rosa S, Mansueto S. Pathogenesis of rickettsial eschars: the tache noire of boutonneuse fever. Hum Pathol 1988;19:1449-54.  
[PUBMED](#) | [CROSSREF](#)
89. Vyas NS, Shieh WJ, Phelps RG. Investigating the histopathological findings and immunolocalization of rickettsialpox infection in skin biopsies: A case series and review of the literature. J Cutan Pathol 2020;47:451-8.  
[PUBMED](#) | [CROSSREF](#)
90. Tappe D, Booken N, Böer-Auer A, Rauch J, Schmiedel S, Reich K. Histology and serum cytokine responses in an Imported *Rickettsia slovaca* Infection, Germany. Am J Trop Med Hyg 2018;98:248-51.  
[PUBMED](#) | [CROSSREF](#)
91. Feng H, Popov VL, Yuoh G, Walker DH. Role of T lymphocyte subsets in immunity to spotted fever group Rickettsiae. J Immunol 1997;158:5314-20.  
[PUBMED](#)
92. Bourgeois AL, Olson JG, Fang RC, Huang J, Wang CL, Chow L, Bechthold D, Dennis DT, Coolbaugh JC, Weiss E. Humoral and cellular responses in scrub typhus patients reflecting primary infection and reinfection with *Rickettsia tsutsugamushi*. Am J Trop Med Hyg 1982;31:532-40.  
[PUBMED](#) | [CROSSREF](#)
93. Hauptmann M, Kolbaum J, Lilla S, Wozniak D, Gharaibeh M, Fleischer B, Keller CA. Protective and pathogenic roles of CD8+ T lymphocytes in murine *Orientia tsutsugamushi* infection. PLoS Negl Trop Dis 2016;10:e0004991.  
[PUBMED](#) | [CROSSREF](#)

94. Nacy CA, Osterman JV. Host defenses in experimental scrub typhus: role of normal and activated macrophages. *Infect Immun* 1979;26:744-50.  
[PUBMED](#) | [CROSSREF](#)
95. Ricketts HT, Gomez L. Studies on immunity in Rocky Mountain spotted fever. First communication. *J Infect Dis* 1908;5:221-44.  
[CROSSREF](#)
96. Nicolle C, Comte C, Conceil E. [Experimental transmission of exanthematic typhus through body lice] [French.]. *C R Hebd Seances Acad Sci* 1909;149:486-9.
97. da Rocha-Lima H. [On the etiology of typhus fever]. *Berliner. Klin Wochenschr* 1916;53:567-9. German.
98. Watanabe M. [An outbreak of epidemic louse-borne typhus in Tokyo 1914: a study on the prevention of epidemics]. *Nihon Ishigaku Zasshi* 2002;48:597-616.
99. Ludlow AI. Thrombo-angiitis obliterans. A review and report of the disease in Koreans. *China Med J* 1931;45:487-514.
100. Koyano K. A clinical study of one hundred twenty cases of thromboangiitis obliterans among the Japanese. *Acta Sch Med Univ Kioto* 1922;4:489-510.
101. Zinsser H. Varieties of typhus virus and the epidemiology of the American form of European typhus fever (Brill's disease). *Am J Hyg* 1934;20:513-32.  
[CROSSREF](#)
102. Sigel MM, Weiss LB, Blumberg N, Doane JC. Survey of epidemic typhus antibody levels in bloods of individuals born in Eastern and Central Europe and the United States. *Am J Med Sci* 1952;223:429-32.  
[PUBMED](#) | [CROSSREF](#)
103. Schaefer GL, Friedman M, Lewis C. The incidence of epidemic typhus antibodies in individuals born in Eastern Europe. *Ann Intern Med* 1955;42:979-82.  
[PUBMED](#) | [CROSSREF](#)
104. Price WH. Studies on the interepidemic survival of louse borne epidemic typhus fever. *J Bacteriol* 1955;69:106-7.  
[PUBMED](#) | [CROSSREF](#)
105. Brill NE. A study of 17 cases of a disease clinically resembling typhoid fever, but without the Widal reaction; together with a short review of the present status of the serodiagnosis of typhoid fever. *New York M J* 1898;67:48-54, 77-82.
106. Brill NE. An acute infectious disease of unknown origin; a clinical study based on 221 cases. *Am J Med* 1952;13:533-41.  
[PUBMED](#) | [CROSSREF](#)
107. Brill NE. Pathological and experimental data derived from a further study of an acute infectious disease of unknown origin. *Am J Med Sci* 1911;142:196-218.  
[CROSSREF](#)
108. Murray ES, Cohen S, Jampol J, Ofstrock A, Snyder JC. Epidemic-typhus antibodies in human subjects in Boston, Massachusetts. *N Engl J Med* 1952;246:355-9.  
[PUBMED](#) | [CROSSREF](#)
109. Shishido A, Hikita M, Kitaka M. [A study on inapparent infection of scrub typhus in Japan. III. Serological survey of mild febrile diseases on inapparent infection of scrub typhus]. *J Japanese Ass Infect Dis* 1963;37:130-5. Japanese.
110. Graf PC, Chretien JP, Ung L, Gaydos JC, Richards AL. Prevalence of seropositivity to spotted fever group rickettsiae and *Anaplasma phagocytophilum* in a large, demographically diverse US sample. *Clin Infect Dis* 2008;46:70-7.  
[PUBMED](#) | [CROSSREF](#)
111. Montoya JA, Jordan ME, Kvamme L, Quiros C, Fox JP. A survey of sero-immunity against epidemic typhus among certain population groups in Peru. *Am J Hyg* 1955;62:255-69.  
[PUBMED](#)
112. Mansueto S, Tringali G, Di Leo R, Maniscalco M, Montenegro MR, Walker DH. Demonstration of spotted fever group rickettsiae in the tache noire of a healthy person in Sicily. *Am J Trop Med Hyg* 1984;33:479-82.  
[PUBMED](#) | [CROSSREF](#)
113. Park JH, Gill B, Acharya D, Yoo SJ, Lee K, Lee J. Seroprevalence and Factors Associated with Scrub Typhus Infection among Forestry Workers in National Park Offices in South Korea. *Int J Environ Res Public Health* 2021;18:3131.  
[PUBMED](#) | [CROSSREF](#)
114. Kim YH, Hyun W, Kim DP, Chung MH, Im JH, Baek JH, Lee JS, Kang JS. The eschar size and early inoculation lesion of *Tsutsugamushi* disease on Jeju Island, Korea. *Infect Chemother* 2019;51:345-54.  
[PUBMED](#) | [CROSSREF](#)

115. Paddock CD, Sumner JW, Comer JA, Zaki SR, Goldsmith CS, Goddard J, McLellan SL, Tamminga CL, Ohl CA. *Rickettsia parkeri*: a newly recognized cause of spotted fever rickettsiosis in the United States. Clin Infect Dis 2004;38:805-11.  
[PUBMED](#) | [CROSSREF](#)
116. Kawamura A Jr, Murata M, Osono M, Nogami S, Shirasaka A, Tanaka H, Sudo K, Suzuki K, Miyairi T, Kijima H. Studies on inapparent infection of *tsutsugamushi* disease in Izu Shichito Islands: seroepidemiology and demonstration of an avirulent *Rickettsia* strain for mice. Jpn J Exp Med 1980;50:91-105.  
[PUBMED](#)
117. McQuiston JH, Knights EB, Demartino PJ, Paparello SF, Nicholson WL, Singleton J, Brown CM, Massung RF, Urbanowski JC. Brill-Zinsser disease in a patient following infection with sylvatic epidemic typhus associated with flying squirrels. Clin Infect Dis 2010;51:712-5.  
[PUBMED](#) | [CROSSREF](#)
118. Turiaf J, Battesti JP. [Acute pneumopathies, "solitary recurrences" of typhus]. Poumon Coeur 1964;20:903-15. French.  
[PUBMED](#)
119. Donzelot E, Kaufmann H, Escalle JE. [The negative blood culture form of subacute infectious endocarditis (Osler's disease)]. Presse Med 1947;55:337. French.  
[PUBMED](#)
120. Camelin G, Garnung , Vigneau , Forestier . [Malignant infectious aortic sigmoiditis with negative penicillin-resistant blood cultures]. Presse Med 1947;55:870-1. French.  
[PUBMED](#)
121. Donzelot E, Kaufmann H, Vernant P. [Primary subacute infective endocarditis; its relationship to exanthematic typhus]. Bull Mem Soc Med Hop Paris 1950;66:379-86. French.
122. Worms R. Rickettsial endocarditis. BMJ 1963;2:745-6.  
[CROSSREF](#)
123. Worms R, Péquignot H, Held JP. [Primary subacute infective endocarditis and exanthematic typhus]. Bull Mem Soc Med Hop Paris 1950;66:412-4. French.
124. Cattan R, Carasso R, Frumusan P, Cotoni P, Weill-Fage JC. [Infective endocarditis and exanthematous typhus; 2 new cases treated with aureomycin]. Bull Mem Soc Med Hop Paris 1950;66:1473-9. French.  
[PUBMED](#)
125. Faure . [Infectious endocarditis and exanthematous typhus]. J Med Bord 1952;129:840-3. French.
126. Baylon H, Bloch F, Giroud P, Coumel H. [The cardiovascular manifestations and the evolution of rickettsial diseases]. Bull Mem Soc Med Hop Paris 1952;68:67-72. French.  
[PUBMED](#)
127. Cauvin L, Tasque P, Languillon J. [Primary subacute bacterial endocarditis and rickettsial diseases; rapid recovery with rovamycin]. Bull Soc Pathol Exot 1956;49:786-9. French.
128. Michon P, Giroud P, Mathieu L, Bernard JG, Larcan A, Huriet C. [Rickettsiosis & cardiovascular diseases; concerning 27 observations]. Bull Mem Soc Med Hop Paris 1959;75:23-32. French.  
[PUBMED](#)
129. Justin-Besancon L, Cornet A, Giroud P. [Intestinal manifestations in a former typhus patient; serological syndrome of typhus]. Bull Mem Soc Med Hop Paris 1951;67:1167-74. French.  
[PUBMED](#)
130. Philip CB, Parker RR. The persistence of the viruses of endemic (murine) typhus, Rocky Mountain spotted fever, and boutonneuse fever in tissues of experimental animals. Public Health Rep 1938;53:1246-51.  
[CROSSREF](#)
131. Benoist F, Giroud P, Heraud G. [Recurrent murine typhus]. Bull Mem Soc Med Hop Paris 1954;70:158-62. French.  
[PUBMED](#)
132. Benoist F, Giroud P, Heraud G, Lelievre A. [Murine typhus and its recurrence]. Bull Mem Soc Med Hop Paris 1957;73:248-50. French.  
[PUBMED](#)
133. Ledru J, Bonnet-Eymard J, Rachail M. [Attenuated forms of rickettsial infections, recurrences, anamnestic reactions. (Apropos of 19 clinical cases)]. J Med Lyon 1964;45:2093-9. French.  
[PUBMED](#)
134. Lamotte M, Labrousse C, Rozenbaum H, Normand JP. [Myopericarditis with relapses related to murine typhus]. Sem Hop 1965;41:518-22. French.  
[PUBMED](#)
135. Rauber G, Pernot C, Cuny G, Larcan A, Peters A. [Primary malignant inflammation of the semilunar valves; 4 new case reports; possible etiological role of rickettsial diseases]. Rev Med Nancy 1957;82:798-812. French.  
[PUBMED](#)





136. Austin SM, Smith SM, Co B, Coppel IG, Johnson JE. Serologic evidence of acute murine typhus infection in a patient with culture-negative endocarditis. *Am J Med Sci* 1987;293:320-3.  
[PUBMED](#) | [CROSSREF](#)
137. Buchs AE, Zimlichman R, Sikuler E, Goldfarb B. Murine typhus endocarditis. *South Med J* 1992;85:751-3.  
[PUBMED](#) | [CROSSREF](#)
138. Espino Barros Palau A, Morgan ML, Lee AG. Bilateral optic atrophy in endemic typhus. *Can J Ophthalmol* 2014;49:e90-2.  
[PUBMED](#) | [CROSSREF](#)
139. Parker RT, Menon PG, Merideth AM, Snyder MJ, Woodward TE. Persistence of *Rickettsia rickettsii* in a patient recovered from Rocky Mountain spotted fever. *J Immunol* 1954;73:383-6.  
[PUBMED](#)
140. Hove MG, Walker DH. Persistence of rickettsiae in the partially viable gangrenous margins of amputated extremities 5 to 7 weeks after onset of Rocky Mountain spotted fever. *Arch Pathol Lab Med* 1995;119:429-31.  
[PUBMED](#)
141. Cartagenova L, Agnese A. [Primary pneumopathy in Mediterranean exanthematous fever]. *Minerva Pediatr* 1952;4:979. Italian.  
[PUBMED](#)
142. Ardaillou A, Deparis M, Giroud P, Sarrazin A. [Atypical pneumonia caused by Mediterranean exanthematous fever]. *Rev Prat* 1956;6:3025-6. French.  
[PUBMED](#)
143. Fox JP. The long persistence of *Rickettsia orientalis* in the blood and tissues of infected animals. *J Immunol* 1948;59:109-14.  
[PUBMED](#)
144. Shirai A, Chan TC, Gan E, Huxsoll DL. Persistence and reactivation of *Rickettsia tsutsugamushi* infections in laboratory mice. *Jpn J Med Sci Biol* 1979;32:179-84.  
[PUBMED](#) | [CROSSREF](#)
145. Kawamura R, Fukuzumi S, Nishinarita F, Yamashina A, Watanabe S, Obata Y. [On rickettsiosis and immunity]. *Nippon Igaku* 1947;(3414):103-5. Japanese.
146. Smadel JE, Ley HL Jr, Diercks RH, Cameron JAP. Persistence of *Rickettsia tsutsugamushi* in tissues of patients recovered from scrub typhus. *Am J Hyg* 1952;56:294-302.  
[PUBMED](#)
147. Kawamura R, Ueda M. On the treatment of general paresis with the Pescadores strain of tsutsugamushi disease. *Kitasato Arch Exp Med* 1939;16:183-99.
148. Kawamura R, Kasahara S, Toyama T, Nishinarita F, Tsubaki S. On the prevention of tsutsugamushi. Results of preventive inoculation for people in the endemic region, and laboratory tests with the Pescadores strain. *Kitasato Arch Exp Med* 1939;16:93-109.
149. Hayashi H, Watanabe M. On the possibility of appearance of rickettsiae in the circulating blood after the recovery of rickettsiosis. *Kitasato Arch Exp Med* 1948;21:135-41.
150. Chung MH, Lee JS, Baek JH, Kim M, Kang JS. Persistence of *Orientia tsutsugamushi* in humans. *J Korean Med Sci* 2012;27:231-5.  
[PUBMED](#) | [CROSSREF](#)
151. Lee HW, Cho PY, Moon SU, Na BK, Kang YJ, Sohn Y, Youn SK, Hong Y, Kim TS. Current situation of scrub typhus in South Korea from 2001-2013. *Parasit Vectors* 2015;8:238.  
[PUBMED](#) | [CROSSREF](#)
152. Park JW, Yu DS, Lee GS, Seo JJ, Chung JK, Lee JI. Epidemiological characteristics of rodents and chiggers with *Orientia tsutsugamushi* in the Republic of Korea. *Korean J Parasitol* 2020;58:559-64.  
[PUBMED](#) | [CROSSREF](#)
153. Seo MG, Song BG, Kim TK, Noh BE, Lee HS, Lee WG, Lee HI. Nationwide incidence of chigger mite populations and molecular detection of *Orientia tsutsugamushi* in the Republic of Korea, 2020. *Microorganisms* 2021;9:1563.  
[PUBMED](#) | [CROSSREF](#)
154. Kim DM, Kim SW, Choi SH, Yun NR. Clinical and laboratory findings associated with severe scrub typhus. *BMC Infect Dis* 2010;10:108.  
[PUBMED](#) | [CROSSREF](#)
155. Park JH, Kim SJ, Youn SK, Park K, Gwack J. Epidemiology of scrub typhus and the eschars patterns in South Korea from 2008 to 2012. *Jpn J Infect Dis* 2014;67:458-63.  
[PUBMED](#) | [CROSSREF](#)

156. Kinoshita H, Arima Y, Shigematsu M, Sunagawa T, Saijo M, Oishi K, Ando S. Descriptive epidemiology of rickettsial infections in Japan: Scrub typhus and Japanese spotted fever, 2007-2016. *Int J Infect Dis* 2021;105:560-6.  
[PUBMED](#) | [CROSSREF](#)
157. Ogawa M, Hagiwara T, Kishimoto T, Shiga S, Yoshida Y, Furuya Y, Kaiho I, Ito T, Nemoto H, Yamamoto N, Masukawa K. Scrub typhus in Japan: epidemiology and clinical features of cases reported in 1998. *Am J Trop Med Hyg* 2002;67:162-5.  
[PUBMED](#) | [CROSSREF](#)
158. Yotsukura M, Aoki N, Fukuzumi N, Ishikawa K. Review of a case of *tsutsugamushi* disease showing myocarditis and confirmation of Rickettsia by endomyocardial biopsy. *Jpn Circ J* 1991;55:149-53.  
[PUBMED](#) | [CROSSREF](#)
159. Park SD, Chung MH, Lee HM, Kim MK, Kang JS. [A case of scrub typhus in summer presenting as atypical pneumonia] (in Korean). *Infect Chemo* 2008;40:241-5.  
[CROSSREF](#)
160. Im JH, Baek JH, Lee JS, Chung MH, Lee SM, Kang JS. A case series of possibly recrudescent *Orientia tsutsugamushi* infection presenting as pneumonia. *Jpn J Infect Dis* 2014;67:122-6.  
[PUBMED](#) | [CROSSREF](#)
161. Levine HD. Pathologic study of thirty-one cases of scrub typhus fever with especial reference to the cardiovascular system. *Am Heart J* 1946;31:314-28.  
[PUBMED](#) | [CROSSREF](#)
162. Levine HD. Cardiac complications of tsutsugamushi fever (scrub typhus): investigation of their persistency. *War Med* 1945;7:76-81.
163. Benjamin JE, Porter RR, Dreisbach RH. Sudden death in patient supposed to have myocarditis following scrub typhus. *Bull US Army Med Dep* 1945;4:235-8.
164. Browning JS, Raphael M, Klein EF, Coblenz A. Scrub-typhus. *Am J Trop Med Hyg* 1945;25:481-92.  
[PUBMED](#) | [CROSSREF](#)
165. Elsom KA, Beebe GW, Sayen JJ, Scheie HG, Gammon GD, Wood FC. Scrub typhus: a follow-up study. *Ann Intern Med* 1961;55:785-95.  
[PUBMED](#) | [CROSSREF](#)
166. Chung WS, Lin CL, Hsu WH, Kao CH. Scrub typhus increases the risk of developing acute coronary syndrome: a nationwide cohort study. *Heart* 2014;100:1844-50.  
[PUBMED](#) | [CROSSREF](#)
167. Jung LY, Lee J, Jeon M, Hwang JH, Hong JY, Lee CS. Risk of cerebro- and cardiovascular disease in patients with scrub typhus. *Eur J Clin Microbiol Infect Dis* 2020;39:451-4.  
[PUBMED](#) | [CROSSREF](#)
168. Jeong MH, Ahn YK, Gill GC, Park JH, Cho JG, Park JC, Kang JC. *Tsutsugamushi* myocarditis with congestive heart failure and persistent atrial standstill. *Jpn Circ J* 1996;60:382-8.  
[PUBMED](#) | [CROSSREF](#)
169. Chan CH, Lai F, Daly B, Ho AK, Yu CM, Cheng A. Scrub typhus pneumonitis with delayed resolution. *J Trop Med Hyg* 1995;98:114-6.  
[PUBMED](#)
170. Kim DY, Park HS, Han DJ, Kang HC, Lee JH, Jang WJ, Gil HW, Yang JO, Lee EY, Hong SY. A case of scrub typhus requiring maintenance hemodialysis. *Kidney Res Clin Pract* 2013;32:190-3.  
[PUBMED](#) | [CROSSREF](#)
171. Papa MZ, Rabi I, Adar R. A point scoring system for the clinical diagnosis of Buerger's disease. *Eur J Vasc Endovasc Surg* 1996;11:335-9.  
[PUBMED](#) | [CROSSREF](#)
172. Shionoya S. Diagnostic criteria of Buerger's disease. *Int J Cardiol* 1998;66 (Suppl 1):S243-5; discussion S247.  
[PUBMED](#) | [CROSSREF](#)
173. Goodman C, Bernstein E. Presenile gangrene—thromboangiitis obliterans. *New York Medical Journal* 1916;103:1073-4.
174. Goodman C. A skin test to suggest the diagnosis of recovered typhus and thrombo-angiitis. *Bull N Y Acad Med* 1935;11:403-12.  
[PUBMED](#)
175. Goodman C. Thrombo-angiitis obliterans and typhus. *Arch Surg* 1937;35:1126-44.  
[CROSSREF](#)
176. Goodman C. Thrombo-angiitis and rickettsia—etiologic relationship. *J Mt Sinai* 1940;7:391-404.
177. Perla D. Analysis of forty-one cases of thrombo-angiitis obliterans; with report of case involving coronaries and aorta. *Surg Gynecol Obstet* 1925;41:21-30.

178. Meleney FL, Gavin Miller G. A contribution to the study of thrombo-angiitis obliterans. *Ann Surg* 1925;81:976-93.  
[PUBMED](#) | [CROSSREF](#)
179. Silbert S. Etiology of thromboangiitis obliterans. *JAMA* 1945;129:5-9.  
[CROSSREF](#)
180. Goodman C, Gottesman J. Pain and its treatment in thrombo-angiitis obliterans. *New York Medical Journal* 1923;117:774-5.
181. Brown GE. The treatment of peripheral vascular disturbances of the extremities. *JAMA* 1926;87:379-83.  
[CROSSREF](#)
182. Allen EV. Thrombo-angiitis obliterans: a clinical study of 200 cases. II. Treatment and prognosis. *Ann Intern Med* 1928;1:550-79.  
[CROSSREF](#)
183. Barker NW. Results of treatment of thromboangiitis obliterans by foreign protein. *JAMA* 1931;97:841-3.  
[CROSSREF](#)
184. Allen EV. Thrombo-angiitis obliterans. *Bull N Y Acad Med* 1942;18:165-89.  
[PUBMED](#)
185. Ball GV, Wright IS. Thromboangiitis obliterans. Simultaneous quadrilateral acute ulcerations in thromboangiitis obliterans. Follow-up studies of a case after 27 years. *Am Heart J* 1966;71:260-4.  
[PUBMED](#) | [CROSSREF](#)
186. Hărăguș S, Stăncioiu N, Schneider E, Vlaicu R. [Fever therapy in thromboangiitis obliterans]. *Med Interna (Bucur)* 1968;20:1489-96. Romanian.  
[PUBMED](#)
187. Corelli F. [Clinical cure of Buerger's disease with malariotherapy]. *Riv Malariol* 1958;37:21-43. Italian.  
[PUBMED](#)
188. Corelli F. Buerger's disease: cigarette smoker disease may always be cured by medical therapy alone. Uselessness of operative treatment. *J Cardiovasc Surg (Torino)* 1973;14:28-36.  
[PUBMED](#)
189. Margini GF. [Malariotherapy of Buerger type endarteritis obliterans]. *G Clin Med* 1959;40:1231-42. Italian.  
[PUBMED](#)
190. Ramsine S. [Inapparent form of exanthematic typhus in human]. *Arch Inst Pasteur Tunis* 1929;18:247-54. French.
191. Troisier J, Horowitz A. [Buerger's disease and exanthematic typhus]. *Bull Mem Soc Med Hop Paris* 1933;49:151-7. French.
192. Mandl F. Trial with penicillin in certain cases of thrombangiitis obliterans (Buerger's disease). *Acta Med Orient* 1946;5:1-7.  
[PUBMED](#)
193. Dreyfus G, Zarachovitch M, Sterboul J. [Sequelae of obliterating arteritis of exanthematic typhus origin. Dramatic improvement under the influence of intravenous infusion of hypertonic NaCl solution]. *Bull Mem Soc Med Hop Paris* 1946;62:359-60. French.
194. Fery D. [Penicillin in two cases of painful ulcers due to Raynaud's disease and in one case of Buerger arteritis]. *Concours Med* 1947;69:95-6. French.  
[PUBMED](#)
195. Marty J, Renner R, Rispe R, Bouvet B, Navarranne P, Mollaret J. [Diffuse rickettsial thromboarteritis obliterans]. *Bull Mem Soc Med Hop Paris* 1955;71:176-9. French.  
[PUBMED](#)
196. Neel JL. [Buerger's disease and exanthematous typhus]. *Presse Med* 1955;63:135-6.  
[PUBMED](#)
197. Worms R. [Cardiovascular complications from rickettsia infections]. *Rev Prat* 1956;6:1309-20. French.  
[PUBMED](#)
198. Michon P, Mathieu L, Hugonot R, Larcen A, Streiff F, Huriet C. [Rickettsial diseases and vascular diseases; with reference to serologic observations made during the course of thrombotic vasculitis]. *Presse Med* 1958;66:1353-5. French.  
[PUBMED](#)
199. Michon P. [Importance of serodiagnosis of rickettsiosis in vascular disorders]. *Bull Acad Natl Med* 1958;142:354-60. French.  
[PUBMED](#)
200. Bernard JG, Giroud P, Masbernard A. [Arterites juveniles et rickettsioses]. *Angeiol Ann Soc Fr Angeiol Histopathol* 1958;10:9-16. French.  
[PUBMED](#)

201. Bernard JG, Giroud P, Masbernard A. [Arteritis in young subjects and rickettsiosis]. *Angeiol Ann Soc Fr Angeiol Histopathol* 1958;10:11-5. French.  
[PUBMED](#)
202. Bernard JG, Giroud P, Laaban J, Masbernard A. [A case of obliterating thrombo-angiitis caused by *Rickettsia prowazekii*]. *Bull Mem Soc Med Hop Paris* 1959;75:639-42. French.  
[PUBMED](#)
203. Bernard JG, Giroud P, Pfister R, Hugonot R. [The etiological problem of thromboangitis obliterans of the young adult. Apropos of 7 observations]. *Sem Hop* 1959;35:326-32. French.  
[PUBMED](#)
204. Ouradou J, Comte H. [Juvenile arteritis in Moroccans]. *Maroc Med* 1959;38:100-7. French.  
[PUBMED](#)
205. Comte H, Martin LA, Ouradou J. [Apropos of 42 cases of juvenile arteritis] (in French). *Arch Inst Pasteur Maroc* 1960;6:85-102.
206. Comte H, Ouradou J, Martin LA, Defrance M. [The problem of the rickettsial etiology of chronic juvenile arteritis]. *Sem Hop* 1961;37:1330-40. French.  
[PUBMED](#)
207. Chevat H, Giroud P, Bernard JG, Merlen JF. [Migratory thrombo-phlebitis of the lower limbs of neo-rickettsial etiology]. *Angeiol Ann Soc Fr Angeiol Histopathol* 1959;11:21-2. French.  
[PUBMED](#)
208. Giroud P, Bernard JG, Chevat H, Merlen JF, Perot GJ. [Thrombophlebitis caused by neo-rickettsias; isolation of the strain]. *Bull Mem Soc Med Hop Paris* 1959;75:634-8. French.
209. Rollier R. [Arteriolitis. Thrombophlebitis migrans. Benign insular gangrene. Mutilating acropathy and rickettsiosis. Neo-rickettsiosis]. *Bull Soc Fr Dermatol Syphiligr* 1959;3:327-33. French.  
[PUBMED](#)
210. Delanoe G. [Rickettsioses and cardiovascular diseases. Apropos of 13 cases, of which 12 were heart diseases]. *Maroc Med* 1960;39:523-38. French.  
[PUBMED](#)
211. Giroud P. [Vascular lesions of rickettsiosis and neo-rickettsiosis]. *Maroc Med* 1959;38:570-4. French.
212. Giroud P, Capponi M. Etiopathogenie rickettsienne de certaines thromboangioses. In: Fontaine R, SouM P, eds. *Premier Congres du College Frangais de pathologie vasculaire*. Paris: L'expansion Scientifique;1968;85-96.
213. Le Gac P. [Rickettsies and pararickettsies. Technique and results of microagglutination. Importance of reactivation (author's transl)]. *Ann Ist Super Sanita* 1979;15:745-54. Italian.  
[PUBMED](#)
214. Martin M, Cabanes L. [Acute arteritis obliterans of the lower limbs in scrub typhus]. *Med Trop (Mars)* 1961;21:597-8. French.  
[PUBMED](#)
215. Chippaux C, Nosny P, O'Connor HL, Plessis J. [Thrombo-angiostasis and rickettsial infection]. *Mem Acad Chir (Paris)* 1961;87:658-62. French.  
[PUBMED](#)
216. Bureau Y, Mousseau , Barriere H, de Ferron . [Arteritis of the lower extremities, Raynaud's syndrome and necrotic purpura, in the same subject. Rickettsiosis?]. *Bull Soc Fr Dermatol Syphiligr* 1961;68:479-81. French.  
[PUBMED](#)
217. Burgar-Meszaros K. Intra-arterial methylpyrrolidino-oxytetracyclin treatment in cases of extremital gangrene. *Ther Hung* 1963;11:31-2.  
[PUBMED](#)
218. Lojaco F. [Clinical observations on intra-arterial antibiotic therapy in peripheral artery diseases]. *Minerva Chir* 1964;19:73-7. Italian.  
[PUBMED](#)
219. House AK. The intraarterial use of tetracycline in the treatment of two patients with digital gangrene secondary to obliterative arterial disease. *Aust N Z J Surg* 1973;42:247-50.  
[PUBMED](#) | [CROSSREF](#)
220. Gervaziev VB, Fust VI, Bykov VM. [Regional drug microemboli in the treatment of patients with thromboangiitis obliterans of the lower extremities]. *Khirurgiia (Mosk)* 1990:67-71. Russian.  
[PUBMED](#)
221. Gervaziev VB, Kolobova OI. [Intraarterial thrombolytic therapy in obliterative thromboangiitis of the lower extremities]. *Khirurgiia (Mosk)* 1993:26-32. Russian.  
[PUBMED](#)

222. Bazex A, Salvador R, Dupre A, Christol B, Lauriere M. [Leo Buerger's disease: positive microagglutination for *R. prowazekii*]. Bull Soc Fr Dermatol Syphiligr 1962;69:487-8. French.  
[PUBMED](#)
223. Sassolas M. [Historical typhus and acute arteritis]. Maroc Med 1963;42:967-9. French.  
[PUBMED](#)
224. Nicolau SS, Sarateanu D, Surdan C, Athanasiu P, Anagnoste B, Sorodoc G, Iliescu C, Radescu R, Malitchi E. [Inframicrobial etiology in the field of cardiovascular diseases. III. Thromboangiitis obliterans with migratory phlebitis of rickettsial etiology]. Stud Cercet Inframicrobiol 1961;12:535-41. Romanian.  
[PUBMED](#)
225. Nicolau SS, Surdan C, Sarateanu D, Athanasiu P, Anagnoste B, Sorodoc G, Popescu G, Iliescu C, Radescu R, Malitchi E. [Study on the rickettsial etiology of various angiopathies]. Rev Sci Med 1963;8:69-73. French.  
[PUBMED](#)
226. Surdan CT. [The Rumanian contribution to the study of latent human infections due to rickettsiae and pararickettsiae (cardiovascular diseases; vascular dermatoses; ophthalmopathies; some pathological aspects of pregnancy)]. Bull Soc Pathol Exot Filiales 1968;61:737-52. French.
227. Surdan C, Sorodoc G. [Studies at the Institutul de inframicrobiologie "St. S. Nicolau" on chronic rickettsial and pararickettsial infections in humans]. Stud Cercet Inframicrobiol 1970;21:265-73. Romanian.  
[PUBMED](#)
228. Erel SH, Kandan S, Sasmaz O. [On a case of arteritis cured with tetracycline and heparin therapy]. Turk Tip Cemiy Mecm 1964;30:316-8. Turkish.  
[PUBMED](#)
229. Charmot G, Mafart Y, Aandre LJ, Ducloux M, Boucheau P. [Purposeful research on possible rickettsial origin in coronaritis and arteritis observed in a military environment]. Bull Soc Pathol Exot 1964;57:367-70. French.
230. Constantinescu N, Franche M, Zavate OM, Micu I. [Rickettsial etiology (*R. prowazekii*) of post-exanthematic late thromboarteritis]. Rev Roum Inframicrobiol 1966;3:221-4. French.
231. Florian I. [Vasculopathic incidents in patients with positive seroreaction for rickettsiosis and pararickettsiosis]. Stud Cercet Inframicrobiol 1966;17:457-63. Romanian.  
[PUBMED](#)
232. Bologa S, Lustig T. [Thromboangiitis obliterans with rickettsial etiology in children]. Pediatria (Bucur) 1966;15:57-60. Romanian.  
[PUBMED](#)
233. Vlaicu R, Hărăguș S, Mureșan T, Olinic N. [The role of rickettsial and pararickettsial diseases in the etiopathogenesis of some chronic arteriopathies]. Med Interna (Bucur) 1968;20:1369-77. Romanian.  
[PUBMED](#)
234. Dugois P, Amblard P, Imbert R, de Bignicourt B, Seigneurin JM. [Multiple distal arteritis with skin necrosis of rickettsial origin]. Bull Soc Fr Dermatol Syphiligr 1969;76:681-2. French.  
[PUBMED](#)
235. Schneider E. [Peripheral arterial occlusions in the extremities due to rickettsias]. Dtsch Med J 1972;23:380-1. German.  
[PUBMED](#)
236. Benyahia B, Ammar F, Sefrioui AL, Sefrioui AR, Bensouda M. [Leo Buerger's disease: a review and report on 23 cases (author's transl)]. Chirurgie 1980;106:687-98. French.  
[PUBMED](#)
237. Bartolo M, Rulli F, Raffi S. Buerger's disease: is it a rickettsiosis? Angiology 1980;31:660-5.  
[PUBMED](#) | [CROSSREF](#)
238. Bartolo M, Rulli F. [Rickettsiosis in vascular pathology. Personal experience]. Ann Ital Chir 1981;53:247-54. Italian.  
[PUBMED](#)
239. Bartolo M, Antignani PL, Todini AR, Ricci G. [Buerger's disease: etiologic role of the rickettsiae?]. J Mal Vasc 1987;12:82-4. French.  
[PUBMED](#)
240. Allegra C. [Therapy of Buerger's disease]. J Mal Vasc 1989;14:45-6. French.  
[PUBMED](#)
241. Fazeli B, Ravari H, Farzadnia M. Does a species of *Rickettsia* play a role in the pathophysiology of Buerger's disease? Vascular 2012;20:334-6.  
[PUBMED](#) | [CROSSREF](#)



242. Fazeli B, Ravari H, Ghazvini K. Rickettsia infection could be the missing piece of the Buerger's disease puzzle. *Int Angiol* 2017;36:410-6.  
[PUBMED](#) | [CROSSREF](#)
243. Maddock WG, Collier FA. Peripheral vasoconstriction by tobacco and its relation to thrombo-angiitis obliterans. *Ann Surg* 1933;98:70-81.  
[PUBMED](#) | [CROSSREF](#)
244. Grotenhermen F. Cannabis-associated arteritis. *Vasa* 2010;39:43-53.  
[PUBMED](#) | [CROSSREF](#)
245. Sterne J, Ducastaing C. [Arteritis caused by Cannabis indica]. *Arch Mal Coeur Vaiss* 1960;53:143-7. French.  
[PUBMED](#)
246. Disdier P, Granel B, Serratrice J, Constans J, Michon-Pasturel U, Hachulla E, Conri C, Devulder B, Swiader L, Piquet P, Branchereau A, Jouglard J, Moulin G, Weiller PJ. Cannabis arteritis revisited--ten new case reports. *Angiology* 2001;52:1-5.  
[PUBMED](#) | [CROSSREF](#)
247. Lee C, Moll S. Migratory superficial thrombophlebitis in a cannabis smoker. *Circulation* 2014;130:214-5.  
[PUBMED](#) | [CROSSREF](#)
248. Smadel JE, Jackson EB, Cruise AB. Chloromycetin in experimental rickettsial infections. *J Immunol* 1949;62:49-65.  
[PUBMED](#)
249. Wisseman CL Jr, Silverman DJ, Waddell A, Brown DT. Penicillin-induced unstable intracellular formation of spheroplasts by rickettsiae. *J Infect Dis* 1982;146:147-58.  
[PUBMED](#) | [CROSSREF](#)
250. Moragues V, Pinkerton H, Greiff D. Therapeutic effectiveness of penicillin in experimental murine typhus infection in dba mice. *J Exp Med* 1944;79:431-7.  
[PUBMED](#) | [CROSSREF](#)
251. Miyamura S, Ohta T, Tamura A. [Comparison of in vitro susceptibilities of Rickettsia prowazekii, R. rickettsii, R. sibirica and R. tsutsugamushi to antimicrobial agents]. *Nihon Saikingaku Zasshi* 1989;44:717-21. Japanese.  
[PUBMED](#) | [CROSSREF](#)
252. Rolain JM, Stuhl L, Maurin M, Raoult D. Evaluation of antibiotic susceptibilities of three rickettsial species including *Rickettsia felis* by a quantitative PCR DNA assay. *Antimicrob Agents Chemother* 2002;46:2747-51.  
[PUBMED](#) | [CROSSREF](#)
253. Kim ES, Kim MK, Lee HM, Chung MH, Lee JS, Park JE, Kang JS. [*In vitro* study on the dose and duration of doxycycline treatment against Orientia tsutsugamushi]. Korean. *Infect Chemother* 2008;40:249-54.  
[CROSSREF](#)
254. Lee SM, Kim MK, Kim MJ, Kang JS. Novel polysaccharide antigen of *Orientia tsutsugamushi* revealed by a monoclonal antibody. *FEMS Microbiol Lett* 2009;297:95-100.  
[PUBMED](#) | [CROSSREF](#)