



Case series: Two cases of severe retinal cicatricial contraction after vitrectomy for open-globe injury in patients with skin keloid

Mengyu Liao, Jinguo Yu, Caiyun You, Hua Yan*

Department of Ophthalmology, Tianjin Medical University General Hospital, No. 154 Anshan Road, Tianjin, China

ARTICLE INFO

Keywords:

Open-globe injury
Retinal cicatricial contraction
Skin keloid
Retinal detachment
Pars plana vitrectomy

ABSTRACT

Purpose: To report two cases of severe retinal cicatricial contraction after vitrectomy for open-globe injury in patients with skin keloid.

Observations: One was a 33-year-old male patient who developed severe retinal cicatricial contraction 6.5 months post-operatively, and his skin wound was observed with keloid simultaneously. The second case was a 36-year-old male patient who developed recurrent retinal detachment 1 week after the two operations, and keloid was also found on his skin.

Conclusions and Importance: Retinal detachment is a vision-threatening complication of open-globe injury. Besides most of the already known factors, skin keloid should be concerned.

1. Introduction

Pars plana vitrectomy (PPV) is essential to patients with retinal detachment (RD) after open-globe injury (OGI), and the successful rate of retinal reattachment was 83%. The outcomes of RD repair might be influenced by multiple factors, such as removal of epiretinal proliferations, retinotomy/retinectomy, laser photocoagulation, intraocular tamponade, etc.^{1,2} Besides, we strangely found that skin keloid might have a close relationship with post-operative severe retinal cicatricial contraction for OGI. Here we report two cases of severe retinal cicatricial contraction in patients with keloid.

2. Findings

2.1. Case 1

One (Fig. 1) was a 33-year-old male patient who had experienced a fire and explosion in Tianjin Port of China on August 12, 2015,³ causing injuries to his face, right eye and right arm. The right ocular rupture repair, the lacerations of the bilateral eyelids and right arm skin suture were performed at the local hospital. When he was referred to our hospital emergency, the diagnosis included ocular blast injury, vitreous hemorrhage, RD, suprachoroidal hemorrhage, traumatic cataract,

hyphema, sclera rupture, lens dislocation, and subpalpebral foreign body, and the best corrected visual acuity (BCVA) was no light perception (NLP). Ocular Trauma Score (OTS)⁴ was calculated as 26 and graded into category 1 (0 ~ 44). The wound was located at 8 o'clock of the limbus and extended to equatorial regions, with the length of 12mm, involved the ciliary body, choroid and totally detached funnel-shaped retina. The secondary PPV was performed 15 days after the primary emergency surgery, which included phacoemulsification, vitrectomy, membrane peeling, electrocoagulation, photocoagulation, retinotomy, perfluorocarbon liquid injection, silicone oil tamponade and iridectomy. The post-operative BCVA was 0.3, and the retina was attached completely until 54 days post-operatively. However, the severe retinal cicatricial contraction was found 6.5 months post-operatively, and his right arm skin wound was observed with keloid simultaneously. His BCVA was kept hand motion (HM) until the last follow-up.

2.2. Case 2

The second case (Fig. 2) was a 36-year-old male patient who got eye injured by glass fragments on workplace with BCVA of light perception (LP), and underwent emergency treatment for penetrating ocular injury. OTS was calculated as 45 and graded into category 2 (45 ~ 65). The wound was located at 7 o'clock of the limbus and extended to the nasal

Abbreviations: PPV, pars plana vitrectomy; RD, retinal detachment; OGI, open-globe injury; BCVA, best corrected visual acuity; NLP, no light perception; OTS, Ocular Trauma Score; HM, hand motion; LP, light perception; PVR, proliferative vitreoretinopathy; RPE, retinal pigment epithelium.

* Corresponding author.

E-mail address: zyyyanhua@tmu.edu.cn (H. Yan).

<https://doi.org/10.1016/j.ajoc.2021.101248>

Received 29 April 2021; Received in revised form 19 August 2021; Accepted 30 December 2021

Available online 31 December 2021

2451-9936/© 2021 Published by Elsevier Inc. This is an open access article under the CC BY-NC-ND license (<http://creativecommons.org/licenses/by-nc-nd/4.0/>).

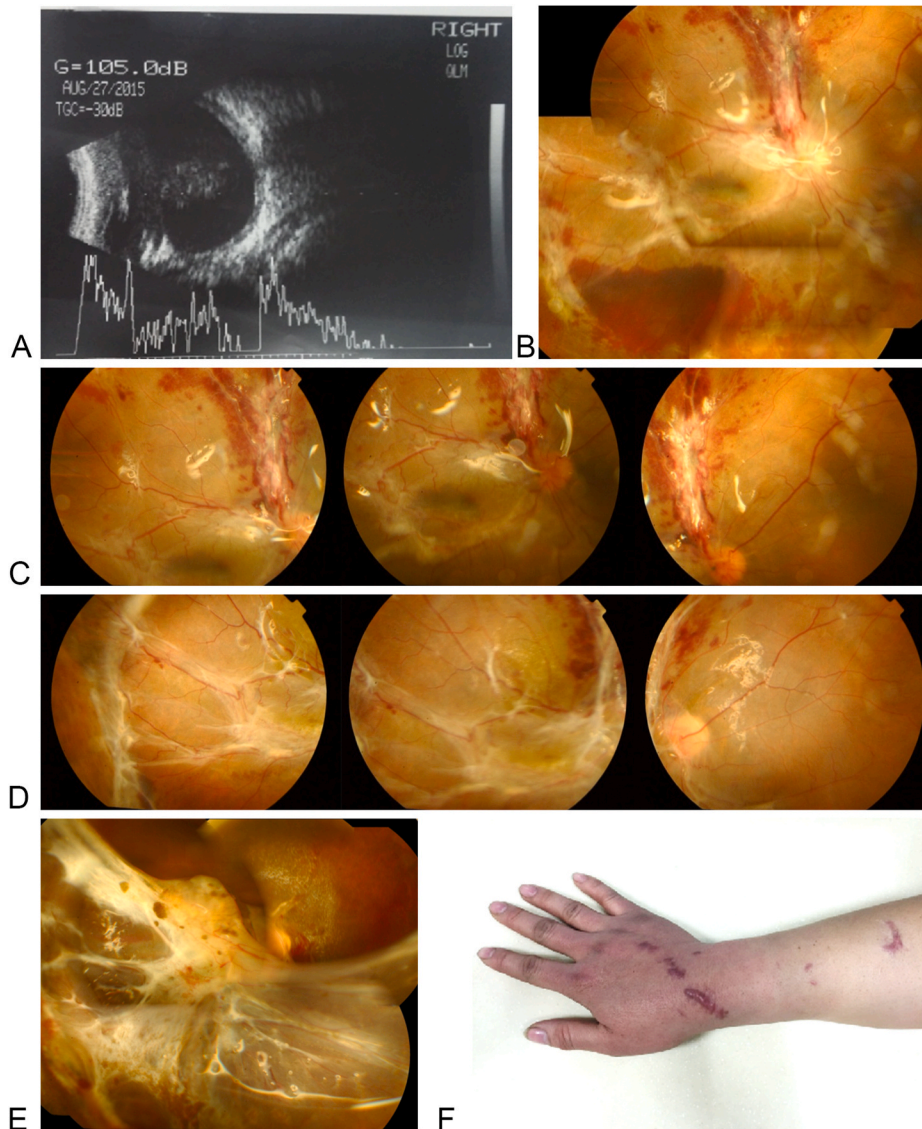


Fig. 1. The B scan ultrasound image (1A) was performed 1 day before pars plana vitrectomy (PPV). Fundus color photography (1B, 1C and 1D) were performed 1, 14, and 39 days after PPV, and the retina was attached well. Severe retinal cicatricial contraction (1E) and skin wound keloid of the hand (1F) were observed 6.5 months after PPV. (For interpretation of the references to color in this figure legend, the reader is referred to the Web version of this article.)

posterior retina, with a length of 23mm. It was described that damaged uvea tissue and vitreous gel prolapsed from the wound. Secondary PPV combined with intravitreal vancomycin injection and photocoagulation was performed 3 weeks after the primary emergency surgery, and the post-operative BCVA was 0.25. However, the recurrent RD (Fig. 2A and B) occurred 1 week later, so he was referred to Dr. Yan and his eye was re-operated with PPV, which included vitrectomy, membrane peeling, intravitreal injection of triamcinolone acetonide, electrocoagulation, retinotomy, photocoagulation, cryotherapy and silicone oil tamponade. The post-operative BCVA was 0.2, and the retina was attached well. After about 3 months, the silicone oil was removed, and the BCVA was 0.5. Regrettably, the severe retinal cicatricial contraction occurred just 1 week after the silicone oil removal (Fig. 2C and D). Remarkably, we also found keloid on his skin (Fig. 2E). Surgical treatment was recommended, so the patient immediately had the final PPV with silicone oil refilled, and phacoemulsification, retinotomy, photocoagulation was performed. The last follow-up was 3 months after the final PPV, his post-operative BCVA was 0.15 and the retina was re-attached well.

3. Discussion

In all influence factors resulting in severe RD and traumatic proliferative vitreoretinopathy (PVR) after OGI, intraocular damage elements were usually emphasized and focused no matter pre- or post-operatively. However, another important factor of skin keloid was rarely concerned. In these two cases with severe retinal cicatricial contraction, we considered keloid to be a possible damage factor. In our report, pre- and post-operative data and surgical procedures were reliable, for all surgeries were performed by the same experienced vitreoretinal surgeon (Dr. Yan). In our series of OGI cases with secondary PPV, severe retinal cicatricial contraction only occurred in these two cases at about half year after injury, with a common characteristic of keloid on skin. Figures of the two cases showed that the more bulge the skin keloid was, the more severe the retinal cicatricial contraction would be. Therefore, it was highly suspected that keloid might play a strong role in traumatic PVR formation after retina damaged. Traumatic PVR is one of the failure reasons for OGI treatment, characterized by epi/subretinal membrane formation induced by retinal pigment epithelium (RPE) cells, glial cells, fibroblasts and other cells of mesenchymal origin.⁵ As the most critical

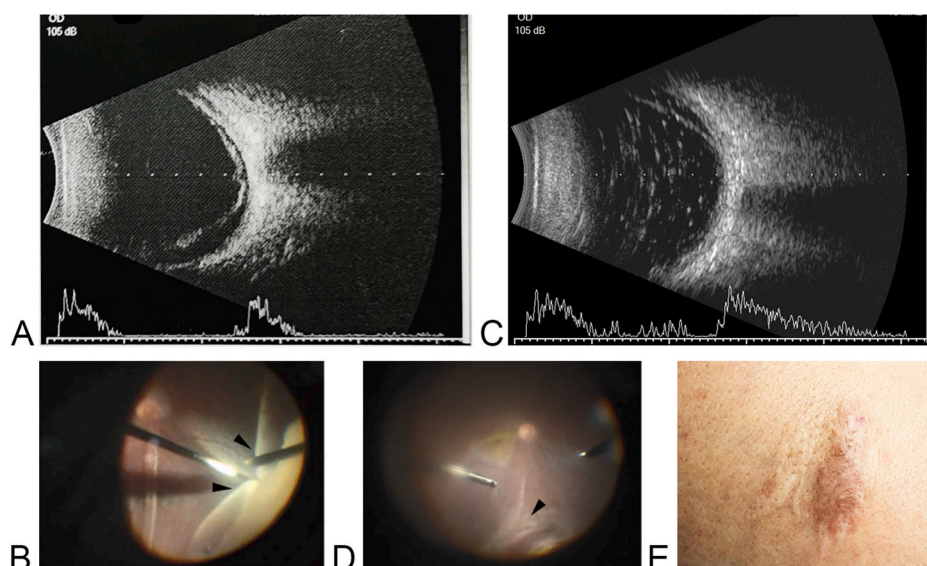


Fig. 2. The B scan ultrasound image (2A) was performed 2 day before pars plana vitrectomy (PPV). Ocular fundus showed tractional retinal detachment during the PPV (42 days after injury). (2B, black arrows) The B scan ultrasound image (2C) showed re-detachment of retina. It was deteriorated to severe retinal cicatricial contraction 7 days after the silicone oil removal (about 6 months after injury) (2D, black arrow), and the keloid (2E) was observed on the skin wound of the thigh simultaneously.

contributor in traumatic PVR, RPE cells undergo abnormal proliferation and migration, and then transform to fibroblast-like cells. Fibroblasts, the key player of fibrotic diseases, not only proliferate actively in keloids, but also trigger signal transduction, enhance collagen synthesis, and increase accumulation of extracellular matrix in ocular tissues.^{6,7} In summary, the role and mechanism of keloid in aggravating traumatic PVR after retinal damage should be explored further. It is suggested that clinicians should inquire about the history of keloid in details before OGI treatment that will be helpful to predict and explain the management and prognosis of traumatic PVR.

4. Conclusions

Retinal detachment is a vision-threatening complication of open-globe injury. Besides most of the already known factors, skin keloid should be concerned.

Patient consent

Consent to publish the case report was not obtained. This report does not contain any personal information that could lead to the identification of the patient.

Funding

This was supported by National Natural Science Foundation of China (Grant Numbers 82020108007, 81830026) and Beijing-Tianjin-Hebei Special Project (Grant Number 19JCZDJC64300(Z)).

Authorship

All authors attest that they meet the current ICMJE criteria for Authorship.

Declaration of competing interest

The following authors have no financial disclosures: MYL, JGY, CYY, HY.

Acknowledgements

None.

References

1. He Y, Zhang L, Wang F, et al. Timing influence on outcomes of vitrectomy for open-globe injury: a prospective randomized comparative study. *Retina*. 2020;40(4):725–734.
2. Reed DC, Juhn AT, Rayess N, Hsu J, Chiang A. Outcomes of retinal detachment repair after posterior open globe injury. *Retina*. 2016;36(4):758–763.
3. Liu Y, Feng K, Jiang H, et al. Characteristics and treatments of ocular blast injury in Tianjin explosion in China. *BMC Ophthalmol*. 2020;20(1):185.
4. Kuhn F, Maisiak R, Mann L, Mester V, Morris R, Witherspoon CD. The ocular trauma Score (OTS). *Ophthalmol Clin North Am*. 2002;15(2):163.
5. Jin Y, Chen H, Xu X, et al. Traumatic proliferative vitreoretinopathy: clinical and histopathological observations. *Retina*. 2017;37(7):1236–1245.
6. Saika S, Yamanaka O, Sumioka T, et al. Fibrotic disorders in the eye: targets of gene therapy. *Prog Retin Eye Res*. 2008;27(2):177–196.
7. Morescalchi F, Duse S, Gambicorti E, et al. Proliferative vitreoretinopathy after eye injuries: an overexpression of growth factors and cytokines leading to a retinal keloid. *Mediat Inflamm*. 2013;2013, 269787.