

Co-administration of retinoic acid and atorvastatin mitigates high-fat diet induced renal damage in rats

Leila Zarei¹, Saied Mahdavi Rad², Amin Abdollahzade Fard^{3,4*}

¹ Department of Anatomical Sciences, Faculty of Medicine, Lorestan University of Medical Sciences, Khorramabad, Iran; ² Student Research Committee, Faculty of Medicine, Urmia University of Medical Sciences, Urmia, Iran; ³ Nephrology and Kidney Transplant Research Center, Urmia University of Medical Sciences, Urmia, Iran; ⁴ Department of Physiology, Faculty of Medicine, Urmia University of Medical Sciences, Urmia, Iran.

Article Info	Abstract
Article history: Received: 22 October 2017 Accepted: 21 February 2018 Available online: 15 June 2019	<p>Obesity causes many problems such as cardiovascular and chronic kidney diseases. The aim of this study was to evaluate the efficacy of retinoic acid and atorvastatin co-administration in kidneys protection against high-fat diet induced damage. Twenty-five male Wistar rats (200.00 ± 20.00 g) were divided into five groups: 1) Control (standard diet), 2) High-fat diet (cholesterol 1.00%, 75 days), 3) High-fat diet + atorvastatin (20.00 mg kg^{-1} per day, orally, on the 30th day, for 45 consecutive days), 4) High-fat diet + retinoic acid (5 mg kg^{-1} per day, orally, on the 30th day, for 45 consecutive days), and 5) High fat diet + atorvastatin and retinoic acid. At the end, blood and tissue samples were collected for biochemical and histological analyses. The results showed that atorvastatin and retinoic acid alone and in combination decreased cholesterol and low-density lipoprotein and increased high-density lipoprotein in high-fat diet. Also, atorvastatin – caused total antioxidant capacity increase and protein carbonyl content decrease the in the renal tissue. Atorvastatin also prevented high-fat diet-induced renal histological injury. Treatment with atorvastatin significantly mitigates high-fat diet-induced renal changes probably due to its potent antioxidant and lipid-lowering effects. The effect of retinoic acid in renal protection in a high-fat diet is far less than that of atorvastatin. The protective effect of the combination of these two agents in the high-fat diet on the kidneys seems to be due to the effect of atorvastatin.</p>
Key words: Atorvastatin High-fat diet Protein carbonyl Retinoic acid	

© 2019 Urmia University. All rights reserved.

تجویز همزمان اسید رتینوئیک و آتوروستاتین، آسیب کلیوی ناشی از رژیم غذایی پرچرب را در موش های صحرائی کاهش می دهد

چکیده

چاقی مشکلات متعددی از جمله بیماری های قلبی عروقی و مزمن کلیوی ایجاد می کند. هدف از این مطالعه بررسی کارایی تجویز همزمان اسید رتینوئیک و آتوروستاتین در محافظت از کلیه ها در برابر آسیب ناشی از رژیم غذایی پرچرب بود. ۲۵ موش صحرائی نژاد ویستار ($200/00 \pm 20/00$ گرم) به پنج گروه تقسیم شدند: ۱- شاهد (رژیم غذایی استاندارد)، ۲- رژیم پرچرب (کلسترول یک درصد به مدت ۷۵ روز)، ۳- رژیم غذایی پرچرب + آتوروستاتین ($20/00$ میلی گرم بر کیلوگرم روزانه، خوراکی، از روز ۳۰ به مدت ۴۵ روز متوالی)، ۴- رژیم غذایی پرچرب + اسید رتینوئیک ($5/00$ میلی گرم بر کیلوگرم روزانه، خوراکی، از روز ۳۰ به مدت ۴۵ روز متوالی)، ۵- رژیم غذایی پرچرب + آتوروستاتین + اسید رتینوئیک. در پایان، نمونه های خون و بافت جهت ارزیابی های بیوشیمیایی و بافت شناسی جمع آوری شد. نتایج نشان داد که آتوروستاتین و اسید رتینوئیک به تنهایی و توأم کلسترول و لیوپروتئین با چگالی پایین را کاهش و لیوپروتئین با چگالی بالا را در رژیم غذایی پرچرب افزایش دادند. آتوروستاتین همچنین باعث افزایش ظرفیت آنتی اکسیدانی کل و کاهش محتوی پروتئین کربونیل در بافت کلیوی شد. آتوروستاتین همچنین از آسیب بافت شناسی کلیه ناشی از رژیم غذایی پرچرب جلوگیری کرد. درمان با آتوروستاتین به طور معنی داری تغییرات کلیوی ناشی از رژیم غذایی پرچرب را کاهش می دهد که این امر ممکن است به خاطر تاثیرات آنتی اکسیدانی و کاهندگی چربی آن باشد. اثر اسید رتینوئیک در محافظت کلیوی در رژیم غذایی پرچرب خیلی کمتر از آتوروستاتین می باشد. اثر محافظتی ترکیب این دو عامل بر کلیه ها در رژیم غذایی پرچرب به نظر می رسد به واسطه اثر آتوروستاتین بوده است.

واژه های کلیدی: آتوروستاتین، اسید رتینوئیک، پروتئین کربونیل، رژیم غذایی پرچرب

*Correspondence:

Amin Abdollahzade Fard. PhD

Department of Physiology, Faculty of Medicine, Urmia University of Medical Sciences, Urmia, Iran

E-mail: abdollahzade.a@umsu.ac.ir



This work is licensed under a Creative Commons Attribution-NonCommercial 4.0 International License which allows users to read, copy, distribute and make derivative works for non-commercial purposes from the material, as long as the author of the original work is cited properly.

Introduction

Obesity is a health problem for industrialized countries potentially leading to a decreased life expectancy.¹ Obesity is currently a medical problem and among the complications associated with the pathological aspects of this disease, renal disease is a significant issue whose pathophysiological mechanisms are not fully known yet.² For example, hypertension, hyperlipidemia and insulin resistance affect renal function in different ways.^{3,4}

Obesity is a condition in which kidneys demonstrate functional and morphological changes.⁵ Some studies have demonstrated that patients with the metabolic syndrome are at risk for chronic kidney disease (CKD).⁶⁻⁸ Few therapies are available for CKD. Previous studies have suggested that statins may slow the CKD progression.^{9,10} More recent meta-analyses, not including cardiovascular studies, have found that statins provide no kidney function protection.¹¹ Based on other reports, atorvastatin and pravastatin have beneficial effects on kidney function.^{12,13}

Atorvastatin is a member of the drug class known as statins. It is used to reduce cholesterol biosynthesis. Atorvastatin is an inhibitor of 3-hydroxy-3-methylglutaryl-coenzyme A (HMG-CoA) reductase. This enzyme catalyzes the conversion of HMG-CoA to mevalonate, an early limiting step in cholesterol biosynthesis.¹⁴

Retinoic acids (RAs), a group of natural and synthetic derivatives of vitamin A, play important regulatory roles in cellular proliferation, differentiation and apoptosis.¹⁵ Retinoid can have an anti-oxidant effect through blocking lipid peroxidation in streptozotocin (STZ)-induced diabetes in rats.¹⁶ Retinoid have been shown to protect against renal injury in several experimental animal models of kidney diseases.¹⁷⁻²⁰ However, the long-term clinical use of retinoids in patients with kidney disease is problematic due to its side-effect profile including differentiation syndrome, depression, psychosis, severe acne, skin and mucosal membranes dryness, inflammatory bowel diseases and teratogenicity.²¹ The treatment of kidney glomerular disease is challenging. Therefore, it is important to identify new treatment targets or regimes to protect the kidneys under different conditions. The aim of this study was to examine the effectiveness of using a lipid-lowering agent on the contradictory effects of retinoic acid on kidney damages.

Materials and Methods

Chemicals. Atorvastatin (Poursina, Tehran, Iran), retinoic acid (Sigma, Munich, Germany), triglyceride (TG), low-density lipoprotein (LDL), high-density lipoprotein (HDL) and cholesterol measurements kit (Pars Biochemical, Tehran, Iran), total anti-oxidant capacity (TAC) kit (ZellBio, Ulm, Germany), protein carbonyl (PCO) kit (Cayman, Hamburg, Germany) were used in this study.

Study design. Twenty-five male Wistar rats (200.00 ± 20.00 g) were purchased from Pasteur Institute, Tehran, Iran. All procedures for animals were conducted in accordance with the Principles of Laboratory Animal Care (NIH publication No. 85-23, revised in 1985) and approved by the Ethical Committee of Urmia University of Medical Sciences, Urmia, Iran (Ethical code: Ir.umsu.rec.1395.406). Animals were maintained under controlled conditions of temperature (21.00 ± 2.00 °C) and a 12/12hr light/dark cycle. Animals were divided into five groups (five animals each): 1) control (standard diet), 2) high-fat diet (HFD; cholesterol 1.00% of food weight for 75 days), 3) HFD + atorvastatin (20.00 mg kg⁻¹ per day, orally, on the 30th day, for 45 consecutive days), 4) HFD + RA (5.00 mg kg⁻¹ per day, orally, on the 30th day, for 45 consecutive days), and 5) HFD + atorvastatin + RA. The dose of atorvastatin was equivalent to doses used in previous studies reporting that the doses of 10.00 to 80.00 mg kg⁻¹ of atorvastatin in humans are comparable to doses of 5.00 to 18.00 mg kg⁻¹ in rats via oral administration.²² At the end of the study, the animals were anesthetized with ether and sacrificed. Blood sample was collected by cardiac puncture and centrifuged for biochemical including HDL, LDL, cholesterol, blood urea nitrogen (BUN) and creatinine analysis. Also, tissue samples were collected for biochemical and histological analyses.

Biochemical analyses. At the end of the study, the animals were fasted for 12 hr. Afterwards, blood sample was collected for the measurement of BUN, creatinine and serum lipid profile. Serum BUN and creatinine were measured using an auto-analyzer (BT3000; Biotecnica Instruments, Rome, Italy), and serum sodium and potassium concentrations were measured by flame photometry. After blood collection, serum was separated and stored at -20 °C until analysis. Blood total cholesterol, TG, HDL and LDL concentrations were measured via a blood analysis kit using an enzymatic colorimetric method. Left kidneys were cut into suitable pieces and homogenized with a Potter-Elvehjem tissue homogenizer (Thomas Scientific, Swedesboro, USA) in 10.00 mM potassium phosphate buffer with the pH of 7.40. The homogenate was centrifuged for 15 min at 1000 rpm at 4 °C and the resultant supernatant was used for PCO and TAC determinations.

Protein carbonyl measurement. The tissue PCO content was determined spectrophotometrically by a method based on the formation of a Schiff base from the reaction between 2,4-dinitrophenylhydrazine (DNPH) and PCOs. The DNPH reacts with PCOs forming a Schiff base to produce the corresponding hydrazone which can be analyzed spectrophotometrically. Briefly, after the precipitation of protein with an equal volume of 1.00% trichloroacetic acid, the pellet was re-suspended in 10 mmol L⁻¹ DNPH plus 2N hydrochloric acid or in 2N HCl as a control blank. After the washing procedure with 1:1 ethanol-ethyl acetate, the final pellet was dissolved in

6.00 mol L⁻¹ guanidine. The carbonyl group was determined from the absorbance at 370 nm. The carbonyl content was calculated in terms of nmol mg⁻¹ protein.²³

Total antioxidant capacity measurement. Kidney homogenate TAC was measured using a commercial kit following the manufacturer's protocol on the basis of the ferric-reducing antioxidant power (FRAP) assay. The FRAP assay measures the change in absorbance at the wavelength of 593 nm due to the formation of a blue-colored Fe²⁺-tripyridyltriazine compound from the colorless oxidized Fe³⁺ by the action of electron-donating antioxidants.²⁴ Concisely, 50.00 µL of kidney homogenate was added to 1.50 mL of FRAP reagent in a test tube and incubated at 37 °C for 10 min. The absorbance of the blue-colored complex was read against the reagent blank (1.50 mL of FRAP reagent plus 50.00 µL of distilled water) at 593 nm. The data were expressed as µmol ferric ions reduced to ferrous form per mg protein.

Protein measurement The protein concentration tested in 1 mL of homogenate used for TAC was estimated by the method of Lowry *et al.* using bovine serum as a standard.²⁵ Results of TAC were adjusted by protein content in each sample as µmol mg⁻¹ protein.

Histological study Following blood sample collection, to assess the extent of renal tissue damage, the right kidney was removed and stored in 10% formaldehyde. Tissue sections were stained with hematoxylin and eosin (H & E) and Masson's trichrome (MTC) stains and observed under the light microscope.

Statistical analysis. Results are expressed as mean ± SD. Data were analyzed using one-way ANOVA followed by Tukey's test in SPSS (version 22; SPSS Inc., Chicago, USA). The *p* values less than 0.05 were considered as statistically significant.

Results

Serum concentration of BUN, creatinine, Na and K.

As shown in Table 1, a slight increase could be noted in the BUN and creatinine levels of the HFD rats in comparison with the control, although these increases were not significant. There was no significant difference regarding the serum concentration of sodium and potassium.

The administration of atorvastatin and RA alone and together in the HFD reduced serum creatinine, BUN, K and increased serum Na, though none of these changes was statistically significant.

Lipid profile. As shown in Table 1, HFD rats showed clear hyperlipidemia. Compared to the control group, HFD induced significant increases in plasma lipids including total cholesterol and LDL (*p* < 0.001). There were no significant differences regarding serum TG and HDL of HFD rats compared to control ones. The administration of atorvastatin and RA alone and together in the HFD significantly reduced cholesterol and LDL (*p* < 0.001) and significantly increased HDL (*p* < 0.01) under HFD feeding (Table 1). In the case of TG, only atorvastatin significantly reduced this factor and the effect of RA was not significant. These findings suggest that atorvastatin and RA alone and together may help restore the lipid imbalance in HFD. The results indicated that atorvastatin had a better effect on restoring the lipid imbalance.

Renal tissue total antioxidant capacity. A significant decrease in the TAC of renal tissue was recorded in the HFD group compared to the control group (*p* < 0.01). Atorvastatin alone and together with RA significantly increased TAC compared to the HFD (*p* < 0.01). Retinoic acid alone did not increase this factor in HFD, (Fig. 1A).

Renal tissue content of protein carbonyl. Renal tissue PCOs were assessed as an indicator of protein peroxidation products. The HFD rats showed a significant increase of PCOs compared to the control group (*p* < 0.001). Atorvastatin alone and together with RA in HFD significantly reduced POC (*p* < 0.01). Retinoic acid alone had no effect on PCO reduction in HFD (Fig. 1B).

Histological analysis. The results of H & E and MTC revealed that the HFD rats had an obvious renal injury with glomerular hypertrophy and Bowman's space narrowing compared to the control ones. In contrast, atorvastatin alone and together with RA ameliorated these lesions in rats' kidneys. The ameliorative effect of RA treatment was lesser than atorvastatin in HFD (Figs. 2 and 3). According to the results of MTC staining, renal fibrosis was not seen in HFD rats.

Table 1. Serum levels of creatinine, blood urea nitrogen, sodium and potassium and lipid profile in experimental groups.

Parameters	Control	HFD	HFD + AT	HFD + RA	HFD+RA+AT
Cr (mg dL ⁻¹)	0.79 ± 0.04	1.06 ± 0.11	0.87 ± 0.09	0.98 ± 0.17	0.94 ± 0.23
BUN (mg dL ⁻¹)	31.45 ± 2.24	36.62 ± 5.43	32.65 ± 4.71	28.25 ± 3.42	24.73 ± 5.31
Na (meq L ⁻¹)	136.00 ± 2.13	139.77 ± 1.85	145.74 ± 4.56	145.00 ± 2.82	139.37 ± 1.58
K (meq L ⁻¹)	4.33 ± 0.44	4.41 ± 0.91	3.22 ± 0.13	3.74 ± 0.21	3.53 ± 0.42
TG (mg dL ⁻¹)	136.25 ± 26.85	188.57 ± 27.15	129.75 ± 19.33 [†]	161.33 ± 25.35	170.25 ± 22.81
Chol (mg dL ⁻¹)	74.00 ± 21.72	1266.25 ± 161.93 [*]	245.00 ± 81.35 [†]	718.00 ± 85.18 [†]	378.33 ± 95.34 [†]
HDL (mg dL ⁻¹)	15.56 ± 4.25	32.00 ± 9.26 [*]	66.75 ± 16.82 [†]	82.59 ± 20.43 [†]	77.33 ± 20.57 [†]
LDL (mg dL ⁻¹)	26.00 ± 4.71	576.00 ± 108.85 [*]	152.75 ± 29.4 [†]	322.53 ± 57.27 [†]	306.33 ± 51.57 [†]

HFD: High fat diet; AT: Atorvastatin; RA: Retinoic Acid; Cr: Creatinine; Chol: Cholesterol; TG: triglyceride; LDL: Low-density lipoprotein; HDL: High-density lipoprotein.

* and † show the significance in comparison with control and HFD groups, respectively (*p* < 0.05).

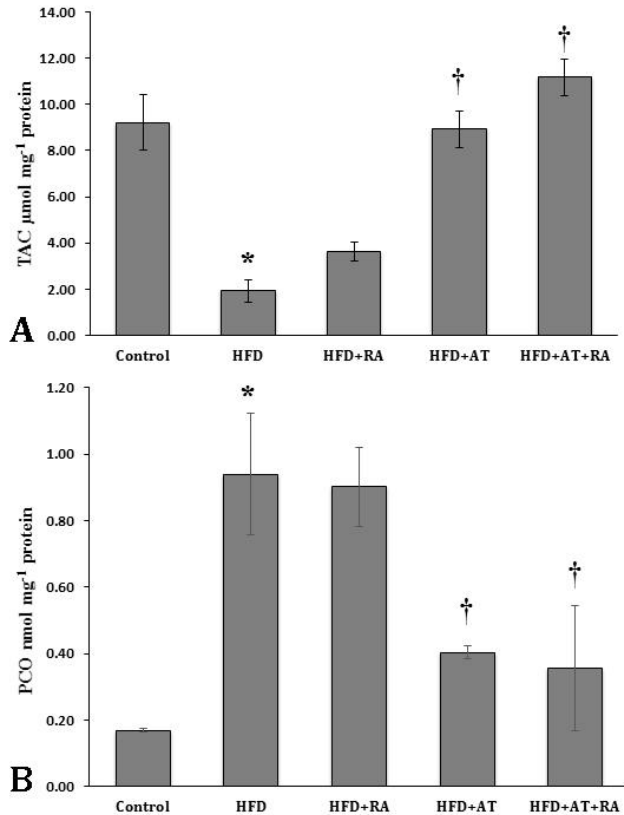


Fig. 1. A) Total antioxidant capacity (TAC) of renal tissue; **B)** Protein carbonyl (PCO) concentration as a marker for renal oxidative stress. HFD: High-fat diet; AT: Atorvastatin; RA: Retinoic acid. * indicates significant difference compared to the controls and † compared to HFD group ($p < 0.01$).

Discussion

The HFD can alter the function and structure of rat kidney. In the present study, the effects of HFD on rat kidneys were studied. Serum BUN and creatinine increased in HFD indicating a change in renal function, although these changes were not significant compared to the controls. Although the glomerular filtration rate (GFR) was not measured in this study, the results of previous studies have shown that obesity induces hemodynamic change and increases GFR.^{26,27} Since the serum level of BUN and creatinine is strongly dependent on the GFR, the lack of any significant increase in these parameters may be due to the increased GFR. Because of its beneficial effects on lipid profile and antioxidant status, atorvastatin restores renal function changes. This finding is in agreement with previous studies showing that atorvastatin improves renal function in patients with chronic renal failure.²⁸

In the present study, HFD increased lipid profile (TG, cholesterol, LDL and HDL). The increase in cholesterol and LDL was significant compared to the controls. With regard to atorvastatin, its effects are clear and proven. This agent has long been used as a hydrophobic statin for the treatment of dyslipidemia, especially hypercholesterolemia.^{29,30} In the current study, the effect of atorvastatin in the modulation of lipid profile is similar to previous reports. However, the significant finding of the present study is the effects of RA on cholesterol and LDL reduction and HDL increase in HFD. According to the previous studies, RA must be

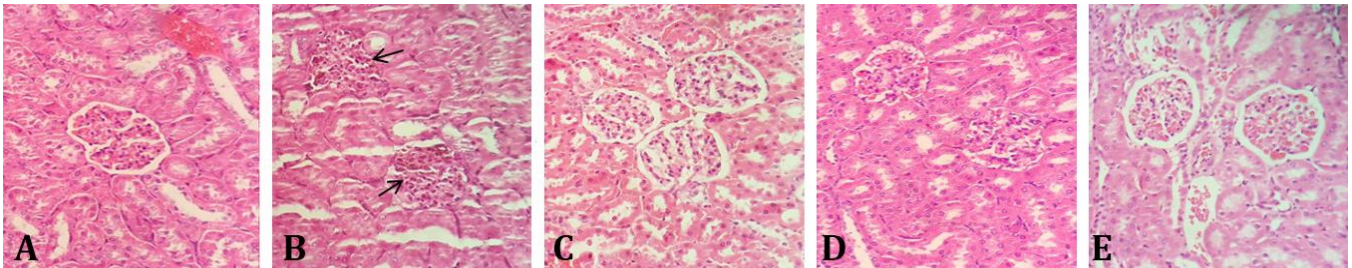


Fig. 2. Photomicrographs of rat renal tissues. HFD rats had an obvious renal injury with glomerular hypertrophy and Bowman's space narrowing compared to the control ones. Arrows show the Bowman's space in glomeruli. A) Control group; B) High-fat diet group; C) Atorvastatin-treated group; D) Retinoic acid-treated group; E) Atorvastatin + retinoic acid-treated group (H & E, 400×).

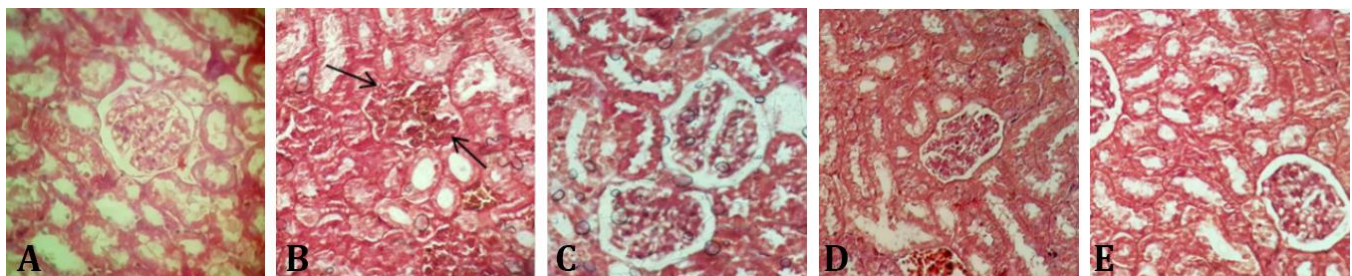


Fig. 3. Photomicrographs of rat renal tissues. There is no obvious renal fibrosis. Arrows show the Bowman's space in glomeruli. A) Control group; B) High-fat diet group; C) Atorvastatin-treated group; D) Retinoic acid-treated group; E) Atorvastatin + retinoic acid-treated group (MTC, 400×).

used with caution, especially in renal patients. The long-term use of retinoids in renal patients is a challenge due to their side-effect profile,²¹ although RA has been shown to protect kidney in various laboratory models of renal disease.¹⁷

Oxidative stress can play an important role in kidney disease. One of the mechanisms is the oxidation of LDL resulting in damaged endothelial cells losing their normal performance.^{31,32} The results of the present study indicated that the HFD group had a significant decrease in TAC compared to the control group that can increase the tissue damage of the kidney. In line with previous studies,^{32,33} the results of the present study showed that atorvastatin can increase the antioxidant capacity of the tissue and reduce tissue damage in the kidney. In the present study, RA did not increase the antioxidant capacity in HFD. Nevertheless, the results of other studies suggest that retinoids can delay renal damage and have antioxidant effects by stopping fat peroxidation in STZ-induced diabetes in rats.^{16,34} Results of this and previous studies confirm the contradiction in the use of RA in renal patients.

Cellular proteins are believed to be the target of free radical-induced oxidation resulting in increased carbonyl content in the tissue. Protein carbonyls are an irreversible form of protein and can be used as a benchmark for protein damage measurement in cells. The results of the present study showed that atorvastatin can prevent the carbonyl proteins production in the renal tissue and as a result, damage from oxidative stress in HFD. This finding confirms the results of previous studies.^{35,36} However, in the present study, RA was not effective in reducing the amount of PCOs. This sheds doubt on the use of RA in the protection against kidney damages.

Histological studies showed clear changes in renal glomeruli including increased cell mass in glomeruli and apparent decrease in glomerular Bowman's space in HFD. This is consistent with previous histological studies about the effects of obesity and HFD on renal glomeruli.^{37,38} Atorvastatin attenuated these histological changes which can be due to modifying and preventing changes in the fat profile as well as strengthening the antioxidant system. With this assumption, the less protective effects of RA can be attributed to the inability of this agent to enhance the antioxidant system in kidneys.

In conclusion, HFD changes the renal function and causes tissue damage in kidney. Treatment with atorvastatin significantly prevents these changes probably due to its potent antioxidant and lipid-lowering effects. The effect of retinoic acid on renal protection in HFD is far less than that of atorvastatin. The protective effect of the combination of these two agents in HFD on the kidneys seems to be due to the effect of atorvastatin.

Acknowledgments

This study was supported by Urmia University of Medical Sciences, Urmia, Iran (grant No. 2338). The authors thank the Nephrology and Kidney Transplant Research Center and the experienced personnel of the laboratory of Motahari Hospital, Urmia University of Medical Sciences, Urmia, Iran.

Conflict of interest

The authors declare that they have no competing interests regarding this paper.

References

1. Olshansky SJ, Passaro DJ, Hershow RC, et al. A potential decline in life expectancy in the United States in the 21st century. *N Engl J Med* 2005;352(11):1138-1145.
2. Kramer H, Luke A. Obesity and kidney disease: A big dilemma. *Curr Opin Nephrol Hypertens* 2007; 16(3):237-241.
3. Odermatt A. The Western-style diet: A major risk factor for impaired kidney function and chronic kidney disease. *Am J Physiol Renal Physiol* 2011; 301(5):F919- F931.
4. Liu Y, Wang Z, Yin W, et al. Severe insulin resistance and moderate glomerulosclerosis in a minipig model induced by high-fat/ high-sucrose/ high-cholesterol diet. *Exp Anim* 2007;56(1):11-20.
5. Papafragkaki DK, Tolis G. Obesity and renal disease: A possible role of leptin. *Hormones (Athens)* 2005;4(2):90-95.
6. Chen J, Muntner P, Hamm LL, et al. The metabolic syndrome and chronic kidney disease in US adults. *Ann Intern Med* 2004;140(3):167-174.
7. Kurella M, Lo JC, Chertow GM. Metabolic syndrome and the risk for chronic kidney disease among nondiabetic adults. *J Am Soc Nephrol* 2005;16(7):2134-2140.
8. Palaniappan L, Carnethon M, Fortmann SP. Association between microalbuminuria and the metabolic syndrome: NHANES III. *Am J Hypertens* 2003;16(11Pt 1):952-958.
9. Bianchi S, Bigazzi R, Caiazza A, et al. A controlled, prospective study of the effects of atorvastatin on proteinuria and progression of kidney disease. *Am J Kidney Dis* 2003;41(3):565-570.
10. Gheith OA, Sobh MA, Mohamed Kel S, et al. Impact of treatment of dyslipidemia on renal function, fat deposits and scarring in patients with persistent nephrotic syndrome. *Nephron* 2002;91(4):612-619.
11. Strippoli GF, Navaneethan SD, Johnson DW, et al. Effects of statins in patients with chronic kidney disease: Meta-analysis and meta-regression of randomised controlled trials. *BMJ* 2008;336(7645):645-651.

12. Koren MJ, Davidson MH, Wilson DJ, et al. Focused atorvastatin therapy in managed-care patients with coronary heart disease and CKD. *Am J Kidney Dis* 2009;53(5):741-750.
13. Nakamura H, Mizuno K, Ohashi Y, et al. Pravastatin and cardiovascular risk in moderate chronic kidney disease. *Atherosclerosis* 2009;206(2):512-517.
14. Stancu C, Sima A. Statins: Mechanism of action and effects. *J Cell Mol Med* 2001;5(4):378-387.
15. Evans TR, Kaye SB. Retinoids: Present role and future potential. *Br J Cancer* 1999;80(1-2):1-8.
16. Zobali F, Avci A, Canbolat O, et al. Effects of vitamin A and insulin on the antioxidative state of diabetic rat heart: A comparison study with combination treatment. *Cell Biochem Funct* 2002;20(2):75-80.
17. Xu Q, Lucio-Cazana J, Kitamura M, et al. Retinoids in nephrology: Promises and pitfalls. *Kidney Int* 2004;66(6):2119-2131.
18. Lehrke I, Schaefer M, Schade K, et al. Retinoid receptor-specific agonists alleviate experimental glomerulonephritis. *Am J Physiol Renal Physiol* 2002;282(4):F741-F751.
19. Wagner J, Dechow C, Morath C, et al. Retinoic acid reduces glomerular injury in a rat model of glomerular damage. *J Am Soc Nephrol* 2000;11(8):1479-1487.
20. Zhong Y, Wu Y, Liu R, et al. Novel retinoic acid receptor alpha agonists for treatment of kidney disease. *PLoS One* 2011;6(11):e27945.
21. Montesinos P, Bergua JM, Vellenga E, et al. Differentiation syndrome in patients with acute promyelocytic leukemia treated with all-trans retinoic acid and anthracycline chemotherapy: Characteristics, outcome, and prognostic factors. *Blood* 2009;113(4):775-783.
22. Zhang L, Zhang ZG, Ding GL, et al. Multitargeted effects of statin-enhanced thrombolytic therapy for stroke with recombinant human tissue-type plasminogen activator in the rat. *Circulation* 2005;112(22):3486-3494.
23. Levine R, Garland D, Oliver CN, et al. Determination of carbonyl content of oxidatively modified proteins. *Methods Enzymol* 1990;186:464-478.
24. Benzie IF, Strain JJ. The ferric reducing ability of plasma (FRAP) as a measure of antioxidant power: The FRAP assay. *Anal Biochem* 1996;239(1):70-76.
25. Lowry OH, Rosebrough NJ, Farr AL, et al. Protein measurement with the folin phenol reagent. *J Biol Chem* 1951;193(1):265-275.
26. Henegar JR, Bigler SA, Henegar LK, et al. Functional and structural changes in the kidney in the early stages of obesity. *J Am Soc Nephrol* 2001;12(6):1211-1217.
27. Maddox DA, Alavi FK, Santella RN, et al. Prevention of obesity-linked renal disease: Age-dependent effects of dietary food restriction. *Kidney Int* 2002;62(1):208-219.
28. Fassett RG, Robertson IK, Ball MJ, et al. Effect of atorvastatin on kidney function in chronic kidney disease: A randomised double-blind placebo-controlled trial. *Atherosclerosis* 2010;213(1):218-224.
29. Malhotra HS, Goa KL. Atorvastatin - An updated review of its pharmacological properties and use in dyslipidaemia. *Drugs* 2001;61(12):1835-1881.
30. Chalasani N. Statins and hepatotoxicity: Focus on patients with fatty liver. *Hepatology* 2005;41(4):690-695.
31. Stocker R, Keaney JF. Role of oxidative modifications in atherosclerosis. *Physiol Rev* 2004;84(4):1381-1478.
32. Chade AR, Lerman A, Lerman LO. Kidney in early atherosclerosis. *Hypertension* 2005;45(6):1042-1049.
33. Ciftci GA, Ertorun I, Akalin A, et al. The effects of atorvastatin on antioxidant/anti-inflammatory properties of HDLs in hypercholesterolemics. *Turk J Med Sci* 2015;45(2):345-351.
34. Nishimura C, Kuriyama K. Alteration of lipid peroxide and endogenous antioxidant contents in retina of streptozotocin-induced diabetic rats: Effect of vitamin A administration. *Jpn J Pharmacol* 1985;37(4):365-372.
35. Noeman SA, Hamooda HE, Baalash AA. Biochemical study of oxidative stress markers in the liver, kidney and heart of high fat diet induced obesity in rats. *Diabetol Metab Syndr* 2011;3(1):17.
36. Stoll LL, McCormick ML, Denning GM, et al. Antioxidant effects of statins. *Drugs Today (Barc)* 2004;40(12):975-990.
37. Rutkowski P, Klassen A, Sebekova K, et al. Renal disease in obesity: The need for greater attention. *J Ren Nutr* 2006;16(3):216-223.
38. O'Donnell MP, Kasiske BL, Cleary MP, et al. Effects of genetic obesity on renal status and function in the Zucker rat. *J Lab Clin Med* 1985;106(5):605-610.