

Imaging of Lactating Adenoma: Differential Diagnosis of Solid Mass Lesion in a Lactating Woman

Reddy Ravikanth*, Kanagasabai Kamalasekar

Department of Radiology, Holy Family Hospital, Idukki, Kerala, India

Abstract

Lactating adenoma is an uncommon palpable breast lesion occurring in the late pregnancy or lactation period and is commonly found in young primiparous women in the second or third decade of life. Although a benign condition, sometimes, core biopsy is required to exclude malignancy. Approximately 3% of all breast cancers occur in women who are pregnant; and hence, a breast mass in this group of women must be investigated. The main differential diagnosis for a palpable solid breast mass is lobular hyperplasia which is a normal physiological event, fibroadenoma, focal mastitis, lactating adenoma, tubular adenoma, phyllodes tumor, and breast carcinoma. Here, we present a case of lactating adenoma of the breast at 6 months' postpartum in a 24-year-old primiparous woman.

Keywords: Benign, lactating adenoma, lactation, late pregnancy, primiparous woman, ultrasound

INTRODUCTION

Many physiological changes in the breast are associated with pregnancy. Lactating adenoma is one such benign tumor of the breast frequently occurring during late pregnancy and lactation periods. Lactating adenoma is a unique entity and is one of the most prevalent breast masses seen during this time and tends to occur commonly in young primiparous women in second or third decades of life.^[1] Clinically and radiologically, lactating adenomas are indistinguishable from other benign breast tumors.^[2] Sometimes, the diagnosis may be obscured by the symptoms of infarction which mimic mass lesions, both benign and malignant. History, radiological appearance, and histopathological examination help in diagnosing lactating adenoma. Here, we present a case of lactating adenoma of the breast at 6 months' postpartum in a 24-year-old primiparous woman.

CASE REPORT

A 24-year-old primiparous woman, who had been breastfeeding for 6 months, presented with a 2-month history of pain in the right breast since the time she started breastfeeding. There was no family or personal history of breast cancer. At physical examination, the markedly asymmetric right breast was filled

with a firm, painless mass and did not seem to be adherent to the chest wall. There were no axillary lymphadenopathy, skin changes, or nipple discharge. The sonographic images were assessed for the presence of solid masses, and if masses were present their shapes, margins, orientations, echo patterns, posterior acoustic features, and surrounding tissue effects were recorded according to the American College of Radiology Breast Imaging-Reporting and Data System (BI-RADS) ultrasound lexicon 5th edition. Ultrasonography of the breast revealed a well-defined hypoechoic lesion measuring 2.9 cm × 1.3 cm with well-circumscribed borders, lobulated margins, and increased central vascularity at 2–4 o' clock position involving the superomedial quadrant of the right breast [Figure 1a] with its long axis parallel to the chest wall and was categorized as a suspicious lesion (BI-RADS category 4A). Color Doppler demonstrated central vascularity, which differentiates the lesion from a galactocele which demonstrates a lack of blood flow. Subsequent core biopsy demonstrated lobules that are lined by actively secreting epithelial cells with vacuolated cytoplasm, hyperchromatic nuclei, and prominent

Address for correspondence: Dr. Reddy Ravikanth,
Department of Radiology, Holy Family Hospital, Thodupuzha,
Idukki - 685 605, Kerala, India.
E-mail: ravikanthreddy06@gmail.com

Received: 09-01-2019 Revised: 26-04-2019 Accepted: 24-06-2019 Available Online: 07-08-2019

Access this article online

Quick Response Code:



Website:
www.jmuonline.org

DOI:
10.4103/JMU.JMU_3_19

This is an open access journal, and articles are distributed under the terms of the Creative Commons Attribution-NonCommercial-ShareAlike 4.0 License, which allows others to remix, tweak, and build upon the work non-commercially, as long as appropriate credit is given and the new creations are licensed under the identical terms.

For reprints contact: reprints@medknow.com

How to cite this article: Ravikanth R, Kamalasekar K. Imaging of lactating adenoma: Differential diagnosis of solid mass lesion in a lactating woman. J Med Ultrasound 2019;27:208-10.

nucleoli which are features of lactating adenoma, and she was advised to have the mass excised [Figure 1b].

DISCUSSION

In late pregnancy and lactation period, the main differential diagnosis for a palpable solid breast mass is lobular hyperplasia which is a normal physiological event, fibroadenoma, focal mastitis, lactating adenoma, tubular adenoma, phyllodes tumor, and breast carcinoma.^[3] Among them, lactating adenoma and fibroadenoma are most prevalent.^[4] About 3% of breast cancers are diagnosed during pregnancy.^[5]

Lactating adenoma is typically seen during late pregnancy through the period of lactation and is a benign stromal tumor. Clinically, it presents as a firm, nontender, and mobile mass that usually regresses spontaneously after the period of lactation. It has been suggested that lactating adenoma is a variant of lobular hyperplasia, fibroadenoma, or tubular adenoma, which has undergone hormonal influences during lactation.^[6]

The ultrasound features may mimic malignancy; although typical features favor a benign mass. Lactating adenoma is a solid, ovoid, or macrolobulated mass with well-defined margins, 1–4 cm in diameter, with its long axis parallel to the chest wall. Typical lesions have a homogeneous and hypoechoic appearance with posterior acoustic enhancement.^[7] Atypical lesions may have heterogeneous echotexture, indistinct, or irregular margins with posterior acoustic shadowing and are difficult to distinguish from a malignant mass. Hemorrhage and necrosis are not prominent features of lactating adenomas. Only 5% demonstrate histological evidence of infarction and is the result of rapidly enlarging mass reaching a considerable size.^[8]

Ultrasound evaluation is the first step in assessing the features of the lesion and show typical benign features such as smooth lobulations, circumscribed borders, or an echogenic pseudocapsule. Atypical features such as irregular, ill-defined or angulated margins with posterior acoustic shadowing are associated with malignancy.^[9] On a mammogram, a lactating

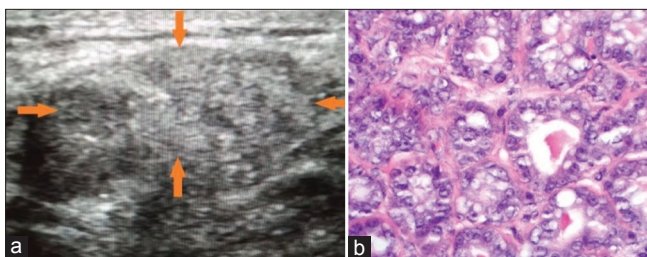


Figure 1: A 24-year-old female who had been breastfeeding for 6 months presented with a palpable breast mass. Ultrasonography image demonstrating a well-defined hypoechoic lesion (a) with lobulated margins (arrows) and long axis parallel to the chest wall, categorized as a suspicious lesion (Breast Imaging-Reporting and Data System category 4A) in a biopsy-proven case of lactating adenoma. (b) Histopathology image demonstrating lobules that are lined by actively secreting epithelial cells with vacuolated cytoplasm. Cells are noted to demonstrate basophilic cytoplasm, hyperchromatic nuclei with prominent nucleoli, and inconspicuous myoepithelial cell layer (H and E, $\times 40$)

adenoma is often seen as a circumscribed mass without calcification.^[10] Magnetic resonance imaging is helpful for avoiding surgery in cases of inconclusive evaluation of the lesion after the ultrasound and histological examination. The main differential considerations for a palpable solid breast mass in the pregnant or lactating female are lactating adenoma, fibroadenoma, galactocele, tubular adenoma, lobular hyperplasia (normal physiological event in pregnancy), breast cancer, focal mastitis, and phyllodes tumor. Patients are often treated conservatively as most lactating adenomas resolve spontaneously after pregnancy and lactation periods. However, some lactating adenomas increase in size or even persist, and the surgery is required in such cases. A lactating adenoma usually does not increase the risk of developing breast carcinoma, and coexistence with malignancy is very rare.

A lactating adenoma may be indistinguishable from a fibroadenoma on sonography^[11] and such as fibroadenomas, lactating adenomas may be multiple and bilateral.^[12] Lactating adenomas typically appear as oval masses with a wider than tall orientation, posterior acoustic enhancement, and a circumscribed margin with a microlobulated margin is often seen. Infarcted lactating adenomas often show atypical features including posterior acoustic shadowing and irregular margins and are indistinguishable from other benign and malignant entities. The most common sonographic appearance of fibroadenomas in pregnant and lactating women is similar to that seen in nongestational patients – an oval or round mass with a wider than tall orientation, with a circumscribed margin, and with or without a few gentle lobulations. Infarcted fibroadenomas may show internal cystic spaces and a more irregular border than typical fibroadenomas.

CONCLUSION

Although lactating adenoma is a rare benign, breast lesion is very much a possibility and should be considered as a differential diagnosis while evaluating breast lesions in pregnancy and lactation period. Lactating adenomas undergo spontaneous regression, and simple enucleation is the treatment of choice when lesion persists. Lactating adenomas have an excellent prognosis with rare recurrence, and hence, diagnosing and differentiation from malignancy is necessary.

Declaration of patient consent

The authors certify that they have obtained all appropriate patient consent forms. In the form the patient(s) has/have given his/her/their consent for his/her/their images and other clinical information to be reported in the journal. The patients understand that their names and initials will not be published and due efforts will be made to conceal their identity, but anonymity cannot be guaranteed.

Financial support and sponsorship

Nil.

Conflicts of interest

There are no conflicts of interest.

REFERENCES

1. Baker TP, Lenert JT, Parker J, Kemp B, Kushwaha A, Evans G, *et al.* Lactating adenoma: A diagnosis of exclusion. *Breast J* 2001;7:354-7.
2. Darling ML, Smith DN, Rhei E, Denison CM, Lester SC, Meyer JE, *et al.* Lactating adenoma: Sonographic features. *Breast J* 2000;6:252-6.
3. Vashi R, Hooley R, Butler R, Geisel J, Philpotts L. Breast imaging of the pregnant and lactating patient: Imaging modalities and pregnancy-associated breast cancer. *AJR Am J Roentgenol* 2013;200:321-8.
4. Joshi S, Dialani V, Marotti J, Mehta TS, Slanetz PJ. Breast disease in the pregnant and lactating patient: Radiological-pathological correlation. *Insights Imaging* 2013;4:527-38.
5. Collins JC, Liao S, Wile AG. Surgical management of breast masses in pregnant women. *J Reprod Med* 1995;40:785-8.
6. Byrd BF Jr., Bayer DS, Robertson JC, Stephenson SE Jr. Treatment of breast tumors associated with pregnancy and lactation. *Ann Surg* 1962;155:940-7.
7. Sumkin JH, Perrone AM, Harris KM, Nath ME, Amortegui AJ, Weinstein BJ, *et al.* Lactating adenoma: US features and literature review. *Radiology* 1998;206:271-4.
8. Behrndt VS, Barbakoff D, Askin FB, Brem RF. Infarcted lactating adenoma presenting as a rapidly enlarging breast mass. *AJR Am J Roentgenol* 1999;173:933-5.
9. Parnes AN, Akalin A, Quinlan RM, Vijayaraghavan GR. AIRP best cases in radiologic-pathologic correlation: Lactating adenoma. *Radiographics* 2013;33:455-9.
10. Sabate JM, Clotet M, Torrubia S, Gomez A, Guerrero R, de las Heras P, *et al.* Radiologic evaluation of breast disorders related to pregnancy and lactation. *Radiographics* 2007;27 Suppl 1:S101-24.
11. Robbins J, Jeffries D, Roubidoux M, Helvie M. Accuracy of diagnostic mammography and breast ultrasound during pregnancy and lactation. *AJR Am J Roentgenol* 2011;196:716-22.
12. Hogge JP, De Paredes ES, Magnant CM, Lage J. Imaging and management of breast masses during pregnancy and lactation. *Breast J* 1999;5:272-83.