

Description of the Sacropelvic Parameters Measurement Method for S2-alar iliac Screw Insertion

Descrição do método de aferição dos parâmetros sacropélvicos para a inserção do parafuso S2-asa do íliaco

Mariana Demétrio de Sousa Pontes¹  Lucas Klarosk Ismael¹  Lucas Américo Francisco¹ 
 Carlos Fernando Pereira da Silva Herrero¹ 

¹Department of Biomechanics, Medicine and Rehabilitation of the Locomotor System, Faculdade de Medicina de Ribeirão Preto, Universidade de São Paulo, Ribeirão Preto, SP, Brazil

Rev Bras Ortop 2020;55(6):702–707.

Address for correspondence Mariana Demétrio de Sousa Pontes, MD, MSc, Departamento de Biomecânica, Medicina e Reabilitação do Aparelho Locomotor, Hospital das Clínicas da Faculdade de Medicina de Ribeirão Preto da Universidade de São Paulo, Avenida Bandeirantes, 3900, 11° Andar, Ribeirão Preto, SP, 14048-900, Brazil (e-mail: marianadpontes@gmail.com; mdsPontes@usp.br).

Abstract

Objective Description of the sacropelvic parameters measurement method for S2-alar iliac (S2AI) screw insertion.

Methods Descriptive study of the method for measuring sacropelvic parameters for the insertion of the S2AI screw using computed tomography (CT). The data evaluated in multiplanar reconstructions were the parameters of the screw trajectory, including length, diameter and angles of the trajectory in the axial and sagittal planes.

Results From the sagittal reconstruction, the axis of the series of axial slices is angled three-dimensionally so that it is possible to visualize the S2 vertebra, the screw entry point, and the anteroinferior iliac spine (AIIS) in the same plane. The entry point is demarcated at the midpoint between the dorsal foramina of S1 and S2. To measure the length of the screw, lines are drawn tangent to the inner and outer cortices of the iliac. The diameter is determined by the shortest distance between the inner and outer iliac faces minus half of the diameter of the screw chosen medially and laterally. The path angle in the axial plane is formed by the anteroposterior midline of the sacrum and the line of the screw length. The craniocaudal inclination angle in relation to the S1 plateau corresponds to the degree of inclination made in the sagittal plane to find the image in which the entry point and the AIIS are seen in the same plane.

Conclusion It was possible to adequately assess, through multiplanar CT reconstructions, the sacropelvic parameters necessary for the safe insertion of the S2AI screw.

Keywords

- ▶ sacroiliac joint
- ▶ spine
- ▶ sacrum

Resumo

Objetivo Descrever como aferir os parâmetros sacropélvicos para a inserção segura do parafuso S2-asa do íliaco (S2AI).

Métodos Estudo descritivo do método de aferição dos parâmetros sacropélvicos para a inserção do parafuso S2AI por meio de tomografia computadorizada (TC). Os dados

avaliados em reconstruções multiplanares foram os parâmetros da trajetória do parafuso, incluindo comprimento, diâmetro e ângulos de trajetória nos planos axial e sagital.

Resultados A partir da reconstrução sagital, angula-se tridimensionalmente o eixo da série de cortes axiais de modo que seja possível visualizar a vértebra S2, o ponto de entrada do parafuso e a espinha íliaca anteroinferior (EIAI) no mesmo plano. O ponto de entrada é demarcado no ponto médio entre os forames dorsais de S1 e S2. Para medir o comprimento do parafuso, traçam-se linhas tangenciando as corticais interna e externa do íliaco. O diâmetro é determinado pela menor distância entre as tábuas interna e externa do íliaco subtraindo metade do diâmetro do parafuso escolhido medialmente e lateralmente. O ângulo de trajetória no plano axial é formado pela linha média anteroposterior do sacro e a linha do comprimento do parafuso. O ângulo de inclinação craniocaudal em relação ao platô de S1 corresponde ao grau de inclinação feito no plano sagital para encontrar a imagem em que o ponto de entrada e a EIAI são vistos no mesmo plano.

Conclusão Foi possível aferir adequadamente, por meio de reconstruções multiplanares de TC, os parâmetros sacropélvicos necessários para a inserção segura do parafuso S2AI.

Palavras-chave

- ▶ articulação sacroilíaca
- ▶ coluna vertebral
- ▶ sacro

Introduction

Spinopelvic fixation remains a challenging subject in spine surgery. Biomechanical forces, anatomical features and bone quality are some of the reasons why surgeons continue to explore sacropelvic fixation options for correcting deformities that extend to the pelvis.^{1,2}

Studies have shown high rates of complications in long fixations of the spine crossing the L5-S1 articulation with exclusive distal anchorage in S1.^{3,4} To overcome them, sacropelvic fixations were introduced, allowing the use of significantly larger implants, increasing the rigidity and stability of the frame necessary for the effective treatment of complex spinal deformities, among other situations.^{2,3,5} A more recently developed option that has shown some benefits in relation to other methods, due to the relative ease of insertion and lower complication rates, is the S2-alar iliac (S2AI) technique. In it, a screw with an S2 entry point is inserted through the sacroiliac joint and travels through the iliac bone toward the anteroinferior iliac spine (AIIS).^{1,5-10}

Studies on this technique, despite exposing the trajectory of the implant, do not detail in an in-depth way how to check the parameters necessary for the insertion of this screw by means of imaging exams. Given this gap in the literature, the present study aims to describe how to measure the parameters of the sacropelvic segment necessary for the safe insertion of the ideal S2AI screw for each patient.

Materials and Methods

The research project was approved by the Research Ethics Committee of the institution where the study was conducted, process nº 7088/2019 (CAAE: 08968219.4.0000.5440).

This is a descriptive study considering computed tomography (CT) of the pelvis. The clinical data included in the

study were the gender and age of the patient. The 100 most recent pelvis CTs from the archive of patients of the institution, of both genders > 18 years old, were consecutively selected. Of these, 66 were excluded because they had previous surgery in the pelvic or lumbosacral region and/or pathologies affecting the sacropelvic segment (fracture, tumor, infection, congenital anomalies, ankylosing spondylitis), totaling $n = 34$ cases, of which 18 were male and 16 female, with ages ranging from 18 to 86 years old (mean of 52.11 and median of 57.5 years old).

All CTs were downloaded in DICOM format, and the exams were transferred to the Horos software, version 1.1.7. The images were analyzed in a dedicated window for bone structures and reconstructed in the software, which allows the evaluator to process and edit 2D image data and reconstruct them in 3D multiplanar models with precision, so that the determination of the entry point of the screw was done with accuracy, as well as their plane and the direction. The reslicing tool was used to obtain precise anatomical alignment.

Considering the entry point described for the insertion of S2AI screws at the midpoint between the dorsal foramina and S1 and S2, the following sacropelvic morphometric parameters were measured^{3,11}:

01) Screw lengths: greater and lesser distances from the entry point to the AIIS, tangent to the medial cortex of the ilium, for the longest length, and the lateral cortical of the ilium, to the shortest length.

02) Screw diameter: minimum width of the iliac wing, which corresponds to the virtual channel of the S2AI screw trajectory, in which there is no violation of any cortex (without risk of injury to neurovascular structures).

03) Screw trajectory angles in the axial plane: anteroposterior inclination angles for the insertion of the S2AI screw. Measured between the screw trajectory lines

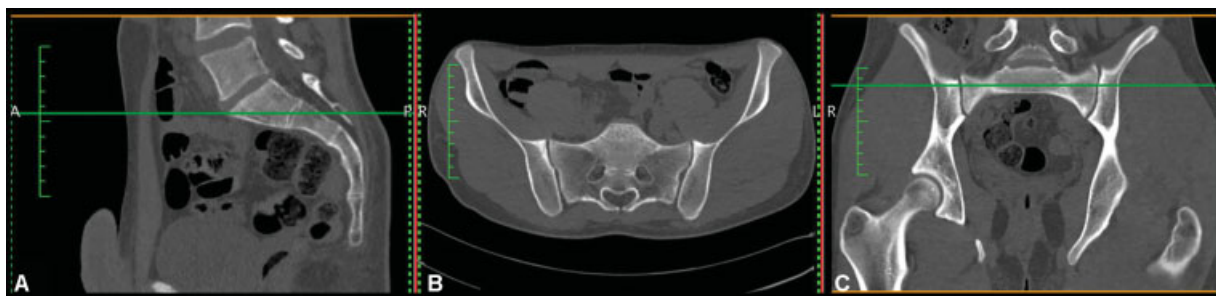


Fig. 1 Computed tomography images in (A) Sagittal reconstruction, (B) Axial plane and (C) Coronal reconstruction.

that correspond to the longest and shortest lengths and the anteroposterior midline of the sacrum.

04) Angle of screw trajectory in the sagittal plane: craniocaudal inclination angle in relation to the S1 plateau for the insertion of the S2AI screw.

Results

The CT exam is only available in the axial plane. The first step is to reconstruct the images in the coronal and sagittal planes (►Fig. 1).

Initially, sagittal reconstruction is used to angle three-dimensionally, using the 3D *multiplanar reformatting* function (MPR), the axis of the series of axial sections so that it is close to the long axis of the sacrum (►Fig. 2) and that it is possible to visualize the S2 vertebra, the entry point and the AIIS in the same plane (►Fig. 3A). The entry point of the S2AI screw is demarcated in the posterior cortex of the sacrum in the axial plane (►Fig. 3A), with the aid of the coronal plane to visualize the midpoint between the dorsal foramina of S1 and S2 (►Fig. 3B).

After defining the entry point, the safe limits of length of the screw to be inserted are checked as follows: knowing that the screw is directed to the AIIS,³ lines are drawn from the entry point, tangential to the inner and outer cortical of the iliac bone wing (►Fig. 4). The line tangent to the internal cortex corresponds to the longest possible length of the S2AI.

The largest possible diameter of the screw to be inserted is determined by the shortest distance between the inner and outer faces of the iliac (►Fig. 5). Because the diameters of the available sacroiliac screws are determined by the measurement of the implant internal diameter, it is extremely important to subtract half of the diameter of the screw chosen, medially and laterally, so that the thread does not violate the cortical of the iliac wing. Afterwards, the length measurements of the implants are adjusted to the new safety limits of the path (►Fig. 6).

To determine the angles of the trajectory of the skull in the axial plane, the anteroposterior midline of the sacrum is used, and the angles formed between it and the lines of the largest and smallest lengths of the screw are measured (►Fig. 7).

To determine the craniocaudal inclination angle in relation to the S1 plateau (►Fig. 8), the degree of inclination made in the sagittal plane is used (►Fig. 2) to find the image where the entry point and the AIIS are seen in the same plane (►Fig. 3A).

In the 34 exams evaluated, it was found that the measurement of the longest screw length ranged from 86.8 to 133.6 mm, with an average of 112.6 mm, and that of the shortest length, from 73.3 to 117.6 mm, with an average of 105.6 mm. The smallest diameter of the virtual space between the internal and external iliac boards ranged from 9.2

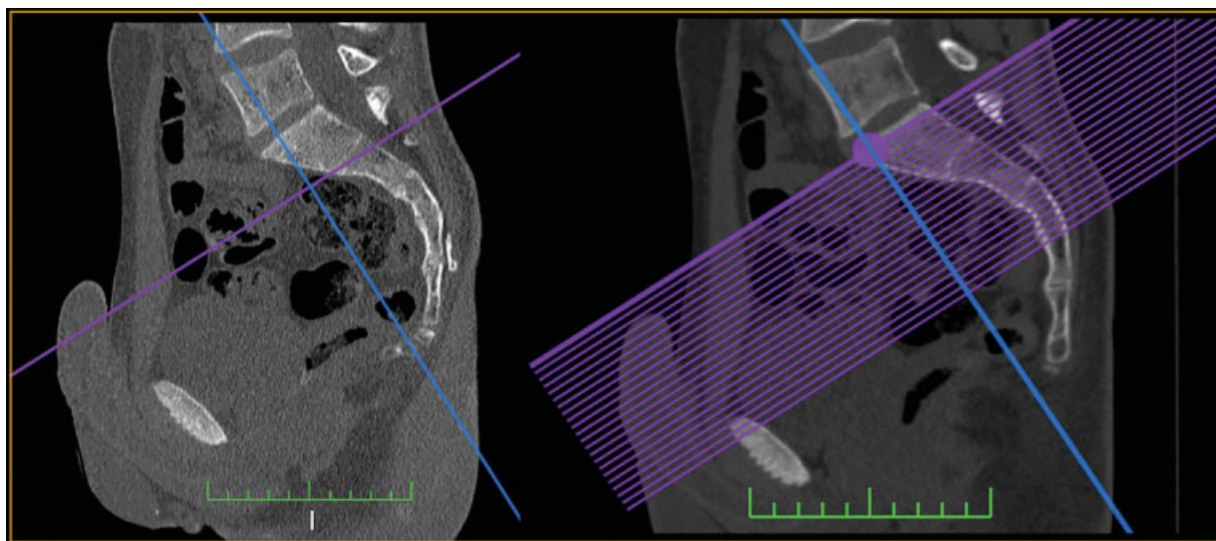


Fig. 2 Reconstruction performed using the 3D MPR function. Axis angulation (blue) of the axial section series (purple).

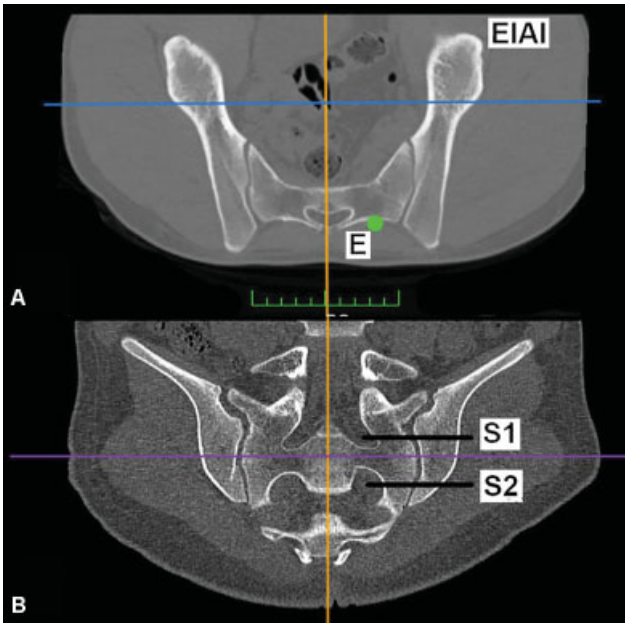


Fig. 3 Images obtained through 3D multiplanar reconstruction after the procedure demonstrated in ►Fig. 2. ((A)) Axial plane image in which the S2 vertebra, the entry point (E) and the AIIS are seen in the same section. ((B)) Coronal reconstruction in which it is possible to visualize the interval between the dorsal foramina of S1 and S2 for the precise demarcation of the entry point of the S2AI screw.

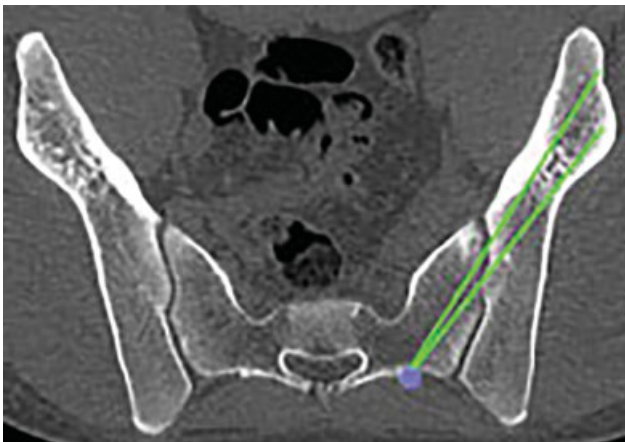


Fig. 4 Checking the lengths of the S2AI screw. From the entry point, lines are drawn tangent to the cortical of the iliac wing toward the AIIS. The length of the line equals the length of the screw.

to 20.6 mm, with a mean of 11 mm. Regarding the trajectory angle in the axial plane for the insertion of the longest screw, we observed a mean of 38° (28.1–46.3°) and a mean variation in relation to the path angle of the shortest screw length of 3.3° (1.2–9°). The trajectory angle in the sagittal plane varied from 4.8 to 10.2°, with a mean of 8.3°.

Discussion

The fixation of the spine extending to the pelvis is indicated to add anchoring force to the instrumentation, aiming to reduce the complications related to the L5-S1 fixation, in cases of pelvic obliquity, high-grade spondylolisthesis (grade

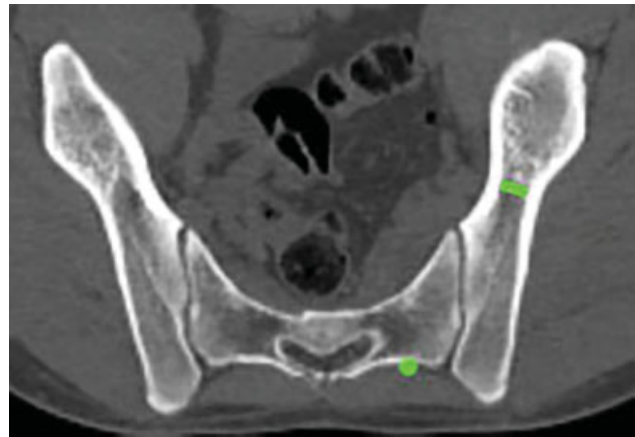


Fig. 5 The largest diameter of the S2AI screw corresponds to the shortest (virtual) space between the inner and outer cortical of the iliac wing.

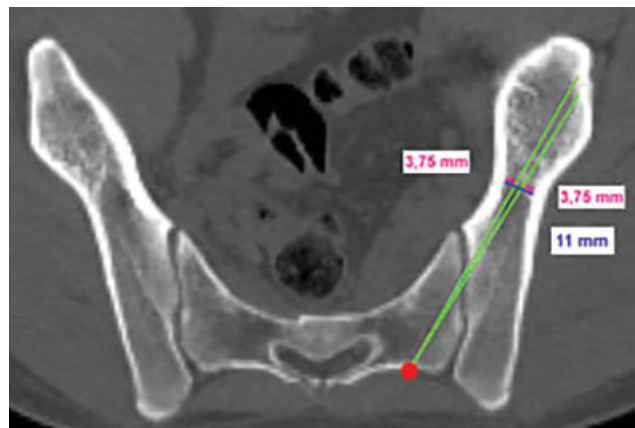


Fig. 6 Example in which a sacroiliac screw of 7.5 mm in internal diameter was chosen. From the maximum diameter of 11 mm, 3.75 mm (half the internal diameter of the implant) was subtracted medially and laterally to avoid the violation of the corticals of the iliac wing by the screw threads. Afterwards, the length measures were adjusted according to the safety limit of the new path.

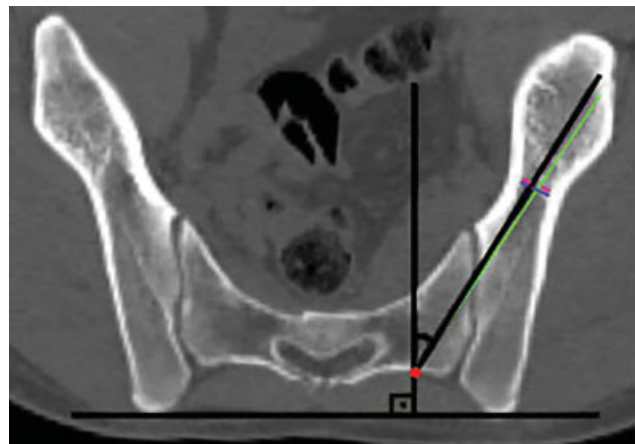


Fig. 7 Measure that determines the anteroposterior inclination angle in the axial plane of the S2AI screw. The anteroposterior midline of the sacrum is used as a parameter (perpendicular to the horizontal line of the pelvis) in relation to the lines corresponding to the screw length measurements.

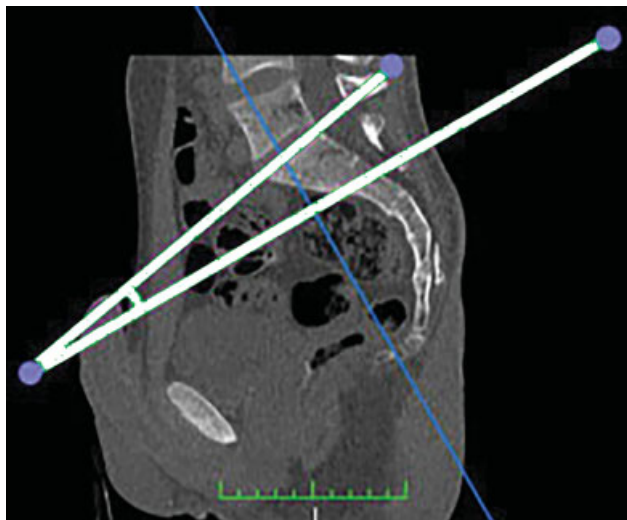


Fig. 8 Measure that determines the craniocaudal inclination angle of the S2AI screw: Angle formed between the S1 plateau and the degree of inclination performed in the sagittal plane to obtain the plane of the screw's path (► **Figure 2**).

3 or higher), deformity with rectification of lumbar lordosis that requires corrective osteotomy, osteoporosis at the lumbosacral junction, spinopelvic trauma as well as other major spinal deformities.^{2,3,5,12-14}

Several factors that may have contributed to the high rates of pseudoarthrosis, fracture of the S1 pedicle and failure of the implants used in sacral fixation associated with long arthrodesis in the thoracolumbar spine, including the direction and depth of the screw insertion, are inadequate bone quality in this region and excessive load resulting from a long lever arm of fusion above the sacrum.^{12,15-17} To circumvent these complications, several sacropelvic fixation techniques have been described, including transiliac bars, iliac and sacroiliac screws.^{1,2} The Galveston technique, described in the 1980s, uses instrumentation with bars inserted between the faces of the iliac bone and, for this, often requires complex and three-dimensional folds of the nails.¹³ The iliac screw technique, in contrast to the transiliac bars, has the advantage of easy insertion and provides greater resistance to pullout, although it may require separate fascial and skin incisions.^{2,4} In addition, interchangeable connectors that link lumbar arthrodesis and sacropelvic fixation are often used, and the wide dissection of the soft tissues necessary for this increases the morbidity of the procedure, and can compromise the integrity and vascularization of the musculature and skin flaps in that area, making the distal portion of the incision more prone to dehiscence of the surgical wound.²

Retrospective studies comparing short-term complications between the iliac screw and S2AI screw techniques show that S2AI fixation was associated with a reduction in the incidence of implant breakage, of surgical site infection and surgical wound dehiscence, in addition to having less need for surgical revision and lower rate of posterior pelvic pain in the postoperative period.^{9,18} The entry point of the traditional iliac screw is in the posterosuperior iliac spine, and its insertion requires considerable dissection of soft

parts, including fascia and paravertebral musculature.² The S2AI screw is an anatomically viable pelvic fixation technique, with an entry point at the level of the second sacral vertebra, that is, lower, medial and anterior, thus avoiding the prominence of the instrumentation, which can lead to pain at the implant site and increased risk of surgical wound dehiscence.^{3,9,19,20} Another advantage of the S2AI technique is that it eliminates the need for modular connectors, used in traditional fixation in the iliac screw technique, to join the sacropelvic fixation to the posterior spine arthrodesis. This is due to the fact that the S2AI entry point is in line with the entry point of the S1 pedicle screw, which can also reduce a potential cause of implant-related failure.^{1-3,5} In addition, studies suggest that the minimally invasive percutaneous fixation of the S2AI screw, as well as the insertion guided by stereotaxic or robotic navigation are viable, safe and accurate options for the precise insertion of the screw.^{4,21-24}

On the other hand, one of the potential disadvantages of this technique, according to studies on cadavers, is the fact that 60% of S2AI screws can violate the sacroiliac joint cartilage without effectively achieving arthrodesis.² However, the clinical significance of this is still unknown.^{13,18-20}

Among the risks of the S2AI technique, there are violations of the vertebral canal, injuries to visceral structures, such as intestines and urogenital organs, and neurovascular structures, mainly internal iliac arteries and veins and the lumbosacral plexus.^{3,25} Detailed knowledge of the anatomy and trajectory characteristics of the screw is necessary to minimize these possible damages.

Regarding the biomechanical properties of S2AI, it is known that the lumbosacral transition resists shear forces and is, evidently, one of the most important regions of the spine in terms of mobility and load support.³ The current literature shows that there is no significant difference in biomechanical properties related to rigidity and failure of instrumentation between the techniques of S2AI and conventional iliac screws.^{1,5,8,9} O'Brien et al. showed that the 65 mm S2AI screw was biomechanically equivalent to the 90 mm iliac screw and the 80 mm S2AI screw.¹ Although this result seems contradictory, the iliac fixation is performed in a spongy bed, and the sacroiliac fixation has cortical penetration in the joint, which can offer additional strength despite the shorter length.¹

In relation to the sacral pedicle screws of S1 and S2, the greater length of the S2AI, as well as the acquisition of multiple corticals, due to the penetration of the sacroiliac joint, makes this instrumentation method biomechanically more stable.³ Burns et al. did not find, in their study, significant differences for torsional stiffness in extension, flexion and lateral inclination between S2AI constructions and iliac screw. There were also no significant differences between S2AI and iliac screws for insertion torque or pullout resistance.⁵

An Asian population study³ shows that screws between 85 and 120 mm in length are potentially favorable in this group with no difference between genders. In the present article, a mean of similar length, 112.6 mm, was observed, and that the 7.5 mm diameter sacroiliac screws were viable, which is in accordance with Wu et al.,⁹ who showed, in a literature review,

that the diameter of the S2AI screws varied from 6.5 to 8.5 mm. The anteroposterior tilt angle found by Elder et al.¹⁹ varied from 30 to 45°, and the craniocaudal inclination angle, from 20 to 45°. This last finding differs from the result found in the sample of Brazilian individuals in the present assessment.

Most studies evaluated the trajectory of spinopelvic implants by means of imaging tests or in cadavers without any injury or deformity.^{3,10,26} As spinopelvic fixation is often performed for the purpose of correcting major deformities, cases in which pelvic asymmetry is occasionally present, we believe that individualization of surgical planning is essential to avoid complications and, consequently, for the acquisition of good results. The present study, therefore, is important for the surgeon to know how to assess in detail the sacropelvic parameters necessary for the safe insertion of the S2AI screw for each case.

Conclusion

It was possible to adequately assess, through multiplanar CT reconstructions, the sacropelvic parameters necessary for the safe insertion of the ideal S2AI screw for each patient.

Conflict of Interests

The authors have no conflict of interests to declare.

References

- O'Brien JR, Yu W, Kaufman BE, et al. Biomechanical evaluation of S2 alar-iliac screws: effect of length and quad-cortical purchase as compared with iliac fixation. *Spine (Phila Pa 1976)* 2013;38(20): E1250–E1255
- Chang TL, Sponseller PD, Kebaish KM, Fishman EK. Low profile pelvic fixation: anatomic parameters for sacral alar-iliac fixation versus traditional iliac fixation. *Spine (Phila Pa 1976)* 2009;34(05):436–440
- Kwan MK, Jeffrey A, Chan CYW, Saw LB. A radiological evaluation of the morphology and safety of S1, S2 and S2-iliac screws in the Asian population using three dimensional computed tomography scan: an analysis of 180 pelvis. *Surg Radiol Anat* 2012;34(03): 217–227
- O'Brien JR, Matteini L, Yu WD, Kebaish KM. Feasibility of minimally invasive sacropelvic fixation: percutaneous S2 alar iliac fixation. *Spine (Phila Pa 1976)* 2010;35(04):460–464
- Burns CB, Dua K, Trasolini NA, Komatsu DE, Barsi JM. Biomechanical Comparison of Spinopelvic Fixation Constructs: Iliac Screw Versus S2-Alar-Iliac Screw. *Spine Deform* 2016;4(01):10–15
- Matteini LE, Kebaish KM, Volk WR, Bergin PF, Yu WD, O'Brien JR. An S-2 alar iliac pelvic fixation. Technical note. *Neurosurg Focus* 2010;28(03):E13
- Nottmeier EW, Pirris SM, Balseiro S, Fenton D. Three-dimensional image-guided placement of S2 alar screws to adjunct or salvage lumbosacral fixation. *Spine J* 2010;10(07):595–601
- Hoernschmeyer DG, Pashuck TD, Pfeiffer FM. Analysis of the s2 alar-iliac screw as compared with the traditional iliac screw: does it increase stability with sacroiliac fixation of the spine? *Spine J* 2017;17(06):875–879
- Wu AM, Chen D, Chen CH, et al. The technique of S2-alar-iliac screw fixation: a literature review. *AME Med J* 2017; 2:179
- O'Brien JR, Yu WD, Bhatnagar R, Sponseller P, Kebaish KM. An anatomic study of the S2 iliac technique for lumbopelvic screw placement. *Spine (Phila Pa 1976)* 2009;34(12): E439–E442
- Jost GF, Walti J, Mariani L, Cattin P. A novel approach to navigated implantation of S-2 alar iliac screws using inertial measurement units. *J Neurosurg Spine* 2016;24(03):447–453
- Kim YJ, Bridwell KH, Lenke LG, Cho KJ, Edwards CC II, Rinella AS. Pseudarthrosis in adult spinal deformity following multisegmental instrumentation and arthrodesis. *J Bone Joint Surg Am* 2006; 88(04):721–728
- Kebaish KM. Sacropelvic fixation: techniques and complications. *Spine (Phila Pa 1976)* 2010;35(25):2245–2251
- Emami A, Deviren V, Berven S, Smith JA, Hu SS, Bradford DS. Outcome and complications of long fusions to the sacrum in adult spine deformity: luque-galveston, combined iliac and sacral screws, and sacral fixation. *Spine (Phila Pa 1976)* 2002;27(07): 776–786
- Edwards CC II, Bridwell KH, Patel A, Rinella AS, Berra A, Lenke LG. Long adult deformity fusions to L5 and the sacrum. A matched cohort analysis. *Spine (Phila Pa 1976)* 2004;29(18):1996–2005
- Klineberg E, McHenry T, Bellabarba C, Wagner T, Chapman J. Sacral insufficiency fractures caudal to instrumented posterior lumbosacral arthrodesis. *Spine (Phila Pa 1976)* 2008;33(16): 1806–1811
- Leong JC, Lu WW, Zheng Y, Zhu Q, Zhong S. Comparison of the strengths of lumbosacral fixation achieved with techniques using one and two triangulated sacral screws. *Spine (Phila Pa 1976)* 1998;23(21):2289–2294
- Ilyas H, Place H, Puryear A. A Comparison of Early Clinical and Radiographic Complications of Iliac Screw Fixation Versus S2 Alar Iliac (S2AI) Fixation in the Adult and Pediatric Populations. *J Spinal Disord Tech* 2015;28(04):E199–E205
- Elder BD, Ishida W, Lo SL, et al. Use of S2-Alar-iliac Screws Associated With Less Complications Than Iliac Screws in Adult Lumbosacropelvic Fixation. *Spine (Phila Pa 1976)* 2017;42(03): E142–E149
- Gupta S, Smith E, Falk D, O'Brien J. S2 alar-iliac screws versus iliac screws for pelvic fixation. *AME Med J* 2017;2:58
- Ray WZ, Ravindra VM, Schmidt MH, Dailey AT. Stereotactic navigation with the O-arm for placement of S-2 alar iliac screws in pelvic lumbar fixation. *J Neurosurg Spine* 2013;18(05): 490–495
- Hyun SJ, Kim KJ, Jahng TA. S2 alar iliac screw placement under robotic guidance for adult spinal deformity patients: technical note. *Eur Spine J* 2017;26(08):2198–2203
- El Dafrawy MH, Kebaish KM. Percutaneous S2 alar iliac fixation for pelvic insufficiency fracture. *Orthopedics* 2014;37(11): e1033–e1035
- Bederman SS, Hahn P, Colin V, Kiester PD, Bhatia NN. Robotic Guidance for S2-Alar-Iliac Screws in Spinal Deformity Correction. *Clin Spine Surg* 2017;30(01):E49–E53
- Mirkovic S, Abitbol JJ, Steinman J, et al. Anatomic consideration for sacral screw placement. *Spine (Phila Pa 1976)* 1991;16(6, Suppl) S289–S294
- Zhu F, Bao HD, Yuan S, et al. Posterior second sacral alar iliac screw insertion: anatomic study in a Chinese population. *Eur Spine J* 2013;22(07):1683–1689