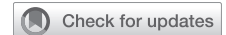

“Collar-like” neocommissure in mitral valve repair for extensive commissural prolapse



Hoshun Chong, MD, PhD,^a Jie Li, MD,^b Yunxing Xue, MD,^a Xiyu Zhu, MD, PhD,^a He Zhang, MD,^a Junxia Wang, MD, PhD,^a and Hailong Cao, MD, PhD^a

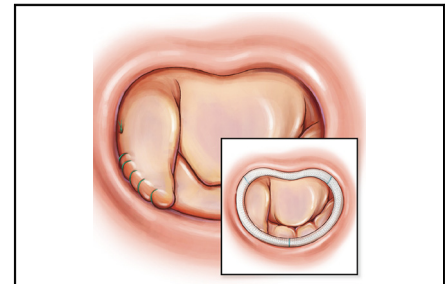
ABSTRACT

Objectives: Mitral valve repair for extensive commissural prolapse is complex; several methods have been reported with variable results. To restore the leaflet area, we introduced an innovative and effective method rather than a simple folding technique through reconstructing a neocommissure with a “collar-like” plasty technique.

Methods: From 2016 to 2021, 62 patients with mitral valve extensive commissural prolapse that received the “collar-like” plasty technique were included.

Results: The mean age was 51.7 ± 13.8 years, and 38 (61%) were female. Postplasty transesophageal echocardiography showed the mean transvalvular pressure gradients were 3.8 ± 1.2 mm Hg, end diastolic peak flow velocity was 1.1 ± 0.3 m/s, and coaptation height was 7.9 ± 1.1 mm. During the follow-up period of 3 to 6 months, no deaths or cardiovascular-/valvular plasty-related adverse events occurred. All patients regained their heart function and returned to normal physical activities.

Conclusions: The “collar-like” plasty technique can be safely performed for patients with extensive commissural prolapse. Echocardiography revealed that the technique can restore the leaflet area of low transvalvular pressure and flow velocity. (JTCVS Techniques 2022;15:73-7)



“Collar-like” neocommissure in mitral valve repair.

CENTRAL MESSAGE

The “collar-like” plasty technique can be safely performed for patients with extensive commissural prolapse, which could restore the leaflet area of low transvalvular pressure and flow velocity.

PERSPECTIVE

We introduced an innovative and effective method through reconstructing a neocommissure with a “collar-like” plasty technique to restore the leaflet area. The “collar-like” plasty technique can be safely performed for patients with extensive commissural prolapse. Echocardiography revealed that the technique can restore computation area while maintaining lower transvalvular pressure and low velocities.

▶ Video clip is available online.

From the ^aDepartment of Cardiothoracic Surgery, The Affiliated Drum Tower Hospital of Nanjing University Medical School, Nanjing, China; and ^bDepartment of Ultrasound, The Affiliated Hospital of Nanjing University Medical School, Nanjing, China.

This work was supported by the Natural Science Foundation of Jiangsu Province (BK20210014), Jiangsu Provincial Key Medical Discipline (ZDXKA2016019), and National Natural Science Foundation of China (81970401, 82100508).

Drs Chong and Li contributed equally to this work.

Mitral valve prolapse (MVP) is one of the most common pathological manifestations of valvular heart disease and affects approximately 2% to 3% of the population.¹ Mitral valve repair is currently the gold standard for the treatment of MVP and provides excellent early and late outcomes.²

Received for publication March 22, 2022; revisions received July 17, 2022; accepted for publication July 19, 2022; available ahead of print Aug 13, 2022.

Address for reprints: Hailong Cao, MD, PhD, No 321 Zhongshan Rd, Nanjing City, Jiangsu Province, China (E-mail: caohailong@njglyy.com).

2666-2507

Copyright © 2022 The Author(s). Published by Elsevier Inc. on behalf of The American Association for Thoracic Surgery. This is an open access article under the CC BY-NC-ND license (<http://creativecommons.org/licenses/by-nc-nd/4.0/>).

<https://doi.org/10.1016/j.jtc.2022.07.025>

Abbreviations and Acronyms

AC	= anterior commissure
MVP	= mitral valve prolapse
NYHA	= New York Heart Association
TEE	= transesophageal echocardiography
TTE	= transthoracic echocardiography

However, commissural prolapse is a risk factor for residual mitral valve regurgitation and requires reoperation. Only limited studies focused on patients with commissural prolapse and these studies' outcomes varied greatly.^{3,4} Thereby several techniques have been accounted for this issue. In most cases, a simple commissural closure will be adequate but for more complicated cases, leaflet resection, sliding technique, and chordal replacement might be required.^{5,6} However, the results of mitral valve repair depend on the extent of commissural prolapse and the effect of valvular plasty. The more complex the technique, the greater the potential surgical risks.

Therefore, we introduced a simple, practical, and effective repair method for mitral valve extensive commissural prolapse through reconstructing a neocommissure with a "collar-like" plasty technique. In terms of "respect when you can, resect when you should,"⁷ the goal of this technique is to reduce the sacrifice of coaptation area caused by leaflet resection. We hereby report the early results of the "collar-like" technique.

METHODS**Patient Enrollment**

From July 2016 to June 2021, 62 patients with mitral valve extensive commissural prolapse who received this technique were included. Preoperative transthoracic echocardiography (TTE) and intraoperative transesophageal echocardiography (TEE) were evaluated by 2 independent

echocardiographers before thoracotomy. All data were collected prospectively from admission to and discharge from the hospital. Then patients' preoperative baseline, operative data, and postoperative outcome were retrieved retrospectively.

Surgical Technique

Mediasternotomy or right infra-axillary vertical thoracotomy was a surgical approach for all patients.⁸ After systemic heparinization, cardiopulmonary bypass was established through the ascending aorta and superior/inferior vena cava. After cardiac arrest, the mitral valve was exposed through the right atrium opening and trans-septal approach. With the aid of retraction, the mitral valve leaflets were checked using a nerve hook starting from A₁ and then evaluated A₂, A₃, P₃, P₂, and P₁ in turn clockwise. The typical extensive mitral commissural prolapse presented as prolapse of the commissural leaflets with or without rupture of the commissural chordae, and the prolapse was extended to A₁ or/and P₁ (Figures 1, A and 2, A). The prolapsed commissural leaflet was cut open directly to the edge of the annulus depending on the high point (usually the cutting line located in the lower one-third of the commissural leaflet); usually, the hinge point of the cut edge was posterior to the anterior commissure (AC) or posterior commissure (Figures 1, B and 2, A). Double-armed 5-0 prolene suture was placed in the high point of the cut edge (P₁ in Figure 2, B), 2 stitches were sutured into the AC point (Figure 2, B) and outside from the left ventricle to the atrium side (Figure 1, D), and 1 pledget was additionally tied and fixed. Another double-armed 5-0 Prolene suture was placed in the high point of another cut edge (P₁ in Figure 2, C) and was sutured into the M point (Figure 1, E), then stitches from the M point to the AC were sutured together (Figure 1, F). After the saline test, a plasty ring was added for every patient in this cohort (Figures 1, G and H and 2, D). Details of the operations are reported in Video 1. Upon resuming the native heart pump, the assistance of cardiopulmonary bypass was adjusted to wean. The valve shape and severity of mitral regurgitation were checked using TEE and the residual of mitral valve regurgitation and mitral valve stenosis larger than mild were indications for mitral valve reintervention.

Follow-up

All patients were assessed with physical examination, electrocardiograph, chest radiograph, and TTE before and every 3 months after discharge. Since the fourth visit, patients' follow-up data were obtained annually.

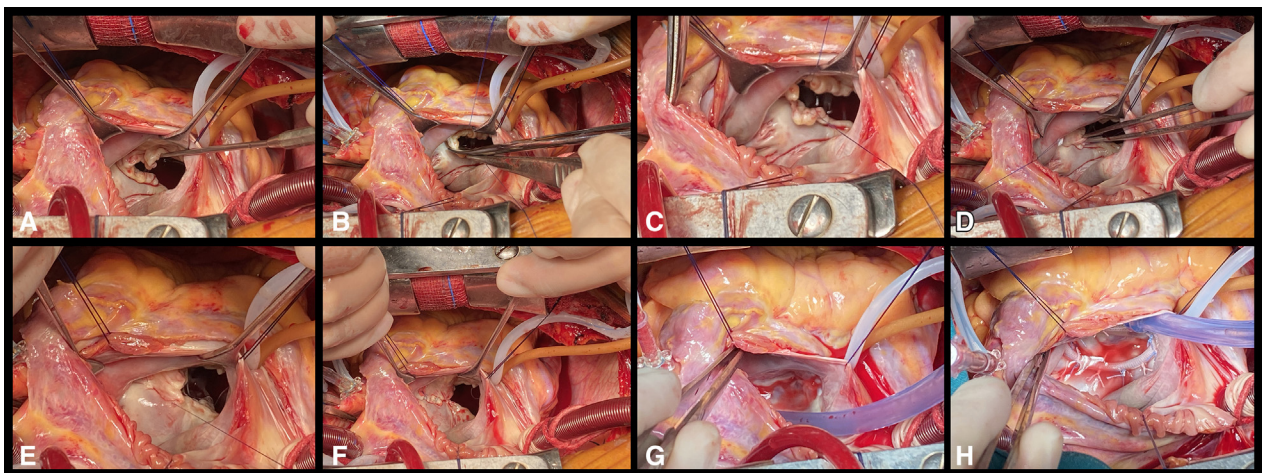


FIGURE 1. Intraoperative photographs of the "collar-like" method. A, Exposure of the extensive commissural prolapse. B, Cut open the prolapsed commissural leaflet. C, Two stay suture stitches are placed in the points of anterior/posterior. D, The posterior point with stay suture is sutured to the commissural annulus with a pledget. E, The anterior point with stay suture is sutured to the posterior annulus. F, Continuous suture connects the 2 sides. G, Saline test to show the effect. H, Additional ring valvuloplasty.

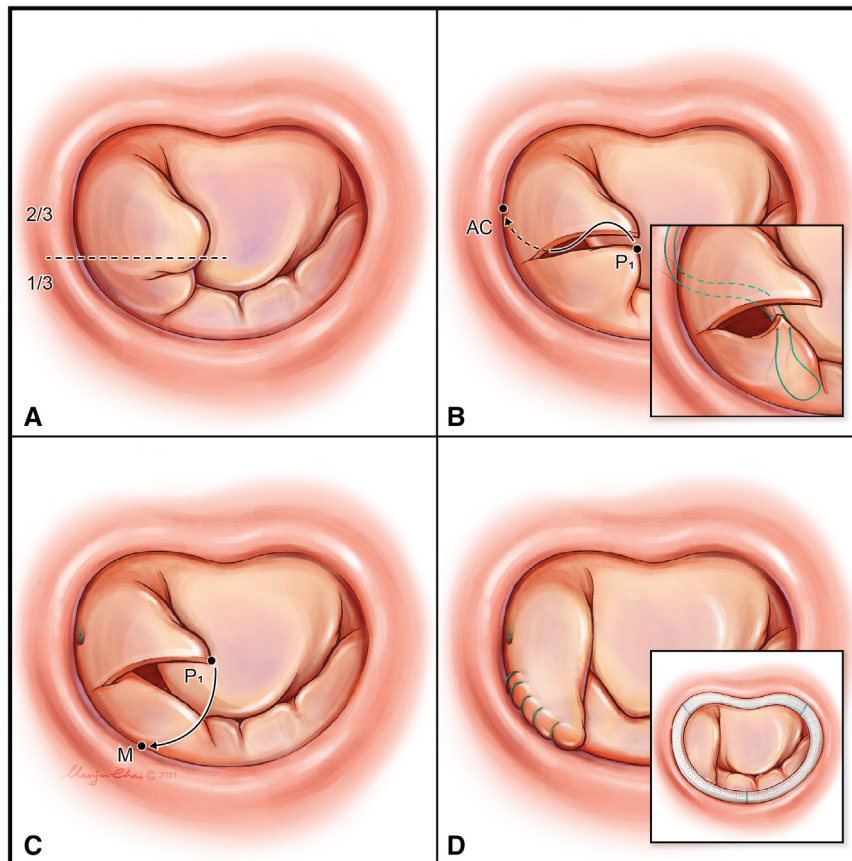
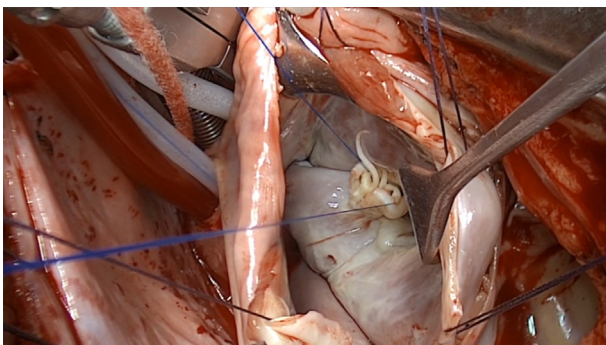


FIGURE 2. Schematic diagrams of “collar-like” method. A, Extensive commissural prolapse; the *dashed line* represents the cutting line. B, P₁ in the posterior leaflet is sutured to the anterior commissure (AC). C, P₁ in the anterior leaflet is sutured to the M point. D, Fine shape without and with ring.

Statistical Analysis

Statistical analyses were performed with SPSS 24.0 (IBM Corp). Categorical and dichotomous data are presented as absolute number count and simple percentages. Normally distributed continuous variables are presented as mean \pm standard deviation. Fisher exact test was used to compare New York Heart Association scores and the frequency of aortic stenosis before and after the intervention. Wilcoxon signed rank test was used to compare pressure gradients before and after the intervention.



VIDEO 1. Surgical procedure for “collar-like” neocommissure in mitral valve repair. Video available at: [https://www.jtcvs.org/article/S2666-2507\(22\)00441-2/fulltext](https://www.jtcvs.org/article/S2666-2507(22)00441-2/fulltext).

Ethical Statement

The study was conducted in accordance with the Declaration of Helsinki (as revised in 2013). The current study was approved by the institutional review board of Nanjing Drum Tower Hospital (2021-604-01; date: November 11, 2021). Informed consent was exempt because of the retrospective nature of the study.

RESULTS

Demographic Data

From July 2016 to June 2021, a total of 62 patients with extensive commissural prolapse were recruited to this study. The follow-up since surgery ranged from 3 to 63 months. The mean age of patients was 51.7 ± 13.8 years (see [Online Data Supplement](#) for patient-level data), and 38 (61%) were female. The New York Heart Association (NYHA) score counts for categories I, II, and III were 12, 40, and 10, respectively. Combined “collar-like” valvular plasty and coronary artery bypass grafting were performed in 7 patients, 5 underwent additional radiofrequency ablation, 8 underwent aortic valve surgery simultaneously, and 74% of “collar-like” valvular plasty patients underwent concomitant tricuspid annuloplasty. All patients received an implant of a 32- to 34-mm Carpentier-Edwards Physio annuloplasty ring (Table 1).

TABLE 1. The baseline demographic and clinical variables

Variable	Value
Age, y	51.7 ± 13.8
Sex (male/female), n	24/38
NYHA classification (I/II/III/IV), n	12/40/10/0
Preoperative TTE	
MR area, cm ²	10.2 ± 2.3
MR (moderate-severe/severe)	16/46
Anterior commissure/posterior commissure lesion, n	22/40
Operative and perioperative variables	
CABG, n	7
RFCA, n	5
AVR/AVP, n	8
TVP, n	46
Minimal Incision, n	34
CPB time, min	62 ± 12
Cross-clamp time, min	36 ± 8
Prolonged mechanical ventilation time, h	7.3 ± 3.2
Post-operative hospital stay, d	6.9 ± 1.4
End diastolic peak flow velocity, m/s	1.1 ± 0.3
Transvalvular pressure gradients (mm Hg)	3.8 ± 1.2
Coaptation height, cm	7.9 ± 1.1

NYHA, New York Heart Association; TTE, transthoracic echocardiography; MR, mitral regurgitation; CABG, coronary artery bypass grafting; RFCA, radiofrequency catheter ablation; AVR, aortic valve replacement; AVP, aortic valve valvuloplasty; TVP, tricuspid valvuloplasty; CPB, cardiopulmonary bypass.

Perioperative Data

Thirty-four (55%) patients underwent minimally invasive surgery. As for operative data, the mean cardiopulmonary bypass time was 62 ± 12 minutes, and crossclamp time was 36 ± 8 minutes. Intraoperative TEE confirmed that all 62 patients with extensive commissural prolapse underwent “collar-like” valvular plasty had no sign of residual regurgitation or only mild regurgitation. No sign of systolic anterior motion and no need for a second aortic crossclamp to redo valvular plasty or mitral valve replacement was seen. The mean mechanical ventilation time was 7.3 ± 3.2 hours. The mean postoperative hospital length of stay was 6.9 ± 1.4 days (Table 1). Over this period, no operative/in-hospital mortality and no adverse complications occurred.

Early and Follow-up Results

Postplasty TEE showed the mean transvalvular pressure gradients were 3.8 ± 1.2 mm Hg, end diastolic peak flow velocity was 1.1 ± 0.3 m/s, and coaptation height was 7.9 ± 1.1 mm (see Online Data Supplement for patient-level data). During the 3- to 6-month follow-up, no deaths or cardiovascular-/valvular plasty-related adverse events occurred. NYHA classification improved in all patients after surgery and all patients claimed to return to normal physical activity. At the recent clinic visit, TTE of patients who

underwent “collar-like” valvular plasty showed neither mitral valve stenosis nor recurrent mitral valve regurgitation more than mild. No cases of bleeding or thrombotic event were observed during follow-up. As a matter of fact, all patients were free from anticoagulant use and their quality of life was restored.

DISCUSSION

The “collar-like” valvular plasty has acceptable early outcomes, reduces transvalvular pressure gradients, preserves coaptation height, and improves NYHA scores in patients with extensive commissural prolapse. MVP is common in patients with valvular heart disease. The fundamental Carpentier techniques and other modified techniques, for instance, triangular, quadrangular, and butterfly resection have been reported with excellent results.^{9,10} Dreyfus and colleagues⁷ proposed the concept “respect when you can, resect when you should”; the debate between leaflet resection and leaflet preservation never ends.¹¹ Altogether, these results were encouragingly showing that mitral valve repair was feasible. However, when it comes to commissural prolapse especially extensive ones, there is no standard procedure obviously better than the others.

Carpentier¹² described the commissural closure when the prolapse is localized and the leaflets are healthy. This is also the concept of the edge-to-edge technique in handling limited commissural prolapse.¹³ Although not “anatomical repair,” De Bonis and colleagues⁵ reported that this “functional repair” can obtain excellent long-term results. However, for certain cases with more extensive commissural prolapse as in Barlow’s disease, much more complicated procedures like leaflet resection,¹⁴ sliding technique for commissure reconstruction,¹⁵ chordal replacement,¹⁶ and papillary muscle reimplantation¹⁷ might be needed. Aubert and colleagues¹⁸ and Shimizu and colleagues⁴ showed that using a variety of techniques, mitral valve with extensive commissural prolapse can be repaired with excellent long-term results. Nevertheless, resection is revocable and requires precision in cutting and suturing. These procedures are too difficult for young surgeons to perform valve repair successfully.

To solve these issues, we introduced a simple, practicable, and effective repair method—the “collar-like” valvular plasty technique. The “collar-like” technique involves an overlapping shape merging from the anterior up toward the posterior leaflet; with the aid of this procedure, the prolapsed commissure can be reconstructed into a neo-commissure. The valvular orifice area in “collar-like” neo-commissure is significantly less than commissural closure, which would decrease the rate of postrepair valvular stenosis. This technique does not increase cardiopulmonary bypass and crossclamp time. Intraoperative TEE confirmed that the “collar-like” technique can obtain an ideal valvular plasty effect. There is no prolonged mechanical ventilation

time or postoperative hospital stay. No operative or in-hospital mortality, and no adverse complications occurred. During the follow-up clinic visit, TTE confirmed acceptable early results, and all patients' quality of life was restored.

CONCLUSIONS

We believe that this simple and practicable technique for combined coaptation height restoration and prolapse elimination. Our experiences show that this technique could offer acceptable early results, and can be handy for every cardiac surgeon, especially young ones.

Conflict of Interest Statement

The authors reported no conflicts of interest.

The *Journal* policy requires editors and reviewers to disclose conflicts of interest and to decline handling or reviewing manuscripts for which they may have a conflict of interest. The editors and reviewers of this article have no conflicts of interest.

References

- Delling FN, Vasan RS. Epidemiology and pathophysiology of mitral valve prolapse: new insights into disease progression, genetics, and molecular basis. *Circulation*. 2014;129:2158-70.
- Otto CM, Nishimura RA, Bonow RO, Carabello BA, Erwin JP III, Gentile F, et al. 2020 ACC/AHA guideline for the management of patients with valvular heart disease: executive summary: a report of the American College of Cardiology/American Heart Association Joint Committee on Clinical Practice Guidelines. *Circulation*. 2021;143:e35-71.
- Duran CM. Surgical techniques for the repair of anterior mitral leaflet prolapse. *J Card Surg*. 1999;14:471-81.
- Shimizu A, Kasegawa H, Tabata M, Fukui T, Takanashi S. Long-term outcomes of mitral valve repair for isolated commissural prolapse: up to 17-year experience. *Ann Thorac Surg*. 2015;99:43-7.
- De Bonis M, Lapenna E, Taramasso M, Pozzoli A, La Canna G, Calabrese MC, et al. Is commissural closure associated with mitral annuloplasty a durable technique for the treatment of mitral regurgitation? A long-term (≤ 15 years) clinical and echocardiographic study. *J Thorac Cardiovasc Surg*. 2014;147:1900-6.
- Lapenna E, De Bonis M, Sorrentino F, La Canna G, Grimaldi A, Torracca L, et al. Commissural closure for the treatment of commissural mitral valve prolapse or flail. *J Heart Valve Dis*. 2008;17:261-6.
- Dreyfus GD, Dulguero F, Marcacci C, Haley SR, Gkouma A, Dommerc C, et al. "Respect when you can, resect when you should": a realistic approach to posterior leaflet mitral valve repair. *J Thorac Cardiovasc Surg*. 2018;156:1856-66.e3.
- Wang D, Wang Q, Yang X, Wu Q, Li Q. Mitral valve replacement through a minimal right vertical infra-axillary thoracotomy versus standard median sternotomy. *Ann Thorac Surg*. 2009;87:704-8.
- Asai T, Kinoshita T, Suzuki T, Shiraishi S, Koike M. Early and follow-up results of butterfly resection of prolapsed posterior leaflet in 76 consecutive patients. *J Thorac Cardiovasc Surg*. 2015;149:1296-300.
- Nakamura K, Orii K, Abe T, Haida H, Hashimoto K, Kuniyama T. Triangular resection versus folding repair for simple posterior mitral leaflet lesions: case-control study. *Cardiovasc Diagn Ther*. 2020;10:1839-46.
- Chan V, Mazer CD, Ali FM, Quan A, Ruel M, de Varennes BE, et al. Randomized, controlled trial comparing mitral valve repair with leaflet resection versus leaflet preservation on functional mitral stenosis: the CAMRA CardioLink-2 Study. *Circulation*. 2020;142:1342-50.
- Carpentier A. Cardiac valve surgery—the "French correction." *J Thorac Cardiovasc Surg*. 1983;86:323-37.
- Maisano F, Torracca L, Oppizzi M, Stefano PL, D'Addario G, La Canna G, et al. The edge-to-edge technique: a simplified method to correct mitral insufficiency. *Eur J Cardiothorac Surg*. 1998;13:240-5; discussion: 245-6.
- lung B, Rousseau-Paziaud J, Cormier B, Garbarz E, Fondard O, Brochet E, et al. Contemporary results of mitral valve repair for infective endocarditis. *J Am Coll Cardiol*. 2004;43:386-92.
- Perier P, Clausnizer B, Mistarz K, Carpentier "sliding leaflet" technique for repair of the mitral valve: early results. *Ann Thorac Surg*. 1994;57:383-6.
- Kasegawa H, Kamata S, Hirata S, Kobayashi N, Mannouji E, Ida T, et al. Simple method for determining proper length of artificial chordae in mitral valve repair. *Ann Thorac Surg*. 1994;57:237-8; discussion: 238-9.
- Jouan J, Tapia M, Cook RC, Lansac E, Acar C. Ischemic mitral valve prolapse: mechanisms and implications for valve repair. *Eur J Cardiothorac Surg*. 2004;26:1112-7.
- Aubert S, Barreda T, Acar C, Leprince P, Bonnet N, Ecochard R, et al. Mitral valve repair for commissural prolapse: surgical techniques and long term results. *Eur J Cardiothorac Surg*. 2005;28:443-7.

Key Words: mitral valve repair, commissure prolapse