

## Case Report

# Bizarre depressed skull fracture by a tile fragment in a young child, causing superior sagittal sinus injury

Jacob Eapen Mathew, Alok Sharma<sup>1</sup>

Department of Neurosurgery, Christian Medical College, Ludhiana – 141 008, Punjab, <sup>1</sup>LTMG Hospital and LTMG Medical College, Sion (West), Mumbai – 400 022, Maharashtra, India

E-mail: \*Jacob Eapen Mathew - [jacobemathew@gmail.com](mailto:jacobemathew@gmail.com); Alok Sharma - [alok276@hotmail.com](mailto:alok276@hotmail.com)

\*Corresponding author

Received: 21 June 10

Accepted: 10 August 10

Published: 16 September 10

DOI: 10.4103/2152-7806.69379

*Surg Neurol Int* 2010, 1:52

This article is available from: <http://www.surgicalneurologyint.com/content/1/1/52>

Copyright: © 2010 Mathew JE. This is an open-access article distributed under the terms of the Creative Commons Attribution License, which permits unrestricted use, distribution, and reproduction in any medium, provided the original author and source are credited.

### This article may be cited as:

Mathew JE, Sharma A. Bizarre depressed skull fracture by a tile fragment in a young child, causing superior sagittal sinus injury. *Surg Neurol Int* 2010; 1:52

Available FREE in open access from: <http://www.surgicalneurologyint.com/text.asp? 2010/1/52/69379>

## Abstract

**Background:** Head injuries following fall from height are not very uncommon in developing countries due to a lack of safety standards. We describe this bizarre injury by a tile fragment penetrating the superior sagittal sinus (SSS) and its successful surgical management.

**Case Description:** A 7-year-old child presented with a tile fragment embedded in the skull, penetrating SSS. Urgent exploration and removal of the foreign body was done to prevent complications like infection and delayed development of intracranial hypertension. Although bleeding from the SSS was a problem, this was tackled by raising the head end and giving pressure with Surgicel and Gelatine sponge. This ensured a favorable outcome.

**Conclusion:** Although compound depressed fractures of the SSS are managed conservatively due to the risk of fatal venous hemorrhage, the unique nature of the injury in this case warranted surgical management. This case illustrates that even in such a scenario, adherence to neurosurgical principles can ensure a good outcome.

**Key Words:** Depressed skull fracture, tile fragment, superior sagittal sinus

## CASE REPORT

Head injuries following fall from height is not very uncommon in developing countries due to a lack of safety standards. A variety of foreign bodies penetrating the cranium has been described in the literature and it often requires operative intervention. However the management of compound depressed fractures of the superior sagittal sinus (SSS) is generally non operative in view of the inherent surgical risks. We describe this bizarre injury by a tile fragment causing a depressed skull fracture over the SSS and its successful surgical management.

## Case Details

A 7-year-old child presented with a history of fall from a height of 10 feet from the roof of his house, 2 hours prior to presentation. He had a history of transient loss of consciousness. On examination, vitals signs were stable, Glasgow Coma Score (GCS) score was 15/15 and pupils were equal and reacting. There was no evidence of systemic injury. Local examination showed that a piece of tile fragment had penetrated the skull in the midline just anterior to the coronal suture [Figures 1 and 2].

Lateral skull X-rays and computed tomography (CT) of the head revealed that the foreign body (FB) had

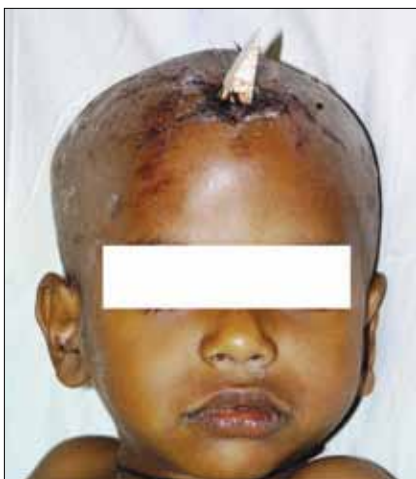

Figure 1: Tile fragment embedded in the skull

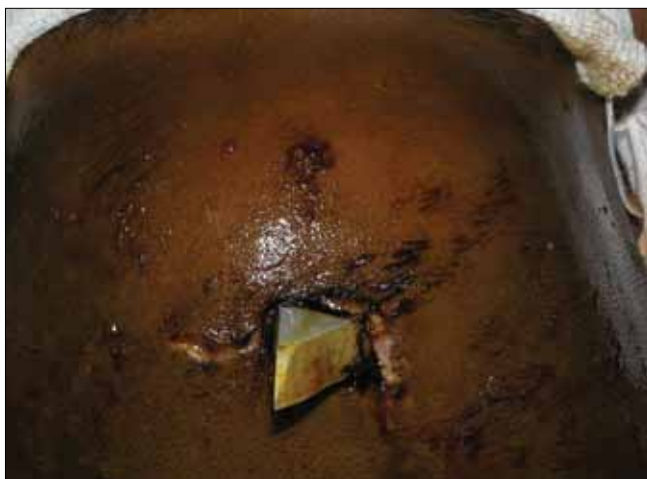

Figure 2: View from the top of the head

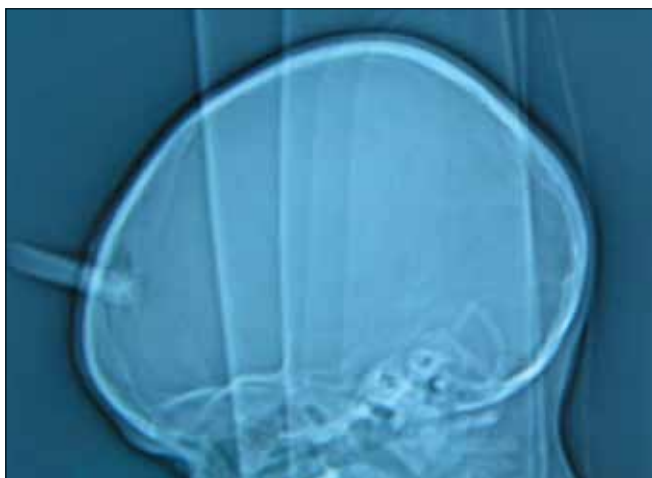


Figure 3: Skull X-ray showing the extent of penetration of the fragment into the skull

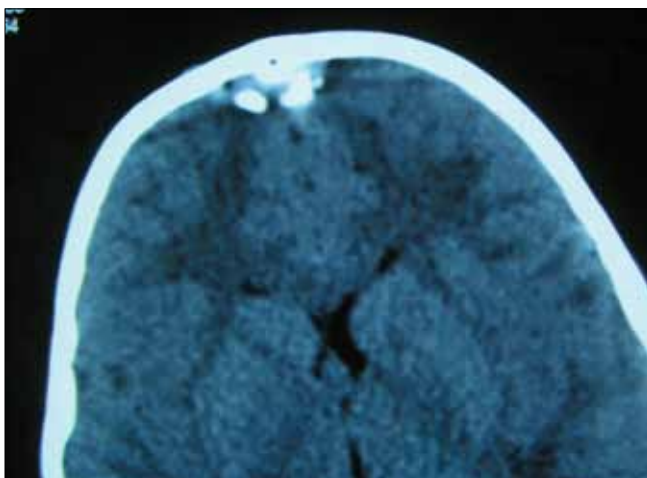


Figure 4: CT brain showing the compression of the SSS by the tile fragment

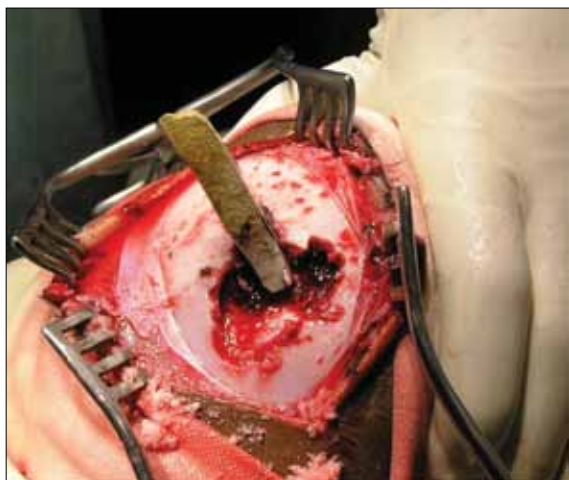

Figure 5: Intraoperative view showing the epidural hematoma around the FB

penetrated 1.5 cm deep to the inner table through a fracture of the skull in the midline [Figures 3 and 4]. We suspected penetration of the SSS. He was taken up for

urgent exploration and removal of the FB. Head end was raised about 30° and continuous saline irrigation was done while a burr hole and craniectomy was done around the FB. There was extradural clot around the FB [Figure 5]. On carefully removing the FB, there was bleeding from the SSS which was controlled with Gelfoam, Surgicel and pressure. After washing the wound, it was closed in layers over a drain. No anticoagulant therapy was used in the peri-operative period. Postoperative period was uneventful and he had no neurological deficits, evidence of infection or symptoms of raised intracranial pressure (suggestive of SSS thrombosis) at the time of discharge. The family was advised to bring the child for cranioplasty at a later date. However, he was lost to follow-up.

## DISCUSSION

Depressed skull fractures involving the SSS are generally treated conservatively as attempts at surgical elevation can cause fatal venous hemorrhage.<sup>[7]</sup> However, not

all cases can be managed conservatively as some cases involve FBs like nails<sup>[8]</sup> or stones.<sup>[1]</sup> Some depressed fractures can cause SSS thrombosis<sup>[9-11]</sup> leading to late deterioration.

Surgery might also be warranted in rare instances of delayed intracranial hypertension in such depressed fractures overlying the SSS, as reported by Fuentes *et al.*<sup>[6]</sup> and Donovan.<sup>[5]</sup> Our patient warranted early surgical treatment in view of contaminated FB to prevent infection and delayed development of intracranial hypertension. Surgical treatment was successful in this unusual case owing to adherence to basic neurosurgical principles of managing SSS injuries, namely, raising the head end, copious irrigation of saline to prevent air embolism and patient pressure tamponade with Surgicel and Gelfoam.

A few additional points merit mention here. The sagittal sinus can be safely transected in its anterior one third, should this become necessary. The sagittal sinus can be repaired in its middle and posterior one third. A bone island surrounding the FB can be created with the help of a high speed drill and the SSS can be mobilized distally and proximally. This can be followed by a direct repair of the SSS. It is also possible to resect the SSS and replace it with a vein or dural graft although it is technically very demanding.<sup>[2-4]</sup>

## REFERENCES

1. Balak N, Aslan B, Serefhan A, Elmaci I. Intracranial retained stone after depressed skull fracture: Problems in the initial diagnosis. *Am J Forensic Med Pathol* 2009;30:198-200.
2. Bederson JB, Eisenberg MB. Resection and replacement of the superior sagittal sinus for treatment of a parasagittal meningioma: Technical case report. *Neurosurgery* 1995;37:1015-9.
3. Bonnal J, Brotchi J. Surgery of the superior sagittal sinus in parasagittal meningiomas. *J Neurosurg* 1978 48(935-45).
4. Caroli E, Orlando ER, Mastronardi L, Ferrante L. Meningiomas infiltrating the superior sagittal sinus: surgical considerations of 328 cases. *Neurosurg Rev* 2006;29:236-41.
5. Donovan DJ. Simple depressed skull fracture causing sagittal sinus stenosis and increased intracranial pressure: Case report and review of the literature. *Surg Neurol* 2005;63:380-4.
6. Fuentes S, Metellus P, Levrier O, Adetchessi T, Dufour H, Grisoli F. Depressed skull fracture overlying the superior sagittal sinus causing benign intracranial hypertension: Description of two cases and review of the literature. *Br J Neurosurg* 2005;19:438-42.
7. Meier U, Gärtner F, Knopf W, Klötzer R, Wolf O. The traumatic dural sinus – A clinical study. *Acta Neurochir (Wien)* 1992;119:91-3.
8. Sani S, Jobe KW, Byrne RV. Successful repair of an intracranial nail-gun injury involving the parietal region and the superior sagittal sinus: Case report. *J Neurosurg* 2005;103:567-9.
9. Tamimi A, Abu-Elrub M, Shudifat A, Saleh Q, Kharazi K, Tamimi I. Superior sagittal sinus thrombosis associated with raised intracranial pressure in closed head injury with depressed skull fracture. *Pediatr Neurosurg* 2005;41:237-40.
10. Tanaka H, Tanaka H, Kobata H. Superior sagittal sinus occlusion caused by a compound depressed skull fracture: A case treated by emergency surgery. *No Shinkei Geka* 2004;32:753-8.
11. Yadav YR, Parihar V, Sinha M, Jain N. Simple depressed skull fracture causing posterior third superior sagittal sinus occlusion and elevated intracranial pressure. *Neurol India* 2009;57:830-1.