

# Cutaneous Cancers in Nigerian Albinos: A Review of 22 Cases

Oluwafemi Olasupo Awe<sup>1,2</sup>, Terence Akhator Azeke<sup>3</sup>

<sup>1</sup>Department of Surgery, Plastic Surgery Unit, Faculty of Clinical Sciences, Ambrose Alli University, Ekpoma, Departments of <sup>2</sup>Surgery and <sup>3</sup>Morbid Anatomy and Histopathology, Irrua Specialist Teaching Hospital, Irrua, Edo State, Nigeria

ABSTRACT

**Context:** Albinism is an inherited disorder of hypopigmentation involving the skin, eyes, and hair. This disorder results in the absence or reduction in melanin production. There are two main types of albinism which are ocular albinism and oculocutaneous albinism. It could also be classified as syndromic or nonsyndromic the melanin, which protects from the harmful effect of ultraviolet radiation of the sun on the normal skin, is deficient in the albino, predisposing them more, to cutaneous malignancies. **Aim:** This study is to highlight the epidemiology of cutaneous cancers in albinos in sub-urban Nigeria. **Methodology:** This is a retrospective review of all albinos with histological diagnoses of cutaneous malignancies that presented to Irrua Specialist Teaching Hospital, Irrua Edo State, Nigeria between September 2010 and August 2016. The following details were extracted from the patients' case-notes, operation register, and the histopathology register. These data include age, gender, site of the lesion, the diagnosis, no of lesions excised, and duration of the lesion (s). These were collated and analyzed using SPSS version 22. **Results:** There were 22 albinos with histopathologically diagnosed cutaneous malignancies. There were 11 males and 11 females with male:female of 1. The age range is from 25 to 55 years with the mean of 34.68. **Conclusion:** Albinism is one of the most common causes of cutaneous malignancies, and majority of them present with locally advanced lesions that will need excision biopsy resulting in disfigurement. This problem can be prevented in many cases with proper community education, support, and free health care. There is also need for them to present early whenever they noticed any skin changes.

**KEYWORDS:** Albinos, cutaneous cancers, Nigeria, problems and care

## INTRODUCTION

Albinism is an inheritable disorder that affects the melanin production due to the absence or defect in tyrosinase enzyme which convert tyrosine to dioxyphenylalanine, the precursor of melanin.<sup>[1]</sup> This leads to the absence or reduction in melanin produced in the melanocytes. This affects the skin, eyes, and hair. There are two main types of albinism, i.e., oculocutaneous type and ocular albinism (OA). There are the syndromic types which are mainly oculocutaneous albinism with bleeding diathesis (Hermansky–Pudlak syndrome), with leukopenia and high predisposition to infection (Chediak–Higashi syndrome) or with immunodeficiency and neuropathy (Griscelli syndrome).<sup>[2]</sup> Melanin has been found to protect the skin from the harmful effects of the ultraviolet radiation of the sun. The absence of

this protective pigment in albinos predisposed them to sunburns and subsequent dysplastic changes in the skin which may later progress to malignant transformation. African albinos are more prone to having cutaneous cancers because they live close to the equator where the exposure to ultraviolet radiation of the sun is very high compared to Caucasian albinos. The most common of the skin cancers documented among the albinos has been the squamous cell carcinoma. Yakubu and Mabogunje (1995) reported squamous cell carcinoma of 83% in Northern Nigeria;<sup>[3]</sup> Luande *et al.* have 96%

**Address for correspondence:** Dr. Oluwafemi Olasupo Awe, Department of Surgery, Irrua Specialist Teaching Hospital, Km 86, Benin- Auchu Expressway, PMB 008, Irrua, Edo State, Nigeria. E-mail: olasupoawe06@yahoo.com

Access this article online	
<b>Quick Response Code:</b> 	<b>Website:</b> www.nigerianjsurg.com
	<b>DOI:</b> 10.4103/njs.NJS_23_17

This is an open access journal, and articles are distributed under the terms of the Creative Commons Attribution-NonCommercial-ShareAlike 4.0 License, which allows others to remix, tweak, and build upon the work non-commercially, as long as appropriate credit is given and the new creations are licensed under the identical terms.

**For reprints contact:** reprints@medknow.com

**How to cite this article:** Awe OO, Azeke TA. Cutaneous cancers in Nigerian albinos: A review of 22 cases. Niger J Surg 2018;24:34-8.

in Tanzania,<sup>[4]</sup> and Opara and Jiburum had 75% in their series.<sup>[5]</sup> The incidence of malignant melanoma (MM) is rare in albinos. Although there have been some few reports in the literature, especially in tyrosinase-positive albinism.<sup>[4-7]</sup> These are all hospital-based studies and cannot be representative of the population. The MM in albinos are usually hypopigmented (amelanotic) and are similar to pyogenic granuloma clinically. This can be confirmed histologically by the use of HMB-45 stain which aid in the identification of melanocytic tumors, even in the absence of noticeable pigmentation. Most of the African albinos present to the hospital with locally advanced lesions with diameter >4 cm due to poverty and ignorance. This resulted in significant disfigurement especially when the lesions are on the head and neck and also the need for combination therapy.<sup>[4,5]</sup>

**METHODOLOGY**

This is a 6 years’ retrospective study of all the albinos with histological diagnoses of cutaneous malignancies which presented to the Irrua Specialist Teaching Hospital, Irrua Edo State, Nigeria, from September 2010 to August 2016. The details of the patients were obtained from the Medical Records Department of the Hospital. The details were extracted from the patients’ case-notes, operation register, and the histopathology register. These data include age, gender, occupation, site of the lesion, the diagnosis, no of lesions excised, and duration of the lesion (s). The data were collated and analyzed using the SPSS version 22 (IBM Inc., California, USA). The diagnoses were made by the two consultant plastic surgeons (one of them is the author) and confirmed by the four consultant pathologists (one of them is the coauthor).

**RESULTS**

There were 22 cases of histological diagnoses of cutaneous malignancies in albinos within the period studied. They constitute 47.8% of all the cutaneous malignancies diagnosed during the same period in the hospital. The ages ranged from 25 to 55 years (mean 34.68 years with standard deviation 8.86, median 32 years). The majority of the patients is in the third and fourth decade of life. Male to female ratio is equal. There were 11 (50%) males and 11 (50%) females. Most of the patients were farmers and artisans (68.2%) as shown in Figure 1. Table 1 shows the type distribution of the cutaneous malignancies. The most common of these malignancies was squamous cell carcinoma (68.2%) followed by basal cell carcinoma (22.7%). The head and neck [Table 2] was the most common site for malignancies in albinos accounting for 63.6% (14). Most of the patients presented with multiple lesions that needed to be excised. Table 3

shows the number of lesion distribution. The number of lesions correlated directly with the duration of the lesion in Table 4. Few of the patients are shown in the Figures 2-6.

There was mortality in four patients (18.2%). The mortality includes three squamous cell carcinomas and one had MM. One of them who had squamous cell

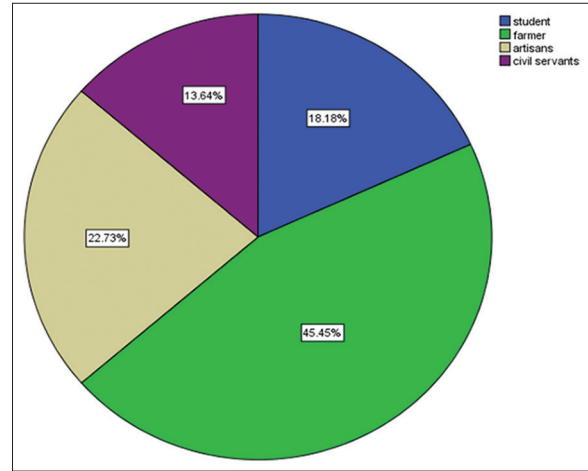


Figure 1: Occupation of the patients

Table 1: Histological diagnosis of the lesions

Valid	Histological diagnosis		
	Frequency (%)	Valid percentage	Cumulative percentage
Squamous cell carcinoma	15 (68.2)	68.2	68.2
Basal cell carcinoma	5 (22.7)	22.7	90.9
Malignant melanoma	2 (9.1)	9.1	100.0
Total	22 (100.0)	100.0	

Table 2: Sites of the lesions

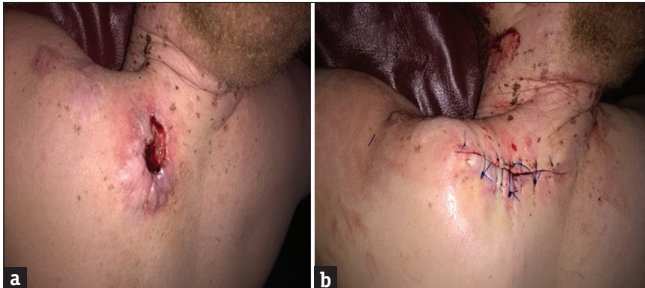
Valid	Sites of the lesions		
	Frequency (%)	Valid percentage	Cumulative percentage
Head and neck	14 (63.6)	63.6	63.6
Upper trunk	5 (22.7)	22.7	86.4
Upper limb	2 (9.1)	9.1	95.5
Lower trunk	1 (4.5)	4.5	100.0
Total	22 (100.0)	100.0	

Table 3: The number of lesions

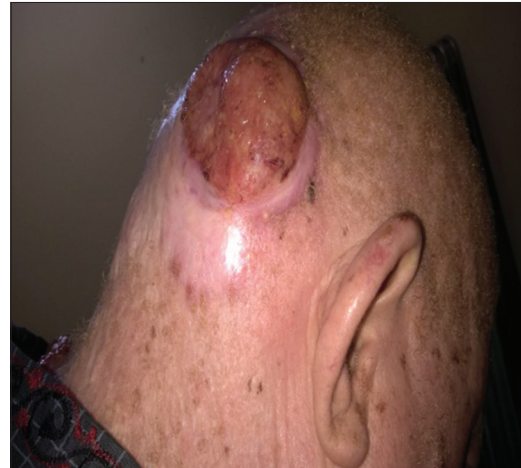Valid	The number of lesions		
	Frequency (%)	Valid percentage	Cumulative percentage
1.00	9 (40.9)	40.9	40.9
2.00	8 (36.4)	36.4	77.3
3.00	4 (18.2)	18.2	95.5
4.00	1 (4.5)	4.5	100.0
Total	22 (100.0)	100.0	

**Table 4: Number of lesion × duration of the lesion crosstabulation**

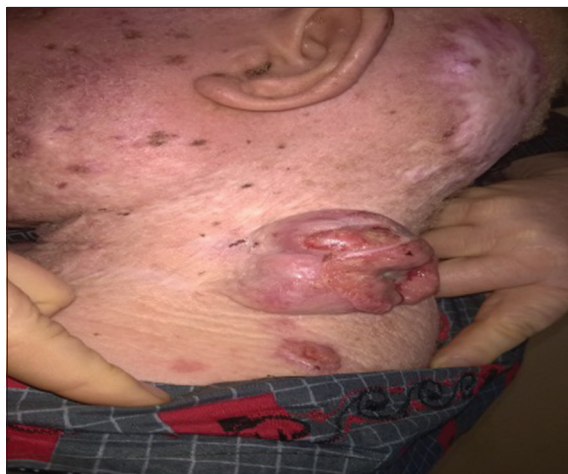Number of lesion	Duration of the lesion in months															Total
	4.00	5.00	6.00	7.00	8.00	9.00	10.00	12.00	13.00	14.00	15.00	16.00	18.00	20.00	21.00	
1.00	1	1	1	0	2	2	0	0	0	0	0	0	1	0	1	9
2.00	0	0	0	1	0	0	2	0	1	1	1	0	1	1	0	8
3.00	0	0	0	0	0	0	0	2	0	0	0	1	0	1	0	4
4.00	0	0	0	0	0	0	0	0	0	0	0	0	1	0	0	1
Total	1	1	1	1	2	2	2	2	1	1	1	1	3	2	1	



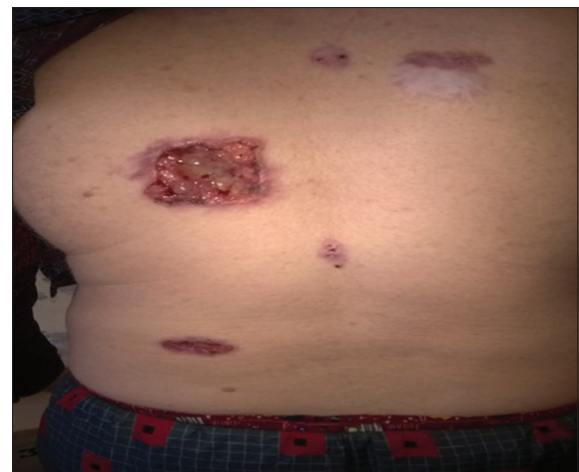**Figure 2:** (a) Squamous cell carcinoma on the upper back (b) after excision and closure of the lesion



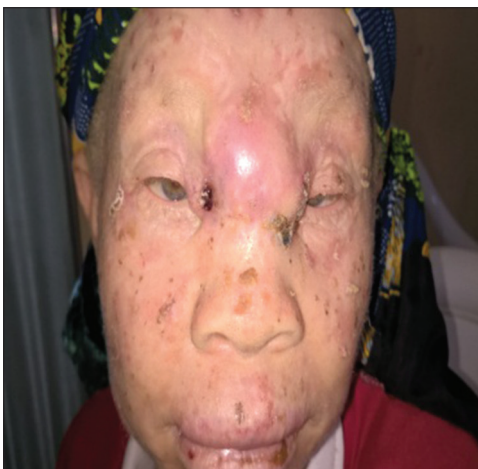**Figure 3:** Basal cell carcinoma on the head



**Figure 4:** Malignant melanoma on the neck



**Figure 5:** Squamous cell carcinoma on the lower back



**Figure 6:** Squamous cell carcinoma on the frontonasal aspect of the face

carcinoma died from assault while the rest, from the complications of the disease.

**DISCUSSION**

Albinism is an inherited disorder resulting in the absence or reduction in production of melanin by the melanocytes in the body. The melanocytes are mainly found in the skin, the pigmented part of the eye, and the peripheral nervous system. Patients with albinism always present with hypopigmentation of these part of the body and characteristic features.

Melanin protects from the harmful effects of the ultraviolet radiation of the sun. The radiation is more in the countries closer to the equator like Nigeria and predisposes Nigerian albinos to higher incidence of cutaneous cancers. The two main types of albinism are OA and oculocutaneous albinism. All the patients in this study are oculocutaneous type as expected. They presented with florid type of lesions due to neglect, poverty, and ignorance. In fact, in some communities in Sub-Sahara Africa, they are considered to demonic or reservoir of evil spirit, and so they abandoned by the parents to be care for by the aged grandparents in the remote places.<sup>[5]</sup> There is high incidence of cutaneous cancers in albinos which account for about 50% of the whole cutaneous cancers burden in our hospital within the period of review this is very high, compared to about 2.5% reported by Yakubu and Mabogunje<sup>[3]</sup> and Asuquo and Ebughe reported 18.4% in Calabar, Southern Nigeria<sup>[8]</sup> and 16.7 was reported in Port Harcourt, Nigeria.<sup>[9]</sup> The high incidence may probably be due to a small sample size or due to increase awareness to treatment among the albinos and their caregivers. The age range in this study is usually in the third to the sixth decade of life. There is a rare incidence of cutaneous cancers in the first and decade of life in albinos, which was also reported by Yakubu and Mabogunje.<sup>[3]</sup> This is because it takes some time for a malignant transformation of the solar (actinic) keratosis in these patients. Majority of the albinos presented in the third and the fourth decade of life with the mean age of 34.68 years and median age of 32 years. Previous studies documented a male preponderance with male to female ratio almost approaching two, but we found equal incidence just as the study by Opara and Jiburum.<sup>[5]</sup> This may be due to improve girl education and acceptance of the people with albinism in the community. The cutaneous cancers are the major risk associated with albinism and are thought to be major cause of death in African albinos.<sup>[5,7,10]</sup> The most frequent cancer in these patients was squamous cell carcinoma which account for 68.3%, it is consistent with previous reports globally.<sup>[4,5,7,11]</sup> Although it is slightly less than them. This is followed by basal cell carcinoma and then the rare MM. It is only about 32 cases of MM that have reported in literature previously.<sup>[12]</sup> In this series, there were 5 cases (22.7%) of basal cell carcinomas and 2 cases (9.1%) of MMs. The cutaneous cancers in albinos were usually found in the head and neck of the body because this is usually exposed to sunlight and hence, ultraviolet radiation. About 63.6% (14) of the patient in this study had their lesions on the head and neck region only. This is very

important also, because of the cosmetic implications. In this study, the number of lesion increases in most cases as the duration of the lesions increases. This is because there are usually multiple dysplastic lesions (actinic or solar keratosis) on the body and as time goes on these will begin to transform one after the other to full-blown malignant lesions. Nearly 40.9% of the patient presented with one malignant lesion while the rest had multiple malignant lesions. It was found that 88.9% of those patients with one lesion presented with duration of lesion <10 months. Management of these patients pose serious challenges due to late presentation come most of the time, include locally invasive lesion that will need reconstructive surgeries, the need for chemotherapy (vincristine, cisplatin, and doxorubicin) which are very expensive and not readily available in the subregion, some had recurrence, and need radiotherapy which is not available in our center, necessitating referrals. Many of our patients could not afford this treatment protocol and resort to only surgical excision and tissue cover, either skin grafting in most cases or flaps in few. Many of the albinos have low socioeconomic status, this most likely due to believe of the community leading to rejection. The ocular problems also affect the academic performance of those that went to school making them to drop-out of school. Cutaneous cancers in albinism could be preventable to a reasonable extent, so early education of the albinos and their caregivers, about the care for their skin. The skin can be protected from ultraviolet radiation by staying indoor most of the time, avoid wearing sleeveless shirts or blouse, wearing of bowler hats, application of sunscreen creams and always using umbrella whenever there is need to enter under the sun. Provision of subsidized or free health care for albinos in our country will almost reduce the burden of cutaneous cancer significantly by encouraging early presentation of skin lesions and cheaper treatment. The establishment of the Albino foundation or groups in the locality, networking with the national body will go a long way to improve the welfare of the albinos.

## CONCLUSION

There seem to be increase in hospital presentation of cutaneous cancers in albinos over the last decades. The percentage of albinos, in patients with cutaneous cancers has been progressively increasing. This may be as a result of increase awareness to treatment and many of these patients are surviving from infanticide and neglect. Although there is still late presentation compared to those in the developed countries. There is more work to be done to increase awareness in the community and education to improve prevention with used of simple

measures such as wearing of long robes, long sleeve shirts, wide border hats, using of sunscreen creams, and indoor employments. Early presentation of any suspicious lesion in the hospital should be encouraged, so that minimally invasive surgery could be done with little or no disfigurement.

#### Declaration of patient consent

The authors certify that they have obtained all appropriate patient consent forms. In the form the patient(s) has/have given his/her/their consent for his/her/their images and other clinical information to be reported in the journal. The patients understand that their names and initials will not be published and due efforts will be made to conceal their identity, but anonymity cannot be guaranteed.

#### Acknowledgment

I profusely acknowledge the heads of the Medical Records Department and the Operating Theater of Irrua Specialist Teaching Hospital, Irrua for their assistance during the study.

#### Financial support and sponsorship

Nil.

#### Conflicts of interest

There are no conflicts of interest.

## REFERENCES

- Oetting WS, King RA. Molecular basis of oculocutaneous albinism. *J Invest Dermatol* 1994;103:131S-136S.
- Kinnear PE, Tuddenham EG. Albinism with haemorrhagic diathesis: Hermansky-Pudlak syndrome. *Br J Ophthalmol* 1985;69:904-8.
- Yakubu A, Mabogunje OA. Skin cancer in Zaria, Nigeria. *Trop Doct* 1995;25 Suppl 1:63-7.
- Luande J, Henschke CI, Mohammed N. The Tanzanian human albino skin. Natural history. *Cancer* 1985;55:1823-8.
- Opara KO, Jiburum BC. Skin cancers in albinos in a teaching hospital in Eastern Nigeria – Presentation and challenges of care. *World J Surg Oncol* 2010;8:73.
- Awe OO, Esezobor EE, Aigbonoga QO. Malignant melanoma in a Nigerian oculocutaneous Albino. *Nig J Plast Surg* 2015;11: 68-70.
- Mabula JB, Chalya PL, Mchembe MD, Jaka H, Giiti G, Rambau P, *et al.* Skin cancers among albinos at a university teaching hospital in Northwestern Tanzania: A retrospective review of 64 cases. *BMC Dermatol* 2012;12:5.
- Asuquo ME, Ebughe G. Cutaneous cancers in Calabar, Southern Nigeria. *Dermatol Online J* 2009;15:11.
- Datubo-Brown DD. Primary malignant skin tumors in Nigerians. *J Natl Med Assoc* 1991;83:345-8.
- Aquaron R. Oculocutaneous albinism in Cameroon. A 15-year follow-up study. *Ophthalmic Paediatr Genet* 1990;11:255-63.
- Asuquo ME, Otei OO, Omotoso J, Bassey EE. Letter: Skin cancer in albinos at the university of Calabar teaching hospital, Calabar, Nigeria. *Dermatol Online J* 2010;16:14.
- Perry PK, Silverberg NB. Cutaneous malignancy in albinism. *Cutis* 2001;67:427-30.