

CASE REPORT

Nagoya J. Med. Sci. 75. 287 ~ 293, 2013

COMPLETE BONE REMODELING AFTER CALCAR RECONSTRUCTION WITH METAL WIRE MESH AND IMPACTION BONE GRAFTING: A CASE REPORT

TOSHIKI IWASE, M.D., Ph.D., ATSUSHI KOUYAMA, M.D., and NAOYA MATSUSHITA, M.D.

Department of Orthopedic Surgery, Hamamatsu Medical Center, Hamamatsu, Japan

ABSTRACT

We report the histological findings of a reconstructed calcar region four years after femoral impaction bone grafting using metal wire mesh for a case with massive defect of the proximal part of the femur. Thin cortical bone was formed just beneath the metal wire mesh and viable trabecular bone containing a small amount of granulation tissue was observed even at the bone-cement interface. Almost no necrotic bone was seen throughout the remodeled bony layer. Histological findings of the present case suggest that calcar reconstruction with impaction bone grafting using a metal wire mesh is a biologically and mechanically favorable reconstruction method for femoral revision cases combined with proximal medial segmental cortex defect.

Key Words: Femoral calcar; impaction bone grafting; remodeling; allograft

INTRODUCTION

Impaction bone grafting is a well-recognized and established surgical technical option for femoral reconstruction.^{1,2)} Some biopsy or autopsy studies have confirmed histological incorporation of allograft around the implant.^{3,4)}

Although surgeons are advised that the segmental bony wall defect should be contained using a metal wire mesh, the biological remodeling ability of grafted allograft bone is not well known.

We report the histological findings of a reconstructed calcar region four years after femoral impaction grafting using a metal wire mesh. The patient and her families were informed that data from the case would be submitted for publication, and gave their consent.

CASE REPORT

A 67-year-old woman visited our institute to undergo second revision surgeries for aseptic loosening of her bilateral total hip arthroplasty (THA).

The patient had undergone primary cementless THA at 47 years of age on her right hip

Received: July 8, 2013; accepted: August 1, 2013

Corresponding author: Toshiki Iwase, M.D., Ph.D

Department of Orthopedic Surgery, Hamamatsu Medical Center, 328 Tomitsuka-cho, Naka-ku, Hamamatsu, Shizuoka Pref. 432-8580, Japan

Phone: +81-53-453-7111, Fax: +81-53-451-2768, Email: tossy.iwase@gmail.com

joint, and at 49 years of age on her left hip joint because of severe bilateral osteoarthritis due to hip dysplasia.

Seven years after the primary THA on her right hip joint and five years after that on her left hip joint, revision surgeries were carried out using cementless THA because of aseptic loosening.

In 2007, eleven and nine years after the revision surgeries for her right and left hip joints, respectively, the patient was advised by a local doctor to visit our hospital for treatment of aseptic loosening of the bilateral total hip implants with severe bony wall defect of the proximal medial femoral cortex (Fig. 1).

The second revision THA was carried out on her right and left hip joints consecutively using an impaction bone grafting technique for femur. In the surgery on her right hip joint, the acetabulum was reconstructed using a Reinforcement ring (K-MAX KT plate, Japan Medical Materials Co., Ltd., Osaka, Japan) and morcellized bone graft. After the large proximal medial femoral segmental defect (calcar defect) on her right femur had been contained using a metal wire mesh (Rim mesh large; Stryker Benoist Girard, Herouville-Saint-Clair, France) with double-strand cerclage wires, morcellized cancellous allograft was tightly impacted to build up the “neo-medullary canal” referring to the impaction bone grafting technique (Fig. 2a, b). The femoral shaft was augmented with a strut allo-bone plate because there was segmental femoral cortical defect around the stem tip. The collarless double-tapered polished Exeter stem (Stryker Orthopaedics, Mahwah, NJ, USA) was inserted by the modern cementing technique (Fig. 3a).

At the surgery for her left hip joint, the acetabulum containing a small supero-lateral segmental

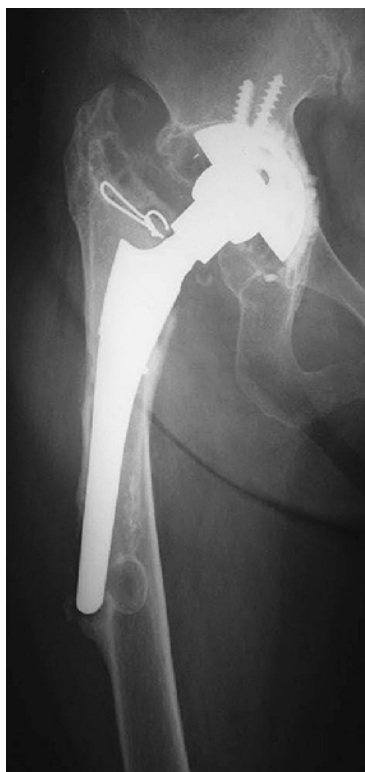

Fig. 1 Radiograph taken at pre-revision total hip arthroplasty of the right side.

HISTOLOGY OF CALCAR RECONSTRUCTION

acetabular wall defect was reconstructed using a metal wire mesh, and the small calcar defect of the femur was also contained with a metal wire mesh.

After the second revision THAs, the patient returned to her daily living activity as a housewife using a single crutch, and continued to be followed at our hospital every six months.

In March 2011, four years after the second revision THAs, the patient visited our emergency clinic complaining of high fever and bilateral hip joint pain. Aspirated joint fluid from bilateral hip joint was turbid and gram-positive coccus was found by microscopic investigation. On the radiographic findings, there was no radiolucent line or osteolysis around all implants (Fig. 3b). On the day of the patient's visit, emergency open irrigation for the bilateral hip joint was carried out. However, as the infection state had not been controlled, removal of all implants and one-stage reconstruction were planned.

The patient's consent was obtained for biopsy specimens from the reconstructed calcar of the right femur.

At the time of removal of implant and metal wire mesh of the right hip joint, the most proximal part of the calcar was cut using an oscillating saw after removal of the wire mesh and sent to the pathology department of our hospital. After removal of the metal mesh at the proximal femur, well-regenerated femoral cortex was found (Fig. 4).

The specimen was fixed in 10% neutral buffered formalin, decalcified, routinely processed, and stained with hematoxylin and eosin for examination by light microscopy.

At this surgery, there was inflammatory soft tissue around the stem neck. After removal of all the implants and inflammatory soft tissue debridement, one-stage reconstruction using antibiotic-loaded bone cement was carried out. At the final follow-up of 2 years after reconstruction, there were no serological and radiological findings indicating infection recurrence.

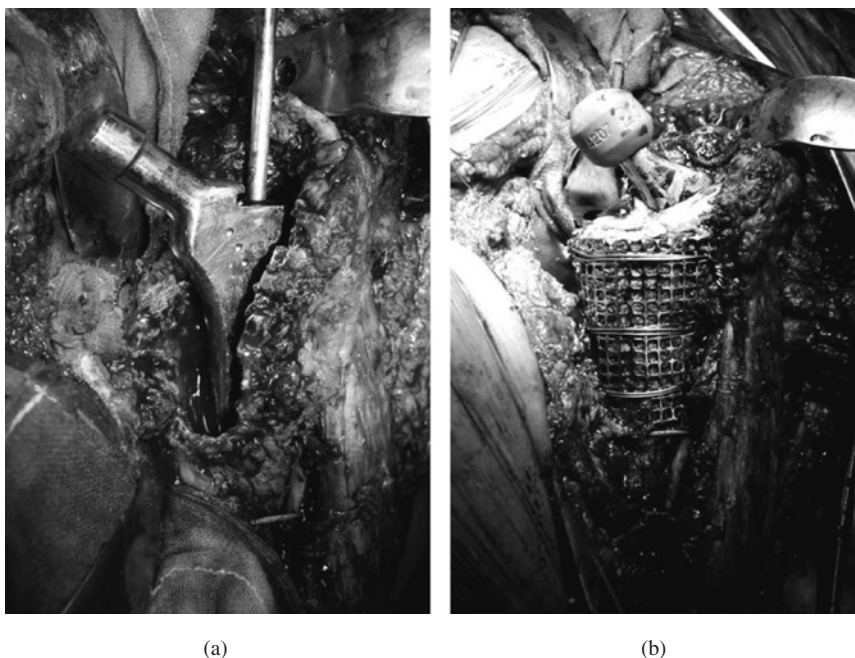


Fig. 2 (a) Intra-operative findings of the segmental defect of the right proximal femur.
(b) Reconstruction with metal wire mesh and impaction bone grafting.

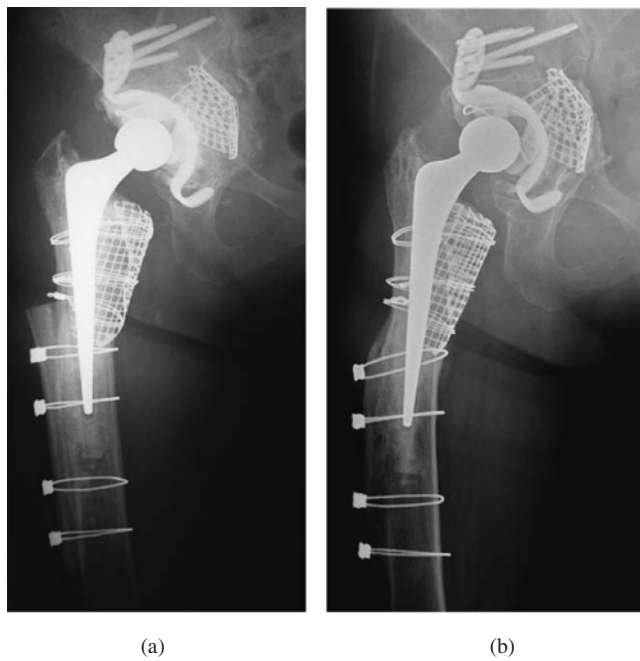


Fig. 3 (a) Post-operative radiograph after the second revision THA.
(b) Radiograph taken at acute infection of the right hip joint (four years after the second revision THA). No radiolucent line or osteolysis around the implants was seen.

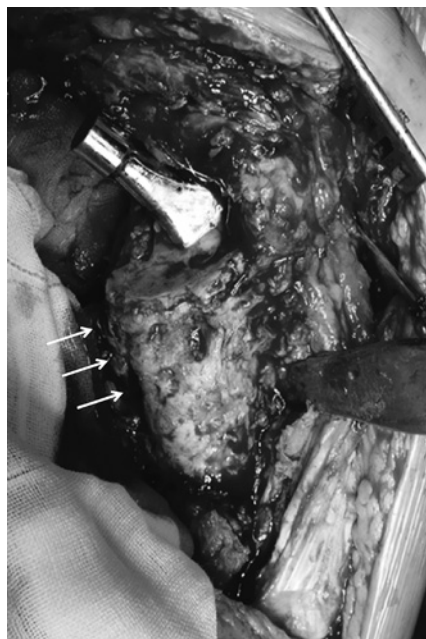


Fig. 4 After removal of the metal wire mesh. Well-regenerated femoral cortex was seen (arrows).

HISTOLOGY OF CALCAR RECONSTRUCTION

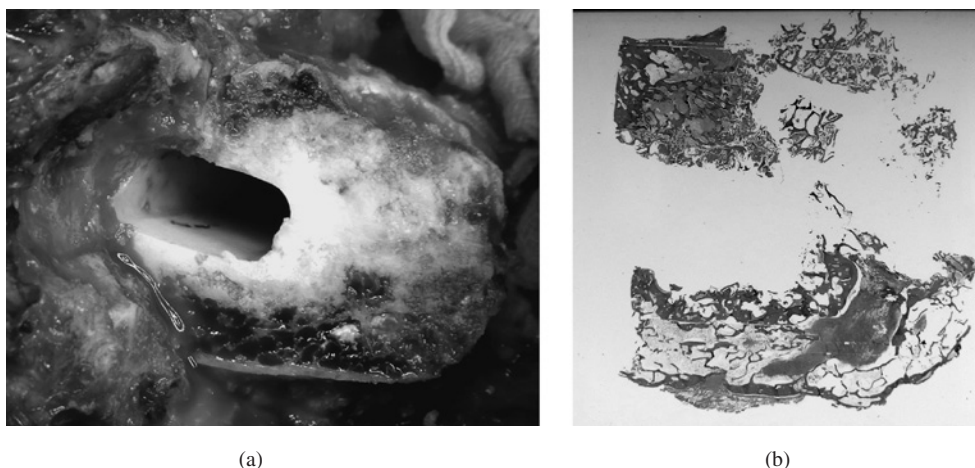


Fig. 5 (a) Surface after resection of the most proximal part of the calcar region. No soft tissue invasion into the cement-bone interface was seen.
 (b) Low-magnification photomicrograph of the biopsy specimen of the resected calcar region (stained with hematoxylin and eosin). Three-zone formation of cortical bone (c), interface between living tissue and cement (i), and bone trabeculae buried in the cement (t) were seen

Histological findings

At the cut surface of the calcar, there was no soft tissue invasion into the cement-bone interface (Fig. 5a). In a low-power magnified view (Fig. 5b), the specimen demonstrated the three-zone formation of cortical bone, an interface between living tissue and cement, and bone trabeculae buried in the cement, which were described previously.³⁾

At the region closest to the surface of the section, thin cortical bone was formed. This cortical bone layer was partially covered with thin fibrous tissue, which was formed just beneath the metal wire mesh (Fig. 6a).

At the middle layer of the specimen, viable trabecular bone containing normal bone marrow and some granulation tissue was observed. In the granulation tissue at this middle layer, a small amount of metal and polyethylene debris surrounded by some multinuclear giant cells was observed (Fig. 6b). However, the origin of this metal and polyethylene debris was uncertain.

Even at the deepest layer of the bone-cement interface, no necrotic bone was found throughout the section (Fig. 6c). Moreover, Howship's lacuna, showing active bone remodeling, was also observed (Fig. 6d).

DISCUSSION

Femoral reconstruction for cases with segmental defect is technically challenging in revision total hip arthroplasty. Several surgical options including cemented and cementless techniques have been reported⁵⁾, and bone stock recovery with stable prosthetic reconstruction is always required to achieve post-operative implant longevity.

Although impaction bone grafting and cemented polished collarless double-tapered stem have been widely used on the femoral side and a high success rate after revision surgery with this technique has been reported^{1, 2)}, some complications such as early massive subsidence in cases with cortical wall defect may compromise the result.⁶⁾

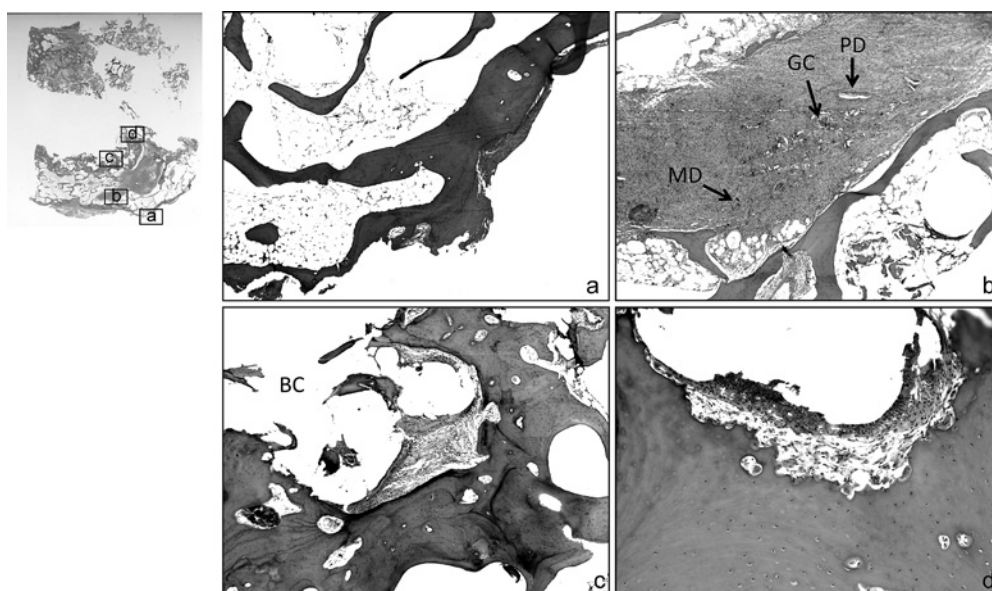


Fig. 6 High-magnification photomicrographs of the biopsy specimen of the resected calcar region. (Upper left: A low-magnification photomicrograph of the whole specimen and each alphabet indicates the place where high-magnification photomicrograph was taken.) (Stained with hematoxylin and eosin)

(a) Thin cortical bone layer covered with thin fibrous tissue was seen at the most superficial region.

(b) At the middle layer of the grafted bone, viable trabecular bone with normal bone marrow and some granulation tissue was observed.
(PD: polyethylene debris, GC: giant cell, MD: metal debris)

(c) At bone-cement interface, well-remodeled trabecular pattern was seen.
Some fibrous tissue existed at the interface. (BC: bone cement)

(d) Howship's lacuna, containing some multinuclear large cells, was found at the bone-cement interface.

As the compressive force at the cement-bone interface of loaded cemented polished double-tapered stem is largest around the proximal medial part of the femur⁷⁾, reconstruction of stable calcar wall is undoubtedly an important technical key to the procedure.²⁾

Bolder *et al.* reported that, in their *in vitro* study, initial stem stability was comparable between reconstruction for calcar wall defect using strut graft and that using a metal wire mesh with morcellized bone.⁸⁾ Moreover, they also reported that the wire mesh allowed more revascularization into the graft than the strut graft in impaction bone grafting.⁹⁾

These findings suggest that reconstruction for calcar wall defect with a metal wire mesh in impaction bone grafting has mechanical and biological benefits.

Although a stainless steel wire mesh and bone cement seemed to have an adverse effect on the biological process of bone graft incorporation in an animal study¹⁰⁾ and wide soft tissue dissection from femur is necessary in applying metal mesh, some previous biopsy studies of clinical cases^{3,5)} suggested that partial viable bone remodeling after impaction bone grafting could occur even beneath a metal wire mesh. However, to the best of our knowledge, no reports have described that complete remodeling between bone cement and a metal wire mesh can be achieved in the calcar region.

The present case showed complete viable bone regeneration between bone cement and a metal wire mesh at four years after impaction bone grafting, and even showed continuing active remodeling activity close to the bone cement layer.

HISTOLOGY OF CALCAR RECONSTRUCTION

With regard to the histological view, calcar reconstruction with a metal wire mesh and impaction bone grafting is a reasonable option for bone stock recovery at the proximal medial part of the femur.

REFERENCES

- 1) Gie GA, Linder L, Ling RS, Simon JP, Slooff TJ, Timperley AJ. Impacted cancellous allografts and cement for revision total hip arthroplasty. *J Bone Joint Surg Br.* 1993; 75: 14–21.
- 2) Iwase T, Otsuka H, Katayama N, Fujita H. Impaction bone grafting for femoral revision hip arthroplasty with Exeter Universal stem in Japan. *Arch Orthop Trauma Surg.* 2012; 132: 1487–94.
- 3) Ling RSM, Timperly AJ, Linder L. Histology of cancellous impaction grafting in the femur. A case report. *J Bone Joint Surg Br.* 1993; 75: 693–6.
- 4) Buttaro M, Araujo GS, Araujo ES, Comba F, Piccaluqa F. Viability of impacted bone allografts under metal mesh at the calcar in revision surgery of the hip. A case report. *J Bone Joint Surg Br.* 2008; 90: 228–31.
- 5) Hartman CW, Garvin KL. Femoral fixation in revision total hip arthroplasty. *Instr Course Lect.* 2012; 61: 313–25.
- 6) Nelissen RG, Valstar ER, Pöll RG, Garling EH, Brand R. Factors associated with excessive migration in bone impaction hip revision surgery: A radiostereometric analysis study. *J Arthroplasty.* 2002; 17: 826–33.
- 7) Kaneuji A, Yamada K, Hirosaki K, Takano M, Matsumoto T. Stem subsidence of polished and rough double-taper stems: In vitro mechanical effects on the cement-bone interface. *Acta Orthopaedica.* 2009; 80: 270–6.
- 8) Bolder SB, Schreurs BW, Verdonschot N, Ling RS, Slooff TJ. The initial stability of an Exeter femoral stem after impaction bone grafting in combination with segmental defect reconstruction. *J Arthroplasty.* 2004; 19: 598–604.
- 9) Bolder SBT, Schreurs BW, Verdonschot N, Veth RP, Buma P. Wire mesh allows more revascularization than a strut in impaction bone grafting. An animal study in goats. *Clin Orthop.* 2004; 423: 280–6.
- 10) Roidis N, Karachalios T, Khaldi L, Stamos K, Lyritis GP. The role of stainless steel wire mesh and cement in bone allograft incorporation in impaction grafting technique: an experimental study in rabbits. *J Arthroplasty.* 2003; 18: 484–93.