

Practical Techniques to Ensure Success in Digital Ring Avulsion Injuries

Sonya Gardiner, MB BChir MA,
FRCS (Plast)*
Thessa Rebecca Friebel, MD,
MD(Res)*
Juliette Bray, BSc (Hons)
Physiotherapy†
Meera Anadkat, BSc (Hons)
Physiotherapy†
Dariush Nikkhah, BM, MSc,
FRCS(Plast)*

Summary: A ring avulsion results from a longitudinal traction to a digit. We discuss practical microsurgical techniques essential in achieving good functional outcomes in these challenging cases, including aggressive debridement of the affected tissues and vessels, liberal use of vein grafts and arterialized venous flow through flaps when needed, and a meticulous microsurgical technique. We have found that patient selection is key in digit salvage and a good outcome is often achieved with the winning triad of optimal patient factors, surgical factors, and intensive hand therapy. We also include a case performed by our senior author to illustrate what can be achieved. (*Plast Reconstr Surg Glob Open* 2021;9:e3771; doi: [10.1097/GOX.0000000000003771](https://doi.org/10.1097/GOX.0000000000003771); Published online 19 August 2021.)

INTRODUCTION

A ring avulsion can be caused by forceful removal of a ring. This causes varying degrees of injury. At worst, complete avulsion of soft tissues, neurovascular bundles, tendons and bony skeleton occurs.¹ In 1981, Urbaniak et al² introduced a classification system based on the circulatory status of the presenting digit. In 1989, Kay et al³ published another focusing on vascularity and degree of skeletal injury. These classifications were developed to assist decision-making regarding salvage or amputation.

Previous reports^{4,5} have recommended amputation for more severe avulsion injuries but we find that good functional outcomes can be achieved for more severe types with a reparative approach.⁶ In the following article, we share techniques critical to achieving good results when salvaging these digits, illustrated by a case performed by the senior author (Fig. 1).

THE WINNING TRIAD

We believe for a good outcome the winning triad of optimal patient factors, surgical factors, and hand therapy is needed. Patient selection is paramount before embarking on digit salvage. Information required includes timing and mechanism of injury, the patient's age, occupation, hand dominance and comorbidities (ie, those affecting wound healing and vascularity). Perhaps, most

importantly, a prediction must be made regarding the patient's likely compliance with hand therapy postoperatively, without which no good outcome can be achieved. Amputation may be the most appropriate intervention in cases where patients are unlikely to engage with rehabilitation and have significant comorbidities.

The type of anesthesia should be chosen according to patient suitability and surgeons' preference. We prefer regional anesthesia, particularly for single-digit amputations which can be completed in 2–3 hours. Regional anesthesia also improves circulation by providing a sympathectomy resulting in vasodilatation.

DEBRIDEMENT AND OSTEOSYNTHESIS

Aggressive tissue debridement is critical so that the soft-tissue and bony injuries heal without infection. Liberal exposure of the proximal part is required, and we adopt a mid-lateral or Bruner extension to achieve this. When replantation or revascularisation is performed, extensive debridement of the damaged artery and vein is critical and must be done to a level outside the zone of trauma. This can be challenging as the zone of traction injury to the neurovascular structures usually extends beyond what is visible even with the microscope. Under high magnification, we are better able to assess for intimal damage and resect back until healthy vessel is identified. Performing the spurt test also helps to evaluate the arterial vessel quality.⁷

Radiographs are important to assess the degree of skeletal injury and plan fixation. For example, even a small displaced tuft fracture (Fig. 2) can warrant K wire fixation to reattach the soft-tissue envelope back to its anatomical position and achieve stability.

Disclosure: The authors have no financial interest to declare in relation to the content of this article.

Related Digital Media are available in the full-text version of the article on www.PRSGlobalOpen.com.

From the *Department of Plastic and Reconstructive Surgery, Royal Free Hospital, London, United Kingdom; and †Hand Therapy Unit, Royal Free Hospital, London, United Kingdom

Received for publication April 8, 2021; accepted June 29, 2021.

Copyright © 2021 The Authors. Published by Wolters Kluwer Health, Inc. on behalf of The American Society of Plastic Surgeons. This is an open-access article distributed under the terms of the [Creative Commons Attribution-Non Commercial-No Derivatives License 4.0 \(CCBY-NC-ND\)](https://creativecommons.org/licenses/by-nc-nd/4.0/), where it is permissible to download and share the work provided it is properly cited. The work cannot be changed in any way or used commercially without permission from the journal.

DOI: [10.1097/GOX.0000000000003771](https://doi.org/10.1097/GOX.0000000000003771)

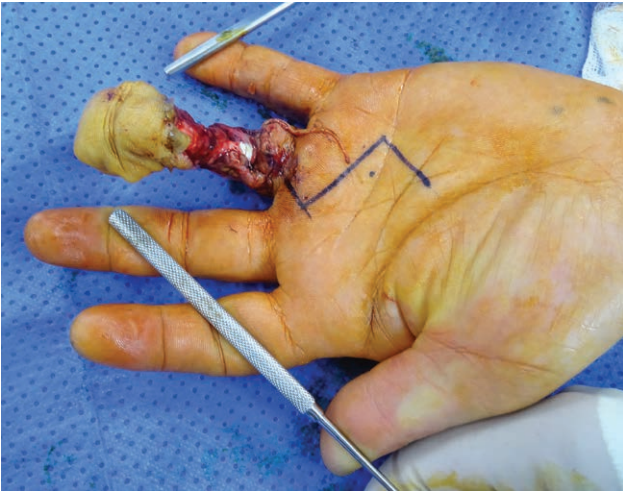


Fig. 1. A 33-year-old right-hand-dominant builder sustained a ring avulsion injury of his left ring finger (Urbaniak class-III) after catching his ring in a machine at work. Examination revealed a devascularized and insensate digit with a circumferential wound at the base of the digit and avulsed neurovascular bundles.

MICROSURGICAL TECHNIQUES

As primary arterial repair is not always possible post-debridement (despite maximal proximal artery mobilization), reversed vein grafts or adjacent finger vessel transfers can be used to bridge gaps. Our preferred

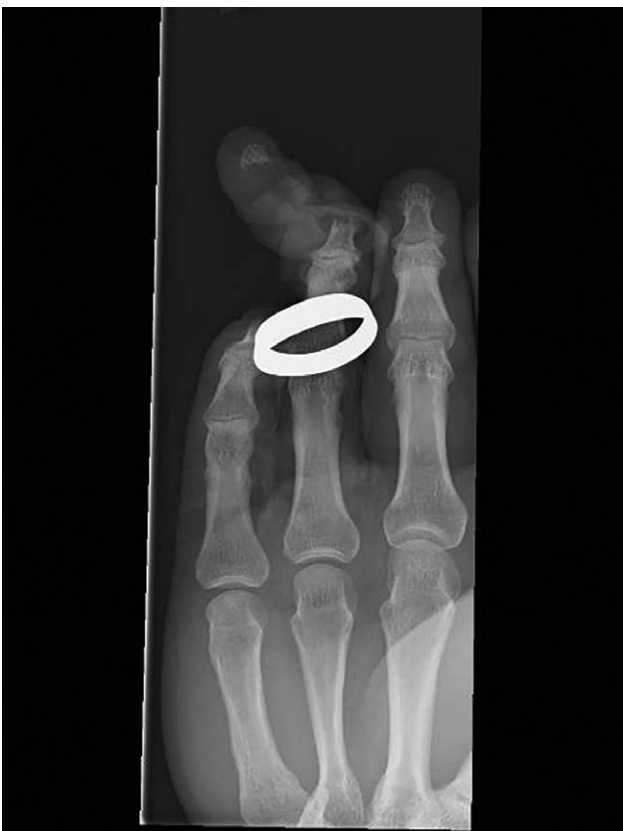

Fig. 2. Anterior posterior radiograph of ring avulsion revealing a distal tuft fracture.

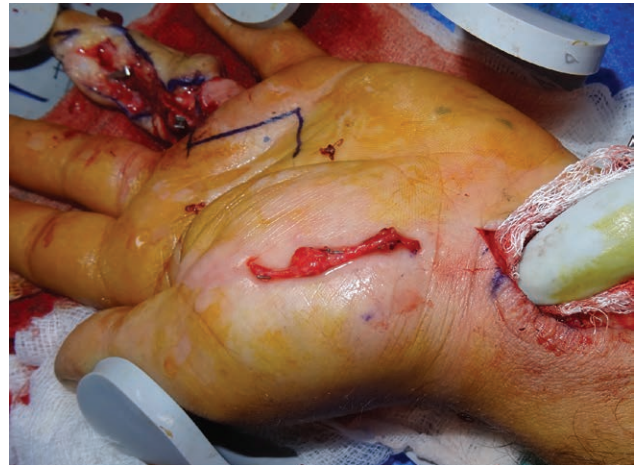


Fig. 3. Intraoperative photograph of reversed vein graft harvested from the distal forearm.

approach is to use reversed vein grafts from the distal forearm (Fig. 3). Thermal injury to the vein grafts is prevented by using microligaclips for side branches. We also consider use of crossed arterial anastomoses in cases where there may be discordance between the ulnar and radial digital vessel quality of the proximal and distal parts.⁶⁻⁹ Generally, it is better to choose vessel quality over size. If there is no difference in quality, pick the larger dominant digital vessel to repair.

If there is a large soft-tissue defect with segmental arterial loss, we use an arterialized venous flow through flap. This technique addresses both vascularity and soft-tissue coverage. Other options such as the second toe medial flap can be considered but we prefer a venous flow through flap due to its lower donor site morbidity and advantage of operating in a single anatomical field. There can, however, be a higher incidence of venous congestion in the transferred flap so one must be vigilant.

A high-quality operating microscope and supermicrosurgical instruments are required as distal vessels can be less than 1 mm diameter. The microsurgical clamps must be removed before repair to ensure adequate proximal flow.

Our preference is to use a posterior wall first approach during arterial anastomosis.¹⁰ Once completed, the hand is turned to perform venous repairs; dorsal veins are larger and easier to anastomose than volar veins. Dissection to identify veins is best performed under the microscope. Finally, tension free digital nerve repairs are performed. If there is a segmental injury to the nerve, consider nerve grafting or an end to side neurorrhaphy.

Coverage of anastomotic repairs is important and if loose skin closure is not possible we use split thickness skin grafts liberally.

INTENSIVE HAND THERAPY

Postoperative hand therapy for this group is essential and should begin preoperatively with patient education to improve engagement and compliance. Rehabilitation principles include (1) edema control; (2) scar management; (3)

Table 1. Case—Functional Outcomes Following Intensive Hand Therapy at 3 and 7 Months Postoperative

	3 Months Postoperative	7 Months Postoperative
Active ROM (extension/flexion)	MCPJ: 0/90 PIPJ: 5/90 DIPJ: 7/45	MCPJ: 0/90 PIPJ: -5/98 DIPJ: 2/60
TAM score	213	251
Sensation	Dorsally proximal to PIPJ diminished light touch. Volar deep pressure nerve recovery to the fingertip	Diminished light touch and protective sensation

DIP, distal interphalangeal joint; MCPJ, metacarpophalangeal joint; PIPJ, proximal interphalangeal joint; ROM, range of motion; TAM, total active motion.

nerve rehabilitation; (4) restoration range of movement alongside hand strength; and (5) return to functional use.

Postoperative splinting for positioning and digit protection can prevent contractures. Hand movements (active, passive, isolated, and composite) are commenced early, and timing varies depending on the structures repaired. There is a balance between immobilization to encourage bony union and early movement to reduce tendon tethering and joint contractures.

In the first postoperative week, the emphasis is on maintaining range of movement of unaffected fingers, edema/pain control, and wound care. Massage should commence after wounds have healed to prevent adhesions, aid sensation, and improve edema and cosmesis. Sensory re-education starts early, even with dressings in situ, with touch, texture handling, and temperature differentiation.

Active movement and the start of functional activities of the repaired digit usually commence at week 4 (after K wire removal). Strengthening exercises can start at week 8. **Table 1** and **Video 1** show functional outcomes of the presented case. (**See Video 1 [online]**, which displays a 33-year-old right-hand-dominant builder with a ring avulsion injury of his left ring finger (Urbaniak class-III). As he was highly motivated, a successful salvage was performed

using the techniques described in this article. This video demonstrates the active range of motion following 3.5 months of intense postoperative hand therapy.)

CONCLUSION

With the triad of strict patient selection, surgical factors such as aggressive debridement and vein grafts, and intensive postoperative hand therapy, we have been able to achieve good functional outcomes in severe ring avulsion cases.

Thessa Rebecca Friebe, MD, MD(Res)

Department of Plastic and Reconstructive Surgery
Royal Free Hospital
London WC1E 6BT
United Kingdom
E-mail: t.friebe@nhs.net

REFERENCES

1. Jones M, Gujral S. Ring avulsion injuries. *Eplasty*. 2016;16:ic5.
2. Urbaniak JR, Evans JP, Bright DS. Microvascular management of ring avulsion injuries. *J Hand Surg Am*. 1981;6:25–30.
3. Kay S, Werntz J, Wolff TW. Ring avulsion injuries: classification and prognosis. *J Hand Surg Am*. 1989;14(2 Pt 1):204–213.
4. Bosman WM, Prakken FJ, Ritchie ED. Total deglovement of the fourth digit due to ring avulsion injury. *BMJ Case Rep*. 2013;2013:bcr2013200866.
5. Struckmann VF, Gaus S, Schilling T, et al. Digital avulsion injuries: epidemiology and factors influencing finger preservation. *Arch Orthop Trauma Surg*. 2020;140:1575–1583.
6. Chiu DTW, Matthew MK, Patel A. The impact of microsurgery on the treatment of ring avulsion injuries. *Plast Reconstr Surg*. 2019;144:1351–1357.
7. Safa B, Greyson MA, Eberlin KR. Efficiency in replantation/revascularization surgery. *Hand Clin*. 2019;35:131–141.
8. Redgrave N, Anadkat M, Nikkiah D. Cross-arterial repair in digital revascularization. *Plast Reconstr Surg Glob Open*. 2021;9:e3365.
9. Adani R, Pataia E, Tarallo L, et al. Results of replantation of 33 ring avulsion amputations. *J Hand Surg Am*. 2013;38:947–956.
10. Nikkiah D, Pafitanis G. Posterior wall first anastomosis for replantation. *Plast Reconstr Surg*. 2020;146:827e–828e.