

Early diagnosis and precision treatment of right ovarian vein and inferior vena cava thrombosis following caesarean section: A case report

WEIPING CAO¹, XIA NI¹, QIN WANG¹, JIE LI², YAN LI³, TINGMEI CHEN¹ and XINZHI WANG⁴

Departments of ¹Obstetrics and ²Imaging, Maternity and Child Health Hospital of Zhenjiang, Zhenjiang, Jiangsu 212001;

³Department of Nursing, School of Medicine, Jiangsu University, Zhenjiang, Jiangsu 212013;

⁴Jiangsu Key Laboratory of Drug Screening, China Pharmaceutical University, Nanjing, Jiangsu 210009, P.R. China

Received February 12, 2019; Accepted January 3, 2020

DOI: 10.3892/etm.2020.8548

Abstract. Ovarian vein thrombosis (OVT) is a rare medical complication that is most often diagnosed in the post-partum period. OVT can lead to conditions, including sepsis, inferior vena cava (IVC), pulmonary emboli and mortality. The current study outlines a case of a patient who experienced pain in the lower abdomen and waist without fever postpartum following caesarean section (CS). Plasma FDP, D-Dimer and fibrinogen levels were markedly increased following CS and this was an indicator of the rapid progression of blood coagulation and fibrinolysis. Increased maternal lipid may be one of the risk factors for thrombosis. Based on the clinical presentation, a CT scan demonstrated thrombosis of the right ovarian vein and inferior vena cava, and a diagnosis of OVT and IVC thrombosis was subsequently made. In the current case, an anticoagulant therapy was started with a subcutaneous injection low molecular weight heparin calcium, an intravenous urokinase drip as a thrombolytic agent and implantation of inferior vena cava filters as a novel method of treatment for thrombosis. The patient was discharged from hospital 20 days following treatment in a good condition. The current study

reports a case of OVT associated with IVC that was successfully managed without complication.

Introduction

The ovaries are a pair of structures that are ~15 g and are attached by ligaments to the lateral pelvic wall and the uterus. Ovarian vein thrombosis (OVT), which is a rare puerperal complication, is a type of deep vein thrombosis that can be life threatening. The right ovarian vein is associated with the site of thrombosis due to the right ovarian veins being larger than the left, and due to retrograde flow in the left ovarian veins. The right ovarian vein joins the inferior vena cava (IVC) below the right renal vein, and the left ovarian vein drains into the left renal vein. The right ovarian vein enters the IVC at an acute angle, which makes it more susceptible to compression. Pregnancy is a risk factor for OVT with the sudden stagnation of blood within the dilated ovarian vein combined with contractions during natural delivery or cesarean sections (CS) (1). CS is a risk factor of OVT (2). OVT occurs in 0.05-0.18% of pregnancies worldwide, with the incidence rising to 1-2% following caesarean section (3). In a prospective study, the incidence of ovarian venous thrombosis was demonstrated to be 0.1% for CS (4).

OVT may result in propagation of the thrombosis into the IVC. IVC is a central manifestation of deep venous thrombosis and a major cause of fatal pulmonary embolism (PE) (5). Therefore, ovarian vein and inferior vena cava thrombosis is the leading cause of maternal mortality worldwide (6). The diagnosis of ovarian vein and inferior vena cava thrombosis can be performed using CT. Blood FDP and D-Dimer and fibrinogen levels can be used as an indicator of the rapid progression of blood coagulation and fibrinolysis (7). It has recently been indicated that early diagnosis and appropriate treatment can aid in the prevention of these potentially life threatening complications (8). The current study reports a case of ovarian vein and inferior vena cava thrombosis that was effectively treated with no further requirement for interventional procedures.

Case presentation. A 30-year old pregnant woman presented at the Maternity and Child Health Hospital of Zhenjiang (Jiangsu, China), and without complication, gave birth to a

Correspondence to: Dr Tingmei Chen, Department of Obstetrics, Maternity and Child Health Hospital of Zhenjiang, 20 Zhengdong Road, Zhenjiang, Jiangsu 212001, P.R. China
E-mail: 13815173932@163.com

Dr Xinzhi Wang, Jiangsu Key Laboratory of Drug Screening, China Pharmaceutical University, 24 Tongjia Road, Nanjing, Jiangsu 210009, P.R. China
E-mail: wangxzcpcu@163.com

Abbreviations: OVT, Ovarian vein thrombosis; IVC, Inferior vena cava thrombosis; CS, Caesarean section; CT, Computerized tomography; FDP, Fibrinogen degradation product; FP, Filter placement; TC, Total cholesterol; TG, Triglyceride; LDL, Low density lipoprotein

Key words: right ovarian vein, inferior vena cava, deep venous thrombosis, filter placement, caesarean section, postpartum

Table I. Laboratory tests for coagulation parameters.

Main parameters	Admission	3 days pre-op	CS	OVT at diagnosis	day of filter op	1 day filter post-op	2 day filter post op	Follow-up (1 month)	Normal range
Thrombin time (sec)	10.40	10.80	10.80	11.00	11.80	11.80	11.60	11.10	15.8-24.9
Fibrinogen (g.l ⁻¹)	6.04	6.95	6.92	7.21	7.96	4.59	2.80	2.89	2.38-4.98
FDP (μ g/ml)	3.80	11.60	9.70	13.60	15.40	9.70	3.50	2.50	0.0-5.0
PTR ratio	0.91	0.95	0.95	0.96	1.02	1.03	1.14	1.15	0.82-2.00
PT-INR	0.91	0.95	0.95	0.97	1.02	1.03	1.14	1.02	0.82-2.00
PT percent activity	107	100	89	97	96	120	100	73	80-120
D-dimer	632	1,047	1,193	1,191	1,164	998	432	207	0-255

The normal ranges of the variables are based on the Chinese population. cs, caesarean section; op, operation; OVT, ovarian vein thrombosis; FDP, fibrinogen degradation product; PTR ratio, prothrombin time ratio; PT-INR, prothrombin time-international normalized ratio.

Table II. Laboratory parameters for maternal lipids.

Main parameters (mmol/l)	Admission	3 days pre-op	CS	OVT at diagnosis	day-filter-op	1 day filter post-op	Follow-up (1 month)	Normal range
Cholesterol total	10.88	8.01	8.98	6.26	5.89	5.39	5.26	3.10-5.20
Triglyceride	4.82	4.88	5.08	5.11	5.17	5.10	3.28	0.40-1.70
Low density lipoprotein	6.52	5.22	5.29	4.88	5.39	5.11	4.22	0.00-3.37
High density lipoprotein	2.73	1.91	1.78	1.71	1.78	1.58	1.58	1.15-2.00

The normal ranges of the variables are based on the Chinese population. cs, caesarean section; op, operation; OVT, ovarian vein thrombosis.

second child, a female weighing 3,200 g, with an Apgar score of 9/10 (9). On the second day following a cesarean section, the patient complained of abdominal soreness in the right lower abdominal and waist. Physical examination revealed soreness in the right lower quadrant region. The patients temperature was 36°C, blood pressure was 112/78 mmHg, respiratory rate was 18 breaths/min and pulse was 82 beats/min. A pelvic examination failed to identify any abnormalities. The patient's medical and family history revealed no previous history of any thrombotic events. The estimated blood loss during the cesarean section was 200 ml. Laboratory tests performed were as follows: Leukocyte count, $8.3 \times 10^9/l$ (reference-range, $4.00-10.00 \times 10^9/l$); hemoglobin, 118 g/l (reference range, 115-175 g/l); platelets $226 \times 10^9/l$ (reference range, $100-350 \times 10^9/l$); increased plasma FDP, 11.60-15.40 μ g/ml (reference range, 0.0-5.0 μ g/ml); D-Dimer 632-1164 ng/ml (reference range, 0-255 ng/ml) and fibrinogen, 6.04-7.96 g.l⁻¹ (reference range, 2.38-4.98 g.l⁻¹). Full laboratory test results are presented in Table I. Other coagulation parameters such as thrombin time (s) (reference range, 15.8-24.9), prothrombin time percent activity (reference range, 80-120), prothrombin time ratio and prothrombin time international normalized ratio (reference range, 0.82-2.00) were within normal ranges. Biochemical results for lipid of cholesterol total and triglyceride and low density lipoprotein were also remarkably increased (Table II).

Ultrasonographic examination revealed 5.2x6.5x5.1 cm hypoechoic areas that were causing filling defects within the

right ovarian vein. CT with contrast enhancement demonstrated a thrombus in the right ovarian vein and inferior vena cava (Fig. 1), and a diagnosis of OVT and IVC thrombosis was made.

The treatment of ovarian and inferior vena cava thrombosis is determined using the clinical scenario and patient symptoms (10). An anticoagulant therapy was started with a subcutaneous injection of low molecular weight heparin calcium (0.4 ml, every 12 h for 7 days), urokinase as a thrombolytic agent intravenous drip (25 UI/ day for 3 days). Inferior vena cava filters can be implanted for postpartum OVT to prevent PE. A vena cava filter (Cordis) was implanted via the right internal jugular, which was followed by recanalization of the occluded IVC with the help of a guide wire and catheter (Fig. 2A). A trans-catheter intravenous thrombolysis was subsequently conducted. On day 10 following inferior vena cava filter implantation, the filter was retrieved through the right internal jugular after thrombus was sufficiently dissolved. This was confirmed via angiography, where the thrombus in the inferior vena cava disappeared and recanalization of blood flow occurred (Fig. 2B). The patient was discharged 20 days after the completion of the procedure with no complications.

Discussion

OVT is characterized by the formation of blood clots (thrombosis) in the ovarian veins. The pathogenesis of OVT is a

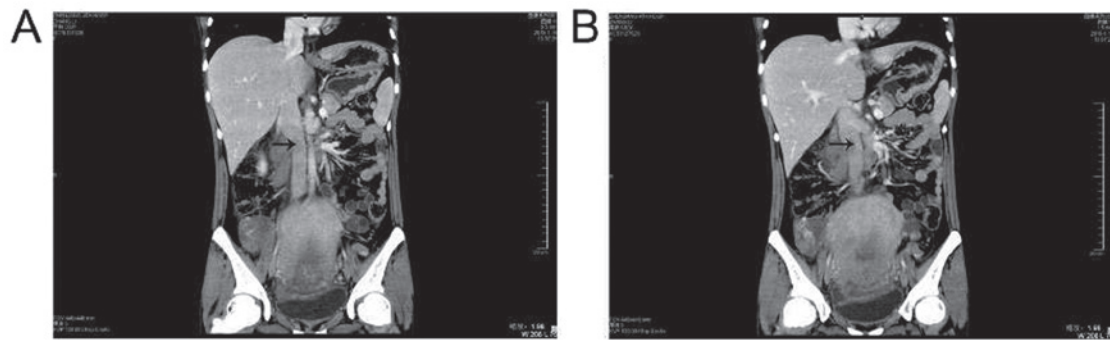


Figure 1. In coronal enhanced CT images. (A) Thrombosis of right ovarian vein was indicated (arrow) (B) up to the inferior vena cava (arrow).

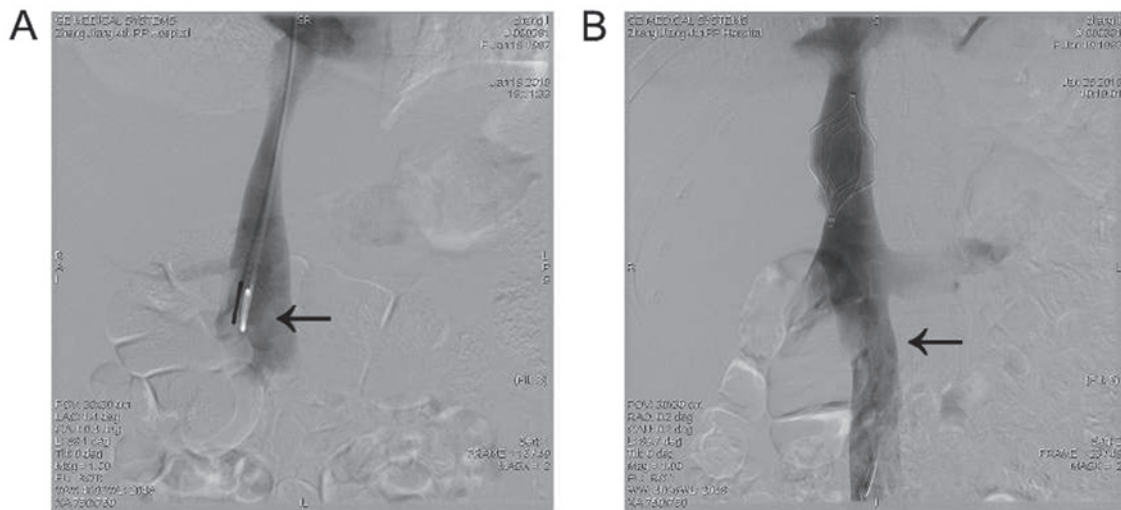


Figure 2. Inferior vena cava filters. (A) A blood clot was identified in the filter (arrow). (B) Angiography confirmed that the thrombus in the inferior vena cava disappeared, and identified the recanalization of the blood flow (arrow).

Virchow triad: Venous stasis, endothelial damage and hypercoagulability (11). In the current case, the increased total cholesterol and triglyceride and low density lipoprotein in pregnancy may cause damage to the endothelial function or increase blood viscosity, which is beneficial for the formation of atherosclerotic plaque and the occurrence of thrombosis (12). Lipids constitute a large part of the arterial wall, as do plasma and intracellular membranes. Therefore, lipid abnormalities may lead to endothelial damage and vascular injury (13). Cesarean section raises the risk of OVT compared with vaginal delivery as when veins are dilated and blood flow velocity decreases under anesthesia, tissue trauma is increased, bed rest is prolonged and the incidence of puerperal infection is higher due to surgery (14).

The early identification of symptomatic OVT and the precise treatment of OVT is important to prevent life-threatening complications. CT scan is primarily used to diagnose OVT as it can assess the extent of thrombosis within the IVC (15). In the current case, dilated right ovarian vein with thrombi, extending up to the inferior vena cava, was identified. A diagnosis of OVT and IVC thrombosis was subsequently made. Pregnant women are at an increased risk of deep vein thrombosis (16). The patient in the present study exhibited increased blood FDP and D-Dimer and fibrinogen levels after CS, further indicating the rapid progression of

blood coagulation and fibrinolysis. OVT is most commonly treated using anticoagulation therapy (17). There are no standard guidelines for the dose, duration or drug of choice for anticoagulation treatment. An anticoagulant therapy was started in the current patient with a subcutaneous injection of low molecular weight heparin calcium (0.4 ml, every 12 h for 7 days), urokinase as a thrombolytic agent intravenous drip (25 UI/day for 3 days) and implantation of inferior vena cava filters. This is the current recommend anticoagulant therapy for ovarian vein and inferior vena cava thrombosis due to the lack of high quality evidence for other treatments. Previous studies have demonstrated that the use of thrombolysis for OVT can break down blood clots and exhibits some advantages, including earlier thrombus removal compared with the use of anticoagulants alone (18-21). At present, urokinase is one of the common thrombolytic agents (22). Studies have reported that urokinase agent combined with implantation of inferior vena cava filters can aid in dissolving thrombi (23). Inferior vena cava filter has been widely used in patients with venous thrombosis and no-pregnancy, effectively preventing PE (24). During pregnancy, there have been some reports of inferior vena cava filter, however, these are controversial (25). In the current case, the treatment received was effective. The patient was treated successively and was discharged from the hospital after 20 days.

Ovarian vein thrombosis with inferior vena cava is a very rare condition postpartum condition. Like any other venous thromboembolic disease, OVT can be fatal and lead to serious complications, including the extension of the thrombus into the IVC. These complications can be managed using anticoagulation and thrombolytic therapy combined with an IVC filter. In the present case, the timely diagnosis and management of OVT successfully prevented these potentially life-threatening complications.

Acknowledgements

Not applicable.

Funding

This study was supported by the preventive medicine program of Jiangsu Provincial Health and Health Committee (grant no. Y2018062) and the Project of Science and Technology Development Research Center of National Health and Family Planning Commission (grant no. W2016CWJS03).

Availability of data and materials

All data generated or analyzed during this study are included in this published article.

Authors' contributions

QW and YL acquired the clinical data. XN performed the investigation. JL conceived of the methodology. WC, TC and XW made substantial contributions to conception, and analysis and interpretation of data. WC was involved in drafting the manuscript and XW revised it critically for important intellectual content. All authors produced and approved the final manuscript.

Ethics approval and consent to participate

The present study was approved by the ethics committee of the Maternity and Child Health Hospital of Zhenjiang. Written informed consent was obtained from the patient.

Patient consent for publication

The patient who participated in the study provided written informed consent for the publication of any associated data.

Competing interests

The authors declare that they have no competing interests.

References

- Jenayah AA, Saoudi S, Boudaya F, Bouriel I, Sfar E and Chelli D: Ovarian vein thrombosis. *Pan Afr Med J* 21: 251, 2015.
- Plastini T, Henry D and Dunleavy K: Ovarian vein thrombus: To treat or not to treat? *Blood Advance* 1: 1120-1123, 2017.
- Rottenstreich A, Da'as N, Kleinstern G, Spectre G, Amsalem H and Kalish Y: Pregnancy and non-pregnancy related ovarian vein thrombosis: Clinical course and outcome. *Thromb Res* 146: 84-88, 2016.
- See A and Chern B: Contained intra-abdominal morcellation: Is it the way forward? *Gynecol Minim Invasive Ther* 5: 99-101, 2016.
- Bates SM, Middeldorp S, Rodger M, James AH and Greer I: Guidance for the treatment and prevention of obstetric-associated venous thromboembolism. *J Thromb Thrombolysis* 41: 92-128, 2016.
- Assal A, Kaner JD, Danda N, Cohen HW and Billett HH: Risk factors and prognosis of ovarian vein thrombosis. *Blood Coagul Fibrinolysis* 28: 468-474, 2017.
- Cassinelli G and Naggi A: Old and new applications of non-anti-coagulant heparin. *Int J Cardiol* 212 (Suppl): S14-S21, 2016.
- Bos AS, Tullius T, Patel M, Leef JA, Navuluri R, Lorenz JM and Van Ha TG: Indwelling and retrieval complications of Denali and celect infrarenal vena cava filters. *J Vasc Interv Radiol* 27: 1021-1026, 2016.
- Iliodromiti S, Mackay DF, Smith GC, Pell JP and Nelson SM: Apgar score and the risk of cause-specific infant mortality: A population-based cohort study. *Lancet* 384: 1749-1755, 2014.
- Murphy EH, Johns B, Varney E and Raju S: Endovascular management of chronic total occlusions of the inferior vena cava and iliac veins. *J Vasc Surg Venous Lymphat Disord* 5: 47-59, 2017.
- Dargaud Y, Rugeri L, Fleury C, Battie C, Gaucherand P, Huissoud C, Rudigoz RC, Desmurs-Clavel H, Ninet J and Trzeciak MC: Personalized thromboprophylaxis using a risk score for the management of pregnancies with high risk of thrombosis: A prospective clinical study. *J Thromb Haemost* 15: 897-906, 2017.
- Streiff MB, Agnelli G, Connors JM, Crowther M, Eichinger S, Lopes R, McBane RD, Moll S and Ansell J: Guidance for the treatment of deep vein thrombosis and pulmonary embolism. *J Thromb Thrombolysis* 41: 32-67, 2016.
- Morelli VM, Lijfering WM, Bos MHA, Rosendaal FR and Cannegieter SC: Lipid levels and risk of venous thrombosis: Results from the MEGA-study. *Eur J Epidemiol* 32: 669-681, 2017.
- Wendelboe AM and Raskob GE: Global burden of thrombosis: Epidemiologic aspects. *Circ Res* 118: 1340-1347, 2016.
- Kearon C, Akl EA, Ornelas J, Blaivas A, Jimenez D, Bounameaux H, Huisman M, King CS, Morris TA, Sood N, *et al*: Antithrombotic therapy for VTE disease: CHEST guideline and expert panel report. *Chest* 149: 315-352, 2016.
- Farge D and Frere C: Clinical practice guidelines for prophylaxis of venous thromboembolism in cancer patients. *Thromb Haemost* 116: 618-625, 2016.
- Djakovic I, Mustapic M, Marleku F, Grgic O, Djakovic Z and Kosec V: Ovarian vein thrombosis-a case report. *Acta Clinica Belg* 70: 445-446, 2015.
- Hong-Kee N, Mei-Fong C, Azhany Y and Zunaina E: Antiphospholipid syndrome in lupus retinopathy. *Clin Ophthalmol* 8: 2359-2363, 2014.
- Giolami A, Treleani M, Bonamigo E, Tasinato V and Giolami B: Venous thrombosis in rare or unusual sites: A diagnostic challenge. *Semin Thromb Haemost* 40: 81-87, 2014.
- Liu M and Zhang F: Administration routes affect thrombolytic effect of catheter-directed thrombolysis with pro-urokinase in treating deep vein thrombosis. *Ann Transl Med* 6: 322, 2018.
- Harris SA, Velineni R and Davies AH: Inferior vena cava filters in pregnancy: A systematic review. *J Vasc Interv Radiol* 27: 354-360.e8, 2016.
- Angelini M, Barillari G, Londero AP, Bertozzi S, Bernardi S, Petri R, Driul L and Marchesoni D: Puerperal ovarian vein thrombosis: Two case reports. *J Thromb Thrombolysis* 35: 286-289, 2013.
- Wan Z, Xiang R, Wang H, Zhong Q and Tu B: Comparative efficacy and safety of local and peripheral venous thrombolytic therapy with urokinase for thrombosed hemodialysis arteriovenous fistulas. *Exp Ther Med* 17: 4279-4284, 2019.
- Bikdeli B, Chatterjee S, Desai NR, Kirtane AJ, Desai MM, Bracken MB, Spencer FA, Monreal M, Goldhaber SZ and Krumholz HM: Inferior vena cava filters to prevent pulmonary embolism: Systematic review and meta-analysis. *J Am Coll Cardiol* 70: 1587-1597, 2017.
- Watson L, Broderick C and Armon MP: Thrombolysis for acute deep vein thrombosis. *Cochrane Database Syst Rev* 11: CD002783, 2016.

