



Case report

Traumatic fracture of the polyethylene tibial post and cone in a posterior-stabilized total knee arthroplasty: A case report

Abdulaziz Alkheraiji^a, Sultana Borai^{b,*}, Rheema Alfadhil^b, Fawzi AlJassir^c

^a Department of Orthopedic Surgery, College of Medicine, AlMajmaah University, Saudi Arabia

^b Orthopedic Surgery Resident, King Saud University Medical City, Riyadh, Saudi Arabia

^c King Saud University Medical City, Riyadh, Saudi Arabia



ARTICLE INFO

Keywords:

Total knee arthroplasty
Revision total knee arthroplasty
Polyethylene fracture

ABSTRACT

Introduction and importance: Very few reports addressed polyethylene tibial post and cone fractures requiring revision surgery. Up to our knowledge, this particular pattern of wear, involving 2 fracture areas simultaneously, has not been previously described.

Case presentation: A 70 year-old female developed a fracture involving both the tibial insert post and cone after a minor trauma after undergoing posterior-stabilized total knee replacement 4 years prior.

Clinical discussion: This unique pattern of wear may occur even after minor trauma.

Conclusion: We recommend having a low threshold to investigate minor trauma in this patient population, even years after undergoing primary knee arthroplasty.

1. Introduction

Excellent long-term results have been shown using posterior-stabilized (PS) total knee arthroplasty (TKA) prosthesis [1]. The key feature of PS-TKA prostheses is the femoral cam and tibial post mechanism that limits posterior displacement and produces femoral rollback [2,3]. However, 6–12 % of primary TKAs fail within 10 years and require revision surgery [4]. Very few reports addressed polyethylene insert cone fractures requiring revision. Our current case highlights a rare complication of a tibial post and polyethylene cone fracture after a minor trauma several years after undergoing PS-TKA. It is unique in a way that the patient developed a fracture in the tibial post as well as the cone. Up to our knowledge, this particular pattern of wear, involving 2 fracture areas simultaneously, has not been previously described.

This case report is in line with the SCARE 2020 criteria [5].

2. Case report

An obese (BMI 32) 70 year-old female has been following in our orthopedic clinic in King Saud University Medical City since 2015 for left knee osteoarthritis (Image 1). A trial of conservative management failed therefore, she underwent TKA in February 2015 through a medial parapatellar approach and using the Persona PS-TKA system (Zimmer

biomet, USA). The sizes used were femur size 5, tibia size D, and the insert thickness was 12 mm which was sterilized using ethylene oxide (Image 2). Post-operatively, she was mobilizing and compliant with physical therapy.

In March 2021, she presented to the clinic complaining of left knee pain and inability to bear weight following a fall on a flexed knee. Her drug, family, and psychosocial history were unremarkable. Examination and imaging AP and lateral standing both knees X-rays were unremarkable, therefore, she was given analgesia and follow-up. She presented 3 months later complaining of pain and instability with weight bearing. Her examination showed varus laxity and recurvatum. Standing AP, lateral and full length lower limbs standing radiographs showed a varus deformity and no loosening (Image 3). She was placed in a knee brace and booked for revision TKA. The patient and relatives were in agreement with our treatment plan.

She underwent left revision TKA in July 2021, which was done by the senior author. Intraoperatively, she was found to have a broken polyethylene tibial post and cone (Image 4), as well as a stretched but intact lateral cruciate ligament. The polyethylene liner was initially exchanged, but since instability with varus laxity persisted on examination, both femur and tibia components were revised using the Persona revision system (Zimmer biomet, USA). The sizes used were tibia size D, 10 mm stem, 10 mm augment used both medial and lateral, femur size

* Corresponding author at: Orthopedic Department, King Saud University Medical City, Postal code 12372 Riyadh, Saudi Arabia.

E-mail addresses: a.alkheraiji@mu.edu.sa (A. Alkheraiji), sultana.borai@gmail.com (S. Borai), faljassir@ksu.edu.sa (F. AlJassir).

<https://doi.org/10.1016/j.ijscr.2022.107437>

Received 30 May 2022; Received in revised form 15 July 2022; Accepted 17 July 2022

Available online 23 July 2022

2210-2612/© 2022 The Authors. Published by Elsevier Ltd on behalf of IJS Publishing Group Ltd. This is an open access article under the CC BY-NC-ND license (<http://creativecommons.org/licenses/by-nc-nd/4.0/>).

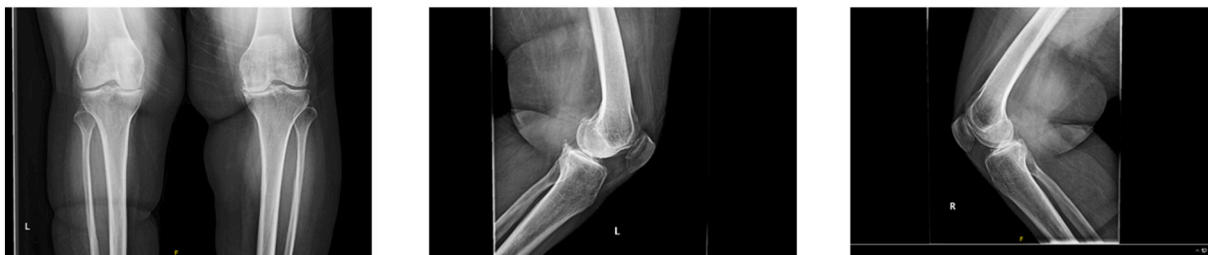

Image 1. Bilateral knees standing AP and lateral radiographs during first visit in clinic.




Image 2. AP and lateral radiographs post Left total knee arthroplasty.

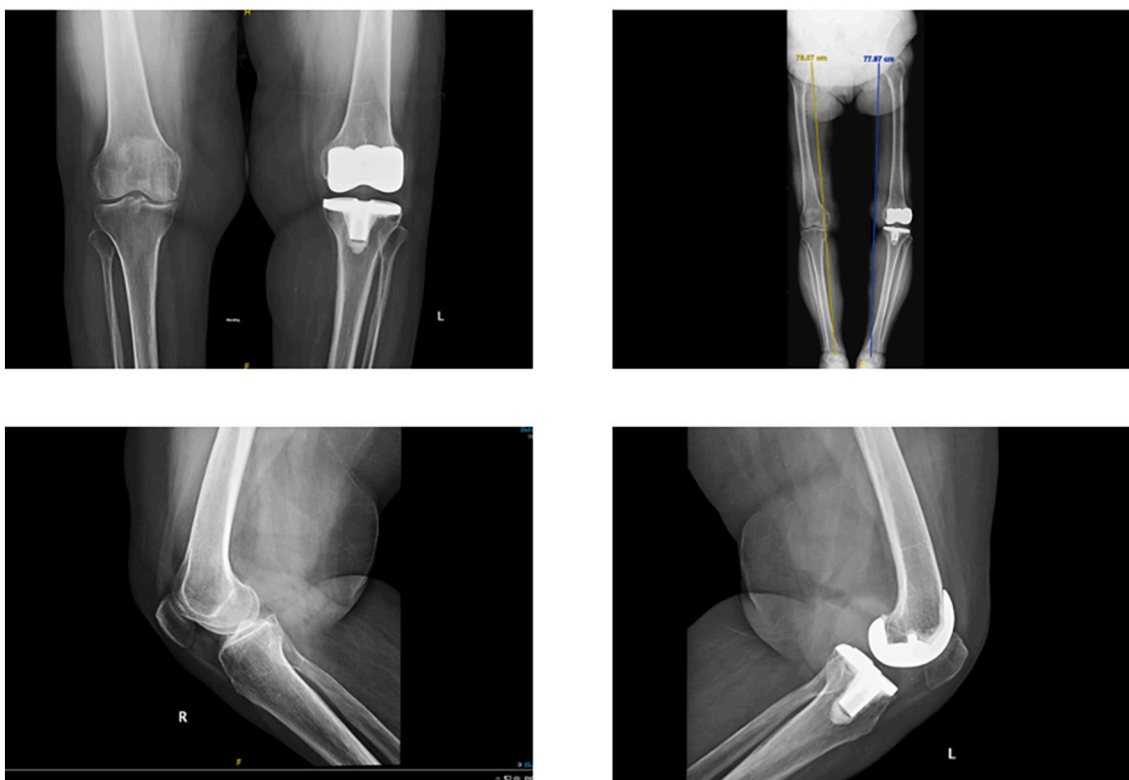

Image 3. Bilateral knees standing AP and lateral and full-length standing radiographs 16 months post left total knee arthroplasty.

5+, 13 mm stem with 9 offset, posterior augment medial condyle 5 mm, and a 14 mm Insert. Examination afterwards revealed a stable knee.

Postoperatively, she was placed in a hinged brace and physical therapy for mobilization weight bearing as tolerated with the brace and range of motion (ROM) was initiated. She was seen 2 weeks post-operatively for wound inspection and was kept on a hinged brace until

her next visit. During her latest follow up at 1 month post-operatively (August 2021), she was doing well and compliant with the physical therapy protocol. The hinged knee brace was removed and her examination showed a stable knee and ROM from 0 to 90 degrees. Her radiographs showed good alignment (Image 5). We initiated weight bearing as tolerated and ROM without the brace. She is still being seen in

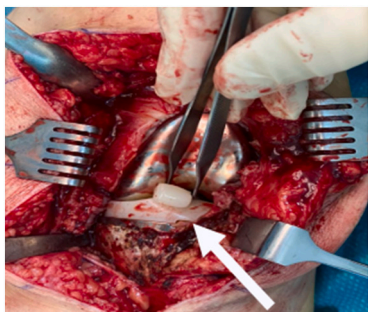


Image 4. Intraoperative photograph showing broken tibial post.

our clinic for ROM and stability assessment of her knee, and is pleased with the results of her treatment so far.

3. Discussion

TKA has provided excellent results in more than 92 to 97 % of patients, which has been reported at 10 to 15 years follow-up [6]. Between 6 and 12 % of primary TKAs fail within 10 years requiring revision surgery [4]. Instability is a common cause of revision TKA with symptomatic instability occurring in less than 1–2 % of patients after primary TKA [4]. Not only has instability been identified as a significant cause of revision TKA but also is a leading cause for early revision [7]. Potential causes of instability include trauma, ligamentous compromise, obesity, inadequate balance of flexion and extension spaces at the time of surgery, joint line malpositioning, connective tissue disorders, insufficient extensor mechanism, or significant hip, foot, or ankle deformities [4,7,8].

As a mechanical restraint against posterior tibial subluxation, the polyethylene tibial post is susceptible to damage related to

impingement, wear, and breakage [2,3].

Mihalko and associates described the mechanics of PS-TKA and the interaction between the components [9]. The cam and post geometry in the transverse plane changes how the femur and tibia interact. In a rectangular post cross-section, femoral rotation on the tibia will be constrained, causing edge loading of the post on the condylar edges of the femoral component. In contrast, in a rounded post, less condylar constraint occurs with rotation, leading to less burnishing and edge wear. The position of the post in the baseplate was also discussed. If the cam position was more anterior, the post would interact with the cam at an earlier point in the flexion arc; once engaged, the contact of the cam would be maintained in the midportion of the post. The opposite is true if the cam was moved more posteriorly or at the top of the femoral condyles [9].

Similar to our case, Kumar et al. reported a single case of PS-TKA failure after 10 years resulting from a minor trauma [3]. They concluded that the possible mechanism behind their patient's tibial post wear and base fracture was anterior impingement between the femoral cam and tibial post [3]. Mestha et al. reported a case of polyethylene tibial post fracture 3 years after primary TKA after trauma who presented with instability [10]. Rapuri et al. reported five cases of tibial polyethylene insert failure in constrained TKA [11]. It was found that breakage of the tibial post was a unique complication. In earlier designs, loosening of locking screws used to secure the stem extensions to the femoral component has been postulated to occur because of micromotion occurring between the 2 components [11]. Mauerhan reported 5 cases with polyethylene tibial post fractures in PS-TKA that mimicked patellar clunk syndrome [12], where they all showed wear on the polyethylene post alongside the fracture, which occurred just above the base, and all had history of high flexion activities (ie, kneeling or squatting) [12].

Mariconda and associates described the first case of fracture of the eminence of the tibial polyethylene insert in a posterior-stabilized

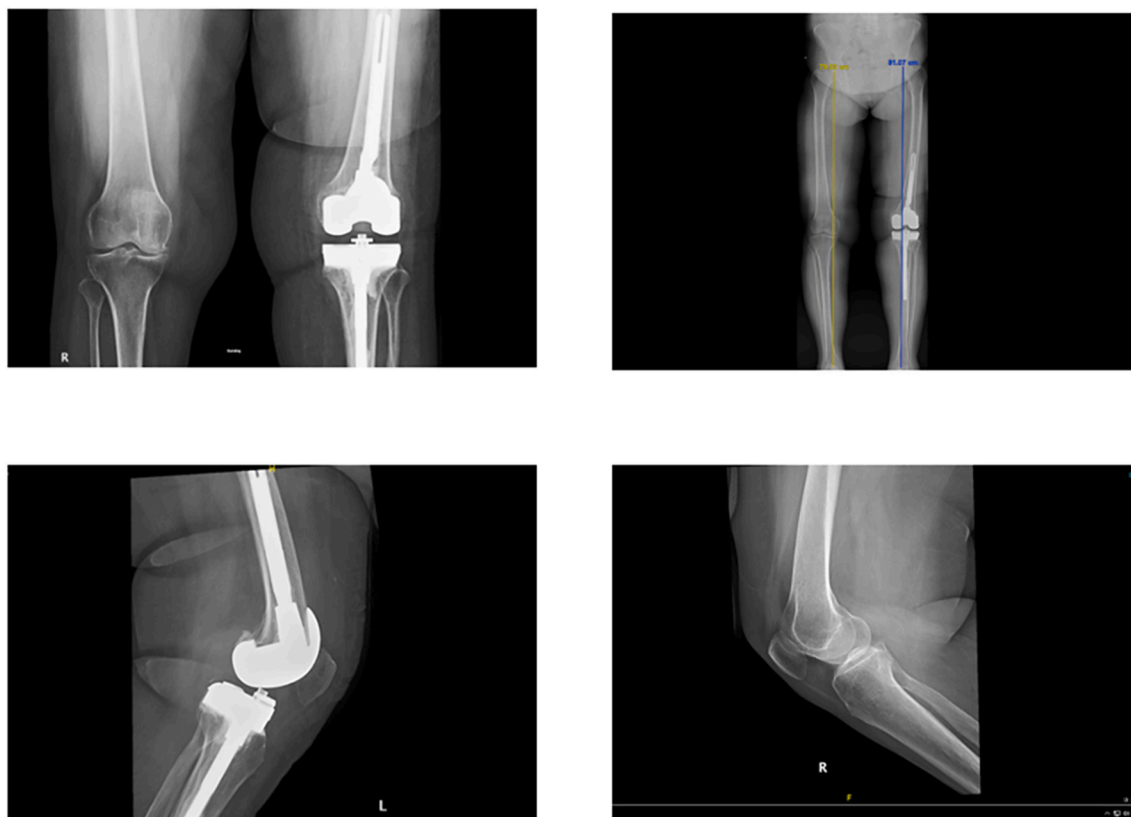


Image 5. Bilateral knees standing AP and lateral and full-length standing radiographs 1 month post left knee revision arthroplasty.

Genesis TKA (Smith & Nephew Orthopaedics, Memphis, TN). Their patient presented with pain, limping, and clicking of the left knee 3 years after her initial surgery. These symptoms arose acutely while the patient had her knees hyperflexed. She underwent revision of tibial and femoral components [13]. A similar case by Clarke and associates presented a case of tibial post PS prosthesis fracture after TKA, where their patient presented with pain and swelling. They recommended that revision of the polyethylene insert should be considered in those patients in whom the components are well fixed and in good sagittal and rotational alignment. If the components are loose or malpositioned, complete revision is preferred [14]. This was supported by Lim and associates, who mentioned that if the components were loose or malpositioned, complete revision is recommended. Moreover, other reports have cautioned that isolated exchange of the polyethylene insert is associated with a high probability of subsequent revision of all components of the total knee [15,16].

Our current study is consistent with Wilson and associates, where they found that the average age at revision TKA was mid-to-late sixties and that revision rates were higher in patients who were less than 70 years of age when the primary knee surgery was performed. However, our case contradicts Wilson et al. in regards to patient BMI. They reported that BMI was not a relevant patient characteristic with regards to revision [7].

Contrary to the available literature, our case describes a rare complication of a tibial post and polyethylene cone fracture after a minor trauma several years after undergoing PS-TKA. It shows an obese female with a history of minor trauma 3 years after her primary TKA. In our case, two implant fractures were encountered, which up to our knowledge, has yet to be reported in the literature. Furthermore, this is the first case that has been described with fractures occurring using the Zimmer Persona PS-TKA system. In addition, most of the published reports showed good outcomes by only changing the polyethylene insert. However, in our case, the initial hardware was well-positioned but our patient remained to have laxity when we changed the insert, which required an exchange of the entire hardware into a constrained implant (Zimmer Biomet, USA). We believe that this remaining laxity is due to the long duration of having the fractured implant in place (4 months), which may have led to stretching of the lateral collateral ligament.

Our current study has several limitations. First, it is a case report, which is not the strongest form of evidence. Second, this patient needs further follow-ups to follow her progress after her revision TKA to fully assess her outcome.

4. Conclusion

We conclude that this unique pattern of wear, involving the tibial post and cone after a minor trauma, may occur. We recommend continuous follow-ups for post-TKA patients. Clinicians should have a low threshold to investigate minor trauma in this patient population, even years after undergoing primary TKA.

Provenance and peer review

Not commissioned, externally peer-reviewed.

Sources of funding

This research did not receive any specific grant from funding agencies in the public, commercial, or not-for-profit sectors.

Ethical approval

This study is exempt from ethical approval.

Declaration of competing interest

The authors in this case study report no potential conflict of interest relevant to this article.

Acknowledgements

The authors sincerely thank King Saud University for their enthusiastic assistance.

Author contribution

Fawzi AlJassir: Revising the article critically for important intellectual content and final approval of the version to be submitted.

Abdulaziz Alkheraiji: Revising the article critically for important intellectual content and final approval of the version to be submitted.

Sultana Borai: The study concept, design, acquisition of data, interpretation of data, drafting the article and revising it critically for important intellectual content.

Rheema Alfadhil: The study concept, design, acquisition of data, interpretation of data, drafting the article and revising it critically for important intellectual content.

Research registration

Not required, as our article does not describe a new surgical technique or new equipment/technology.

Consent

Written informed consent was obtained from the patient's legal guardians (parents) for publication of this case report and accompanying images. A copy of the written consent is available for review by the Editor-in-Chief of this journal on request.

Guarantor

Fawzi AlJassir, Abdulaziz Alkheraiji, Sultana Borai, Rheema Alfadhil.

References

- [1] Y. Tanikake, et al., Nontraumatic tibial polyethylene insert cone fracture in mobile-bearing posterior-stabilized total knee arthroplasty, *Arthroplasty Today* (2016), <https://doi.org/10.1016/j.artd.2016.05.006>.
- [2] H.C. Lim, J.H. Bae, J.H. Hwang, S.J. Kim, J.Y. Yoon, Fracture of a polyethylene tibial post in a scorpion posterior-stabilized knee prosthesis, *Clin. Orthop. Surg.* 1 (2) (2009) 118, <https://doi.org/10.4055/cios.2009.1.2.118>.
- [3] N. Kumar, C. Yadav, R. Raj, S. Yadav, Fracture of the polyethylene tibial post in a posterior stabilized knee prosthesis: a case report and review of literature, *J. Orthop.* 12 (3) (2015) 160–163, <https://doi.org/10.1016/j.jor.2015.01.002>.
- [4] M. Siqueira, C. Higuera, W. Barsoum, A. Klika, Modes of failure of total knee arthroplasty: registries and realities, *J. Knee Surg.* 28 (02) (2014) 127–138, <https://doi.org/10.1055/s-0034-1396014>.
- [5] R.A. Agha, T. Franchi, C. Sohrabi, G. Mathew, for the SCARE Group, The SCARE 2020 guideline: updating consensus Surgical Case Report (SCARE) guidelines, *Int. J. Surg.* 84 (2020) 226–230.
- [6] D.C. McNabb, R.H. Kim, B.D. Springer, Instability after total knee arthroplasty, *J. Knee Surg.* 28 (2) (2015 Apr) 97–104, <https://doi.org/10.1055/s-0034-1396080>. Epub 2014 Dec 17 PMID: 25518877.
- [7] C.J. Wilson, et al., Knee instability as the primary cause of failure following Total Knee Arthroplasty (TKA): a systematic review on the patient, *surg, Knee* (2017), <https://doi.org/10.1016/j.knee.2017.08.060>.
- [8] J.S. Luttjeboer, M.R. Bénard, K.C. Defoort, G.G. van Hellemond, A.B. Wymenga, Revision total knee arthroplasty for instability—outcome for different types of instability and implants, *J. Arthroplast.* 31 (12) (2016) 2672–2676, <https://doi.org/10.1016/j.arth.2016.06.062>.
- [9] W.M. Mihalko, J. Lowell, G. Higgs, S. Kurtz, Total knee post-cam design variations and their effects on kinematics and wear patterns, *Orthopedics* 39 (3 Suppl) (2016 May), <https://doi.org/10.3928/01477447-20160509-14>. PMID: 27219727.
- [10] P. Mestha, Y. Shenava, J.C. D'Arcy, Fracture of the polyethylene tibial post in posterior stabilized (Insall burstein II) total knee arthroplasty, *J. Arthroplast.* 15 (6) (2000) 814–815, <https://doi.org/10.1054/arth.2000.6615>.

- [11] V.R. Rapuri, H.D. Clarke, M.J. Spangehl, C.P. Beauchamp, Five cases of failure of the tibial polyethylene insert locking mechanism in one design of constrained knee arthroplasty, *J. Arthroplast.* 26 (6) (2011), <https://doi.org/10.1016/j.arth.2010.07.013>, 976.e21-976.e24.
- [12] D.R. Mauerhan, Fracture of the polyethylene tibial post in a posterior cruciate-substituting total knee arthroplasty mimicking patellar clunk syndrome, *J. Arthroplast.* 18 (7) (2003) 942–945, [https://doi.org/10.1016/s0883-5403\(03\)00333-4](https://doi.org/10.1016/s0883-5403(03)00333-4).
- [13] M. Mariconda, G. Lotti, C. Milano, Fracture of posterior-stabilized tibial insert in a genesis knee prosthesis, *J. Arthroplast.* 15 (4) (2000) 529–530, <https://doi.org/10.1054/arth.2000.4810>.
- [14] H.D. Clarke, K.R. Math, G.R. Scuderi, Polyethylene post failure in posterior stabilized total knee arthroplasty, *J. Arthroplast.* 19 (5) (2004) 652–657, <https://doi.org/10.1016/j.arth.2004.02.026>.
- [15] G.C. Babis, R.T. Trousdale, B.F. Morrey, The effectiveness of isolated tibial insert exchange in revision total knee arthroplasty, *J. Bone Joint Surg. Am.* 84 (1) (2002 Jan) 64–68, <https://doi.org/10.2106/00004623-200201000-00010>. PMID: 11792781.
- [16] G.A. Engh, L.M. Koralewicz, T.R. Preeles, Clinical results of modular polyethylene insert exchange with retention of total knee arthroplasty components, *J. Bone Joint Surg. Am.* 82 (4) (2000 Apr) 516–523, <https://doi.org/10.2106/00004623-200004000-00007>. PMID: 10761942.