

## Comparative evaluation of two toric intraocular lenses for correcting astigmatism in patients undergoing phacoemulsification

Sheetal A Seth, Rakesh K Bansal, Parul Ichhpujani, Natasha G Seth<sup>1</sup>

**Purpose:** To compare the efficacy of AT-TORBI plate haptic toric intraocular lens (IOL) (Carl Zeiss Meditec AG, Jena, Germany) and AcrySof loop haptic toric IOL (Alcon Laboratories, Inc., Fort Worth, TX, USA) for correcting preexisting astigmatism of  $\geq 1$  diopters (D) in patients undergoing phacoemulsification and to compare the rotational stability of these two toric IOLs. **Methods:** In this prospective randomized controlled trial. Forty-two eyes of 42 cataract patients with preexisting astigmatism of 1 D or more were randomized to receive plate haptic toric (AT TORBI) or loop haptic toric (AcrySof) IOLs, with 21 in each group. Postoperative evaluation was done at day 1, 1 week, 1 month, and 3 months. Uncorrected distance visual acuity (UDVA), best corrected visual acuity (VA), and IOL position were noted in both the groups. **Results:** At 3 months postoperatively, the mean log MAR UDVA was  $0.23 \pm 0.20$  and  $0.20 \pm 0.13$  in Groups I and II, respectively ( $P = 0.7$ ), the mean residual cylindrical refractive error in plate haptic toric group was  $0.40 \pm 0.31$  D and in loop haptic group was  $0.45 \pm 0.33$  D ( $P = 0.64$ ). The mean IOL rotation at 3 months follow-up in plate haptic group was found to be  $3.52 \pm 3.84^\circ$  and in loop haptic group was  $2.05 \pm 2.56^\circ$  ( $P = 0.25$ ). **Conclusion:** Both types of toric IOLs were equally efficacious for attaining good uncorrected VA and correcting preexisting astigmatism between 1–5 D. Both of them were rotationally stable at 3 months follow-up.

**Key words:** Astigmatism, phacoemulsification, rotational stability, toric intraocular lenses

Naturally occurring astigmatism is a common entity and is found in about 95% of the eyes.<sup>[1]</sup> It has been further estimated that 63% of the patients undergoing cataract surgery have astigmatism of  $\leq 1$  diopter (D) and 37% of them have astigmatism of  $>1$  D.<sup>[1]</sup> Recent advances in cataract and intraocular lens (IOL) implant surgery have led to a new concept of “Refractive Cataract Surgery” aiming at a pseudophakic emmetropia to ensure best visual acuity (VA) without the need of spectacles postoperatively.

Various intraoperative techniques have been tried to correct the preexisting astigmatism, such as flattening the steep axis by placing clear corneal incisions or use of coupled opposite clear corneal incision, but they can correct astigmatism up to  $<1$  D. Limbal and corneal relaxing incisions are used for correcting astigmatism of 1–3 D. However, limbal relaxing incisions are associated with potential disadvantages, such as lack of precision, varied healing responses, limited cylinder correction, undercorrection, overcorrection, perforation, wound gape, regression, infection, and loss of best spectacle corrected VA.<sup>[2–6]</sup> Recently, toric IOLs have gained popularity for correcting astigmatism and are found to be effective in correcting moderate to high magnitude of astigmatism.

The AcrySof toric IOL (Alcon Laboratories, Inc., Fort Worth, TX, USA) is an open loop haptic toric IOL with a toric component on the posterior optic surface and axis indentations

indicating the flat meridian of the optic.<sup>[7]</sup> The biomaterial of this lens has demonstrated adhesive properties that support adherence to the capsular bag.<sup>[8]</sup> The haptics are also intended to enhance IOL stability by supporting maximal adherence of the IOL to the capsule.<sup>[7]</sup>

The AT-TORBI (Carl Zeiss Meditec, Berlin, Germany) (previously the Acri comfort toric IOL), is an acrylic, plate haptic IOL, 11 mm in length, possessing two positioning holes on the haptic. It is the first preloaded bitoric MICS IOL and can be inserted through a 1.5 mm incision. The AT-TORBI has a 6 mm optic and can correct high levels of astigmatism, as it is available with a torus of 1–12 D in 0.50 D steps.<sup>[9]</sup>

The major problem with the toric IOLs is their postoperative rotation. It is well known that IOL haptic design is crucial for maintaining axial and rotational stability of the IOL. The postoperative rotation is seen more in early postoperative period and the stability of IOL gradually increases with time.<sup>[10]</sup>

Most of the studies have only studied single type of toric IOL and its postoperative outcome. There are very few comparative studies in literature studying the influence of IOL haptic design on postoperative rotational stability. While the study by Patel *et al.*<sup>[10]</sup> reported plate haptic IOL to be more stable, the study

Access this article online

Website:

www.ijo.in

DOI:

10.4103/ijo.IJO\_73\_18

Quick Response Code:



Department of Ophthalmology, Government Medical College and Hospital, Chandigarh, <sup>1</sup>Advanced Eye Centre, Post Graduate Institute of Medical Education and Research, Chandigarh, India

**Correspondence to:** Dr. Rakesh K Bansal, Department of Ophthalmology, Government Medical College and Hospital, Chandigarh - 160 030, India. E-mail: bansalrk@hotmail.com

**Manuscript received:** 06.03.18; **Revision accepted:** 14.06.18

This is an open access journal, and articles are distributed under the terms of the Creative Commons Attribution-NonCommercial-ShareAlike 4.0 License, which allows others to remix, tweak, and build upon the work non-commercially, as long as appropriate credit is given and the new creations are licensed under the identical terms.

**For reprints contact:** reprints@medknow.com

**Cite this article as:** Seth SA, Bansal RK, Ichhpujani P, Seth NG. Comparative evaluation of two toric intraocular lenses for correcting astigmatism in patients undergoing phacoemulsification. Indian J Ophthalmol 2018;66:1423-8.

by Prinz *et al.*<sup>[11]</sup> showed no significant difference between the two IOL designs but they were based on previous IOL designs. Thus, the present study was planned to compare two different haptic design toric IOLs, i.e. plate haptic vs loop haptic for their postoperative stability and effectiveness in correcting astigmatism.

## Methods

This prospective randomized study with parallel design enrolled patients with age 40–70 years between January 2015 and April 2016, who presented to Refractive Clinic of Tertiary Care Referral Institute, with cataract associated with preoperative regular corneal astigmatism between 1 and 5 D. The study conformed to the tenets of Declaration of Helsinki and was approved by the Institute Ethics Committee. The patients were divided into two groups: Group I included patients implanted with plate haptic toric IOL (AT TORBI, Zeiss) and Group II included patients implanted with loop haptic toric IOL (AcrySof). Randomization was done using computerized random number tables. The case record numbers were used as method of concealment.

Patients with irregular astigmatism, subluxated cataract, or other conditions affecting IOL centration or tilt, corneal dystrophy, tear-film instability, pupillary abnormalities, glaucoma, uveitis, retinal diseases, optic atrophy, or neuro-ophthalmic disease were excluded. Patients developing intraoperative complications such as posterior capsule rent or extension of capsulorhexis or zonular dialysis were also excluded.

### Baseline evaluation

A detailed history and ophthalmological examination was done including careful anterior and posterior segment evaluation and measurement of intraocular pressure.

### Biometry

Preoperative keratometry was performed by the same operator using two different methods: optical coherence biometer (Lenstar LS 900®, Haag–Streit AG, Koeniz, Switzerland) and manual keratometer, to assess magnitude and axis of astigmatism. The keratometry was calculated by two methods to look for concordance and avoid great differences in preoperative keratometry values to avoid postoperative refractive surprise. It was the values of optical keratometry that were relied upon. Axial length was measured by optical coherence biometer. The axial length was matched in both the groups as bag size tends to be larger in long eyes and this is an important factor in toric IOL rotation. Four formulas were used (SRK-T, Holladay, Hoffer Q, and Universal Barrett formula) to calculate standard error (SE) of toric IOL. The four formulas were employed just to look at concordance of calculated IOL power (spherical equivalent). We used Universal Barrett formula for SE calculation as this was found to be more accurate compared to other formulas for all axial lengths.

The determination of model of toric IOL to be implanted and the axis at which it should be placed with an aim of minimum residual cylinder was performed using online calculator ([www.acrysoftoriccalculator.com](http://www.acrysoftoriccalculator.com) and [www.zcalc.meditec.zeiss.com](http://www.zcalc.meditec.zeiss.com)). We did not do any vector analysis. Surgeon-induced astigmatism of 0.37 was incorporated in each calculation (based on his previous surgical results using 2.8 mm incision).

### Procedure

All the surgeries were performed by a single surgeon. Toric marking was done under topical anesthesia at 3, 6, and 9 o'clock using Bubble marker from Appasamy, while the patient was sitting to avoid cyclotorsion errors. The patient was made supine and prior to initiation of surgery, the site of main incision and placement axis was marked using Mendez ring and toric marker. The surgery was performed as a routine procedure. Polishing of anterior capsule was done. Toric IOL was implanted in the bag with orientation of the IOL just few degrees short of the intended axis as per toric calculator. After thorough aspiration of viscoelastic, the IOL axis was aligned to premarked placement axis.

### Follow-up

Postoperative evaluation was done at day 1, 1 week, 1 month, and 3 months. Uncorrected distance visual acuity (UDVA), best corrected visual acuity (BCVA), keratometry, IOL position after full mydriasis by masked observer on slit lamp biomicroscope were noted at 1 week, 1 month, and 3 months. Because Itrace aberrometry is not available at our institute, the position of IOL was checked after full dilatation of pupil, using retroillumination on photo slit lamp and using reticule on the slit lamp to measure the angle of placement. The beam of slit lamp was made narrow and parallel to the axis of the toric IOL. All the observations were made by single independent observer, who did not know the aligned axis of IOL. The data were compiled and statistically analyzed. A note of complications such as persistent corneal edema, pupillary block, retinal detachment, endophthalmitis and/or need for neodymium: YAG capsulotomy was made during the follow-up.

### Statistical analysis

Considering the minimum difference in the astigmatic correction between the two lenses to be detected as 0.5 D, with a standard deviation of 1, 80% power of study, and estimated alpha error of 0.05, the minimum required number of subjects were 21 in each group after accounting for dropouts.

The statistical analysis was carried out using Statistical Package for the Social Sciences (SPSS version 22, IBM, New York, USA). Distributions were summarized as mean  $\pm$  standard deviation. The statistical significance of the differences in the mean values between the groups was computed by Mann–Whitney U test. *P* value  $<$  0.05 was considered statistically significant.

## Results

Forty-two patients were randomized into two groups of 21 each. The patients in Group I had a mean age of  $57.9 \pm 10.9$  years with 10 males and 11 females, while Group II patients had mean age of  $62.6 \pm 11.4$  years with 10 males and 11 females. Both the groups were age and sex matched (*P* = 0.88 and 0.61, respectively).

### Preoperative parameters

#### Preoperative keratometry

The mean preoperative corneal astigmatism in Group I was  $1.87 \pm 1.01$  D (1.07–4.91 D) and in Group II was  $1.82 \pm 1.08$  D (1.04–4.92 D), which was not statistically different (*P* = 0.26). Majority of patients had corneal astigmatism between 1.00

and 1.50 D in both the groups (47.6 and 52.3%, respectively). Nine patients (42.8%) in Group I and eight patients (38%) in Group II had preoperative corneal astigmatism of >1.50 D and ≤3.00 D, while in both the groups only two patients (9.52%) had preoperative corneal astigmatism of >3.00 D.

*Preoperative axial length*

The preoperative axial length in Group I was 23.08 ± 1.25 mm and in Group II was 22.39 ± 1.46 mm, which was not significantly different (P = 0.11).

*Models of IOLs used in both the groups*

The IOL model was calculated as per the online calculator in both the groups. The model of IOL used with their incorporated cylinder is shown in Table 1.

*Spherical equivalent*

The mean preoperative spherical equivalent of the IOL power implanted in both the groups was 20.12 ± 2.83 and 23.06 ± 3.07 in Groups I and II, respectively, which was statistically significant (P = 0.00).

**Postoperative outcomes**

*Postoperative visual acuity*

The VA as assessed by mean logMAR UDVA at 1 month was 0.33 in Group I and 0.27 in Group II (P = 0.59) and at 3 months was 0.2 in both the groups (P = 0.7). The mean logMAR BCVA at 1 month was 0.12 in Group I and 0.18 in Group II (P = 0.05) and at 3 months was 0.09 in Group I and 0.12 in Group II (P = 0.14). It was taken as Snellen equivalent 6/9 (logMAR 0.2) or better for calculation purpose.

Though 47.6% patients in Group I had VA of Snellen equivalent ≥6/9 compared to 19% in Group II at 1 week follow-up, there was no significant difference in the number of patients who attained Snellen equivalent VA of ≥6/9 in the two

groups at final follow-up (P = 0.50). Only two (9.52%) patients in each group had a VA of 6/36 or worse due to corneal edema and inflammation in early postoperative period, but it resolved with topical medications in 2 weeks.

*Residual cylindrical correction*

Mean residual cylindrical refractive error at 1 month follow-up visit in Group I was 0.53 ± 0.31 D (0–1 D) and Group II was 0.58 ± 0.23 D (0.25–1 D) (P = 0.06), while at 3 months follow-up, it was 0.40 ± 0.31 D (0–0.75 D) in Group I and 0.45 ± 0.33 D (0–1 D) in Group II (P = 0.64). The residual refractive cylinder of ≤0.5 D was seen in 66.67 and 61.90% of cases in plate haptic and loop haptic group, respectively, while 100% of cases had residual refractive cylinder ≤1 D in both the groups.

*IOL rotation*

The position of the IOL was noted at each follow-up visit under full dilation of pupils as shown in Figs. 1 and 2.

In Group I at 1 week postoperative, the IOL was oriented within 5° of its intended axis in 16 out of 21 patients (76.19%), which remained stable at 1 month and 3 months follow-up visits, while 20 patients (95.23%) had within 10° of intended axis and only one patient had a rotation of 13° from its intended axis. The average IOL rotation in this group was found to be 3.52 ± 3.84° at 3 months follow-up.

In Group II at 1 week postoperative of the 21 patients, the IOL was oriented within 5° of its intended axis in 19 patients (90.48%). Twenty patients (95.2%) at 1 month and 3 months follow-up visits had the IOL oriented at an axis within 5° of intended axis and only one patient had a rotation of 11° from its intended axis. The average IOL rotation in this group was found to be 2.05 ± 2.56° at 3 months follow-up.

The mean IOL rotation in the lenses in the study population at 1 week, 1 month, and 3 months follow-up visits in both the groups is shown in Table 1. There was no statistically significant difference in the IOL rotation between Group I and Group II at all time points during follow-up. As age group of 40–50 years would be expected to have more aggressive rates of posterior capsule opacification formation and anterior capsular rim fibrosis, which may contribute to IOL rotation, subgroup analysis was performed after dividing them into three groups: age group 40–50, 50–60, and 60–70 years. There was no difference in the IOL rotation within the three age groups (P = 0.29 in Group I and 0.36 in Group II) or between the groups (P = 0.58).

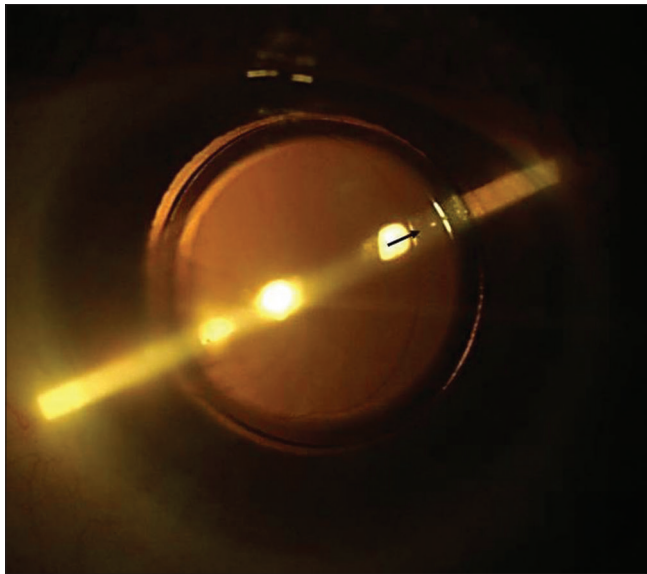
**Discussion**

Cataract surgery has undergone tremendous advances over the years. It has evolved as kerato-refractive procedure wherein preexisting refractive errors are taken care of and every attempt is made to provide spectacle freedom. Astigmatism is one such refractive error. Astigmatism of ≤1 D is not considered a major hurdle for achieving emmetropia. There has been a paradigm shift in addressing astigmatism over the years, from methods utilizing neutralization of corneal astigmatism by astigmatic keratotomy and peripheral corneal relaxing incision, the focus has shifted to implantation of toric IOLs as shown in Table 2.<sup>[12]</sup>

The most common IOL haptic designs used are either plate or loop haptics. The first toric lens (Staar Surgical) was a plate haptic one-piece silicone lens but was associated with rotational

**Table 1: The frequency of each model of IOL used in the two groups and the mean values for IOL rotation at 1 and 3 months in both the groups**

IOL model	Group I		Group II	
	Number of patients	IOL model	Number of patients	IOL model
AT TORBI 709 M (1.00 D Cylinder)	3	SN6AT2	2	
AT TORBI 709 M (1.50 D Cylinder)	10	SN6AT3	10	
AT TORBI 709 M (2 D Cylinder)	5	SN6AT4	1	
AT TORBI 709 M (2.50 D Cylinder)	1	SN6AT5	1	
AT TORBI 709 M (3 D Cylinder)	1	SN6AT6	3	
AT LISA 909 M (1.50 D Cylinder)	1	SN6AT9	4	
<b>Mean IOL rotation</b>				
Follow-up	Group I	Group II	P	
1 week	4.56±3.95	2.83±2.55	0.25	
1 month	3.48±3.86	2.48±2.56	0.65	
3 months	3.52±3.84	2.05±2.56	0.25	



**Figure 1:** Plate haptic toric IOL after full dilatation of pupil

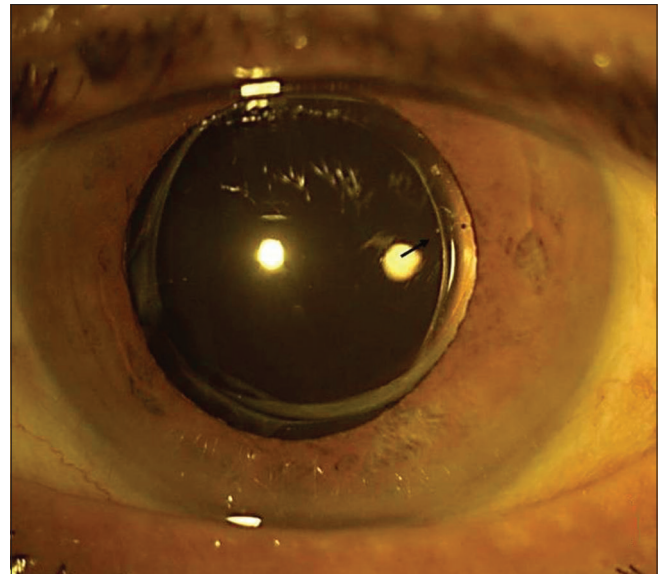
instability and needed early repositioning.<sup>[13]</sup> Chang<sup>[14]</sup> recommended to use the longer IOL whenever available in the desired spherical power, because the presumed mechanism for instability of the shorter lenses was found to be early rotation within large capsules, particularly when the bag circumference was oval rather than circular.

The Zeiss et Torbi IOL is acrylic, plate haptic design but has the advantages of bitoric design and MICS compatibility for astigmatically neutral surgery and correcting high amount of cylinder.<sup>[9]</sup>

The second toric IOL introduced by Alcon Laboratories (Fort Worth, Texas, USA) AcrySof toric IOL was a single-piece, open loop-haptic, hydrophobic acrylic posterior chamber IOL, available in three toric powers; the SN60T3 model corrects 1.5 D, the SN60T4 corrects 2.25 D, and the SN60T5 corrects 3 D in the IOL plane. The biomaterial adheres to the capsular bag using a single layer of lens epithelial cells. As a result, there is no space for the nutrients to pass, which leads to cell death. The lens then adheres directly to the lens capsule, which also minimizes the lens rotation.<sup>[7,8]</sup>

In plate haptic and loop haptic groups, UDVA of 20/40 or better was achieved in 85.7 and 90.4%, respectively, after 3 months of follow-up. Both the groups performed well. Our results were comparable to the observation of Bascaran *et al.*<sup>[9]</sup> and Holland *et al.*<sup>[7]</sup> who recorded the UDVA of 20/40 or better in 88.1 and 92%, respectively.

The mean residual refractive cylinder following toric IOL implantation in our study in cases with plate haptic toric IOL was  $0.40 \pm 0.31$  D and in cases with loop haptic toric IOL was  $0.45 \pm 0.33$  D at 3 months postoperatively and was not statistically significant. It was noted that residual refractive cylinder of 0.5 D or less was seen in 66.67 and 61.90% of cases in plate haptic and loop haptic groups, respectively, while 100% of cases had residual refractive cylinder  $\leq 1$  D in both the groups. Various studies conducted on AcrySof IOL have reported the residual refractive cylinder  $<0.50$  D in the range of 50–90%, but they had a variable follow-up period



**Figure 2:** Loop haptic toric IOL after full dilatation of pupil

**Table 2: Step ladder approach in managing astigmatism**

Measured corneal astigmatism	Treatment options
<1 D	Clear corneal surgical incision is placed on steeper corneal axis; may be coupled with an opposite clear corneal incision
1-3 D (if toric IOL unavailable)	Peripheral corneal relaxing incisions (limbal relaxing incision)
1-4 D	Toric IOLs
4-6 D	High-powered toric IOLs or combination of toric IOL with limbal relaxing incision/bioptics
>6 D	High-powered toric IOL or custom-made toric IOL

[Table 3].<sup>[8,9,13,15-22]</sup> Bascaran<sup>[9]</sup> has studied only AT Torbi IOL and found residual refractive cylinder  $<0.50$  D in 95.2% at 6 months follow-up.

The major problem with the toric IOLs is their postoperative rotation. It is well known that IOL haptic design is crucial for maintaining axial and rotational stability of the IOL. Retained viscoelastic and immediate postoperative IOP fluctuations can also influence IOL stability. We started assessing the IOL axis at 1 week to negate the influence of IOP fluctuations and retained viscoelastic. An average rotation of  $3.52 \pm 3.84^\circ$  was seen in plate haptic design vs  $2.05 \pm 2.56^\circ$  in loop haptic design at 3 months postoperative follow-up. We found much lower postoperative IOL rotation in both the groups as compared to those reported in the literature. The reported IOL rotation varied from 3 to  $9^\circ$  in cases of AcrySof IOL.<sup>[8,14,18,23-26]</sup> This difference can not only be attributed to early vs late postoperative rotation owing to short follow-up of our study because three studies with AcrySof have reported mean postoperative rotation of  $3-4^\circ$  at 1-3 months follow-up.<sup>[13,23,26]</sup> The misalignment rates seen with various types of IOL that have been reported in the literature are summarized in Table 4.<sup>[7,9,14,22-28]</sup> Bascaran *et al.*<sup>[9]</sup> have also

reported mean postoperative IOL rotation of  $4.42 \pm 4.3^\circ$  with AT TORBI IOL at 6 months follow-up.

In plate haptic toric IOL, rotation of  $5^\circ$  or less from its intended axis was seen in 76.1% and  $10^\circ$  or less in 95.2%. Only one patient had rotation of more than  $10^\circ$  from its intended axis. In none of the cases, IOL repositioning was required. In loop haptic group, 95.2% were within  $5^\circ$  of its intended axis, and only one patient showed IOL rotation of more than  $10^\circ$ .

A comparative study was conducted by Torio *et al.*,<sup>[29]</sup> who has compared three toric IOLs (Acrysof, Envista, and Finevision) and compared the rotational stability and cylinder reduction in 68 eyes that had at least 0.75 D of corneal astigmatism. They reported a mean axis deviation of  $2.43^\circ$ ,  $2.66^\circ$ , and  $2.75^\circ$  for Acrysof (loop haptic), Envista (loop haptic), and Finevision (four-point fixation haptic), respectively, and

concluded that there was no significant difference in the rotational stability of the three toric IOLs.

Chua *et al.*<sup>[30]</sup> compared rotational stability of one-piece acrylic and plate haptic silicone toric IOLs in Asian eyes. The mean IOL rotation was  $4.23^\circ$  in the acrylic IOL group and  $9.42^\circ$  in the silicone IOL group at 3 months follow-up, which was statistically significant. They concluded that acrylic toric IOLs had better rotational stability compared to silicone toric IOLs.

Our study had few limitations. Though the patients had short follow-up of 3 months but the IOL rotation decreases whenever anterior and posterior capsule fuses. The capsule fusion starts as early as 2 weeks and IOL rotation is barely seen after 3 months.

The second limitation was lack of Pentacam rotating Scheimpflug camera for keratometry readings as it enhances the accuracy of total corneal astigmatism calculations and the efficacy of toric IOL correction by measuring astigmatism of both the anterior and posterior corneal surfaces.<sup>[31]</sup> The Lenstar allows measurement of the anterior corneal astigmatism. The posterior corneal astigmatism has not been measured in the study. Ignoring the posterior corneal astigmatism can result in overcorrection with the rule of astigmatism and under correction against the rule astigmatism.<sup>[32]</sup>

Further, compared with standard methods, the use of intraoperative aberrometry system for toric lens placement can increase the proportion of eyes with postoperative refractive astigmatism of 0.50 D or less and hence, can reduce the mean postoperative refractive astigmatism.<sup>[33]</sup>

**Conclusion**

In conclusion, both toric IOLs, plate haptics (AT-TORBI toric IOL) and loop haptics (AcrySof toric IOL), performed well in correcting preexisting astigmatism between 1 and 5 D. Although loop haptic AcrySof IOL showed less IOL rotation than plate haptic design at 3 months follow-up, it was statistically insignificant. Both the IOLs were found to be rotationally stable. UDVA and BCVA in both the groups were found to be similar and were, therefore, found to be equally

**Table 3: The reported residual refractive cylinder rates in literature**

Toric IOL*	Study	Follow-up (months)	Residual Refractive astigmatism	
			≤0.50 D	≤1.00 D
Acrysof	Bauer <sup>[15]</sup> (2008)	4	-	91%
	Lane <sup>[16]</sup> (2009)	6	60%	95%
	Ahmed <sup>[17]</sup> (2010)	6	71%	90%
	Holland <sup>[7]</sup> (2010)	12	53%	88%
	Kim <sup>[18]</sup> (2010)	13	87%	100%
	Visser <sup>[19]</sup> (2011)	6	-	81%
	Venkataraman <sup>[20]</sup> (2013)	12	-	94%
	Current study (2016)	3	66.6%	100%
Staar	Till <sup>[13]</sup> (2002)	6	48%	75%
	Ruhswurm <sup>[21]</sup> (2000)	20	49%	78%
Tecnis	Ferreira TB <sup>[22]</sup> (2012)	2	75%	100%
AT TORBI	Bascaran <sup>[9]</sup> (2013)	6	95.2%	100%
	Current study (2016)	3	61.9%	100%

\*IOL: Intraocular Lens

**Table 4: A summary of various IOL misalignment rates that have been reported in literature**

Toric IOL*	IOL design	Study	Follow up	IOL rotation (in degrees)
Acrysof	Loop haptics (Acrylic)	Chang <sup>[14]</sup> (2008)	1 month	3±3
		Mendicute <sup>[23]</sup> (2009)	3 months	4±2
		Koshy <sup>[24]</sup> (2010)	6 months	9±2
		Holland <sup>[7]</sup> (2010)	12 months	4
		Kim <sup>[18]</sup> (2010)	13 months	3±3
		Alio <sup>[25]</sup> (2011)	6 months	5±4
		Mencucci R <sup>[26]</sup> (2014)	3 months	3.2±1
		Current study (2016)	3 months	2.15±2.58
		Tecnis	Loop haptics (Acrylic)	Ferreira TB <sup>[22]</sup> (2012)
Staar	Plate haptic (Silicon)	Chang <sup>[14]</sup> (2008)	1 month	6±8
		Leyland <sup>[27]</sup> (2001)	2 months	9±12
Acri.Comfort	Plate haptics (Acrylic)	Alio <sup>[28]</sup> (2010)	3 months	2±3
AT TORBI (Zeiss)	Plate haptics (Acrylic)	Bascaran <sup>[9]</sup>	6 months	4.42±4.31
		Current study	3 months	3.52±3.82

\*IOL: Intraocular Lens

effective in correcting preexisting corneal astigmatism and achieving spectacle independence.

### Financial support and sponsorship

Nil.

### Conflicts of interest

There are no conflicts of interest.

## References

- Miyake T, Kamiya K, Amano R, Shimizu K. Corneal astigmatism before cataract surgery. *Nippon Ganka Gakkai Zasshi* 2011;115:447-53.
- Horn JD. Status of toric intraocular lenses. *Curr Opin Ophthalmol* 2007;18:58-61.
- Kaufmann C, Peter J, Ooi K, Phipps S, Cooper P, Goggin M, *et al.* Limbal relaxing incisions versus on-axis incisions to reduce corneal astigmatism at the time of cataract surgery. *J Cataract Refract Surg* 2005;31:2261-5.
- Budak K, Yilmaz G, Aslan BS, Duman S. Limbal relaxing incisions in congenital astigmatism: 6-month follow-up. *J Cataract Refract Surg* 2001;27:715-9.
- Bayramlar H, Daglioglu MC, Borazan M. Limbal relaxing incisions for primary mixed astigmatism and mixed astigmatism after cataract surgery. *J Cataract Refract Surg* 2003;29:723-8.
- Carvalho MJ, Suzuki SH, Freitas LL, Branco BC, Schor P, Lima AL. Limbal relaxing incisions to correct corneal astigmatism during phacoemulsification. *J Refract Surg* 2007;23:499-504.
- Holland E, Lane S, Horn JD, Ernest P, Arleo R, Miller KM. The AcrySof Toric intraocular lens in subjects with cataracts and corneal astigmatism: A randomized, subject-masked, parallel-group, 1-year study. *Ophthalmology* 2010;117:2104-11.
- Linnola RJ, Sund M, Ylonen R, Philajaniemi T. Adhesion of soluble fibronectin, vitronectin, and collagen type IV to intraocular lens materials. *J Cataract Refract Surg* 2003;29:146-52.
- Bascaran L, Mendicute J, Macias-Murelaga B, Arbelaitz N, Martinez-Soroa I. Efficacy and stability of AT TORBI 709 M toric IOL. *J Refract Surg* 2013;29:194-9.
- Patel CK. OS. Postoperative intraocular lens rotation: A randomized comparison of loop and plate haptic implants. *Ophthalmology* 1999;106:2190-6.
- Prinz A, Neumayer T, Buehl W, Vock L, Menapace R, Findl O, *et al.* Rotational stability and posterior capsule opacification of a plate-haptic and an open-loop-haptic intraocular lens. *J Cataract Refract Surg* 2011;37:251-7.
- Taneja M. Management of Astigmatism in cataract. *Delhi J Ophthalmol* 2015;25:252-8.
- Till JS, Yoder PR Jr, Wilcox TK, Spielman JL. Toric intraocular lens implantation: 100 consecutive cases. *J Cataract Refract Surg* 2002;28:295-301.
- Chang DF. Comparative rotational stability of single-piece open-loop acrylic and plate-haptic silicone toric intraocular lenses. *J Cataract Refract Surg* 2008;34:1842-7.
- Bauer NJ, de Vries NE, Webers CA, Hendrikse F, Nuijts RM. Astigmatism management in cataract surgery with the AcrySof toric intraocular lens. *J Cataract Refract Surg* 2008;34:1483-8.
- Lane SS, Ernest P, Miller KM, Hileman KS, Harris B, Waycaster CR. Comparison of clinical and patient-reported outcomes with bilateral AcrySof toric or spherical control intraocular lenses. *J Refract Surg* 2009;25:899-901.
- Ahmed II, Rocha G, Slomovic AR, Climenhaga H, Gohill J, Grégoire A. Visual function and patient experience after bilateral implantation of toric intraocular lenses. *J Cataract Refract Surg* 2010;36:609-16.
- Kim MH, Chung TY, Chung ES. Long-term efficacy and rotational stability of AcrySof toric intraocular lens implantation in cataract surgery. *Korean J Ophthalmol* 2010;24:207-12.
- Visser N, Ruiz-Mesa R, Pastor F, Bauer NJ, Nuijts RM, Montés-Micó R. Cataract surgery with toric intraocular lens implantation in patients with high corneal astigmatism. *J Cataract Refract Surg* 2011;37:1403-10.
- Venkataraman A, Kalpana. Visual outcome and rotational stability of open loop toric intraocular lens implantation in Indian eyes. *Indian J Ophthalmol* 2013;61:626-9.
- Ruhswurm I, Scholz U, Zehetmayer M, Hanselmayer G, Vass C, Skorpik C. Astigmatism correction with a foldable toric intraocular lens in cataract patients. *J Cataract Refract Surg* 2000;26:1022-7.
- Ferreira TB, Almeida A. Comparison of the visual outcomes and OPD scan results of AMO tecnis toric and Alcon Acrysof IQ toric intraocular lenses. *J Refract Surg* 2012;8:551-5.
- Mendicute J, Irigoyen C, Ruiz M, Illarramendi I, Ferrer-Blasco T, Montés-Micó R. Toric intraocular lens versus opposite clear corneal incisions to correct astigmatism in eyes having cataract surgery. *J Cataract Refract Surg* 2009;35:451-8.
- Koshy JJ, Nishi Y, Hirschall N, Crnej A, Gangwani V, Maurino V, *et al.* Rotational stability of a single-piece toric acrylic intraocular lens. *J Cataract Refract Surg* 2010;36:1665-70.
- Alio JL, Pinero DP, Tomas J, Aleson A. Vector analysis of astigmatic changes after cataract surgery with toric intraocular lens implantation. *J Cataract Refract Surg* 2011;37:1038-49.
- Mencucci R, Giordano C, Favuzza E, Gicquel JJ, Spadea L, Menchini U. Astigmatism correction with toric intraocular lenses: Wavefront aberrometry and quality of life. *Br J Ophthalmol* 2013;97:578-82.
- Leyland M, Zinicola E, Bloom P, Lee N. Prospective evaluation of a plate haptic toric intraocular lens. *Eye (Lond)* 2001;15:202-5.
- Alio JL, Agdeppa MC, Pongo VC, El Kady B. Microincision cataract surgery with toric intraocular lens implantation for correcting moderate and high astigmatism: Pilot study. *J Cataract Refract Surg* 2010;36:44-52.
- Torio KC, Ang RET, Martinez GHA, Remo JTM. Comparison of the rotational stability of different toric intraocular implants. *Philippine J Ophthalmol* 2014;39:67-72.
- Chua WH, Yuen LH, Chua J, Teh G, Hill WE. Matched comparison of rotational stability of 1-piece acrylic and plate-haptic silicone toric intraocular lenses in Asian eyes. *J Cataract Refract Surg* 2012;38:620-4.
- Zhang B, Ma JX, Liu DY, Guo CR, Du YH, Guo XJ, *et al.* Effects of posterior corneal astigmatism on the accuracy of AcrySof toric intraocular lens astigmatism correction. *Int J Ophthalmol* 2016;9:1276-82.
- Koch DD, Ali SF, Weikert MP, Shirayama M, Jenkins R, Wang L. Contribution of posterior corneal astigmatism to total corneal astigmatism. *J Cataract Refract Surg* 2012;38:2080-7.
- Woodcock MG, Lehmann R, Cionni RJ, Breen M, Scott MC. Intraoperative aberrometry versus standard preoperative biometry and a toric IOL calculator for bilateral toric IOL implantation with a femtosecond laser: One-month results. *J Cataract Refract Surg* 2016;42:817-25.