

Case Series

# Green Nail Syndrome Treated with Ozenoxacin: Two Case Reports

Terenzio Cosio<sup>a,b</sup> Rosalba Petruccelli<sup>c</sup> Roberta Gaziano<sup>d</sup> Carla Fontana<sup>e</sup>  
Marco Favaro<sup>d</sup> Paola Zampini<sup>b</sup> Enrico Salvatore Pistoia<sup>d</sup>  
Laura Diluvio<sup>a</sup> Flavia Lozzi<sup>a</sup> Luca Bianchi<sup>a</sup> Elena Campione<sup>a</sup>

<sup>a</sup>Dermatologic Unit, Department of Systems Medicine, University of Rome Tor Vergata, Rome, Italy; <sup>b</sup>PhD course in Microbiology, Immunology, Infectious Diseases, and Transplants (MIMIT), Microbiology Section, Department of Experimental Medicine, University of Rome "Tor Vergata", Rome, Italy; <sup>c</sup>Laboratory of Microbiology, Polyclinic of "Tor Vergata", Rome, Italy; <sup>d</sup>Department of Experimental Medicine, "Tor Vergata" University, Rome, Italy; <sup>e</sup>National Institute for Infectious Diseases (INMI) L. Spallanzani, IRCCS, Rome, Italy

## Keywords

Green nail syndrome · *Pseudomonas aeruginosa* · *Achromobacter xylosoxidans* · Ozenoxacin

## Abstract

Green nail syndrome (GNS) is a persistent greenish pigmentation of the nail plate, originally described in 1944 by Goldman and Fox, due to *Pseudomonas aeruginosa* infection. Recently, pulmonary co-infection of *P. aeruginosa* and *Achromobacter* spp. has been described in patients with cystic fibrosis. *Achromobacter xylosoxidans* is a multidrug-resistant (MDR) pathogen involved in lung and soft tissue skin infections. Both *Achromobacter xylosoxidans* and *P. aeruginosa* are mainly found in humid environments or in water. There are no recognized co-infections due to *P. aeruginosa* and *A. xylosoxidans* in the skin and appendages. We describe two cases of GNS, the first due to *P. aeruginosa* associated with *Achromobacter xylosoxidans*; the other due to MDR *P. aeruginosa*, both successfully treated with topical ozenoxacin 1% cream daily for 12 weeks. The clinical management of GNS can be confusing, especially when the bacterial culture result is inconsistent or when non-*Pseudomonas* bacteria are isolated. In our case, due to the co-infection of *P. aeruginosa* and *Achromobacter* spp., local treatment with ozenoxacin – the first nonfluorinated quinolone – could be a safe and effective treatment in case of MDR nail infections. Further studies are required to evaluate clinical isolation from nail infections and the co-presence of *P. aeruginosa* and *A. xylosoxidans*.

© 2023 The Author(s).  
Published by S. Karger AG, Basel

Correspondence to:  
Terenzio Cosio, [terenziocosio@gmail.com](mailto:terenziocosio@gmail.com)

## Introduction

Green nail syndrome (GNS) also known as chloronychia is a persistent greenish pigmentation of the nail plate, originally described in 1944 by Goldman and Fox, due to *Pseudomonas aeruginosa* infection [1, 2]. *P. aeruginosa* is a Gram-negative, aerobic, coccobacillus belonging to the Pseudomonadaceae family [3]. These pathogens are widespread in nature and can be present in soil, water, plants, and animals (including humans). Moreover, *P. aeruginosa* is an opportunistic human pathogen that can produce pulmonary, kidney, and urinary tract infections as well as systemic infections. *P. aeruginosa* is not part of normal skin flora and can also be involved in soft tissue, skin, and nail infections in immunocompetent subjects and patients with immune deficiency syndrome, although infections of the intact nail are rare [3, 4]. *P. aeruginosa* is often co-isolated with other microbial species sharing the same environment, but the available information regarding interactions with emerging pathogens is still limited. *P. aeruginosa* and *S. aureus* are frequently co-isolated in clinical settings. The co-infection leads to delayed wound repair, increased antibiotic resistance and mortality related to the mixed-biofilm formation [5].

Recently, pulmonary co-infection of *P. aeruginosa* and *Achromobacter* spp. has been described in patients with cystic fibrosis [6, 7]. *Achromobacter xylosoxidans* is an emerging, multidrug-resistant pathogen involved in lung and soft tissue skin infection. It is common in nature and mainly found in water just like *P. aeruginosa* [8]. To date, there are no recognized co-infections due to *P. aeruginosa* and *A. xylosoxidans* in skin and skin appendages. In this case series, we describe the first documented cases of GNS due to *P. aeruginosa* associated with *Achromobacter xylosoxidans* and the first use of ozenoxacin in nail infections.

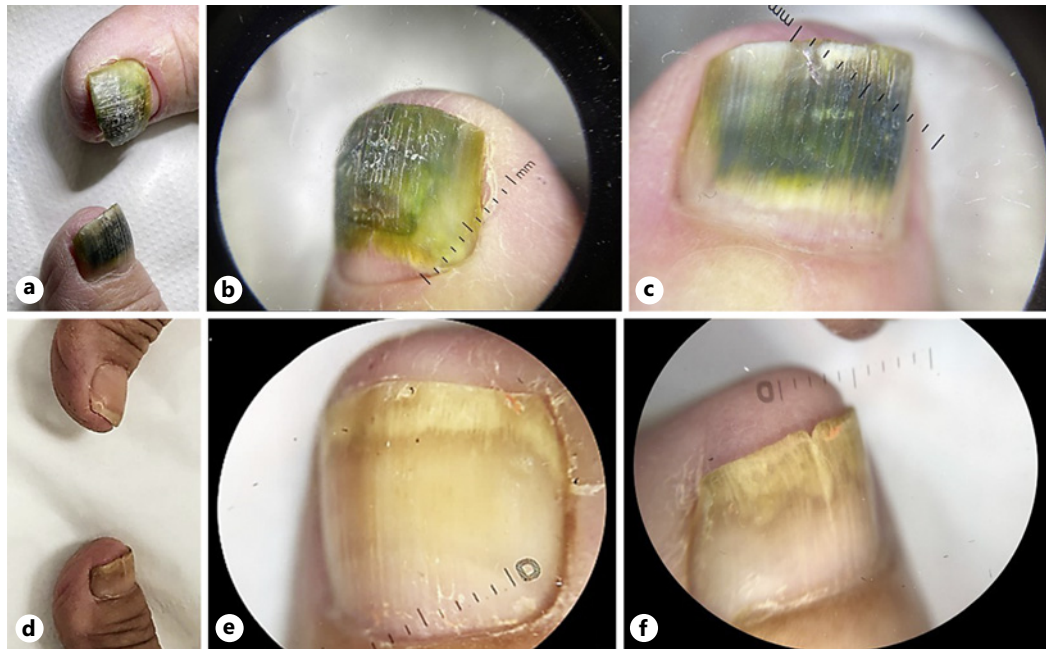
## Case I

A 65-year-old healthy retired woman came to our attention for a symptomatic greenish discoloration of the nail plate of the right and left fingernails over a period of 10 months. The patient reported she had suffered from *Candida parapsilosis* nail infection 2 years before but did not treat it. Dermatologic examination showed greenish-yellow bilateral discoloration of the first fingernail. Onychoscopy revealed an intense green color of the nail with shaded and irregular yellow areas, especially in the proximal area, mild onychodystrophy of the entire nail plate, onychomadesis, and distal onycholysis (Fig. 1a–c). A predisposing factor was daily water contact, typical of subjects such as housewives.

The bacteriologic culture of nail clipping was positive for multidrug-resistant (MDR) *A. xylosoxidans* and for quinolone-resistant (QR) *P. aeruginosa* (Table 1). Fungal co-infection was excluded by potassium hydroxide preparation and culture. Due to the co-infection of *P. aeruginosa* and *A. xylosoxidans*, topical therapy with ozenoxacin 1% cream daily for 12 weeks was prescribed. After 12 weeks of application, the patient presented clinical resolution, regrowth of the right nail, and disappearance of the chloronychia of the left nail without any local adverse events (Fig. 1d, e). Follow-up at 12 months did not provide any clinical signs of re-infection or adverse event.

## Case II

A 48-year-old healthy woman came to our attention for an asymptomatic greenish discoloration of the nail plate of the first left toenail over a period of 15 days. No concomitant comorbidities were reported. Dermatologic examination showed greenish-yellow bilateral



**Fig. 1.** **a** The patient presents bilateral green-yellow discoloration of the nail plate and onycholysis of the right nail. **b** Onychoscopy of the right nail reveals diffuse green-yellow pigmentation and onycholysis of the nail from the matrix. **c** Onychoscopy of the left nail shows widespread green coloration with proximal yellow irregular discoloration, suggesting the presence of *P. aeruginosa*. **d** The patient presents resolution of the infections after 12 weeks of topical treatment. No green or structural alterations could be detected at macroscopic examination. **e** Onychoscopy of the right nail reveals resolution of the green pigmentation without permanent alteration. **f** Onychoscopy of the left nail shows the absence of the infections and a regrowing white nail with no structural alterations.

discoloration of the first fingernail. Onychoscopy revealed a light greenish, circular area of the nail with mild onycholysis (Fig. 2).

A gel polish was applied 30 days before and then removed. This caused visible traumatization in the distal part of the nail. The bacteriologic culture of nail clipping was positive for MDR *P. aeruginosa* (Table 2).

Fungal co-infection was excluded by potassium hydroxide preparation and culture. Due to MDR *P. aeruginosa* topical therapy with ozenoxacin 1% cream daily for 12 weeks was prescribed, with a follow-up after 8 weeks. Follow-up at 11 months did not provide any clinical signs of re-infection or adverse event. The CARE Checklist has been completed by the authors for this case series, attached as online supplementary material (for all online suppl. material, see <https://doi.org/10.1159/000533923>).

## Discussion

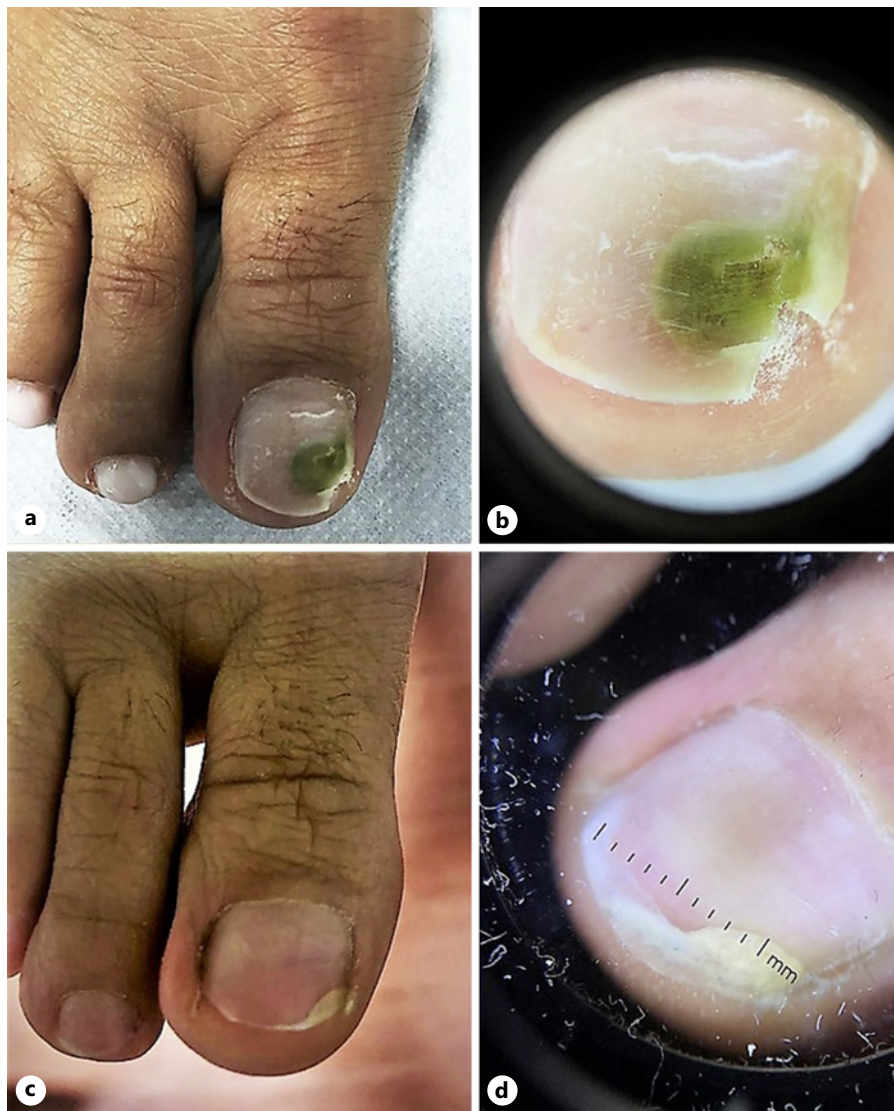The pathogenesis of nail infections caused by *P. aeruginosa* is not fully elucidated. *P. aeruginosa* can be a colonizer on healthy skin but if there is a trauma or alteration of the nail unit barrier, *Pseudomonas* can penetrate and lead to a clinically manifest infection. Onycholysis could be followed by secondary *Pseudomonas* infection, especially when the nails are exposed to a warm and damp environment. Chloronychia in Goldman-Fox

**Table 1.** Antibiotic susceptibility testing interpreted according to the European Committee on Antimicrobial Susceptibility Testing (EUCAST) criteria (2022) for patient 1

	<i>P. aeruginosa</i>	<i>A. xylosoxidans</i> spp. <i>xylosoxidans</i>
Amikacin	2 S	16 R
Cefepime	2 I	16 R
Cefotaxime		>64 R
Ceftazidime	2 I	2 S
Ceftazidime/avibactam	2 S	2 S
Ceftolozane/tazobactam	0.5 S	8 R
Ciprofloxacin	0.25 I	>4 R
Colistin	≤0.5 S	
Gentamicin	1 S	8 R
Imipenem	1 I	1 S
Meropenem	≤0.25 S	≤0.25 S
Meropenem (meningitis)	≤0.25 S	
Piperacillin/tazobactam	≤4 I	≤4 S
Tobramycin	1 S	8 R

S, susceptible; I, susceptible, increased exposure; R, resistant.

syndrome, including chloronychia and viridionychia, is mainly due to *Pseudomonas aeruginosa*, characterized by green discoloration of the nail plate. However, also other bacteria such as *Citrobacter braakii* could be involved in this condition [9–11]. Although the diagnosis of GNS is mainly clinical, bacterial culture should always be performed to identify non-*Pseudomonas* bacteria and provide a complete antibiotic resistance profile. The clinical management of the syndrome can be confusing, especially when the bacterial culture result is inconsistent or when non-*Pseudomonas* bacteria or MDR bacteria are isolated with *P. aeruginosa*. Lee et al. [10] reported an inconsistent bacterial culture for *P. aeruginosa* in 64.7% (17/22) of patients in their study. Moreover, they identified only 12 cultures positive for *P. aeruginosa* (35.2%), while 22 (64.7%) resulted positive for other bacteria. Despite a poor positive rate in *P. aeruginosa* culture, fluoroquinolones have good therapeutic efficacy, with 22 (64.7%) patients showing complete clearance and eight (23.5%) showing notable improvement [10]. *A. xylosoxidans* should be considered a potential pathogen in patients with skin and soft tissue infections, especially in patients with vascular diseases or after surgery or trauma. A history of contact with water should be investigated in all cases [12]. Topical and systemic fluoroquinolones and aminoglycosides are the mainstay for the treatment of Gram-negative as *Pseudomonas* spp. [13, 14]. In our case, due to the nail co-infection of *P. aeruginosa* and *Achromobacter* spp. no guidelines or previous reports have been published, and antibiotic stewardship has been crucial to act on both pathogens and thus reduce adverse events. However, for *A. xylosoxidans*, there are no solid data, in vivo or in vitro, regarding optimal topical antibiotic treatment [15]. Following the antibiogram and after a review of the literature, we decided to treat the patients with topical ozenoxacin 1% cream for 12 weeks. Ozenoxacin is a topical, fourth-generation quinolone, showing potent antimicrobial activities against Gram-negative and Gram-positive bacteria and widely used for the treatment of inflammatory acne [16].



**Fig. 2.** **a** The patient presents a greenish pigmentation of the distal part of the toenail. **b** Onychoscopy of the right nail reveals a diffuse greenish pigmentation and onycholysis, suggestive for *P. aeruginosa* infection. **c** The patient presents a resolution of the distal pigmentation and improvement in onycholysis of the toenail. **d** Onychoscopy of the right nail reveals the complete resolution of the green pigmentation and a light onychomadesis with negative culture.

Ozenoxacin is approved in Europe to treat non-bullous impetigo in adults and children aged  $\geq 6$  months [17]. It has excellent in vitro antibacterial activity against Gram-positive cocci, including QR strains with mutations in the QR determining region, being 3–321-fold more active than other quinolones [17, 18]. This strong in vitro activity of the new quinolones is probably based on improved affinity for the DNA gyrase and topoisomerase IV targets, creating more potent antibiotic and decreasing the in vitro selection of mutants and the emergence of spontaneous resistant mutants in clinical settings [19, 20]. In this view, we decided to use ozenoxacin in the treatment of our patients. To date, no data regarding the use of ozenoxacin have been reported against Gram-negative *Pseudomonas* spp. and *Achromobacter* spp. In our case, we have

**Table 2.** Antibiotic susceptibility testing interpreted according to the European Committee on Antimicrobial Susceptibility Testing (EUCAST) criteria (2022) for patient 2

	<i>P. aeruginosa</i>
Amikacin	2 S
Cefepime	2 I
Ceftazidime	2 I
Ceftazidime/avibactam	2 S
Ceftolozane/tazobactam	1.5 S
Ciprofloxacin	>4 R
Colistin	2 S
Gentamicin	2 S
Imipenem	4 R
Meropenem	≤ 0.25 S
Meropenem (meningitis)	≤ 0.25 S
Piperacillin/tazobactam	≤ 4 I
Tobramycin	4 R

S, susceptible; I, susceptible, increased exposure; R, resistant.

described the co-presence of *Pseudomonas* spp. and *Achromobacter* spp., paving the way for further studies concerning the microbiome of the nail and demonstrating the efficacy of topical ozenoxacin. More detailed research should be conducted to understand its clinical administration in MDR nail infections.

## Conclusion

The results of our study show that topical treatment with ozenoxacin 1% cream can determine the clinical and microbiological resolution of chloronychia caused by *P. aeruginosa* and *Achromobacter* spp. without nail plate removal. Moreover, these cases highlight the complexity of the nail microbiome in GNS and provide a possible treatment option in case of MDR co-infection of the nail unit. Nonetheless, future studies are required to evaluate nail infections and the co-presence of *P. aeruginosa* and *A. xylosoxidans* as culprit bacteria in skin and skin appendage infection.

## Acknowledgments

We would like to thank Denis Mariano, who kindly revised the English language.

## Statement of Ethics

Ethical approval is not required for this study in accordance with local or national guidelines. Written informed consent was obtained from the patients for publication of this case series and any accompanying images.

## Conflict of Interest Statement

The authors have no conflicts of interest to declare.

## Funding Sources

This research received no external funding.

## Author Contributions

Conceptualization: Terenzio Cosio, Roberta Gaziano, and Elena Campione; methodology and writing—original draft preparation, Terenzio Cosio, Roberta Gaziano; validation and data curation, Terenzio Cosio, Rosalba Petrucelli, Roberta Gaziano, Carla Fontana, Marco Favaro, Paola Zampini, Enrico Pistoia, Laura Diluvio, Flavia Lozzi, Luca Bianchi, Elena Campione; investigation and writing—review and editing, Terenzio Cosio, Rosalba Petrucelli, Roberta Gaziano, Carla Fontana, Marco Favaro, Paola Zampini, Enrico Pistoia, Flavia Lozzi, Luca Bianchi, Elena Campione; resources and supervision, Roberta Gaziano, Elena Campione; project administration, Terenzio Cosio. All authors have read and agreed to be accountable for all aspects of the work in ensuring that questions related to the accuracy or integrity of any part of the work are appropriately investigated and resolved.

## Data Availability Statement

All data generated or analyzed during this study are included in this article. Further inquiries can be directed to the corresponding author.

## References

- 1 Goldman L, Fox H. Greenish pigmentation of nail plates from bacillus pyocyanus infection: report of two cases. *Arch Derm Syphilol*. 1944;49(2):136–7.
- 2 Schwartz RA, Kapila R. The Goldman-Fox syndrome: treating and preventing green pseudomonas nails in the era of COVID-19. *Dermatol Ther*. 2021;34(1):e14624.
- 3 Diggle SP, Whiteley M. Microbe Profile: *Pseudomonas aeruginosa*: opportunistic pathogen and lab rat. *Microbiology*. 2020;166(1):30–3.
- 4 Moser C, Jensen PØ, Thomsen K, Kolpen M, Rybtke M, Lauand AS, et al. Immune responses to *Pseudomonas aeruginosa* biofilm infections. *Front Immunol*. 2021;12:625597.
- 5 Serra R, Grande R, Butrico L, Rossi A, Settimio UF, Caroleo B, et al. Chronic wound infections: the role of *Pseudomonas aeruginosa* and *Staphylococcus aureus*. *Expert Rev Anti Infect Ther*. 2015;13(5):605–13.
- 6 Esposito S, Pisi G, Fainardi V, Principi N. What is the role of *Achromobacter* species in patients with cystic fibrosis? *Front Biosci*. 2021;26(12):1613–20.
- 7 Menetrey Q, Sorlin P, Jumas-Bilak E, Chiron R, Dupont C, Marchandin H. *Achromobacter xylosoxidans* and *Stenotrophomonas maltophilia*: emerging pathogens well-armed for life in the cystic fibrosis patients' lung. *Genes*. 2021;12(5):610.
- 8 Crosby MD, Petropolis AA, Mackey VT, Culpepper KS. An unusual skin infection with *Achromobacter xylosoxidans*. *Cutis*. 2020;106(4):2110–212.
- 9 Mulita F, Tchabashvili L, Liolis E, Tasios K, Iliopoulos F, Kaplanis C, et al. Green nail syndrome caused by *Citrobacter braakii*. *Clin Case Rep*. 2021;9(5):e04203.
- 10 Lee H, Mun JH, Cho S, Park H. Clinical analysis of *Pseudomonas aeruginosa*-positive and -negative green nail syndrome cases: a single center retrospective analysis. *J Dermatol*. 2021;48(7):1073–6.
- 11 Forouzan P, Cohen PR. Fungal viridionychia: onychomycosis-induced chloronychia caused by *Candida parapsilosis*-associated green nail discoloration. *Cureus*. 2021;13(12):e20335.
- 12 Tena D, Martínez NM, Losa C, Solís S. Skin and soft tissue infection caused by *Achromobacter xylosoxidans*: report of 14 cases. *Scand J Infect Dis*. 2014;46(2):130–5.
- 13 Chiriaca A, Brzezinski P, Foia L, Marincu I. Chloronychia: green nail syndrome caused by *Pseudomonas aeruginosa* in elderly persons. *Clin Interv Aging*. 2015;10:265–7.
- 14 Müller S, Ebnöther M, Itin P. Green nail syndrome (*Pseudomonas aeruginosa* nail infection): two cases successfully treated with topical nadifloxacin, an acne medication. *Case Rep Dermatol*. 2014;6(2):180–4.

- 15 Beauruelle C, Lamoureux C, Mashi A, Ramel S, Le Bihan J, Ropars T, et al. In Vitro activity of 22 antibiotics against *achromobacter* isolates from people with cystic fibrosis. Are their new therapeutic options? [Microorganisms](#). 2021;9(12):2473.
- 16 Tabara K, Tamura R, Nakamura A, Mori S, Kitano T, Fujikawa K, et al. Anti-inflammatory effects of ozenoxacin, a topical quinolone antimicrobial agent. [J Antibiot](#). 2020;73(4):247–54.
- 17 Torreló A, Grimalt R, Masramon X, Albareda López N, Zsolt I. Ozenoxacin, a new effective and safe topical treatment for impetigo in children and adolescents. [Dermatology](#). 2020;236(3):199–207.
- 18 López Y, Muñoz L, Gargallo-Viola D, Cantón R, Vila J, Zsolt I. Uptake of ozenoxacin and other quinolones in gram-positive bacteria. [Int J Mol Sci](#). 2021;22(24):13363.
- 19 López Y, Tato M, Espinal P, Garcia-Alonso F, Gargallo-Viola D, Cantón R, et al. In vitro activity of Ozenoxacin against quinolone-susceptible and quinolone-resistant gram-positive bacteria. [Antimicrob Agents Chemother](#). 2013;57(12):6389–92.
- 20 Mitton-Fry MJ, Brickner SJ, Hamel JC, Brennan L, Casavant JM, Chen M, et al. Novel quinoline derivatives as inhibitors of bacterial DNA gyrase and topoisomerase IV. [Bioorg Med Chem Lett](#). 2013;23(10):2955–61.