

## Inflammation and infection

## Two cases of nonbacterial cystitis associated with nivolumab, the anti-programmed-death-receptor-1 inhibitor

Kimihiko Shimatani <sup>a</sup>, Tetsuro Yoshimoto <sup>a</sup>, Yutaka Doi <sup>a</sup>, Takashi Sonoda <sup>b</sup>, Shingo Yamamoto <sup>c</sup>, Akihiro Kanematsu <sup>c,\*</sup>

<sup>a</sup> Meiwa Hospital, Urology Department, Japan

<sup>b</sup> Meiwa Hospital, Medical Oncology Department, Japan

<sup>c</sup> Hyogo College of Medicine, Urology Department, Japan

## ARTICLE INFO

## Article history:

Received 26 November 2017

Accepted 14 December 2017

Available online 28 January 2018

## Keywords:

Nivolumab

PD-1

Cystitis

## 1. Introduction

Anti-programmed-death-receptor-1 (anti-PD1) inhibitor, nivolumab, is an immune checkpoint inhibitor, which has recently been widely used and has become a standard treatment for various cancers, including non-small cell lung cancer and renal cell carcinoma. Nivolumab is known to induce various immune-related adverse effects (irAEs) in the lungs, skin, gastrointestinal tract, and endocrine organs. The most frequent irAEs of nivolumab were reported to be fatigue (34.2%), rash (25.9%), and diarrhea (19.2%).<sup>1</sup> However, no report exists regarding the adverse effect of nivolumab on the urinary bladder. Here, we report two cases of nonbacterial cystitis after long-term nivolumab administration.

## 2. Case presentation

## 2.1. Case 1 (Fig. 1A)

A 50-year-old man was referred to us for sudden onset

pollakisuria, micturition pain, and diarrhea after seven cycles of nivolumab for stage IV lung squamous cell carcinoma. Urinalysis results were normal before treatment of nivolumab, but at the referral, significant pyuria with >100 white blood cells per high power field, mainly neutrophils in urine cytology, were found (Fig. 1B). Levofloxacin was administered for 10 days, but had no effect on the symptom; a urine culture was negative for bacteria. The micturition pain was so severe that daily living activities were restricted. It was suspected that the symptoms were related to nivolumab, and upon discussion with the medical oncologist treating his lung cancer, 60 mg of oral prednisolone (1 mg/kg/day) was initiated. After the steroid treatment, the symptoms and pyuria immediately alleviated. However, readministration of nivolumab exacerbated the symptoms. After the eighth cycle, nivolumab treatment was discontinued for progression of lung cancer, and the symptoms and pyuria completely disappeared. The dosage of the steroid was tapered gradually, without recurrent bladder symptoms.

## 2.2. Case 2 (Fig. 2A)

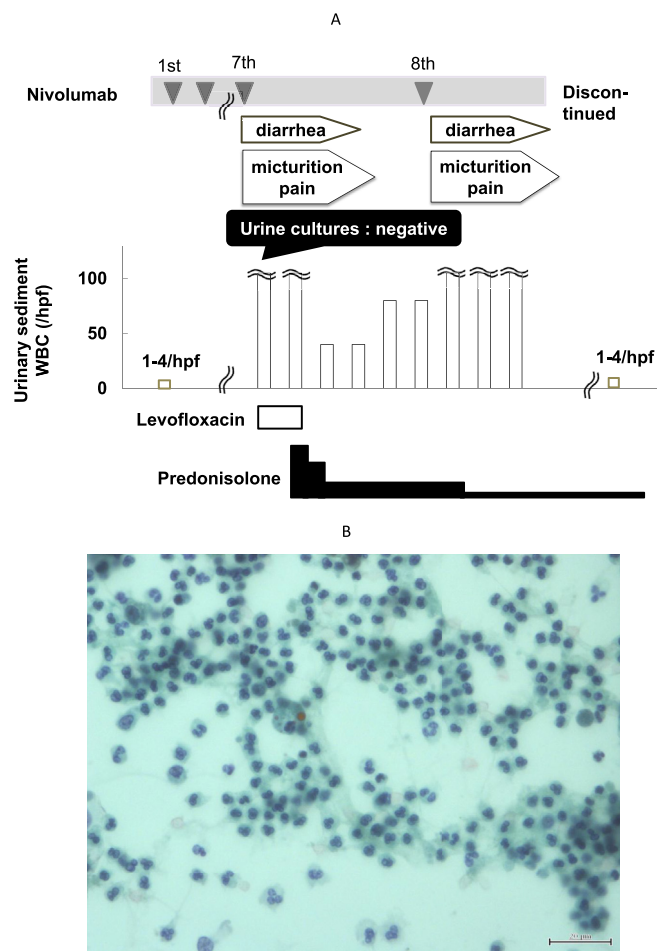
A 60-year-old man presented with pollakisuria, dysuria, and diarrhea after 12 courses of nivolumab administration for stage IV lung squamous cell carcinoma. Urinalysis revealed that pyuria consisted of neutrophils and lymphocytes in urine cytology (Fig. 2B). The symptoms and pyuria were resistant to antibiotics and the urine culture was negative. Similar to the first case, the symptoms and pyuria improved or worsened in accordance with discontinuation and readministration of nivolumab. By discontinuing nivolumab treatment, the symptoms resolved completely.

## 3. Discussion

This is the first report on non-bacterial cystitis associated with the administration of an immune checkpoint inhibitor. In the two presented cases, symptoms such as micturition pain and nonbacterial pyuria appeared similarly after long-term nivolumab

\* Corresponding author. Hyogo College of Medicine, Urology Department, 1-1 Mukogawacho, Nishinomiya, Japan.

E-mail address: [aqui@hyo-med.ac.jp](mailto:aqui@hyo-med.ac.jp) (A. Kanematsu).

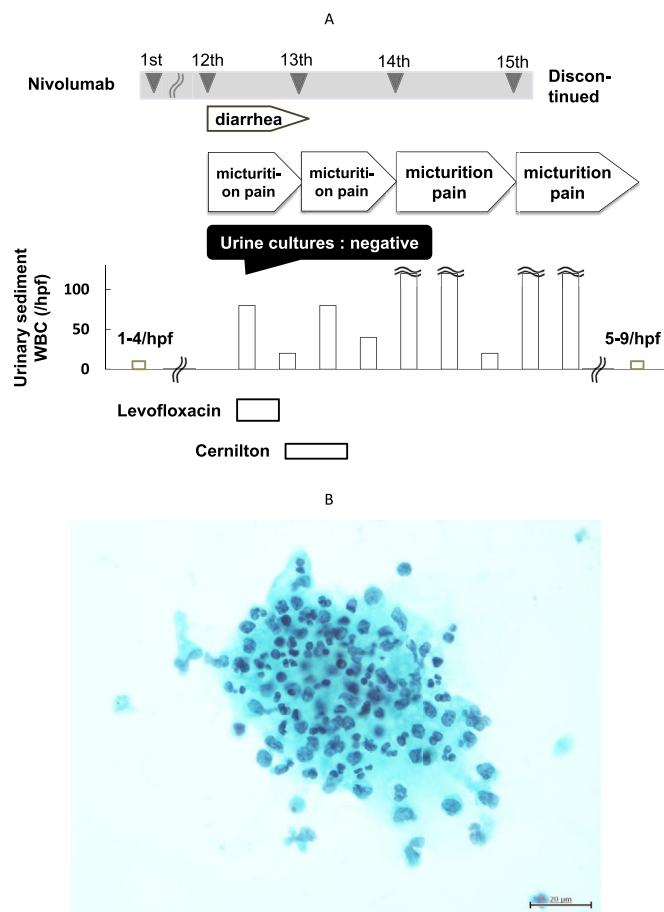


**Fig. 1.** A). Clinical course of Case 1. B) Cytological appearance of urine in Case 1. Acute inflammation mainly consisted of neutrophils in urine cytology.

treatment. The symptoms and pyuria coincided with nivolumab administration and rapidly improved by taking oral prednisolone. Therefore, both patients were considered to have experienced immune-related adverse effects (irAEs) related to nivolumab.

Nivolumab, an immune checkpoint inhibitor, which blocks the PD-1 receptor, works as an antitumor agent by maintaining activity of T-lymphocytes. Concurrently, various organs could experience adverse effects from autoimmunity. Nivolumab, used for non-small cell lung cancer, has been reported to exert irAEs in the lungs, skin, gastrointestinal tract, and endocrine organs, but no study had reported these effects on the urinary bladder.<sup>2</sup> According to the manufacturer's post-marketing surveillance of nivolumab among the 11761 cases, there was a very small number of adverse events that involved the bladder; nonbacterial cystitis in 1 case, urethral pain in 1 case, and pollakisuria in 2 cases.<sup>3</sup> However, precise clinical course, management, and the outcomes of these patients were not reported. Therefore, to the best of our knowledge, this is the first report showing a clinical relationship between nivolumab and lower urinary tract pathology.

Sugino et al. reported, in an experimental animal model, that inhibition of an immune checkpoint was associated with irAEs in the bladder. They reported existence of anti-urothelial autoantibody (AUAb) in BALB/c mice deficient of two genes, PD-1 and low affinity type IIb FC receptor for IgG (FCγRII). The double-knockout mice that had AUAb developed autoimmune cystitis with reduced



**Fig. 2.** A). Clinical course of Case 2. B) Cytological appearance of urine in Case 2. Inflammatory cells consisted of neutrophils and lymphocytes in urine cytology.

bladder capacity.<sup>4</sup> This model may not be completely similar to our clinical cases. We did not attempt to detect AUAb in our patients due to technical difficulty, but reversibility of the symptoms in the clinical cases seems to be unlikely for antibody-mediated inflammation. For development of autoimmune cystitis in mice, ablation of the PD-1 gene alone was not sufficient, but ablation of another gene, FCγRII, was required. Therefore, blockade of the PD-1 receptor alone in a human could, but only rarely, induce non-bacterial cystitis as irAEs, as seen in these cases.

One common feature between these two cases was concomitant diarrhea, which paralleled clinical improvement and exacerbation of the bladder symptoms. It may implicate that the autoimmune response in the bladder may have a certain common feature with irAE in digestive tract. Interestingly, the reported double-knockout mice exhibited elevated tissue TNF alpha levels in both the bladder and digestive tract.<sup>4</sup>

Clinically, as far as we know, this is the first report of non-bacterial cystitis associated with immune checkpoint inhibition therapy. Although the cases are still rare, it is expected that we could encounter similar cases more frequently in the future because of increased usage of nivolumab for various cancers and continued long-term administration, as these drugs enable longer survival for cancer patients. Not only the PD-1 receptor, but also the PD-1 ligand could potentially induce similar irAEs in the bladder. Therefore, the management stated in this report could be referenced as a prototype therapy for bladder irAEs. Regarding management of irAEs, it is recommended to discontinue the

administration of the drug and to administer steroids according to the grade of Common Terminology Criteria for Adverse Events.<sup>5</sup> Adequate and prompt treatment should be initiated before conditions become severe, because irreversible and fatal sequelae do occur in other organs, such as interstitial pneumonia and gastrointestinal perforation.

#### 4. Conclusion

We reported two cases of nonbacterial cystitis associated with nivolumab treatment. Today nivolumab and other immune checkpoint drugs are employed against various kinds of cancer for longer term. Thus, we must be aware of their potential risk of bladder irAEs and its adequate management.

#### Acknowledgment

This work was supported by JSPS KAKENHI Grant Number 17K10164 for A.K.

#### Appendix A. Supplementary data

Supplementary data related to this article can be found at <https://doi.org/10.1016/j.eucr.2017.12.006>.

#### Disclosures

The authors have no conflicts of interest to declare.

#### References

1. Larkin J, Chiarion-Sileni V, Gonzalez R, et al. Combined nivolumab and ipilimumab or monotherapy in untreated melanoma. *N Engl J Med*. 2015;373:23–34.
2. ONO Pharmaceutical. Opdivo (Nivolumab) Guide for Appropriate Use (NSCLC). [https://uat.opdivo.jp/contents/pdf/open/guide\\_nsclc.pdf](https://uat.opdivo.jp/contents/pdf/open/guide_nsclc.pdf).
3. ONO Pharmaceutical. Opdivo (Nivolumab) Occurrence of Adverse Drug Reactions. [https://uat.opdivo.jp/contents/pdf/open/side\\_effect.pdf](https://uat.opdivo.jp/contents/pdf/open/side_effect.pdf).
4. Sugino Y, Nishikawa N, Yoshimura K, et al. BALB/c-Fcgr2bPdc1 mouse expressing anti-urolithelial antibody is a novel model of autoimmune cystitis. *Sci Rep*. 2012;2:317.
5. Katharina CK, Jessica CH, Lucie H, et al. Management of side effects of immune checkpoint blockade by anti-CTLA-4 and anti-PD-1 antibodies in metastatic melanoma. *JDDG*. 2016;14(7):662–681.