JACC: CASE REPORTS VOL. 1, NO. 2, 2019

CASE REPORT

BEGINNER

HEART CARE TEAM/MULTIDISCIPLINARY TEAM LIVE

Pheochromocytoma-Induced Takotsubo Syndrome Treated With Extracorporeal Membrane Oxygenation

Beware of the Apical Sparing Pattern

Omid Kiamanesh, MD,[a] Erik N. Vu, MD,[b] Douglas L. Webber, MD,[c] Edgar Lau, MD,[d] Jordanna E. Kapeluto, MD,[e] Heather Stuart, MD, MSc,[f] David A. Wood, MD,[a] Graham C. Wong, MD, MPH[a]

JACC: CASE REPORTS CME/MOC/ECME

This article has been selected as this issue's CME/MOC/ECME activity, available online at http://www.acc.org/jacc-journals-cme by selecting the *JACC* Journals CME/MOC/ECME tab.

Accreditation and Designation Statement

The American College of Cardiology Foundation (ACCF) is accredited by the Accreditation Council for Continuing Medical Education (ACCME) to provide continuing medical education for physicians.

The ACCF designates this Journal-based CME/MOC/ECME activity for a maximum of 1 *AMA PRA Category 1 Credit(s)*™. Physicians should only claim credit commensurate with the extent of their participation in the activity. Successful completion of this CME activity, which includes participation in the evaluation component, enables the participant to earn up to 1 Medical Knowledge MOC point in the American Board of Internal Medicine's (ABIM) Maintenance of Certification (MOC) program. Participants will earn MOC points equivalent to the amount of CME credits claimed for the activity. It is the CME activity provider's responsibility to submit participant completion information to ACCME for the purpose of granting ABIM MOC credit.

Pheochromocytoma-Induced Takotsubo Syndrome Treated With Extracorporeal Membrane Oxygenation: Beware of the Apical Sparing Pattern will be accredited by the European Board for Accreditation in Cardiology (EBAC) for 1 hour of External CME credits. Each participant should claim only those hours of credit that have actually been spent in the educational activity. The Accreditation Council for Continuing Medical Education (ACCME) and the European Board for Accreditation in Cardiology (EBAC) have recognized each other's accreditation systems as substantially equivalent. Apply for credit through the post-course evaluation. While offering the credits noted above, this program is not intended to provide extensive training or certification in the field.

Method of Participation and Receipt of CME/MOC/ECME Certificate

To obtain credit for this CME/MOC/ECME activity, you must:

1. Be an ACC member or *JACC: Case Reports* subscriber.
2. Carefully read the CME/MOC/ECME-designated article available online and in this issue of the *journal*.
3. Answer the post-test questions. A passing score of at least 70% must be achieved to obtain credit.
4. Complete a brief evaluation.
5. Claim your CME/MOC/ECME credit and receive your certificate electronically by following the instructions given at the conclusion of the activity.

CME/MOC/ECME Objective for This Article: Upon completion of this activity, the learner should be able to: 1) describe the classification of Takotsubo syndrome; 2) recognize common triggers of Takotsubo syndrome; 3) differentiate Takotsubo syndrome from common mimicking diagnoses; and 4) describe long-term outcomes of patients with Takotsubo syndrome.

Author Disclosures: The authors have reported that they have no relationships relevant to the contents of this paper to disclose.

Medium of Participation: Online (article and quiz).

CME/MOC/ECME Term of Approval

Issue Date: August 2019
Expiration Date: July 31, 2020

From the [a]Division of Cardiology, University of British Columbia, Vancouver, Canada; [b]Division of Critical Care Medicine, University of British Columbia, Vancouver, Canada; [c]Department of Pathology and Laboratory Medicine, University of British Columbia, Vancouver, Canada; [d]Department of Medicine, Richmond General Hospital, Richmond, Canada; [e]Division of Endocrinology, University of British Columbia, Vancouver, Canada; and the [f]Division of General Surgery, University of British Columbia, Vancouver, Canada. The authors have reported that they have no relationships relevant to the contents of this paper to disclose.

Manuscript received May 6, 2019; revised manuscript received June 16, 2019, accepted June 19, 2019.

ISSN 2666-0849 https://doi.org/10.1016/j.jaccas.2019.06.001

JACC: CASE REPORTS, VOL. 1, NO. 2, 2019
AUGUST 2019:85–90

Pheochromocytoma-Induced Takotsubo Syndrome Treated With Extracorporeal Membrane Oxygenation

Beware of the Apical Sparing Pattern

Omid Kiamanesh, MD,[a] Erik N. Vu, MD,[b] Douglas L. Webber, MD,[c] Edgar Lau, MD,[d] Jordanna E. Kapeluto, MD,[e] Heather Stuart, MD, MSc,[f] David A. Wood, MD,[a] Graham C. Wong, MD, MPH[a]

ABSTRACT

A 45-year-old female presents with suspected acute myocardial infarction with cardiogenic shock requiring mechanical circulatory support. Pheochromocytoma-induced atypical Takotsubo syndrome is diagnosed. Clinicians should suspect high catecholamine states as a cause of the basal subtype of atypical Takotsubo syndrome. (**Level of Difficulty: Beginner.**)
(J Am Coll Cardiol Case Rep 2019;1:85–90)

A 45-year-old woman with diabetes mellitus type II, dyslipidemia, and a family history of premature coronary artery disease presented to a peripheral hospital with severe retrosternal chest pain, dyspnea, and headache lasting 30 min. She rapidly decompensated and received mechanical ventilation and vasopressor support before transfer for the management of cardiogenic shock.

At our institution, the patient required high-dose infusions of norepinephrine, dobutamine, epinephrine, and vasopressin for hemodynamic support. Her temperature was 36.9°C, heart rate 120 beats/min, blood pressure 82/64 mm Hg, and oxygen saturation 94% on mechanical ventilation (positive end-expiratory pressure 12 mm Hg, tidal volume 500 ml, fraction of inspired oxygen 1.0, and respiratory rate 16 breaths/min). Her skin was cold and mottled, and her jugular venous pulse was elevated. Auscultation yielded normal heart sounds and scattered pulmonary crackles. Her white blood cell count was 33.3×10^9/l, creatinine 156 μmol/l, arterial pH 7.27, venous lactate 9.4 mmol/l, troponin I 49.5 μg/l, B-type natriuretic peptide 124 ng/l, and C-reactive protein 14.4 mg/l (**Table 1**). An electrocardiogram showed sinus tachycardia, possible septal infarct, and widespread upsloping ST-segment depression (**Figure 1**). Chest x-ray showed pulmonary edema (**Figure 2**). An emergent transthoracic echocardiogram demonstrated severe left ventricular (LV) systolic dysfunction with a hyperdynamic apex and akinesis of the remaining walls (Video 1).

LEARNING OBJECTIVES

- To identify the 4 main variants of TTS.
- To recognize pheochromocytoma-related crisis as a cause of TTS.
- To recognize the basal subtype of atypical TTS and its association with pheochromocytoma.

WHAT ARE THE DIFFERENTIAL DIAGNOSIS AND NEXT STEPS IN MANAGEMENT?

This 45-year-old patient with multiple cardiovascular risk factors presents with chest pain, electrocardiographic evidence of myocardial ischemia, biomarker evidence of myocyte necrosis, and cardiogenic shock. Acute myocardial infarction is suspected, which may be caused by atherosclerotic plaque rupture or other causes of myocardial oxygen supply and demand imbalance, such as coronary vasospasm, coronary embolism, spontaneous coronary artery dissection, or microvascular dysfunction. Emergent cardiac catheterization and coronary angiography is indicated to exclude epicardial coronary artery disease with the additional benefit of yielding hemodynamic data.

Emergency coronary angiography showed normal epicardial coronary arteries (Videos 2A and 2B), a LV end-diastolic pressure of 36 mm Hg, and an estimated LV ejection fraction of 15% by ventriculography. The mid- and basal-ventricular segments were akinetic and the apex was hyperdynamic. Endomyocardial biopsy was not performed.

HOW DOES THIS INFORMATION REFINE THE DIFFERENTIAL DIAGNOSIS AND NEXT STEPS OF MANAGEMENT?

Approximately 6% of patients with suspected myocardial infarction will have no obstructive coronary artery disease (1). This should prompt clinicians to consider other causes of myocyte injury, including ischemic causes due to myocardial infarction in the absence of obstructive coronary artery disease. Coronary vascular imaging with intravascular ultrasound and optical coherence tomography may identify subtle plaque rupture, emboli and/or thrombus, or coronary artery dissection. Coronary functional assessment may demonstrate coronary spasm or microvascular disease. The revised concept of myocardial infarction in the absence of obstructive coronary artery disease mandates that nonischemic causes of myocyte injury are excluded before a diagnosis of myocardial infarction in the absence of obstructive coronary artery disease can be made (2,3). Contrast cardiac magnetic resonance imaging may identify nonischemic causes such as Takotsubo syndrome (TTS), myocarditis, or cardiomyopathies. The pattern of regional wall motion abnormality in this case did not fit a coronary artery distribution or typical pattern of TTS, and therefore myocarditis was suspected.

SEE PAGE 91

A provisional diagnosis of fulminant myocarditis was made and high-dose empiric methylprednisolone was administered. Several hours later, the patient's blood pressure became labile and rose from 84/60 mm Hg to 190/106 mm Hg. All prior vasoactive agents were discontinued and infusions of milrinone and nitrates were administered for inotropy and vasodilation. After 1 h, her blood pressure precipitously dropped to 64/50 mm Hg and remained critically low despite vasopressor support. Transesophageal echocardiogram showed severe LV systolic dysfunction with apical sparing (Videos 3A, 3B, 3C, and 3D). Temporary mechanical circulatory support was required.

WHAT SHOULD GUIDE DEVICE SELECTION FOR TEMPORARY MECHANICAL CIRCULATORY SUPPORT?

Mechanical circulatory support device selection should be dictated by the requirements for cardiac support (LV, right ventricular, or biventricular) and oxygenation. In this case, LV support and oxygenation were required, and therefore peripheral veno-arterial extracorporeal membrane oxygenation was a suitable choice. If oxygenation was not required, an alternate strategy may use percutaneous insertion of a LV-to-aortic pump or left atrial-to-arterial pump to treat LV failure.

Peripheral veno-arterial extracorporeal membrane oxygenation was initiated. A computed tomography angiogram to assess the femoral arteries showed an incidental 4.2-cm right adrenal lesion (**Figure 3**), raising the possibility of pheochromocytoma-induced TTS.

The patient's 24-h urine metanephrine and epinephrine levels measured 51× and 109× the upper limit of normal, respectively (**Table 1**). Adrenal computed tomography, adrenal magnetic resonance imaging, and technetium-99m metaiodobenzylguanidine whole-body scintigraphy scan showed a 4.2 × 3.8 × 3.6 cm heterogeneous

ABBREVIATIONS AND ACRONYMS

CT = computed tomography

ED = emergency department

LV = left ventricle

LVEF = left ventricular ejection fraction

MIBG = metaiodobenzylguanidine

MRI = magnetic resonance imaging

TEE = transesophageal echocardiogram

TTE = transthoracic echocardiogram

TTS = Takotsubo syndrome

TABLE 1 Laboratory Data

	Reference Range	Day 0	Day 2
White blood cell count	4.0–11.0 × 10^9/l	33.3	28.3
Hemoglobin, g/l	120–155	141	100
Platelets	140–400 × 10^9/l	301	123
International normalized ratio	0.9–1.2	1.0	1.1
Partial thromboplastin time, s	25–38	26	41
Sodium, mmol/l	135–145	141	144
Potassium, mmol/l	3.5–5.0	3.6	4.5
Chloride, mmol/l	95–107	105	112
Carbon dioxide, mmol/l	22–31	19	27
Urea, mmol/l	2.0–8.2	8.7	5.2
Creatinine, μmol/l	40–95	155	55
Phosphate, mmol/l	0.80–1.45	1.74	1.01
Ionized calcium, mmol/l	1.10–1.30	1.05	1.17
Magnesium, mmol/l	0.7–1.10	0.96	1.09
Lactate, mmol/l	0.5–2.2	9.4	1.9
Troponin I, μg/l	<0.05	49.48	22.4
Beta natriuretic peptide, ng/l	<59	124	
C-reactive protein, mg/l	<3.1	14.4	–
Arterial blood gas			
Fraction of inspired oxygen,		1.0	0.3 (ECMO)
pH	7.35–7.45	7.27	7.46
Partial pressure of carbon dioxide, mm Hg	35–45	48	37
Partial pressure of oxygen, mm Hg	>80	425	119
24-h urine excretion			
Creatinine, mmol/day	0.5–16.0	–	11.4
Metanephrine, μmol/day	0.26–1.73	–	88.10
Normetanephrine, μmol/day	0.48–2.42	–	18.72
Norepinephrine, μmol/day	89–470	–	11,257
Epinephrine, μmol/day	<160	–	17,564
Dopamine, μmol/day	0.4–3.3	–	0.9
Volume, l	0.6–2.4	-	2.753

ECMO = extracorporeal membrane oxygenation.

JACC: CASE REPORTS, VOL. 1, NO. 2, 2019
AUGUST 2019:85–90

FIGURE 1 ECG on Presentation to Emergency Department

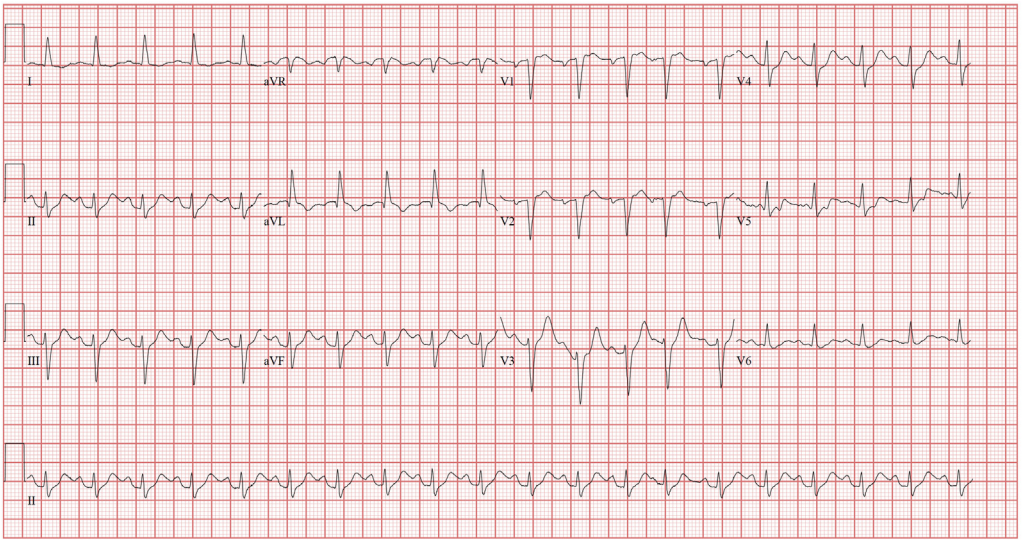

An electrocardiogram (ECG) was taken on the patient's presentation to emergency department.

right adrenal mass with an intralesional hemorrhage that was metaiodobenzylguanidine avid (**Figure 4**), confirming the diagnosis of pheochromocytoma.

The patient was separated from veno-arterial extracorporeal membrane oxygenation on day 3. She received 2 weeks of therapy with nonselective (phenoxybenzamine) and alpha-1 selective (doxazosin) alpha-adrenoreceptor antagonists along with intravenous fluid with sodium loading in preparation for surgical excision of the adrenal mass. Preoperative cardiac magnetic resonance imaging showed near normalization of LV function and no evidence of myocardial scar or edema (Video 4). Open right adrenalectomy was safely performed, yielding a 4.0 × 3.0 × 3.3 cm tumor that was confined within the adrenal capsule and had extensive tumor necrosis (**Figure 5**). The tumor showed zellballen groups of relatively large, but monomorphic neoplastic cells with abundant basophilic to amphophilic cytoplasm, diagnostic of pheochromocytoma when within the adrenal gland (**Figure 6**). After an uncomplicated post-operative course and a total of 24 days in the hospital, the patient was discharged with a diagnosis of pheochromocytoma-induced TTS. She did not require medical therapy and remained clinically stable at follow-up at 2 months.

FIGURE 2 Radiograph of Acute Pulmonary Edema and Malposition of Endotracheal Tube

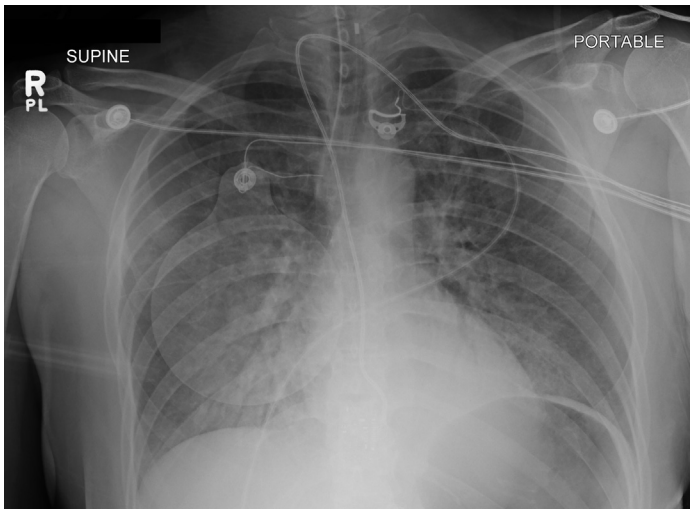

Portable chest radiograph demonstrated acute pulmonary edema and malposition of an endotracheal tube.

WHAT IS TTS?

TTS is an increasingly recognized clinical syndrome that often mimics an acute myocardial infarction and is characterized by transient myocardial dysfunction in the absence of culprit coronary artery disease (4). TTS may be precipitated by a wide range of physical and emotional stress factors (5). Whereas previous diagnostic criteria of TTS have explicitly excluded cases of pheochromocytoma (6), the contemporary International Expert Consensus Document on

FIGURE 3 CT Scan of Right Adrenal Mass

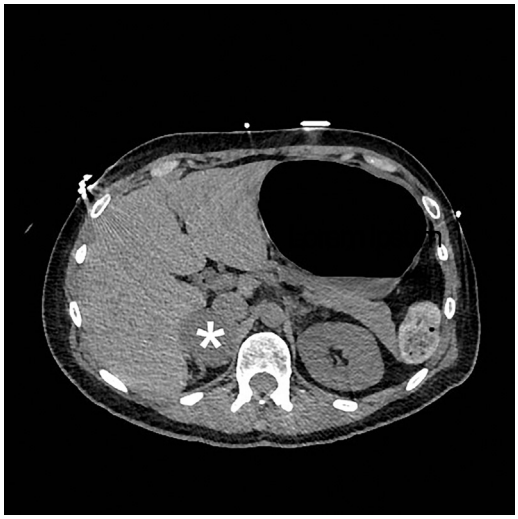

Computed tomography (CT) scan showing an incidental 4.2-cm right adrenal mass **(*)**.

FIGURE 4 MIBG Scan of Right Adrenal Mass

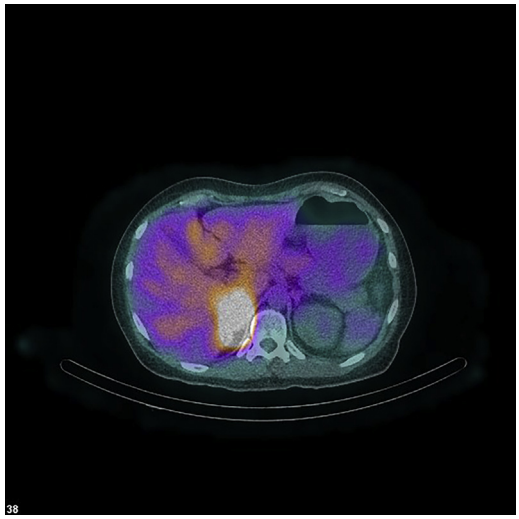

Technetium-99m metaiodobenzylguanidine (MIBG) whole-body scintigraphy scan showing a 4.2 × 3.8 × 3.6-cm heterogeneous right adrenal mass with an MIBG avid focus.

Takotsubo syndrome acknowledges pheochromocytoma as a known trigger of TTS (5). Fulminant myocarditis was the preliminary diagnosis in this case; however, the later findings of blood pressure lability and adrenal mass were suggestive of pheochromocytoma-related crisis.

HOW IS TTS SUBTYPED?

The 4 major TTS variants are differentiated by the pattern of regional wall motion abnormality. The stereotypic pattern is the apical ballooning type (typical TTS) and occurs in 81.7% of patients. Atypical TTS types include mid-ventricular, basal, and focal wall motion abnormalities (5). The basal subtype of atypical TTS demonstrated in this case is a particularly rare phenotype and occurs in only 2.2% of all-comers with TTS (7). It is associated with high-catecholamine states, including pheochromocytoma, epinephrine infusion, and subarachnoid hemorrhage (8-10). The basal subtype is particularly common in pheochromocytoma-induced TTS, occurring in 30% of such cases (9). The rapid resolution of LV dysfunction demonstrated in this case is characteristic of TTS and a distinguishing feature from cardiomyopathies.

CONCLUSIONS

TTS occurs in a minority of patients with suspected myocardial infarction but is an increasingly recognized cause of cardiogenic shock in the absence of

FIGURE 5 Right Adrenal Gland With Extensive Tumor Necrosis

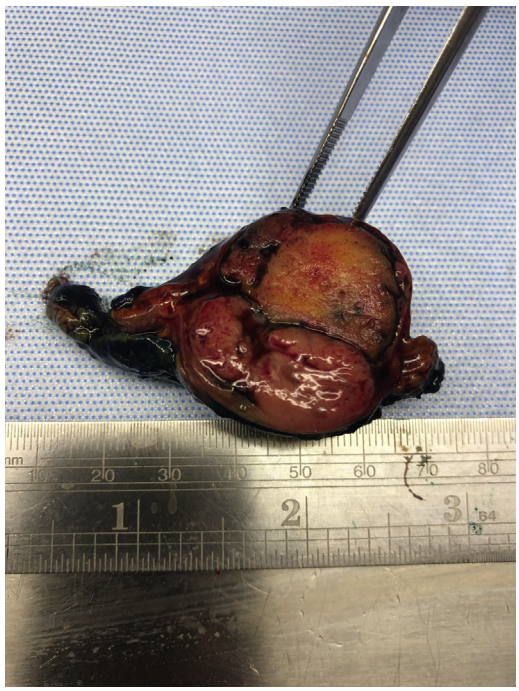

Right adrenal gland with extensive tumor necrosis of a 4.0 × 3.0 × 3.3-cm tumor confined within the adrenal capsule.

JACC: CASE REPORTS, VOL. 1, NO. 2, 2019
AUGUST 2019:85–90

FIGURE 6 H&E Stain of Resected Adrenal Tumor

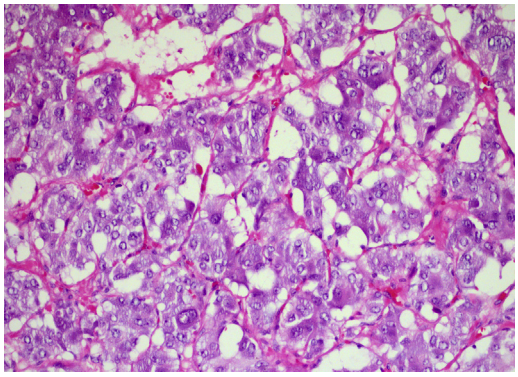

Hematoxylin and eosin (H&E) stain of a section of the resected adrenal tumor at 200× magnification shows zellballen groups of relatively large, but monomorphic neoplastic cells with abundant basophilic to amphophilic cytoplasm, which are diagnostic of pheochromocytoma when within the adrenal gland.

significant atherosclerotic coronary artery disease. The basal subtype of atypical TTS is particularly rare, occurring in 2.2% of all-comers with TTS. Pheochromocytoma is a known trigger for TTS and presents with the basal subtype in 30% of patients with pheochromocytoma-induced TTS. Given the rarity of the basal TTS, the strong association of the basal subtype of TTS with pheochromocytoma, and the high rate of complications with pheochromocytoma-induced TTS, clinicians should consider this pheochromocytoma in the evaluation of a patient with basal TTS.

ACKNOWLEDGMENT The authors thank Dr. Faisal Alballa for their contribution to this paper.

ADDRESS FOR CORRESPONDENCE: Dr. Graham Wong, University of British Columbia Division of Cardiology, Floor 9, 2775 Laurel Street, Vancouver, British Columbia V5Z 1M9, Canada. E-mail: gcwong@mail.ubc.ca.

REFERENCES

1. Pasupathy S, Air T, Dreyer RP, Tavella R, Beltrame JF. Systematic review of patients presenting with suspected myocardial infarction and nonobstructive coronary arteries. Circulation 2015;131:861–70.

2. Tamis-Holland JE, Jneid H, Reynolds HR, et al., for the American Heart Association Interventional Cardiovascular Care Committee of the Council on Clinical Cardiology, Council on Cardiovascular and Stroke Nursing, Council on Epidemiology and Prevention, Council on Quality of Care and Outcomes Research. Contemporary diagnosis and management of patients with myocardial infarction in the absence of obstructive coronary artery disease: a scientific statement from the American Heart Association. Circulation 2019;139:e891–908.

3. Thygesen K, Alpert JS, Jaffe AS, et al., for the ESC Scientific Document Group. Fourth universal definition of myocardial infarction (2018). Eur Heart J 2019;40:237–69.

4. Agewall S, Beltrame JF, Reynolds HR, et al., for the Work Group on Cardiovascular Pharmacotherapy. ESC working group position paper on myocardial infarction with non-obstructive coronary arteries. Eur Heart J 2017;38:143–53.

5. Ghadri JR, Wittstein IS, Prasad A, et al. International expert consensus document on Takotsubo syndrome (part I): clinical characteristics, diagnostic criteria, and pathophysiology. Eur Heart J 2018;39:2032–46.

6. Prasad A, Lerman A, Rihal CS. Apical ballooning syndrome (Tako-Tsubo or stress cardiomyopathy): a mimic of acute myocardial infarction. Am Heart J 2008;155:408–17.

7. Lairez O, Koenig W, Hasenfuss G, et al. Clinical features and outcomes of Takotsubo (stress) cardiomyopathy. N Engl J Med 2015;373:929–38.

8. Y-Hassan S. Clinical features and outcome of epinephrine-induced takotsubo syndrome: analysis of 33 published cases. Cardiovasc Revascularization Med 2016;17:450–5.

9. Y-Hassan S. Clinical features and outcome of pheochromocytoma-induced Takotsubo syndrome: analysis of 80 published cases. Am J Cardiol 2016;117:1836–44.

10. Shoukat S, Awad A, Nam DK, et al. Cardiomyopathy with inverted Tako-Tsubo pattern in the setting of subarachnoid hemorrhage: a series of four cases. Neurocrit Care 2013;18:257–60.

KEY WORDS advanced heart failure, cardiogenic shock, extracorporeal membranous oxygenation, pheochromocytoma, Takotsubo syndrome

APPENDIX For supplemental videos, please see the online version of this paper.