

Bhooma R. Aravamuthan,
MD, DPhil
Iván Sánchez Fernández,
MD

Jonathan Zurawski, MD
Heather Olson, MD
Mark Gorman, MD
Masanori Takeoka, MD

*Neurol Neuroimmunol
Neuroinflamm*
2015;2:e150; doi: 10.1212/
NXI.000000000000150

PEDIATRIC ANTI-HU-ASSOCIATED ENCEPHALITIS WITH CLINICAL FEATURES OF RASMUSSEN ENCEPHALITIS

OPEN

Anti-Hu antibodies (anti-neuronal nuclear antibodies, type 1) are associated with paraneoplastic encephalomyelitis in adults, especially those with small cell lung cancer. Anti-Hu antibodies are extremely rare in children, but they have been observed in neuroblastoma with or without opsoclonus-myoclonus syndrome or in limbic encephalitis without associated malignancy.¹ However, anti-Hu antibodies are not typically associated with clinical features of Rasmussen encephalitis (RE).

Case history. We present a 5-year-old right-handed girl meeting clinical, EEG, and MRI diagnostic criteria for RE² but with elevated serum and CSF anti-Hu antibodies. She was asymptomatic until age 4, when she developed simple partial seizures with right face and arm clonic movements without epilepsy partialis continua (EPC). She then developed right lower facial weakness, dysarthria, and stagnation in cognition and learning. EEG showed left hemispheric slowing and left frontotemporal focal seizures. Serial MRIs showed progressive left-greater-than-right hemispheric atrophy and left frontal, temporal, insular and caudate greater than right frontal and temporal T2 signal hyperintensity (figure). She had no personality changes, ataxia, opsoclonus, movement disorders, dysautonomia, neuropathy, or myopathy.

Diagnostic evaluation 1 year after symptom onset included serum and CSF inflammatory markers and antibodies (including anti-glutamic acid decarboxylase, anti-NMDA receptor, anti-contactin-associated protein 2, and anti-leucine-rich glioma-inactivated 1 protein). Results were notable for elevated anti-Hu antibody titers (Mayo Clinic Paraneoplastic Antibody Panel immunofluorescence assay³) in serum (1:960, normal <1:240) and CSF (1:16, normal <1:2), 13 CSF oligoclonal bands, and CSF neopterin of 67 nmol/L (normal 7–40 nmol/L) without significant pleocytosis (2 white and 0 red blood cells per mm³) or high titers of other anti-neuronal antibodies. Serum striational

antibody titer was 1:3,840 (normal <1:120) with normal anti-acetylcholine receptor (AChR) antibody and normal collapsin response-mediator protein 5 immunoglobulin (CRMP-5-IgG). Serum thyroperoxidase (TPO) antibody was 15.6 IU/mL (normal <15 IU/mL) with normal thyroid function. Head magnetic resonance angiogram and malignancy workup including whole-body MRI, urine homovanillic acid, and urine vanillylmandelic acid were unremarkable.

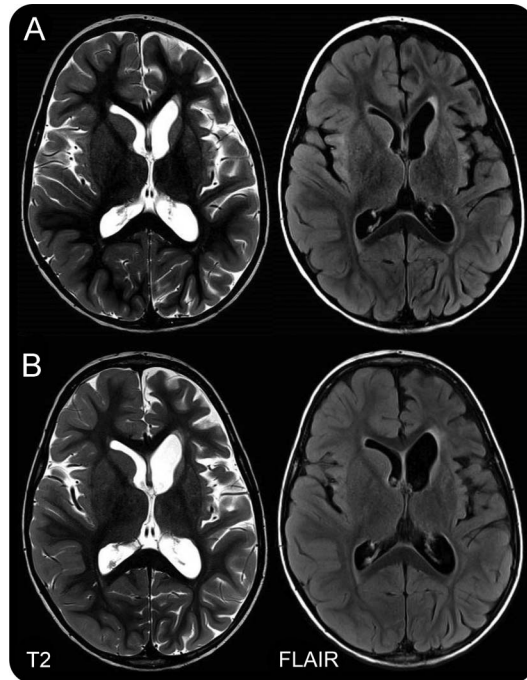
Treatment has included 3 courses of methylprednisolone 30 mg/kg/mo, 7 courses of cyclophosphamide 750 mg/m²/mo, and maintenance immunotherapy with mycophenolate mofetil 600 mg/m²/d. Eleven months after her diagnosis, her seizure frequency has improved from once daily to once weekly on levetiracetam and lacosamide, her right facial weakness has resolved, and her mother notes improvement in school performance.

Discussion. We describe a novel presentation of anti-Hu-associated encephalitis with features of RE.² Cases of anti-Hu-associated EPC have been reported with focal cortical lesions but without hemispheric atrophy or other RE features.^{4–6} Notably, our patient has no malignancy, opsoclonus-myoclonus, or limbic encephalitis, which are typically seen in pediatric anti-Hu-associated encephalitis.¹

Anti-Hu antibodies are not thought to be directly toxic but have been associated with the presence of Hu-specific T cells.¹ This could direct T cell-mediated cytotoxicity considered to be a pathophysiologic mechanism of RE.² Anti-Hu-associated encephalitis, as in our patient, is most commonly treated with IV immunoglobulins, cyclophosphamide, and/or methylprednisolone. Since both anti-Hu-associated encephalitis and RE involve T cell-mediated cytotoxicity, T cell-directed treatments may be particularly useful. Furthermore, as anti-Hu-associated cytotoxicity could further affect her contralateral hemisphere, hemispherectomy alone may not be sufficient to control her seizures and may not be curative.

Our patient has predominantly unilateral hemispheric atrophy, but she also has mild contralateral atrophy and T2 hyperintensity. Diffuse cerebral

Figure Progressive unilaterally predominant brain atrophy



Brain MRI with predominantly left-greater-than-right hemispheric atrophy and T2 hyperintensity involving the caudate that has progressed between 2 months (A) and 10 months (B) after seizure onset. FLAIR = fluid-attenuated inversion recovery.

damage may be due to the fact that Hu antigens are expressed by all neurons.¹ The pathophysiology underlying unilaterally predominant atrophy is unclear given that Hu antigens are ubiquitously expressed. In a previous case of anti-Hu encephalitis, Hu antigen neuronal expression variability was hypothesized to underlie focal pathologic features.⁴

In addition to high anti-Hu titers, our patient also had mild elevation of 2 other autoantibodies, as has been noted previously.³ Anti-TPO levels in Hashimoto thyroiditis and encephalopathy are >100–1,000 IU/mL. An anti-TPO level of 15.6 is likely not pathogenic. Anti-striated muscle antibodies are classically elevated in thymoma-associated myasthenia, although they are nonspecific and may be a generic marker of autoimmunity. Absence of myasthenic features and normal anti-AChR antibody and CRMP-5-IgG make thymoma-associated myasthenia unlikely.⁷ Anti-Hu antibodies may also be a nonspecific inflammatory marker. Noting the difficulty of comparing titers across labs, our patient's serum anti-Hu titer is lower than in previous pediatric cases (>1:10,000), but it is still 4 times the upper normal limit.¹

This case provides insights into the anti-Hu-associated neurologic disorder spectrum. New-onset

refractory focal seizures or focal cerebral atrophy, including RE, could be a presentation of anti-Hu-associated encephalitis. Thorough evaluations for autoimmune etiologies should be strongly considered, especially because this could potentially guide treatment.

From the Department of Neurology (B.R.A., I.S.F., H.O., M.G., M.T.), Boston Children's Hospital; Department of Neurology (J.Z.), Beth Israel Deaconess Medical Center; and Harvard Medical School (B.R.A., I.S.F., J.Z., H.O., M.G., M.T.), Boston, MA.

Author contributions: Bhooma Aravamathan helped formulate the diagnostic and treatment plan for the patient as part of the patient's inpatient clinical team. She also researched and drafted this manuscript. Iván Sánchez Fernández helped formulate the diagnostic and treatment plan for the patient as part of the patient's inpatient clinical team. He also helped revise this manuscript. Jonathon Zurawski initially evaluated the patient in outpatient clinic and referred her to the Epilepsy Division for further workup of possible Rasmussen encephalitis. He also helped revise this manuscript. Heather Olson helped formulate the diagnostic and treatment plan for the patient as part of the patient's inpatient clinical team. She also helped revise this manuscript. Mark Gorman helped formulate further diagnostic and treatment plans for the patient following discovery of anti-Hu antibodies in her serum and CSF. He continues to care for this patient in clinic. He also helped revise this manuscript. Masanori Takeoka directed formulation of the diagnostic and treatment plan for the patient as the primary attending of the patient's inpatient clinical team. He continues to care for this patient in clinic. He also helped revise this manuscript and supervised the researching and drafting of this manuscript.

Acknowledgment: The authors thank Sean J. Pittock, MD, for his assistance in the interpretation of serum and CSF anti-Hu antibody titers and for explaining the methodologic processes involved in the Mayo Clinic Paraneoplastic Antibody Panel.

Study funding: No targeted funding reported.

Disclosures: B. Aravamathan reports no disclosures. I. Sánchez Fernández received research support from Fundacion Alfonso Martin Escudero and HHV6 Foundation. J. Zurawski reports no disclosures. H. Olson spends 20% of her clinical effort on evaluating and treating epilepsy and received research support from NIH, Dravet Syndrome Foundation, Child Neurology Foundation, and Rasmussen Encephalitis Children's Project. M. Gorman received research support from NIH, United States Department of Defense, and National Multiple Sclerosis Society. M. Takeoka is on the editorial board for Journal of Pediatric Epilepsy and received research support from Children's Hospital Boston. Go to Neurology.org for full disclosure forms. The Article Processing Charge was paid by the authors.

This is an open access article distributed under the terms of the Creative Commons Attribution-NonCommercial-NoDerivatives License 4.0 (CC BY-NC-ND), which permits downloading and sharing the work provided it is properly cited. The work cannot be changed in any way or used commercially.

Received May 14, 2015. Accepted in final form July 17, 2015.

Correspondence to Dr. Takeoka: masanori.takeoka@childrens.harvard.edu

1. Honnorat J, Didelot A, Karantoni E, et al. Autoimmune limbic encephalopathy and anti-Hu antibodies in children without cancer. *Neurology* 2013;80:2226–2232.
2. Bien CG, Granata T, Antozzi C, et al. Pathogenesis, diagnosis and treatment of Rasmussen encephalitis: a European consensus statement. *Brain* 2005;128:454–471.
3. Pittock SJ, Kryzer TJ, Lennon VA. Paraneoplastic antibodies coexist and predict cancer, not neurological syndrome. *Ann Neurol* 2004;56:715–719.

4. Shavit YB, Graus F, Probst A, Rene R, Steck AJ. Epilepsia partialis continua: a new manifestation of anti-Hu-associated paraneoplastic encephalomyelitis. *Ann Neurol* 1999;45:255–258.
5. Jacobs DA, Fung KM, Cook NM, Schalepfer WW, Goldberg HI, Stecker MM. Complex partial status epilepticus associated with anti-Hu paraneoplastic syndrome. *J Neurol Sci* 2003;213:77–82.
6. Mut M, Schiff D, Dalmau J. Paraneoplastic recurrent multifocal encephalitis presenting with epilepsy partialis continua. *J Neuro Oncol* 2005;72:63–66.
7. Cikes N, Momoi MY, Williams CL, et al. Striational autoantibodies: quantitative detection by enzyme immunoassay in myasthenia gravis, thymoma, and recipients of D-penicillamine or allogeneic bone marrow. *Mayo Clin Proc* 1988;63:474–481.