

Arthroscopic Bankart Repairs With and Without Remplissage in Recurrent Adolescent Anterior Shoulder Instability With Hill-Sachs Deformity

Jessica L. Hughes,* MD, Tracey Bastrom,[†] MS, Andrew T. Pennock,^{††} MD, and Eric W. Edmonds,^{††§} MD

Investigation performed at Rady Children's Hospital, San Diego, California, USA

Background: Recurrent shoulder dislocation after surgical intervention in adolescents with anterior instability is now understood to occur with a relatively high frequency. The remplissage procedure is successfully used in the adult population to mitigate the ability of a Hill-Sachs lesion to engage the anterior glenoid and can be used during an arthroscopic Bankart repair for anterior shoulder instability.

Purpose: To compare the clinical outcomes in adolescent patients who underwent a Bankart repair with or without remplissage for treatment of recurrent anterior shoulder instability and associated Hill-Sachs defects.

Study Design: Cohort study; Level of evidence, 3.

Methods: A retrospective review was conducted on adolescents who underwent a remplissage procedure for recurrent anterior shoulder instability from 2009 to 2017 at a single institution. Controls were identified in a cohort of patients who underwent a Bankart repair only and were matched based on age, sex, and size of Hill-Sachs lesion. All patients were then contacted to determine instability recurrence as well as to complete the shortened version of the Disabilities of the Arm, Shoulder and Hand (QuickDASH) and the Pediatric Adolescent Shoulder Score (PASS) outcome surveys.

Results: Twenty-one adolescents underwent a remplissage procedure, and 20 matched controls underwent only a Bankart procedure. A significantly higher rate of recurrence was noted in the Bankart-only patients (8/17) compared with remplissage patients (2/15) ($P = .04$). No statistical difference was found in patient-reported outcome scores between treatment groups or in range of motion measurements ($P > .05$). In a subset of patients in the remplissage group with pre- and postoperative surveys available, mean \pm SD scores for PASS (77 ± 11) and QuickDASH (19 ± 12) improved when compared with preoperative scores (PASS, 54 ± 16 ; QuickDASH, 35 ± 28), but only the PASS score was statistically improved (PASS, $P = .003$; QuickDASH, $P = .23$).

Conclusion: The addition of the remplissage procedure to a Bankart repair is a reasonable surgical option to treat a Hill-Sachs deformity in adolescents with anterior shoulder instability. The success of this additional procedure may be due to filling the Hill-Sachs defect, or perhaps it augments stability through a mechanism of posterior capsulorrhaphy. Either way, this young athletic population appears to have a lower rate of recurrence and improved patient-reported outcomes with a remplissage procedure to address the Hill-Sachs deformity.

Keywords: shoulder; instability; remplissage; Hill-Sachs; adolescent

Recurrent anterior shoulder instability is a costly and debilitating problem that has challenged orthopaedic surgeons. Recurrent dislocations lead to structural damage to the shoulder joint³⁰ as well as functional disability and reduced work capacity.²³ A Hill-Sachs lesion¹⁶ occurs in 47% of first-time shoulder dislocations and is present in up to 90% of recurrent dislocations.^{3,5,26}

Risk factors for recurrent instability following an isolated Bankart repair without addressing the humeral head injury include age, number of dislocations, size of Hill-Sachs lesion, amount of glenoid bone loss, and bipolar bone loss.^{4,19,21,27} Several procedures have been described to address the humeral head osseous deficiency, but most require an open procedure and have high complication rates.⁶ Purchase et al²² described an arthroscopic Bankart repair combined with a method of filling the humeral head defect with the infraspinatus tendon and posterior capsule (Figure 1).⁷ The remplissage (French, "to fill in") procedure during arthroscopic stabilization prevents recurrent

The Orthopaedic Journal of Sports Medicine, 6(12), 2325967118813981
DOI: 10.1177/2325967118813981
© The Author(s) 2018

This open-access article is published and distributed under the Creative Commons Attribution - NonCommercial - No Derivatives License (<http://creativecommons.org/licenses/by-nc-nd/4.0/>), which permits the noncommercial use, distribution, and reproduction of the article in any medium, provided the original author and source are credited. You may not alter, transform, or build upon this article without the permission of the Author(s). For article reuse guidelines, please visit SAGE's website at <http://www.sagepub.com/journals-permissions>.

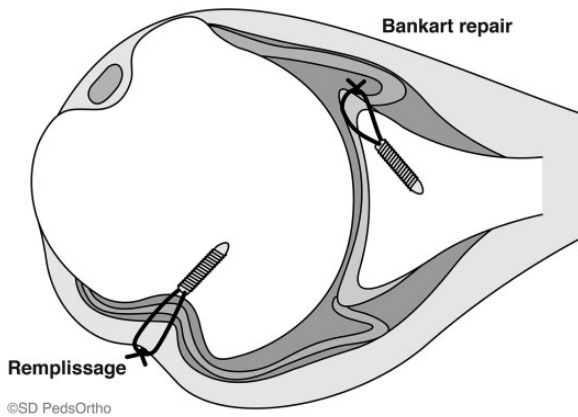


Figure 1. Illustration of an axial view of the shoulder demonstrating the remplissage procedure and Bankart-only repair. Image courtesy of SD PedsOrtho.

dislocations in 2 ways: (1) the infraspinatus tenodesis acts as a checkrein against anterior translation of the humeral head, and (2) filling in the defect with the tendon and capsule converts the Hill-Sachs lesion to an extra-articular defect, preventing it from engaging the glenoid.^{3,6,22,29}

Promising outcomes following a remplissage procedure in adult patients with large Hill-Sachs lesions without significant glenoid loss have been reported in the literature.^{3,6,8,17,22} Wolf and Arianjam²⁹ evaluated the 2- to 10-year outcomes of 45 patients after a remplissage and reported a 4.4% recurrence rate and no significant decrease in range of motion. Boileau et al³ reported a 90% return to sport after remplissage with a 10° reduction in external rotation that did not limit the patients' athletic performance. To date, insufficient literature has directly compared the outcomes between arthroscopic Bankart repairs with an arthroscopic remplissage and an isolated Bankart procedure for adolescents with recurrent anterior shoulder instability and the presence of a Hill-Sachs lesion. Therefore, the purpose of this study was to compare the outcomes in adolescents with recurrent shoulder dislocations who underwent a Bankart repair only versus a Bankart repair with remplissage procedure. Our hypothesis was that the adolescent patients undergoing remplissage would have a lower rate of recurrent instability and outcome scores that were equivalent or better than those undergoing Bankart-only repair.

METHODS

An institutional review board–approved shoulder instability database that was created by using surgical Current

Procedural Terminology codes 29806, 29807, and 23465 was retrospectively reviewed for adolescents who underwent an arthroscopic Bankart repair and remplissage procedure without any form of coracoid transfer to the glenoid from 2009 to 2017. These patients constituted the remplissage cohort. Adolescents with a prior remplissage, coracoid procedure, or multidirectional instability were excluded. Patients who had undergone a previous failed Bankart repair but then underwent revision arthroscopic Bankart repair and remplissage during the study period were included. Demographic data were recorded, including date of birth, date of first dislocation, number of dislocations, mechanism of dislocation, primary sport, and laterality of injured extremity. In addition, specific information regarding the shoulder was recorded, such as previous shoulder procedures and trials of conservative management.

All patients underwent preoperative magnetic resonance imaging (MRI) with arthrogram, and information was recorded such as extent of labral tear; presence and size of Hill-Sachs lesion on axial image²⁰; presence and amount of glenoid bone loss¹⁸; size of humeral head, glenoid,²⁴ and labrum; glenoid version¹¹; and any other associated injury or disease. Routine computed tomography scans are not performed at our institution, in an attempt to minimize both radiation exposure in this pediatric population¹ and medical costs. Additionally, MRI has been shown to be a reasonable alternative in both diagnosing and quantifying bone loss.^{14,15}

The same shoulder instability database was used to then develop a control cohort of patients with anterior shoulder instability who were matched based on age at the time of the index surgery, sex, primary sport type, radiographic size of Hill-Sachs lesion (depth and width) (Figure 2), and whether the lesion was “on-track” or “off-track”⁹ (Figure 3); the control patients had undergone arthroscopic surgery for their Bankart lesion without a remplissage. These patients constituted the Bankart-only cohort. Patients with reported multidirectional instability were excluded. A previous Bankart procedure to the affected shoulder was not an exclusion criterion, but the index procedure for the purposes of this study was selected based on the most recent procedure following the MRI that identified the presence of a Hill-Sachs lesion. The same demographic information, injury- and shoulder-specific data, and preoperative MRI findings were recorded for the Bankart-only cohort, as described above for the remplissage cohort.

All procedures were performed at a single institution by 1 of 2 orthopaedic surgeons. For both cohorts, intraoperative data were recorded such as type of procedure performed, extent of labral tear, presence of a Hill-Sachs lesion and/or glenoid bone loss, and number of suture anchors used. The number of suture anchors counted

[§]Address correspondence to Eric W. Edmonds, MD, 3020 Children's Way, MC 5062, San Diego, CA 92123, USA (email: eedmonds@rchsd.org).

*Baylor Scott and White, Temple, Texas, USA.

†Rady Children's Hospital, San Diego, California, USA.

‡University of California, San Diego, San Diego, California, USA.

One or more of the authors has declared the following potential conflict of interest or source of funding: This study was supported by the Rady Children's Hospital, San Diego Division of Orthopedics. A.T.P. has received educational support from Smith & Nephew, Arthrex, and Sportstek Medical. E.W.E. is a consultant for Orthopediatrics and is a paid speaker/presenter for Arthrex. AOSSM checks author disclosures against the Open Payments Database (OPD). AOSSM has not conducted an independent investigation on the OPD and disclaims any liability or responsibility relating thereto.

Ethical approval for this study was obtained from the University of California, San Diego, Human Research Protections Program.

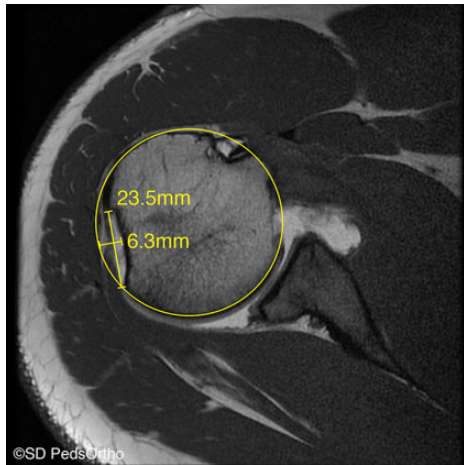


Figure 2. Axial T1-weighted magnetic resonance image of a large Hill-Sachs lesion with minimal glenoid loss that underwent a remplissage procedure. The width and depth of the Hill-Sachs lesions were measured on the axial slice, demonstrating the largest size of the lesion in the plane of the infraspinatus tendon insertion. Image courtesy of SD PedsOrtho.

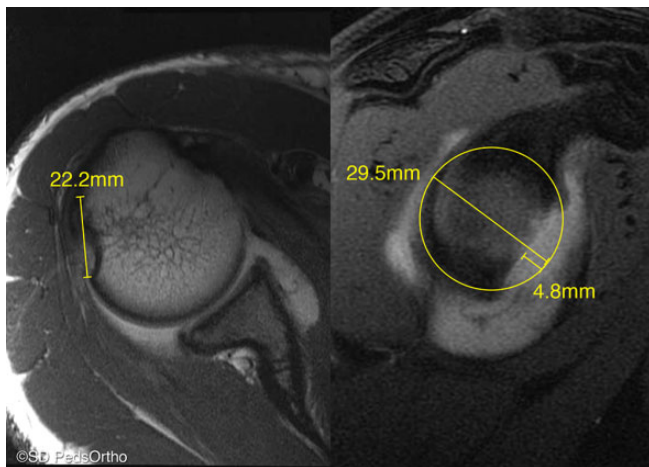


Figure 3. Measurement of “on-track” and “off-track” Hill-Sachs lesions according to Di Giacomo et al.⁹ Measurement of the Hill-Sachs track on the T1-weighted axial image (left) and measurement of the glenoid index on the T1-weighted sagittal image (right). Images courtesy of SD PedsOrtho.

included the combined total number of anchors for the Bankart and remplissage during the procedures.

All patients received general anesthesia with a regional block prior to the procedure. Patients were positioned in the lateral decubitus position on the operating table. The Bankart repairs were performed with suture anchors by use of either knotless suture anchors or square knot tying technique based on surgeon preference. The amount of tissue used in the anteroinferior plication was determined by restoring normal tension on the anterior capsule and the anteroinferior glenohumeral ligament. The remplissage

was performed by use of an accessory posterolateral portal through which 2 anchors were placed in the nadir of the Hill-Sachs deformity. In the remplissage cohort, 3 patients underwent a concomitant posterior labral repair and 2 patients underwent a superior labrum anterior and posterior (SLAP) repair. In the Bankart-only cohort, 7 patients underwent a concomitant posterior labral repair and 3 patients underwent a SLAP repair.

The postoperative protocols for both the remplissage and the Bankart-only cohorts were identical. Patients were immobilized for 2 weeks, followed by use of a sling for an additional 4 weeks. During this sling phase, the patients began performing pendulum swings only, then progressed to formal physical therapy with passive and active-assisted range of motion. Once 80% of motion was achieved (usually 6-8 weeks postoperatively), strength rehabilitation (with a focus on medial scapular stabilizers and the rotator cuff complex) was continued until more than 80% of strength and 90% of motion were achieved. The patients were not released to full activity or contact sports until after 6 months.

For both cohorts, the preoperative and the most recent postoperative clinical physical examination, including range of motion (forward flexion [FF], internal rotation [IR], and external rotation [ER]), was recorded. Patients were classified as having asymmetry of motion if they had a greater than 10° difference or more than 1 spinal segment (IR) between the preoperative and postoperative examinations. In addition, preoperative patient-reported survey scores were recorded: the Pediatric Adolescent Shoulder Score (PASS); the shortened version of the Disabilities of the Arm, Shoulder and Hand (QuickDASH) Sports Module; and the Self-Assessment Numerical Evaluation (SANE). The PASS survey consists of 13 questions that assess symptoms, limitations, need for compensatory mechanisms, and emotional distress related to shoulder dysfunction.¹⁰ Patient responses are on a 0-5 or 0-10 scale, with a score calculation normalized to the number of total possible points (100 indicates minimal impact on quality of life from shoulder dysfunction). The direction of the responses is varied to identify bias in responses by the patient. The QuickDASH is a responsive, validated, and reliable patient-oriented outcome measure for assessing upper extremity disability. A higher score means greater disability, with 100 points indicating a completely disabled extremity and 0 points indicating a “perfect” extremity.² With the SANE score, which is a validated outcome measure, the patient rates the shoulder as a percentage of normal, with 100% being normal.²⁸ The values of the same surveys were also recorded from the most recent postoperative visit.

Postoperatively, all patients were contacted by telephone and asked whether they had experienced any recurrent dislocation of the operative shoulder, defined as a true gross dislocation of the glenohumeral joint, or any subsequent surgeries on the operative extremity. Recurrence of instability was defined as any subluxation event and/or uncomfortable excessive translation of the humeral head that left the patient with a feeling of instability. Surgical failure was defined as any reported recurrent dislocation, recurrent instability, or need for another shoulder procedure. Additionally, the patients completed the PASS, QuickDASH with the DASH

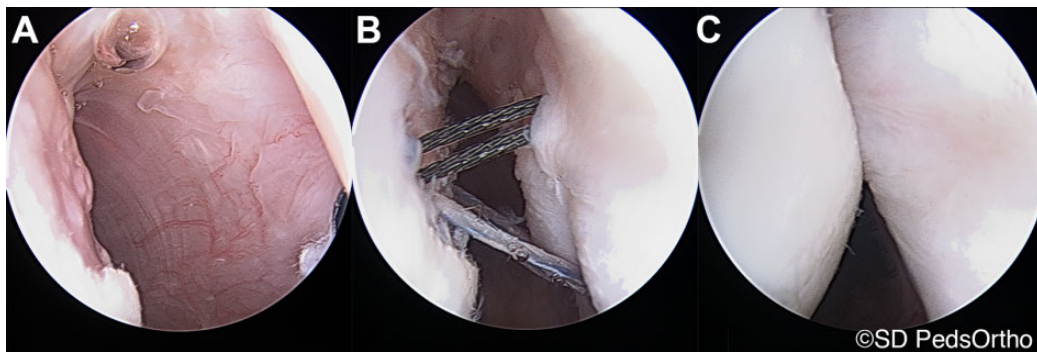


Figure 4. Intraoperative arthroscopic photographs during a remplissage procedure. (A) Appearance of the Hill-Sachs lesion during diagnostic arthroscopy. “Filling-in” of the Hill-Sachs lesion with infraspinatus tendon and posterior capsule (B) before and (C) after sutures are tied down. Images courtesy of SD PedsOrtho.

Sports module, and the SANE. Patients were also asked whether they were able to return to their primary sport.

Continuous data were compared between the two groups through use of 1-way analysis of variance. Data were checked for normality and homogeneity of variances. If either of these assumptions was violated, a nonparametric Mann-Whitney *U* test was used. Categorical variables were compared with a chi-square test or Fisher exact test. Analyses were performed with SPSS v 24 (IBM Corp), and alpha was set at $P < .05$ to declare significance.

RESULTS

Twenty-one adolescents underwent a remplissage procedure for recurrent shoulder instability with a Hill-Sachs lesion; they had a mean age of 18.2 ± 2.6 years, and the mean size of the Hill-Sachs lesion was $5.9 \pm 5.3 \times 16.1 \pm 5.7$ mm (Figure 4). The 20 matched controls in the Bankart-only cohort had a mean age of 17.7 ± 1.9 years and a mean Hill-Sachs lesion size of $4.0 \pm 1.5 \times 14.5 \pm 4.4$ mm (Table 1). The Bankart-only controls were matched by sex, with a mean age difference of 0.71 years and a mean Hill-Sachs depth difference of 1.26 mm and width difference of 1.96 mm. No patients included in this study had more than 20% glenoid bone loss.

No statistical difference was found in the sex distribution between the remplissage cohort (17 male patients, 81%) and the Bankart-only cohort (16 male patients, 80%) ($P = .939$). No significant difference was noted between the number of off-track Hill-Sachs lesions between the remplissage cohort (6/19 patients, 32%) and the Bankart-only cohort (3 patients, 15%) ($P = .273$). No significant difference was found in the mean number of suture anchors used ($P = .988$). One patient in the remplissage cohort had undergone MRI outside our facility and the results were unattainable, but radiology and intraoperative reports confirmed a Hill-Sachs lesion without reporting the size. A second remplissage patient without a matched control was 4 years older than any patient treated at this children’s hospital for a Bankart repair. This patient was not included in the comparison analysis.

TABLE 1
Patient Demographics of Remplissage and Bankart-Only Cohorts^a

	Remplissage (n = 21)	Bankart Only (n = 20)	<i>P</i>
Age, y	18.2 ± 2.6	17.7 ± 1.9	.43
Male sex	17 (81)	16 (80)	.939
≥3 prior dislocations	17 (81)	13 (65)	.294
Prior Bankart surgery	9 (43)	2 (10)	.028
Hill-Sachs depth, mm	5.9 ± 5.3	4.0 ± 1.5	.136
Hill-Sachs width, mm	16.1 ± 5.7	14.5 ± 4.4	.34
Off-track Hill-Sachs	6 (32)	3 (15)	.273 ^b

^aData are reported as n (%) or mean \pm SD. No statistical difference was found between off-track and on-track Hill-Sachs lesions and rate of recurrence within the remplissage group ($P = .11$) and the Bankart-only group ($P = .226$).

^bThis parameter could not be evaluated in 2 of the remplissage patients; thus, n = 19 for the statistical comparison in that cohort.

All patients reported preoperative dislocation requiring reduction except for 2 patients in the Bankart-only cohort who reported only subluxation with spontaneous reduction. In the remplissage cohort prior to surgery, 17 patients had ≥ 3 dislocations, 9 patients had undergone a failed prior Bankart repair, and all but 2 patients had attempted a trial of conservative treatment. In the Bankart-only cohort prior to surgery, 13 patients reported ≥ 3 dislocations, 2 patients had undergone a failed prior Bankart repair, and all but 2 patients attempted a trial of conservative treatment. For the remplissage group, the primary sport was self-identified by 5 patients as football/rugby, 4 patients as soccer, 3 patients as outdoor activities, and 1 patient each as baseball, volleyball, gymnastics, track and field, lacrosse, hockey, weight lifting, martial arts, and extreme sports. In the Bankart-only group, the primary sport was self-identified by 6 patients as football, 3 patients as baseball/softball, 2 patients as swimming, 2 patients as martial arts, and 1 patient each as gymnastics and circus performing. The remaining 5 were unknown, or no sport was reported in the records.

Recurrence

Thirty-two patients were available for the telephone interview in both treatment cohorts at a mean follow-up of 2.6 years in the remplissage cohort ($n = 15$) and 4.2 years in the Bankart-only cohort ($n = 17$) ($P = .366$). Significantly fewer recurrent dislocations were noted in the remplissage cohort ($n = 2$) compared with the Bankart-only cohort ($n = 8$) ($P = .04$). No significant difference was found between the presence of an off-track Hill-Sachs lesion with the rate of recurrence within each cohort (remplissage, $P = .11$; Bankart-only, $P = .23$). When the total number of suture anchors used per procedure was compared, no difference was found between patients who reported recurrence (5.5 ± 0.7 anchors) versus those who reported no recurrence (5.3 ± 1.6 anchors) in the remplissage cohort ($P = .653$). In the Bankart-only cohort, a trend was found toward more suture anchors used in patients who did not report recurrence (7 ± 2.8 anchors) versus those who reported recurrence (4.9 ± 1.2 anchors) ($P = .058$).

In the remplissage cohort, 2 patients with off-track Hill-Sachs lesions had recurrent shoulder dislocations and subsequently underwent a Latarjet procedure because of significant glenoid bone loss sustained after the index procedure. A third patient denied a history of recurrence but did not complete patient surveys.

In the Bankart-only cohort, 7 patients reported subsequent frank shoulder dislocation on the operative side and 4 patients underwent a secondary surgery (revision Bankart or remplissage). An eighth patient complained of her shoulder “slipping out of place” but without evidence of frank dislocation. Her treatment was defined as a failure for our analysis.

Range of Motion

Because of the retrospective nature of the cohort, range of motion data were not available for all patients. No significant difference was found between the cohorts in comparisons of postoperative FF, ER, and IR ($P = .99$, .303, and .99, respectively) (Table 2). In the remplissage cohort at a mean follow-up visit of 5.5 months, 6 patients (42.9%) had FF asymmetry, 8 patients (57.1%) had ER asymmetry, and 7 patients (58.3%) had IR asymmetry. In the Bankart-only cohort at a mean follow-up visit of 2.9 months, 3 patients (42.9%) had FF asymmetry, 1 patient (20%) had ER asymmetry, and 3 patients (50%) had IR asymmetry. One question within the PASS survey asked, “How well can you move your shoulder?” (A score of 10 indicates ability to move without difficulty.) The average score for the remplissage group was 9 and for the Bankart-only group, 8.9 ($P = .79$).

Patient Surveys

A limited number of remplissage patients had both preoperative and postoperative surveys available ($n = 7$ for PASS, $n = 6$ for QuickDASH). When patients in the remplissage cohort were evaluated on preoperative versus postoperative scores, all patients demonstrated

TABLE 2
Remplissage Versus Bankart-Only
Outcome Comparison ($n = 32$ Patients)^a

	Remplissage	Bankart Only	<i>P</i>
Recurrent dislocation ^b	13.3 (2/15)	47.1 (8/17)	.04
Need for second surgery	13.3 (2/15)	25 (4/16)	.206
Postoperative forward flexion asymmetry ^c	42.9 (6/14)	42.9 (3/7)	.99
Postoperative external rotation asymmetry ^c	57.1 (8/14)	20 (1/5)	.303
Postoperative internal rotation asymmetry ^d	58.3 (7/12)	50 (3/6)	.99
Time to follow-up surveys, y	2.7 ± 1.4 ($n = 14$)	3.8 ± 3.1 ($n = 14$)	.231
PASS	76.2 ± 22 ($n = 14$)	74.4 ± 16 ($n = 10$)	.827
QuickDASH	17.2 ± 15.6 ($n = 14$)	12.1 ± 18.3 ($n = 14$)	.434
SANE score	79 ± 21.9 ($n = 14$)	76 ± 18.4 ($n = 14$)	.62

^aData are reported as % (n/N) or mean ± SD. Range of motion data are from the final follow-up visit available in the medical record; given the retrospective nature of the study, data were not available for all patients. PASS, Pediatric Adolescent Shoulder Score; QuickDASH, shortened version of the Disabilities of the Arm, Shoulder and Hand measure; SANE, Self-Assessment Numerical Evaluation.

^bDislocation was defined as dislocation of the glenohumeral joint with the need for reduction.

^cAsymmetry for forward flexion and external rotation was defined as $>10^\circ$ difference compared with the contralateral side.

^dAsymmetry for internal rotation as defined was >1 spinal level difference compared with the contralateral.

improvement in both the PASS and QuickDASH scores, however only the PASS demonstrated a significant difference between preoperative and postoperative scores (53.6 vs 76.6, $P = .003$). The mean postoperative QuickDASH score improved to 18.9 ± 11.6 from the preoperative 35.2 ± 27.5 ($P = .23$). The Bankart-only cohort did not have enough available preoperative surveys to analyze purposely.

When the 32 patients with follow-up data were evaluated, no significant difference was found in patient outcome surveys (PASS, QuickDASH, and SANE) between the remplissage and Bankart-only cohorts at a mean follow-up of 2.7 years and 3.8 years, respectively ($P = .231$) (Table 2). Of the 15 patients in the remplissage cohort who were reached, 9 patients reported returning to their primary sport, 2 patients reported that they chose to not return to their sport, and 4 patients said they had not returned to their sport. Of the 17 patients in the Bankart-only group who were reached, 8 patients had returned to their primary sport, 4 patients were unable to return to their sport, and 5 patients lacked this data point.

DISCUSSION

Prior literature has demonstrated that a history of multiple dislocations is an important predictor of poor outcomes following arthroscopic stabilization procedures.^{13,25,27} The results from this study demonstrate that an arthroscopic remplissage procedure is an effective surgical option for adolescents with recurrent anterior shoulder dislocations and a Hill-Sachs lesion without significant glenoid loss. These results are comparable with the current published literature in adult patients. A similar article by Garcia et al¹² exhibited significantly different recurrence rates between groups after remplissage (2/21, or 9%) and Bankart (7/19, or 36%) at an average follow-up of 40.7 months and 31.6 months, respectively. Both the current study and the study by Garcia et al¹² demonstrated improved outcome scores and decreased rate of recurrence in the remplissage group when compared with the Bankart-only cohort. A systematic review of arthroscopic remplissage for Hill-Sachs demonstrated a 5.4% recurrence rate (9/167 patients).⁶ The recurrence rate in the present study was similar to that observed by Garcia et al¹² and only slightly higher than other studies looking at the high-risk adolescent population.⁶ The recurrence rates in both the current and the Garcia et al¹² studies were significantly less than the rates in their respective Bankart-only cohorts.

The 2 patients in whom the remplissage procedure failed and who subsequently underwent a Latarjet procedure had known glenoid bone loss (16% and 18%). While multiple authors have attempted to identify a “critical” bone loss threshold that predisposes to arthroscopic stabilization failure, this value remains controversial in the adult population and is even more poorly understood in the pediatric population. Some authors have suggested a threshold of 20% to 25%, but more recent data suggest that bone loss greater than 13.5% in higher level athletes will lead to worse patient-reported outcomes regardless of recurrence of instability.²⁵ Based on our limited data, it appears that this lower percentage loss may indeed be a higher risk of subsequent instability, but multiple factors can play a role in the ultimate outcome. For example, a biomechanical study by Arciero et al¹ demonstrated the importance of considering the combined humeral and glenoid osseous defects when shoulder instability recurs and the probability of Bankart failure with both defects is high. Therefore, our study supports this same idea that a remplissage and Bankart repair is less effective in the presence of significant glenoid loss (bipolar lesions), but the amount of bone loss that can be considered significant remains to be determined.

The remplissage procedure is a nonanatomic tenodesis of the infraspinatus tendon and posterior capsule to “fill in” the humeral head defect. As mentioned previously, the patients who typically undergo a remplissage procedure are young, active males. Thus, postoperative range of motion (particularly ER and IR) and strength are a concern for these patients to return to athletics. A study by Deutsch and Kroll⁸ found a significant decrease in ER in 1 patient (decrease of 30° of ER from the preoperative value). This patient required a subsequent surgical release.⁸ Wolf and

Arianjam²⁹ reported their 2- to 10-year follow-up data after arthroscopic remplissage and demonstrated no significant decrease in range of motion in any plane. The decreased range of motion in the remplissage cohort in the current study was found early in follow-up and did not appear to negatively affect the patients’ perceived motion, based on the results of the patient surveys. In addition, no significant difference was found in postoperative range of motion between the remplissage and Bankart-only cohorts. The present study did not demonstrate any significant difference in the amount of final range of motion asymmetry between patients having undergone remplissage repair or a Bankart repair alone.

This study has several limitations, including lack of randomization and the retrospective method. Even though the current data did not indicate a significant difference in the number of suture anchors used between the 2 surgical cohorts, one might speculate a difference in the character and size of the Bankart lesions (larger in the Bankart-only group) given that the same number of anchors was used to complete both types of surgery. The study results are limited by the small sample size, and a larger cohort is needed to determine significant correlations regarding outcomes; however, the significant difference in recurrence rate indicates that the type II error (power) was acceptable for this variable. The patients who have these injuries and procedures are a mobile population, which limits long-term clinical examination follow-up. The current study had limited preoperative patient-reported surveys, and it was difficult to objectively compare preoperative and postoperative patient-reported outcomes in both treatment cohorts. Furthermore, duration of follow-up differed between the groups, even though it was not statistically significant, and slightly more posterior injury was seen in the Bankart-only cohort.

In conclusion, the addition of a remplissage procedure (when compared with an isolated Bankart repair) is an effective surgical option for adolescents with recurrent anterior shoulder instability and a Hill-Sachs lesion without significant glenoid loss. However, the addition of a remplissage procedure does not reliably prevent recurrence if glenoid bone loss is present, creating a bipolar lesion. Further studies are encouraged to examine longer follow-up times and outcomes as surgical technique and technology evolve. Yet, it is safe to conclude that outcomes are improved in adolescent patients treated with a combination of remplissage and Bankart repair for their recurrent anterior instability.

ACKNOWLEDGMENT

The authors thank James Bomar, MPH, for preparing the figures for this manuscript.

REFERENCES

1. Arciero RA, Parrino A, Bernhardtson AS, et al. The effect of a combined glenoid and Hill-Sachs defect on glenohumeral stability: a biomechanical cadaveric study using 3-dimensional modeling of 142 patients. *Am J Sports Med.* 2015;43(6):1422-1429.
2. Atroshi I, Gummesson C, Andersson B, Dahlgren E, Johansson A. The disabilities of the arm, shoulder and hand (DASH) outcome

- questionnaire: reliability and validity of the Swedish version evaluated in 176 patients. *Acta Orthop Scand*. 2000;71(6):613-618.
3. Boileau P, O'Shea K, Vargas P, Pinedo M, Old J, Zumstein M. Anatomical and functional results after arthroscopic Hill-Sachs remplissage. *J Bone Joint Surg Am*. 2012;94(7):618-626.
 4. Boileau P, Villalba M, Héry J-Y, Balg F, Ahrens P, Neyton L. Risk factors for recurrence of shoulder instability after arthroscopic Bankart repair. *J Bone Joint Surg Am*. 2006;88(8):1755-1763.
 5. Burkhart SS, De Beer JF. Traumatic glenohumeral bone defects and their relationship to failure of arthroscopic Bankart repairs: significance of the inverted-pear glenoid and the humeral engaging Hill-Sachs lesion. *Arthroscopy*. 2000;16(7):677-694.
 6. Buza JA III, Iyengar JJ, Anakwenze OA, Ahmad CS, Levine WN. Arthroscopic Hill-Sachs remplissage: a systematic review. *J Bone Joint Surg Am*. 2014;96(7):549-555.
 7. Connolly J. Humeral head defects associated with shoulder dislocations: their diagnostic and surgical significance. *Am Acad Orthop Surg Instr Course Lect*. 1972;21:42-54.
 8. Deutsch AA, Kroll DG. Decreased range of motion following arthroscopic remplissage. *Orthopedics*. 2008;31(5):492.
 9. Di Giacomo G, Itoi E, Burkhart SS. Evolving concept of bipolar bone loss and the Hill-Sachs lesion: from "engaging/non-engaging" lesion to "on-track/off-track" lesion. *Arthroscopy*. 2014;30(1):90-98.
 10. Edmonds EW, Bastrom TP, Roocroft JH, Calandra-Young VA, Pennock AT. The Pediatric/Adolescent Shoulder Survey (PASS): a reliable youth questionnaire with discriminant validity and responsiveness to change. *Orthop J Sports Med*. 2017;5(3):2325967117698466.
 11. Friedman RJ, Black J, Galante JO, Jacobs JJ, Skinner HB. Current concepts in orthopaedic biomaterials and implant fixation. *Instr Course Lect*. 1994;43:233-255.
 12. Garcia GH, Park MJ, Zhang C, Kelly JD, Huffman GR. Large Hill-Sachs lesion: a comparative study of patients treated with arthroscopic Bankart repair with or without remplissage. *HSS J*. 2015;11(2):98-103.
 13. Gasparini G, De Benedetto M, Cundari A, et al. Predictors of functional outcomes and recurrent shoulder instability after arthroscopic anterior stabilization. *Knee Surg Sports Traumatol Arthrosc*. 2016;24(2):406-413.
 14. Gyftopoulos S, Beltran LS, Bookman J, Rokito A. MRI evaluation of bipolar bone loss using the on-track off-track method: a feasibility study. *AJR Am J Roentgenol*. 2015;205(4):848-852.
 15. Gyftopoulos S, Hasan S, Bencardino J, et al. Diagnostic accuracy of MRI in the measurement of glenoid bone loss. *AJR Am J Roentgenol*. 2012;199(4):873-878.
 16. Hill HA, Sachs MD. The grooved defect of the humeral head. *Radiology*. 1940;35(6):690-700.
 17. Ladermann A, Arrigoni P, Barth J, et al. Is arthroscopic remplissage a tenodesis or capsulomyodesis? An anatomic study. *Knee Surg Sports Traumatol Arthrosc*. 2016;24(2):573-577.
 18. McNeil JW, Beaulieu-Jones BR, Bernhardson AS, et al. Classification and analysis of attritional glenoid bone loss in recurrent anterior shoulder instability. *Am J Sports Med*. 2017;45(4):767-774.
 19. Olds M, Donaldson K, Ellis R, Kersten P. In children 18 years and under, what promotes recurrent shoulder instability after traumatic anterior shoulder dislocation? A systematic review and meta-analysis of risk factors. *Br J Sports Med*. 2016;50(18):1135-1141.
 20. Park MJ, Tjoumakaris FP, Garcia G, Patel A, Kelly JD. Arthroscopic remplissage with Bankart repair for the treatment of glenohumeral instability with Hill-Sachs defects. *Arthroscopy*. 2011;27(9):1187-1194.
 21. Provencher MT, Frank RM, LeClere LE, et al. The Hill-Sachs lesion: diagnosis, classification, and management. *J Am Acad Orthop Surg*. 2012;20(4):242-252.
 22. Purchase RJ, Wolf EM, Hobgood ER, Pollock ME, Smalley CC. Hill-Sachs "remplissage": an arthroscopic solution for the engaging Hill-Sachs lesion. *Arthroscopy*. 2008;24(6):723-726.
 23. Robinson CM, Howes J, Murdoch H, Will E, Graham C. Functional outcome and risk of recurrent instability after primary traumatic anterior shoulder dislocation in young patients. *J Bone Joint Surg Am*. 2006;88(11):2326-2336.
 24. Saliken DJ, Bornes TD, Bouliane MJ, Sheps DM, Beaupre LA. Imaging methods for quantifying glenoid and Hill-Sachs bone loss in traumatic instability of the shoulder: a scoping review. *BMC Musculoskelet Disord*. 2015;16:164.
 25. Shaha JS, Cook JB, Song DJ, et al. Redefining "critical" bone loss in shoulder instability: functional outcomes worsen with "subcritical" bone loss. *Am J Sports Med*. 2015;43(7):1719-1725.
 26. Spatschil A, Landsiedl F, Anderl W, et al. Posttraumatic anterior-inferior instability of the shoulder: arthroscopic findings and clinical correlations. *Arch Orthop Trauma Surg*. 2006;126(4):217-222.
 27. Wasserstein D, Dwyer T, Veillette C, et al. Predictors of dislocation and revision after shoulder stabilization in Ontario, Canada, from 2003 to 2008. *Am J Sports Med*. 2013;41(9):2034-2040.
 28. Williams GN, Gangel TJ, Arciero RA, Uhorchak JM, Taylor DC. Comparison of the Single Assessment Numeric Evaluation method and two shoulder rating scales: outcomes measures after shoulder surgery. *Am J Sports Med*. 1999;27(2):214-221.
 29. Wolf EM, Arianjam A. Hill-Sachs remplissage, an arthroscopic solution for the engaging Hill-Sachs lesion: 2- to 10-year follow-up and incidence of recurrence. *J Shoulder Elbow Surg*. 2014;23(6):814-820.
 30. Yiannakopoulos CK, Mataragas E, Antonogiannakis E. A comparison of the spectrum of intra-articular lesions in acute and chronic anterior shoulder instability. *Arthroscopy*. 2007;23(9):985-990.