Internal Medicine
The Japanese Society of Internal Medicine

doi: 10.2169/internalmedicine.7635-21
Intern Med 61: 1415-1422, 2022
http://internmed.jp

【 CASE REPORT 】

An Autopsy Confirmed Neuromyelitis Optica Spectrum Disorder with Extensive Brain White Matter Lesion and Optic Neuritis but Intact Spinal Cord, Clinically Mimicking a Secondary Progressive Multiple Sclerosis-like Course

Fumika Azuma[1], Kazuya Nokura[1], Tetsuharu Kako[1], Mari Yoshida[2] and Shinsui Tatsumi[3]

Abstract:
A 57-year-old woman presented with optic neuritis with repeated clinical symptoms of focal demyelination of the cerebral white matter and brain stem for 14 years. At the end of the patient's course, the clinical signs mimicked secondary progressive multiple sclerosis, but whether it was caused by interferon administration or neuromyelitis optica spectrum disorders (NMOSD) - or a combination of both or others - was unclear. Histopathological findings indicated the etiology to be NMOSD, with no apparent plaque in spinal cord specimens. This case suggests that an accurate clinical diagnosis requires serum anti-aquaporin 4 antibody measurements as well as an autopsy examination.

Key words: neuromyelitis optica (NMO), NMO spectrum disorder (NMOSD), multiple sclerosis (MS), anti-aquaporin 4 antibody (NMO-IgG), optic-brain/brainstem type, autopsy examination

(Intern Med 61: 1415-1422, 2022)
(DOI: 10.2169/internalmedicine.7635-21)

Introduction

Neuromyelitis optica (NMO), also known as Devic's disease, is an inflammatory disease of the central nervous system characterized by severe optic neuritis and transverse myelitis (1, 2). NMO and optic-spinal multiple sclerosis are NMO spectrum disorders (NMOSD) and can be distinguished from multiple sclerosis (MS) by the serum autoantibody marker NMO-IgG/anti-aquaporin 4 antibody (AQP4-IgG) (3). The recognition of variable distributions of NMO lesions outside the spinal cord and optic nerves has promoted the concept of NMOSD (4, 5). Recently, the specificity of AQP4-IgG for making an NMO diagnosis has facilitated observations that further broadened the clinical and neuroimaging spectrum of NMO. The International Panel for NMO Diagnosis released an updated set of guidelines for diagnosing NMO and NMOSD in 2015. These disorders are now known as NMOSD (6).

Initially, NMOSD had been considered mild or with low numbers of cerebral lesions. NMOSD is relatively frequent in Asia (7, 8). Characteristic images are described regularly, but progressive and extensive lesions of the brain are not well described in NMOSD. However, there have been some recent reports of progressive white-matter lesions in NMOSD (9-11).

The present patient showed optic neuritis as the initial symptom after 50 years old. Nine years after the initial symptom, the patient showed exacerbation of clinical symptoms without remission, with lesions mainly in the cerebral white matter and brain stem during the total course of 14 years. There was no evidence of spinal cord symptoms. Thus, we suspected that the patient had secondary progressive MS and did not measure AQP4-IgG. Nevertheless, this case was pathologically diagnosed as NMOSD after an autopsy. In NMOSD, the secondary progressive type is thought to be extremely rare. Therefore, this case is an extremely valuable case diagnosed as NMOSD by a histopathological examination, although this diagnosis was unable to be deduced from the clinical course.

[1]Department of Neurology, Fujita Health University Bantane Hospital, Japan, [2]Aichi Medical University, Institute for Medical Science of Aging, Japan and [3]Department of Neurology, Yao Tokushukai General Hospital, Japan
Received: March 28, 2021; Accepted: August 19, 2021; Advance Publication by J-STAGE: October 12, 2021
Correspondence to Dr. Fumika Azuma, fazuma@fujita-hu.ac.jp

Case Report

A 57-year-old woman with no specific medical history or a family history of neurological illness visited the Department of Ophthalmology because of decreased visual acuity in her left eye. An ophthalmologist diagnosed her with optic neuritis. She received intravenous methylprednisolone (1,000 mg/day for 2 days) and a retrobulbar injection of dexamethasone (80 mg/day for 5 days). A month after starting the treatment, her symptoms subsided.

At 60 years of age (X+3 years), she presented with symptoms of left hemiparesis, including the face, when she visited the Department of Neurology. Computed tomography of the head showed a low-density area at the right internal capsule. She was treated as a patient with ischemic stroke. After this episode, the patient again experienced visual deterioration in her left eye, and she was hospitalized in the ophthalmology department. She was prescribed oral steroids for two months and completely recovered.

At 63 years old (X+6 years), she presented with hemiparalysis on the right side and facial paralysis on the left side. Magnetic resonance imaging (MRI) of the head revealed multiple lesions in her right superior cerebellar peduncle and middle cerebellar peduncle. A diagnosis of MS was made, and we administered steroid pulse therapy, upon which she almost completely recovered. Data on oligoclonal bands and myelin basic protein in the cerebrospinal fluid were not available, but her serum was positive for both anti-SS-A antibody 70.4 (<20) and anti-SS-B antibody 26.8 (<20) without sicca syndrome. Mizoribine was administered for 6 months. However, she had to discontinue treatment due to hepatic dysfunction.

At 67 years of age (X+10 years), she presented with gait disturbance, nystagmus, and left-sided ataxia. At this time, we found a lesion in the cerebellar peduncle. After steroid pulse therapy, β-interferon therapy was initiated. However, even after starting the treatment, her symptoms remained, and she showed gradual deterioration in her activities of daily living (ADL).

At 68 years old (X+11 years), she became susceptible to falling and presented with symptoms of incontinence and cognitive impairment. MRI of the head showed new lesions, including in the right parietal subcortical region and lateral geniculate body. Although steroid pulse therapy was performed, walking difficulties remained, and cognitive impairment progressed.

At 69 years old (X+12 years), she again showed signs of decreasing left visual acuity and received steroid pulse therapy. However, she failed to regain visual acuity and was declared completely blind. During that time, she had another fall and suffered a right femoral and thoracolumbar vertebral fracture. During the course, she had been administered an average steroid dose of 2.5-20 mg/day, but her osteoporosis required reducing these doses. We started to administer tacrolimus hydrate 3 mg/day, to no effect.

At this time, head magnetic resonance T2-weighted and fluid-attenuated inversion recovery (FLAIR) imaging revealed small multiple irregular plaques in her pons and periventricular white matter in which plaques tended to fuse. The new lesion found in the diffusion-weighted image presented with a vague high intensity with an irregular margin (Fig. 1a). The lesions were not enhanced with gadolinium.

At 70 years old (X+13 years), the patient became bedridden and underwent endoscopic gastrostomy because of dysphagia. While β-interferon was considered ineffective, instead exacerbating the symptoms, it had been continued for over three years. MRI of the head showed progression of cerebral atrophy and ventricular dilatation (Fig. 1b). The corpus callosum showed a high intensity and thinning.

At 71 years old (X+14 years), a chest roentgenogram revealed right pleural effusion. A cytological test revealed adenocarcinoma from the effusion. After one month, she died at 71 years old, 14 years after the onset of the disease.

She had experienced no episodes of spinal cord symptoms for 14 years. MRI of the whole spinal cord revealed no abnormal findings at 69 years old. She also did not have Sjögren's syndrome (SjS). Unfortunately, AQP4-IgG had not been measured. The clinical course is shown in Fig. 2. After X+9 years, there was no remission period, and she showed a gradual decline in her ADL and spontaneity, progressive cognitive symptoms, and dysphagia.

An autopsy was performed three hours after the patient's death with the family's informed consent. General pathology revealed pancreatic adenocarcinoma and its metastasis to the thorax.

The central nervous system obtained at the autopsy was fixed with 10% formalin, embedded in paraffin blocks, and sectioned at a thickness of 4-6 μm. Spinal cord specimens were cut in every spinal cord segment. The specimens were stained using hematoxylin and eosin (HE), Klüver-Barrera (KB), and Bodian methods. Immunohistochemical staining was performed on formalin-fixed and paraffin-embedded sections. The primary antibodies used in this study are listed in Table.

After formalin fixation, the brain weighed 1,020 g. Macroscopically, the corpus callosum was atrophied, and diffuse white-matter lesions were present around the lateral ventricle (Fig. 3a, b). No lesions were found in the cerebral cortex. The optic nerve showed severe atrophy (Fig. 3c), and the pons showed signs of moderate atrophy. Cavitated lesions were noted on the cut surface of the pons (Fig. 3d). There were no lesions in the spinal cord segments (Fig. 3e).

Microscopically, multifocal irregular-shaped lesions were found in the cerebral white matter, corpus callosum, and brain stem using KB staining. However, no lesions were found in the cerebral cortex or surround the third and fourth ventricles (Fig. 4a-f). KB staining and myelin basic protein immunostaining labeled the lesions only weakly, but neurofilament immunostaining labeled the lesions strongly. No obvious lesions were observed in any spinal cord section (Fig. 4g-i). AQP4 immunoreactivity was severely decreased

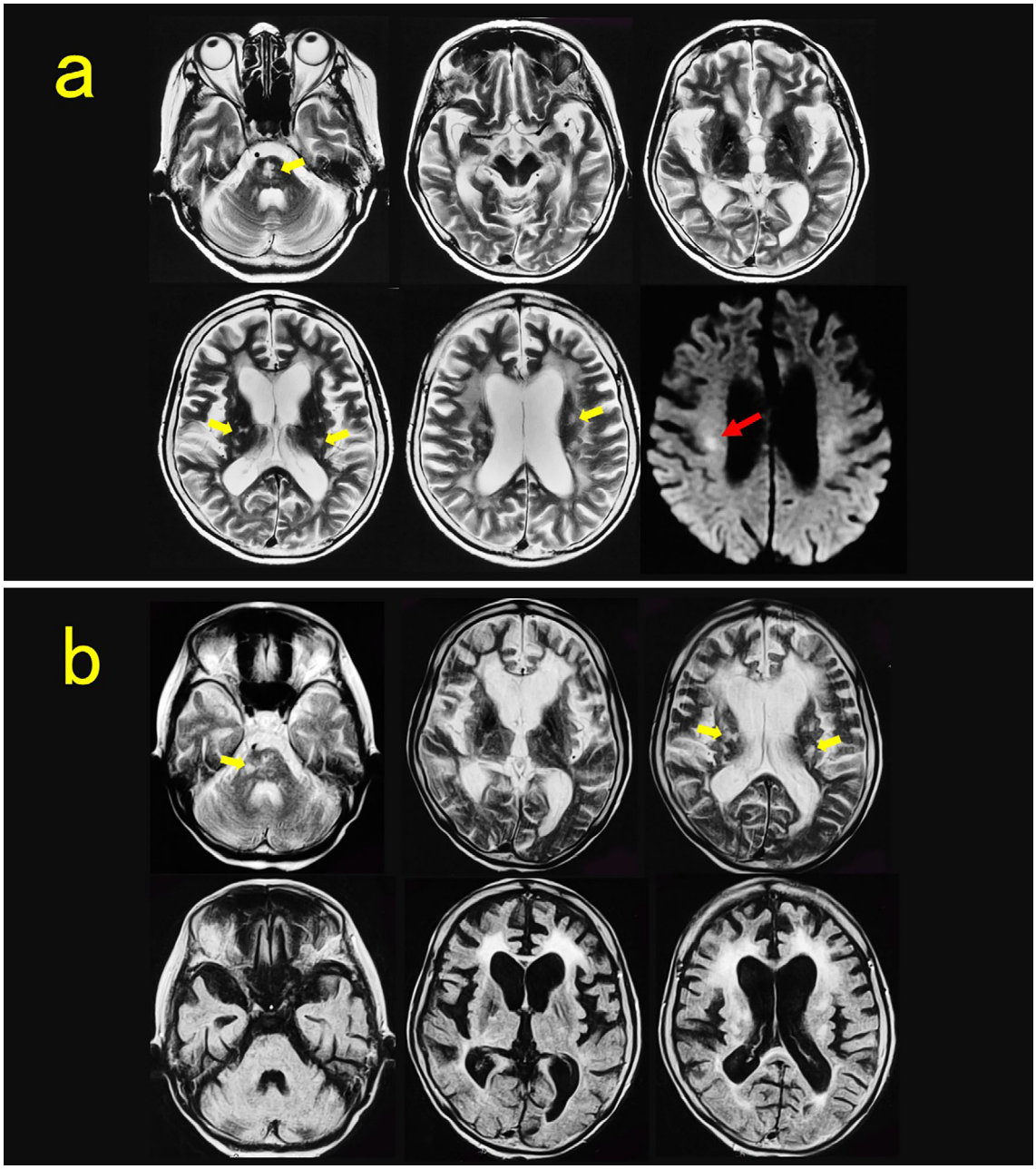

Figure 1. MRI of the head. (a) At 69 years old. Small multiple irregular plaques were found in the pons and periventricular area (T2 and DWI) (yellow arrow). A new lesion was also found on DWI (red arrow). (b) At 70 years old. Progressed white matter lesions accompanied by cerebral atrophy and ventricular dilatation were shown (T2 and FLAIR) (yellow arrow).

in the cystic lesion (Fig. 5). There were severe cystic destructive lesions in the optic nerve (Fig. 6). Many of the demyelinated lesions were obsolete plaques with necrosis or porosity. In these lesions, no AQP4 labeling was found in the perivascular spaces. Multiple irregular cystic plaques in the corpus callosum and periventricular white matter and irregular demyelinating lesions on the same slice were identified by myelin staining. Immunohistochemistry studies revealed no AQP4 labeling in the lesion.

Discussion

The main characteristics of this case were as follows: first, we found extensive white matter lesions and severe optic neuritis but no spinal cord lesion; second, the patient's serum was positive for anti-Sjögren's syndrome antibodies; third, the use of β-interferon was not effective but instead harmful; and fourth, clinically, a secondary progressive MS was diagnosed after X+9 years.

At the initial stage, we diagnosed the patient with relapsing and remitting-type conventional MS (12). However, at nine years after her initial symptoms manifested, there had been no remission period, and the gradual decline in her ADL and spontaneity, progressive cognitive symptoms, and dysphagia due to pseudobulbar palsy seemed to instead mimic secondary progressive MS (13, 14). This was mainly

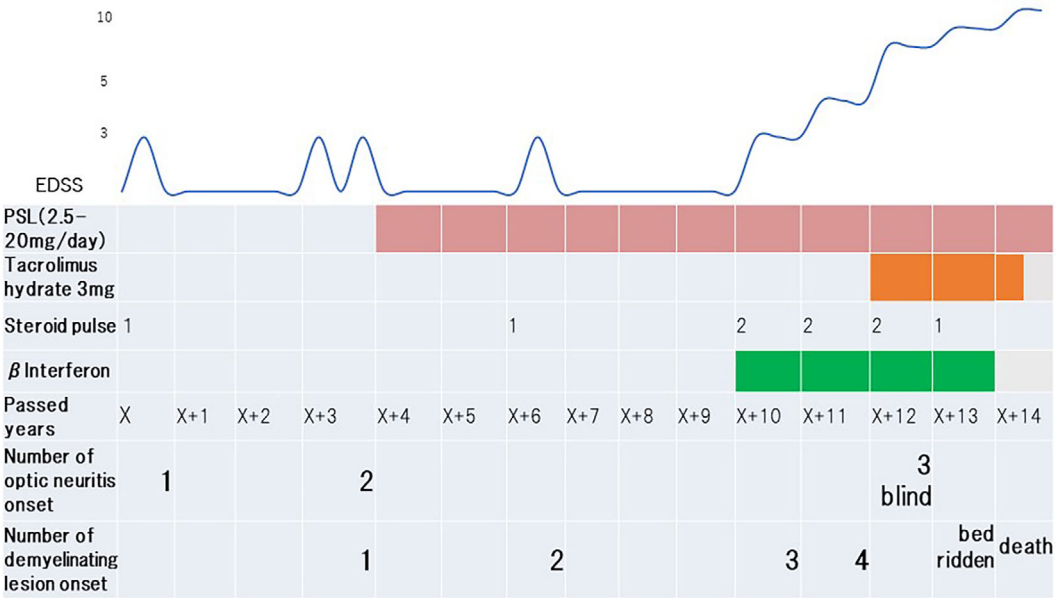

Figure 2. **Clinical course.**

Table. **List of the Antibodies Used for Immunohistochemistry.**

Antibody	Source	Category	Dilution
GFAP (glial fibrillary acidic protein)	Dako	Mouse monoclonal	400
MBP (myelin basic protein)	Dako	Rabbit polyclonal	1,000
AQP (aquaporin)	Sigma Aldrich	Mouse monoclona	800

because she had repeated optic neuritis and clinical symptoms of demyelination of the cerebral white matter and had never presented with spinal cord symptoms. The red flags for MS (15) applicable in this case included “no spinal cord lesions” and “onset of the disease after 50 years old”. The patient’s serum was positive for anti-SS-A/B, but she did not have sicca syndrome. The MRI findings indicated indistinct lesion margins, which was also a red flag for MS (16).

Recently, AQP4-IgG positive cases without optic nerve lesions or distinctive spinal cord lesions have been reported. Tanaka et al. reported that about 10% of patients with NMOSD initially developed a cerebral or brain stem lesion (17). Another study on 106 NMO-IgG-positive cases in England and Japan reported that after phenotype analyses, the brain and optic neuritis type accounted for 8% in England and 13% in Japan (18). Of 14 consecutive autopsy cases diagnosed with NMOSD at Aichi Medical University from 1980 to 2013, there was only 1 case (the present case) without lesions in the spinal cord. Similarly, among the nine patients diagnosed with MS, there was one case where there was no spinal cord lesion (19). Therefore, the presentation in our case is thought to be part of a range of NMOSD presentations.

On analyzing the MRI scans of 60 patients with NMO, 36 (60%) showed evidence of brain abnormalities. Six of these patients had MS-like lesions. Diencephalic, brain stem, or cerebral hemispheric lesions were observed in 5 of these patients (8%), mostly in children, which is distinctly atypical for MS (20). Another study suggested that 8 out of 120 patients had recurring and distinctive MRI abnormalities in the hypothalamic and periventricular areas (21). Li et al. reported that, in an MRI analysis of Chinese patients with NMO, 66.7% presented with well-defined brain parenchymal lesions, 18.2% with macroscopic symmetrical diffuse hyperintensities in deep white matter, and 15.1% with no brain lesion at all (7). These lesions, apparent on MRI, predominantly involve the hypothalamus and occasionally extend to the brain stem areas that surround the third and fourth ventricles. The corpus callosum is also sometimes affected. The distribution of the characteristics of NMO brain lesions mirrors the periventricular and hypothalamic localization of AQP4 (22). Therefore, it might be helpful to differentiate the diagnosis from MS based on the imaging findings of the brain using MRI. Interestingly, the case reported here did not show the typical distribution of NMOSD lesions, such as in the hypothalamus or tegmentum of the brain stem.

There is a case report of SjS showing only brain lesions without optic neuritis or myelitis with positive NMO-IgG findings (23). In addition, there is a report of 49 patients with coexisting SjS and NMOSD. Thirty-two out of 37 patients in whom NMO-IgG was measured were positive, 4 were negative, and 1 patient was borderline (24). In another report in China, serum AQP4-antibodies were detected in

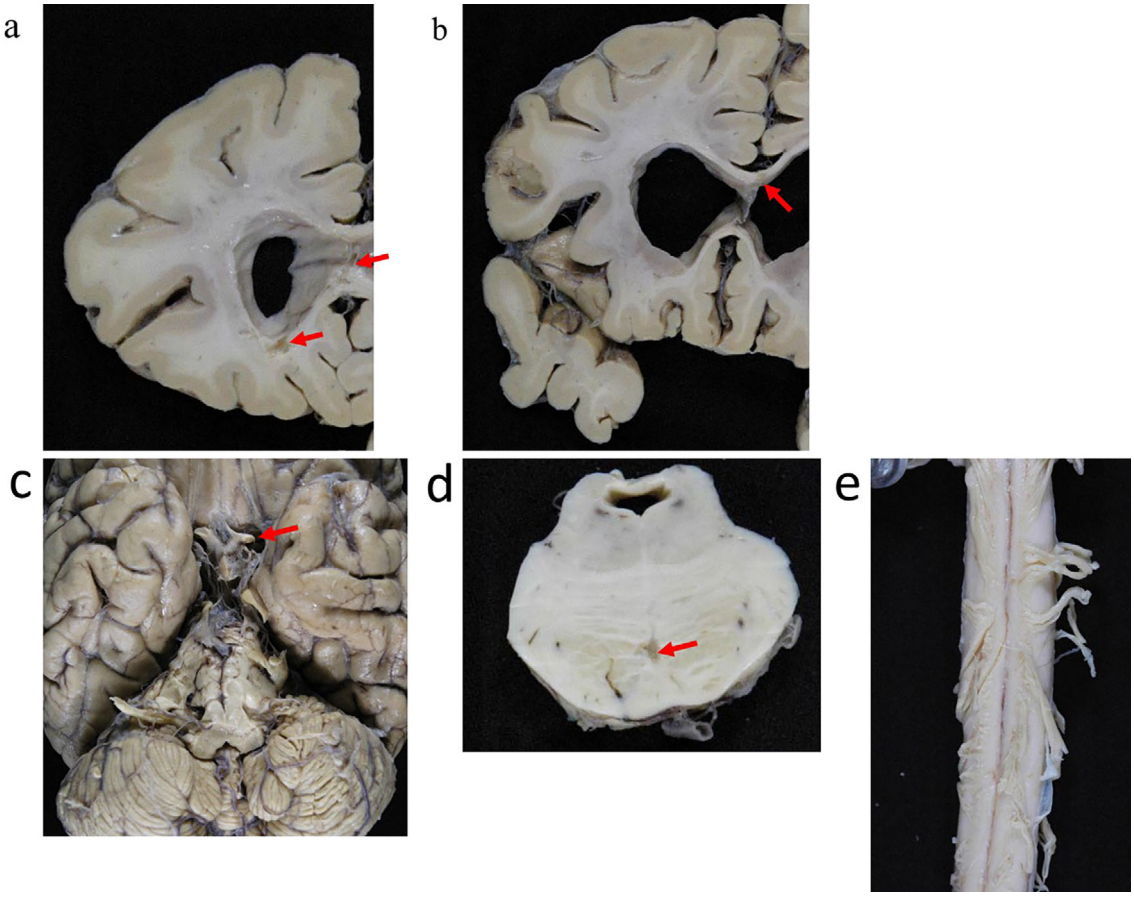

Figure 3. Macroscopic findings. (a, b) The corpus callosum was atrophied, and diffuse white matter lesions were present around the lateral ventricle (arrow). (c) The optic nerve displayed severe atrophy. (d) The pons showed moderate atrophy and cavitated lesions. (e) The spinal cord findings were unremarkable.

89.3% of patients who were diagnosed with primary SjS with NMOSD (25). The reason for the high positive rate of antibody against SjS in NMOSD patients should be elucidated in future studies. Nevertheless, the presence of anti-SjS antibodies might help diagnose NMOSD. NMOSD should be considered in the early stage of the disease, when anti-SjS antibodies are detected.

IFN-β treatment may not be effective in NMO. Previous studies reported that both patients with NMO and MS with long spinal cord lesion (LSCL) had a poor response to IFN-β treatment. Furthermore, patients with NMO had a worse response to IFN-β treatment than patients with MS with LSCL (26). The patient described in the present case had no spinal cord lesion despite having been administered INF-β for over three years. However, we hypothesize that the cerebral lesions were exacerbated by INF-β. Since the administration of INF-β and progression of the clinical course, similar to that for secondary progressive type, occurred at the same time, whether or not INF-β actually affected the progression of symptoms remains unclear.

Histopathologically, the lesions showed multiple irregularly shaped areas of softening in NMOSD. This is substantially different from the sharp margin associated with MS plaques. As a pathological characteristic, severe cystic destructive lesions are found in NMOSD, but MS lesions tend to be milder and fewer in number (19). The AQP4 and glial fibrillary acidic protein (GFAP) expression is decreased in NMOSD lesions. The characteristic pathological change in our case was that the lesions had an irregular margin, showed strong necrosis and softening, occurred along the blood vessel with hyaline degeneration of the vessels, and had negative AQP4 immunostaining. These findings are consistent with the histopathological findings of AQP4-positive NMOSD (27). The plaques were all obsolete lesions, so we did not further examine the deposition of immunoglobulins and complements in this case. Thus, a comparative analysis of the acute pathologic patterns of NMOSD is important. Our case was compatible with NMOSD pathology, but there were several unusual aspects. The absence of lesions in the spinal cord was demonstrated histologically for all spinal segments. Based on his, our case was considered optic-brain-brainstem-type NMOSD.

In another report, only 2 (2%) of 96 patients with definite NMO converted to a secondary progressive course (myelopathy) during a median follow-up of 6.1 years, contrary to the estimate of 21 converted cases based on MS data (28). Yanagawa et al. found no secondary progressive type in 17 definite and limited form cases of NMO. In their report,

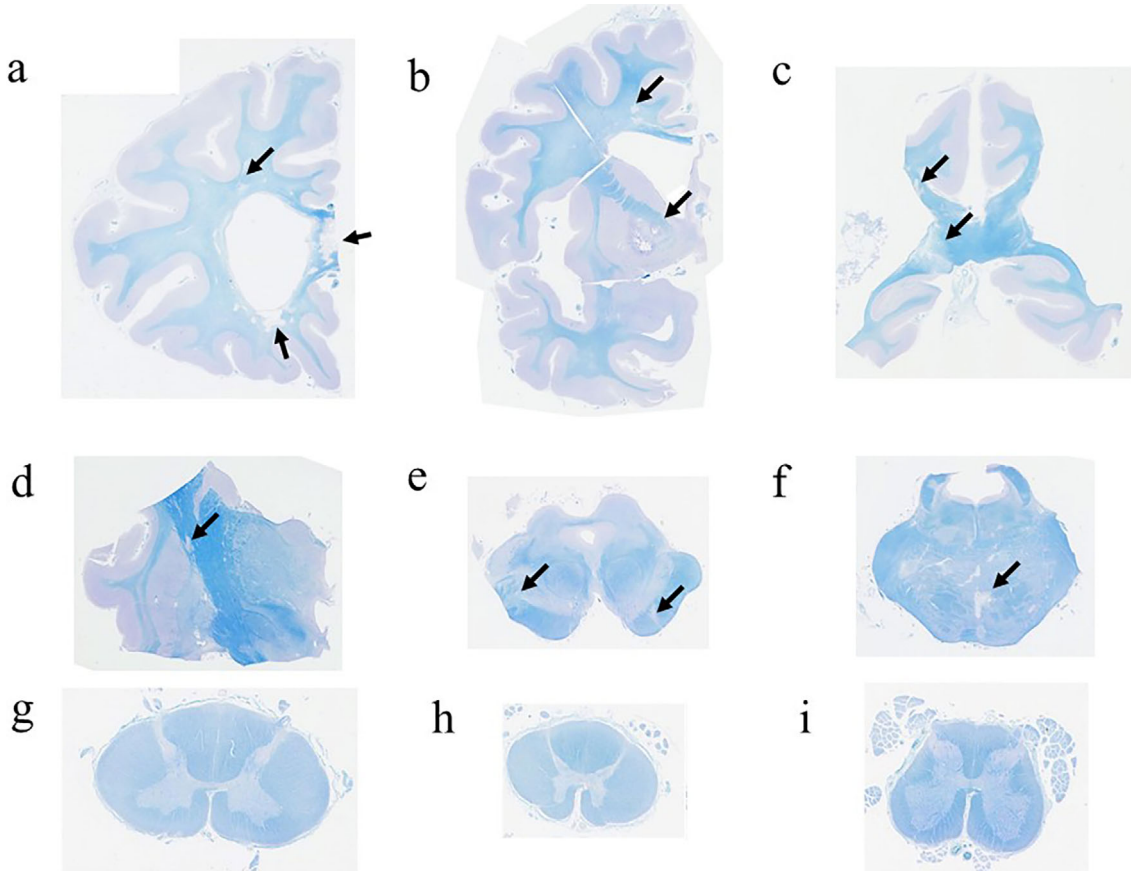

Figure 4. Microscopic findings (KB). Multifocal irregularly shaped lesions were found in the cerebral white matter, corpus callosum, and brainstem (arrow). (a, b) Corpus callosum and the area around the lateral ventricle. (c) Splenium of the corpus callosum. (d-f) Irregular cystic destructive lesions in the brainstem. (g-i) No obvious lesions were observed in any spinal cord specimens.

they concluded that NMO displays homogeneous pathogenic effector immune mechanisms through terminal stages, whereas MS should be recognized as a heterogeneous two-stage disease that can switch from an inflammatory to a degenerative phase (29). In fact, progressive neurologic deterioration (over months to years) unrelated to attacks is a clinical "red flag" in the newly proposed diagnostic criteria for NMOSD. In general, elderly patients with progressive MS have a very low probability of relapse (30, 31); however, the patient in this case, over 60 years old, had several incidents of relapse. MS plaques commonly have distinct margins (16), and relapse is usually rare in elderly patients with progressive MS. Hence, the incidents of relapses in the present case implied a greater possibility of NMOSD rather than MS.

NMOSD patients show progression exclusively at the time of each clinical attack and do not deteriorate without attacks. In contrast, MS patients show spontaneous improvement or deterioration, independent of relapses. The progressive patterns of neurological disability in MS and NMOSD are suggested to differ markedly (11). However, several studies have reported a progressive course in NMOSD (9-11). In our case, it was not possible to distinguish between the two based on the clinical course. The patient's clinical signs mimicked secondary progressive MS, and it was unclear whether it was caused by IFN administration or NMOSD itself (or a combination of both or others). Since this case was observed for a relatively long period compared to the previous report, it became apparent that the patient was progressive after nine years, indicating the importance of long-term follow-up studies.

Recently, Gelfand reported a case with NMOSD wherein an underlying disease process involving the innate immune system was suspected to have caused massive monocytic infiltration and tissue destruction. They proposed that their case illustrated that progressive worsening of NMO could occur in the absence of clinical relapses or contrast-enhanced lesion activity on MRI as a consequence of tissue injury associated with monocytic infiltration (10). The disease process described above might have been similar to that in our own case.

Given the abovementioned findings, it is difficult to distinguish between MS and NMOSD. Even in cases without spinal cord lesions, NMO-IgG should be measured, regardless of whether or not the patients exhibit a typical clinical course or MRI findings.

Our case is extremely rare for secondary progressive-type NMOSD with an optico-brain-brainstem distribution of lesions, and further studies are necessary to elucidate the pathophysiology of NMOSD.

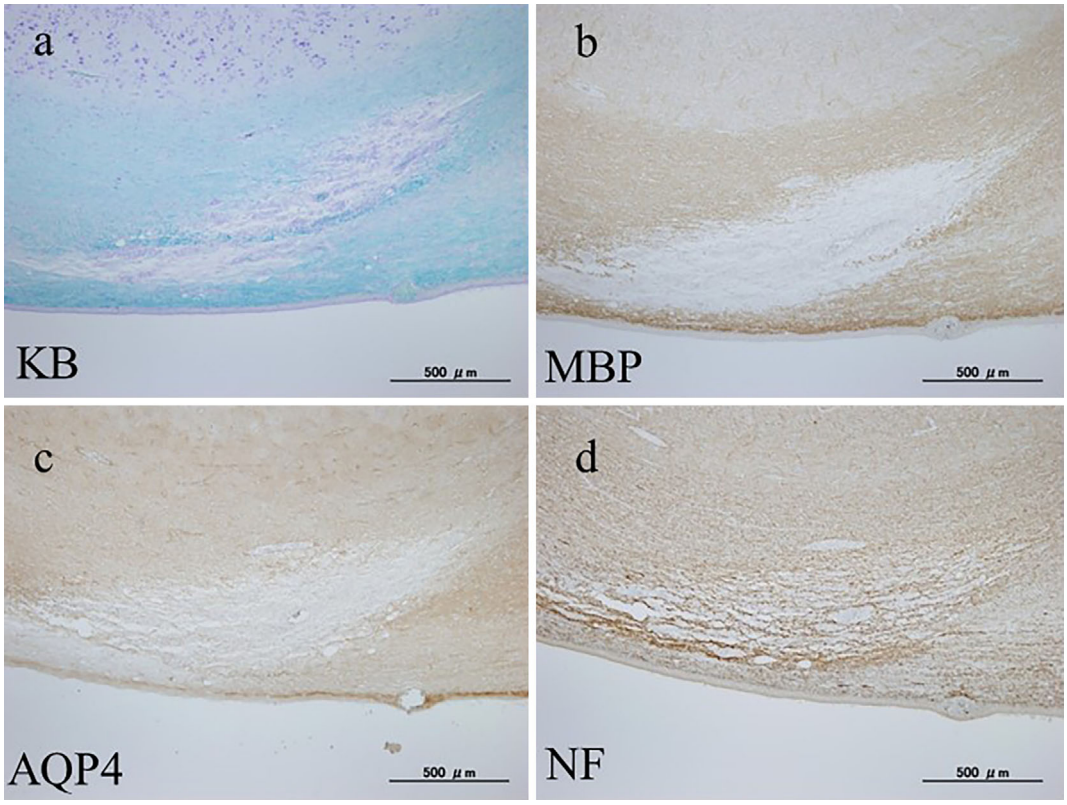

Figure 5. **Immunohistochemistry using anti-AQP4, anti-MBP, and anti-NF antibodies in plaques at occipital white matter lesions. Staining for AQP4 was negative in the lesions.**

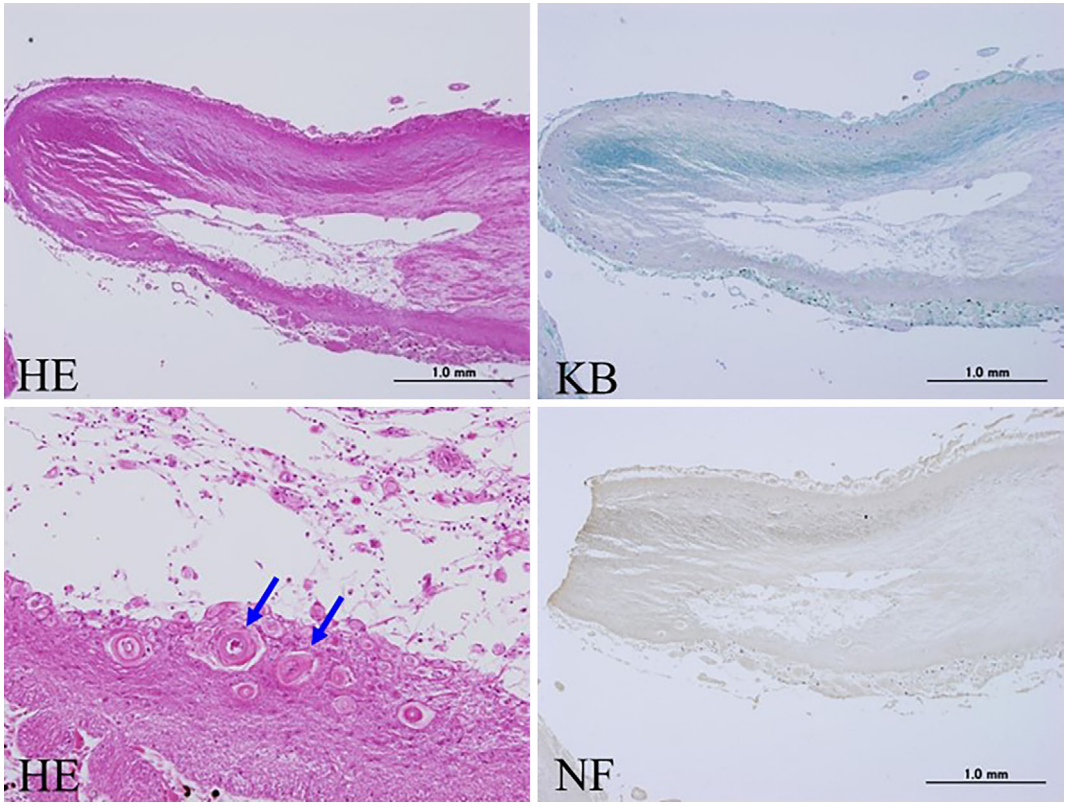

Figure 6. **Optic nerve (HE, KB, NF). Lesions along the blood vessel with hyaline degeneration (arrow).**

The authors state that they have no Conflict of Interest (COI).

References

1. Okinaka S, Tsubaki T, Kuroiwa Y, Toyokura Y, Imamura Y. Multiple sclerosis and allied diseases in Japan; clinical characteristics. Neurology **8**: 756-763, 1958.
2. Wingerchuk DM, Hogancamp WF, O'Brien PC, Weinshenker BG. The clinical course of neuromyelitis optica (Devic's syndrome). Neurology **53**: 1107-1114, 1999.
3. Lennon VA, Wingerchuk DM, Kryzer TJ, et al. A serum autoantibody marker of neuromyelitis optica: distinction from multiple sclerosis. Lancet (London, England) **364**: 2106-2112, 2004.
4. Wingerchuk DM, Lennon VA, Pittock SJ, Lucchinetti CF, Weinshenker BG. Revised diagnostic criteria for neuromyelitis optica. Neurology **66**: 1485-1489, 2006.
5. Wingerchuk DM, Pittock SJ, Lucchinetti CF, Lennon VA, Weinshenker BG. A secondary progressive clinical course is uncommon in neuromyelitis optica. Neurology **68**: 603-605, 2007.
6. Wingerchuk DM, Banwell B, Bennett JL, et al. International consensus diagnostic criteria for neuromyelitis optica spectrum disorders. Neurology **85**: 177-189, 2015.
7. Li Y, Xie P, Lv F, et al. Brain magnetic resonance imaging abnormalities in neuromyelitis optica. Acta Neurol Scand **118**: 218-225, 2008.
8. Nagaishi A, Takagi M, Umemura A, et al. Clinical features of neuromyelitis optica in a large Japanese cohort: comparison between phenotypes. J Neurol Neurosurg Psychiatry **82**: 1360-1364, 2011.
9. Fujihara K, Nakashima I. Secondary progression and innate immunity in NMO: a possible link to alemtuzumab therapy? Neurol Neuroimmunol Neuroinflamm **1**: e38, 2014.
10. Gelfand JM, Cotter J, Klingman J, Huang EJ, Cree BA. Massive CNS monocytic infiltration at autopsy in an alemtuzumab-treated patient with NMO. Neurol Neuroimmunol Neuroinflamm **1**: e34, 2014.
11. Akaishi T, Takahashi T, Misu T, et al. Progressive patterns of neurological disability in multiple sclerosis and neuromyelitis optica spectrum disorders. Sci Rep **10**: 13890, 2020.
12. Thompson AJ, Banwell BL, Barkhof F, et al. Diagnosis of multiple sclerosis: 2017 revisions of the McDonald criteria. Lancet Neurol **17**: 162-173, 2018.
13. Lublin FD, Reingold SC. Defining the clinical course of multiple sclerosis: results of an international survey. National Multiple Sclerosis Society (USA) Advisory Committee on Clinical Trials of New Agents in Multiple Sclerosis. Neurology **46**: 907-911, 1996.
14. Lublin FD, Coetzee T, Cohen JA, Marrie RA, Thompson AJ. The 2013 clinical course descriptors for multiple sclerosis: a clarification. Neurology **94**: 1088-1092, 2020.
15. Miller DH, Weinshenker BG, Filippi M, et al. Differential diagnosis of suspected multiple sclerosis: a consensus approach. Mult Scler **14**: 1157-1174, 2008.
16. Geraldes R, Ciccarelli O, Barkhof F, et al. The current role of MRI in differentiating multiple sclerosis from its imaging mimics. Nat Rev Neurol **14**: 199-213, 2018.
17. Tanaka K. [MS (multiple sclerosis) and NMO (neuromyelitis optica)] clinical symptoms, MRI and laboratory findings of NMO: significance of anti-aquaporin-4 antibody. Brain Med **22**: 331-336, 2010 (in Japanese).
18. Kitley J, Leite MI, Nakashima I, et al. Prognostic factors and disease course in aquaporin-4 antibody-positive patients with neuromyelitis optica spectrum disorder from the United Kingdom and Japan. Brain J Neurol **135**: 1834-1849, 2012.
19. Yoshida M. Neuropathology of demyelinating diseases in Japan. J Neurol Disord Stroke **2**: 1086, 2014.
20. Pittock SJ, Lennon VA, Krecke K, Wingerchuk DM, Lucchinetti CF, Weinshenker BG. Brain abnormalities in neuromyelitis optica. Arch Neurol **63**: 390-396, 2006.
21. Pittock SJ, Weinshenker BG, Lucchinetti CF, Wingerchuk DM, Corboy JR, Lennon VA. Neuromyelitis optica brain lesions localized at sites of high aquaporin 4 expression. Arch Neurol **63**: 964-968, 2006.
22. Nakashima I, Fujihara K, Miyazawa I, Watanabe S, Itoyama Y. Clinical and radiological features of multiplesclerosis patients positive for NMO-lgG. Shinkeinaika **65**: 377-381, 2006 (in Japanese).
23. Furukawa T, Matsui N, Tanaka K, Izumi Y, Kaji R. A case of neuromyelitis optica spectrum disorder (NMOSD) with Sjögren's syndrome manifested only brain involvement by preceding parotitis. Rinsho Shinkeigaku Clin Neurol **57**: 77-81, 2017 (in Japanese).
24. Carvalho DC, Tironi TS, Freitas DS, Kleinpaul R, Talim NC, Lana-Peixoto MA. Sjögren syndrome and neuromyelitis optica spectrum disorder co-exist in a common autoimmune milieu. Arq Neuropsiquiatr **72**: 619-624, 2014.
25. Qiao L, Wang Q, Fei Y, et al. The clinical characteristics of primary Sjögren's syndrome with neuromyelitis optica spectrum disorder in China: a STROBE-compliant article. Medicine **94**: e1145, 2015.
26. Wang KC, Lin KH, Lee TC, et al. Poor responses to interferon-beta treatment in patients with neuromyelitis optica and multiple sclerosis with long spinal cord lesions. PloS One **9**: e98192, 2014.
27. Misu T, Fujihara K, Kakita A, et al. Loss of aquaporin 4 in lesions of neuromyelitis optica: distinction from multiple sclerosis. Brain J Neurol **130**: 1224-1234, 2007.
28. Wingerchuk DM, Lennon VA, Lucchinetti CF, Pittock SJ, Weinshenker BG. The spectrum of neuromyelitis optica. Lancet Neurol **6**: 805-815, 2007.
29. Yanagawa K, Kawachi I, Toyoshima Y, et al. Pathologic and immunologic profiles of a limited form of neuromyelitis optica with myelitis. Neurology **73**: 1628-1637, 2009.
30. Paz Soldán MM, Novotna M, Abou Zeid N, et al. Relapses and disability accumulation in progressive multiple sclerosis. Neurology **84**: 81-88, 2015.
31. Vaughn CB, Jakimovski D, Kavak KS, et al. Epidemiology and treatment of multiple sclerosis in elderly populations. Nat Rev Neurol **15**: 329-342, 2019.

The Internal Medicine is an Open Access journal distributed under the Creative Commons Attribution-NonCommercial-NoDerivatives 4.0 International License. To view the details of this license, please visit (https://creativecommons.org/licenses/by-nc-nd/4.0/).

© 2022 The Japanese Society of Internal Medicine