

Twinkle R 3D Appliance - An Innovative Functional Skeletal Class II Corrector

Abstract

Functional appliances are widely used for regulating and directing growth in which commonly used are Frankel regulator and twinblock. Frankel regulator expands the orofacial arena for allowing growth by passive expansion, whereas twin block aids sagittal correction in retrusive mandible. Here, an attempt to bring about both the changes in a single appliance where sagittal correction as well as keeping away constricted musculature is desired. In this appliance, passive and active expansion has been used simultaneously for better results. In the hindsight of the results, we could get in this case using Twinkle R 3D appliance, we hope that this appliance will be helpful in many more similar cases and act as adundum in clinician's armamentarium.

Keywords: Class II, combination appliance, constricted muscle, Frankel regulator, functional appliance, twin block

Introduction

In the field of orthodontics, class II malocclusion poses a common challenge to the orthodontists for a successful treatment outcome. Worldwide, data show it to be more prevalent in whites than in blacks, more in developed countries than developing countries and more in urban as compared to the rural population. The prevalence of class II malocclusion in India also shows variation, where it is much higher in North India (10%–15%), whereas in South India, it is around 5%.^[1] In spite of the fact that successful treatment of this condition has been proved on many occasions, clinicians and patients continue to look for simpler and better methods for correcting the occlusion while maintaining or improving the facial appearance.^[2] Treatment of Class II malocclusion in adolescents has always relied on growth modification. The majority of treatment modalities such as functional appliances are directed toward stopping or redirecting maxillary growth and simultaneously stimulating mandibular growth.^[3-5] Transverse deficiency is a result of perioral muscles having a restraining effect on dental arches.^[6] This paper demonstrates Twinkle R 3D appliance – A combination of Frankel appliance and

twin-block appliance and R represents the name of the first author (Dr. Rohan Rai) for the treatment of Class II division 1 malocclusion with constricted maxillary arch and hyperactive perioral muscles.

Patient Selection

Patients who can be considered for Twinkle R 3D appliance are those having Class II division 1 dental malocclusion on a moderate skeletal Class II base with abnormal perioral musculature and potential for mandibular growth.

Appliance Design

The design of the appliance is derived from Frankel appliance based on functional matrix theory and twin-block appliance originated from the servo system theory which has been coalesced in a single appliance. Thus, the name Twinkle-R 3D appliance, combination of the parent appliances which brings about three-dimensional changes desired in skeletal class II cases and R stands for the name of the first author of the present article [Figure 1]. Twinkle R 3D appliance consists of two components: the maxillary component and mandibular component. The design of the maxillary component involved an acrylic baseplate which covered the palate and occlusal surfaces of the first molars and second premolars. The inclined

**Rohan Rai,
Jacob
Joseph, K. Mithun,
V. Harshitha,
Suhani Shetty**

*Department of Orthodontics,
A.J. Institute of Dental Sciences,
Mangalore, Karnataka, India*

Submitted : 08-Jan-2020
Revised : 18-Jun-2020
Accepted : 25-Jun-2020
Published : 20-Dec-2020

*Address for correspondence:
Dr. K. Mithun,
Department of Orthodontics,
A.J. Institute of Dental
Sciences, Kuntikana,
Mangalore - 5750 04,
Karnataka, India.
E-mail: dr.mithunknaik@gmail.
com*

This is an open access journal, and articles are distributed under the terms of the Creative Commons Attribution-NonCommercial-ShareAlike 4.0 License, which allows others to remix, tweak, and build upon the work non-commercially, as long as appropriate credit is given and the new creations are licensed under the identical terms.

For reprints contact: WKHLRPMedknow_reprints@wolterskluwer.com

How to cite this article: Rai R, Joseph J, Mithun K, Harshitha V, Shetty S. Twinkle R 3D appliance – An innovative functional skeletal class II corrector. *Contemp Clin Dent* 2020;11:382-6.

Access this article online

Website:
www.contempclindent.org

DOI: 10.4103/ccd.ccd_18_20

Quick Response Code:



planes were constructed at 70° to the occlusal plane and advancement if required was carried out by the addition

of acrylic to the upper block. A midline jack screw was an active expansion component in the upper component. The mandibular component consisted of acrylic baseplate which covered from canine to the second premolars. The buccal shields and the lip pads prevented the abnormal perioral function and enhanced the passive expansion of the maxillary dental arch. Both blocks had delta clasps on the first molars and first premolars to provide posterior retention. Ball end clasps in the anterior segment served the purpose of added retention [Figure 2].

Case Report

A 12-year-old female patient reported to the department with a chief complaint of forwardly placed upper front

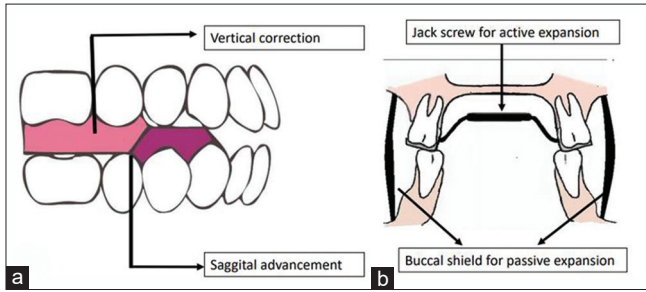


Figure 1: Mode of action of Twinkle R 3D appliance: (a) Sagittal and vertical dimension. (b) Transverse dimension

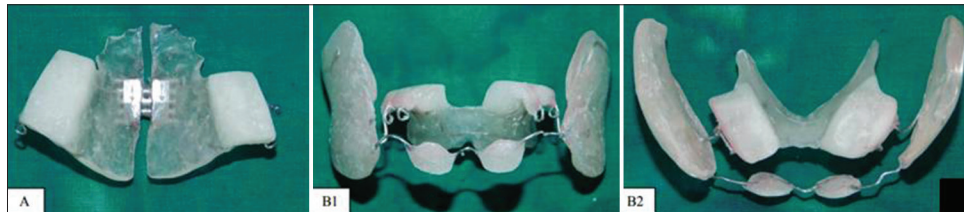


Figure 2: Twinkle R 3D appliance. (a) Maxillary component. (b) (1,2) mandibular component

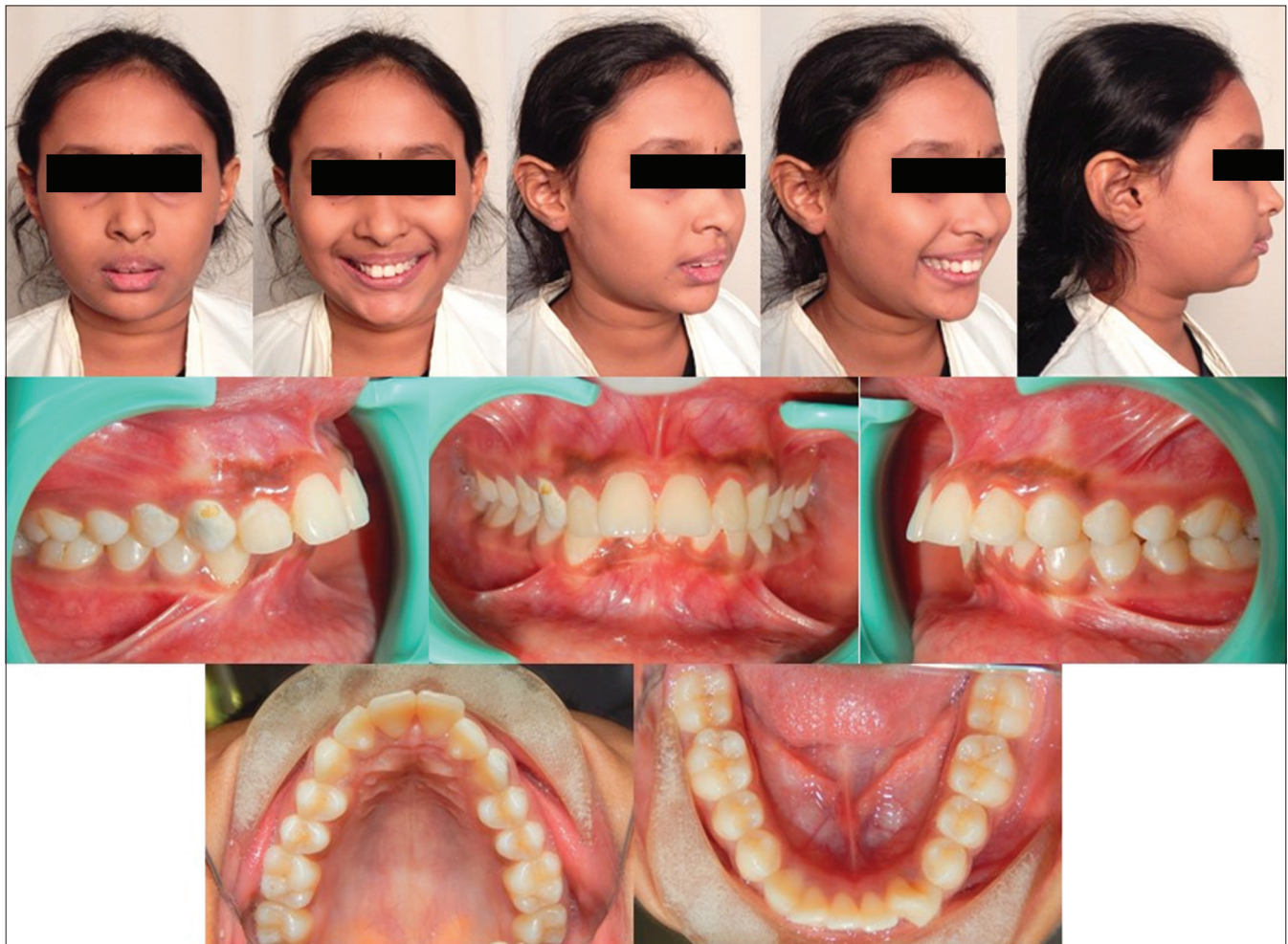

Figure 3: Pretreatment-extra oral and intra oral photographs

teeth. The patient cited esthetics as the main reason for desiring orthodontic treatment.

On extraoral examination, she had a mesocephalic, mesoprosopic face, convex profile, posterior divergence, and incompetent lips. The patient displayed 100% upper incisor crown exposure, increased buccal corridor space, and a nonconsonant smile arc. Intraoral examination revealed a constricted maxilla, reduced intercanine width of 30 mm, and intermolar width of 42 mm and mild crowding in the lower anterior segment. The patient exhibited Class II molar relation bilaterally, over jet of 9 mm and overbite of 6 mm [Figure 3]. Ashley Howe's analysis showed an increased premolar basal arch width compared to premolar diameter concluding that arch expansion is possible. The cephalometric tracing confirmed that the patient had a moderate Class II skeletal pattern with ANB value of 6 degrees. The patient had average growth pattern and proclined maxillary and mandibular incisors [Figure 4 and Table 1].

The objectives of treatment in the sagittal plane were to achieve ideal overjet and overbite by mandibular advancement, in the vertical plane to correct lower anterior facial height, in the transverse plane to achieve expansion of maxilla and overall to attain a pleasing soft tissue profile.

The initial treatment plan decided for the patient was to opt either for twin block or the Frankel appliance. However, according to our treatment objectives, it was essential to achieve maxillary expansion complemented with an ideal overjet, overbite, and improvement in soft-tissue profile. Thus, this led to the discovery of Twinkle R 3D appliance which was fabricated with a construction bite made by sagittal advancement of 6 mm and vertical opening of 4 mm. The patient was asked to wear the appliance for

14 h in a day. Activation of jackscrew was done by slow maxillary expansion protocol,^[7] that is quarter turn every 2 days for 3 weeks. After the desired expansion was attained, activation was discontinued. The patient was asked to follow-up every 3 weeks and was instructed to wear the appliance for a period of 8 months [Figure 5].

Following 8 months of treatment, the patient's profile and smile greatly improved due to expansion of the maxillary arch complemented by mandibular advancement. Overjet and overbite were improved due to the postural forward positioning of the mandible. The midlines were coincident with each other and with the face. In addition, a good buccal occlusion and Class I canine relation were achieved [Figure 6]. End of treatment panoramic tomogram showed good root parallelism and healthy appearance of supporting tissues [Figure 7]. Superimposition and cephalometric analysis showed 4 mm of increase in mandibular length [Figure 8 and Table 1].

Discussion

Class II malocclusions can result from many contributing components, both dental and skeletal. Although maxillary protrusion and mandibular retrusion are both found to be possible causative factors, it has been reported that the most common underlying cause of Class II malocclusion in a population is mandibular retrusion.^[5] In this case report, Twinkle R 3D appliance has been used to bring about the correction of jaw discrepancies.

Table 1: Cephalometric analysis

Parameters	Pre-Rx	Post-Rx
SNA (°)	80	80
Effect maximum length (mm)	87	89
SNB (°)	74	77
Effect mand length (mm)	104	108
ANB (°)	6	3
Angle of convexity (mm)	14	7
FMA (°)	31	32
SN-GO-GN (°)	33	35
LAFH (mm)	58	62
Articular angle (°)	130	137
Base plane angle (°)	19	22
Upper incisor to NA (°)	38	34
Upper incisor to SN (°)	115	110
Lower incisor to NB (°)	30	30
IMPA (°)	96	96
“S” line to upper lip (mm)	3	2
“S” line to lower lip (mm)	-1	1

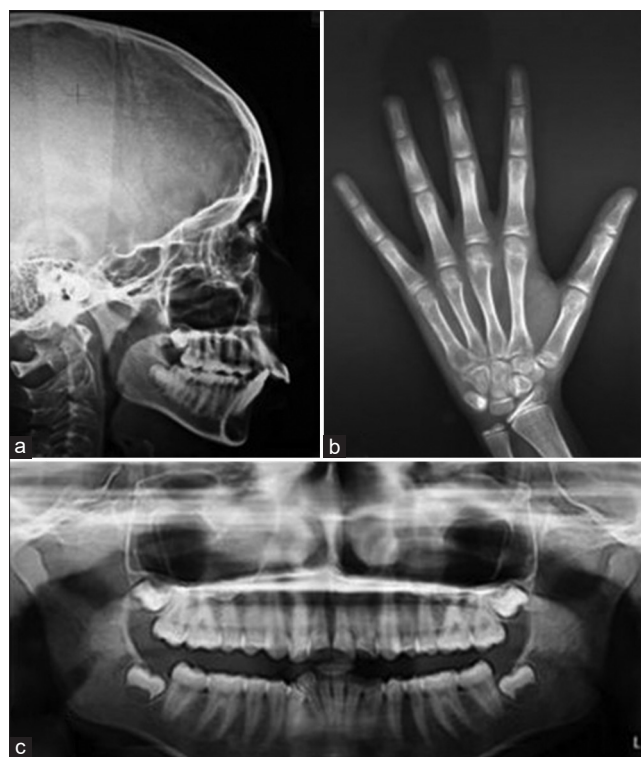

Figure 4: Pretreatment: (a) Lateral cephalogram. (b) Hand wrist radiograph. (c) Orthopantomogram

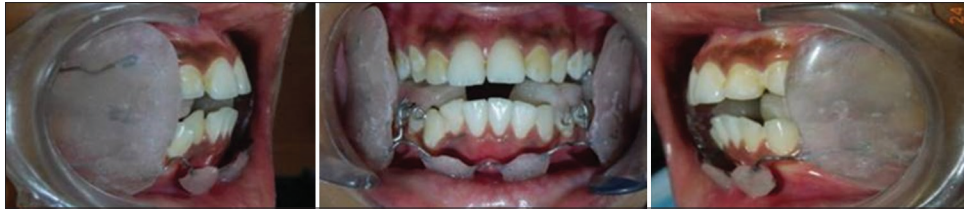

Figure 5: Intra oral: Twinkle R 3D appliance

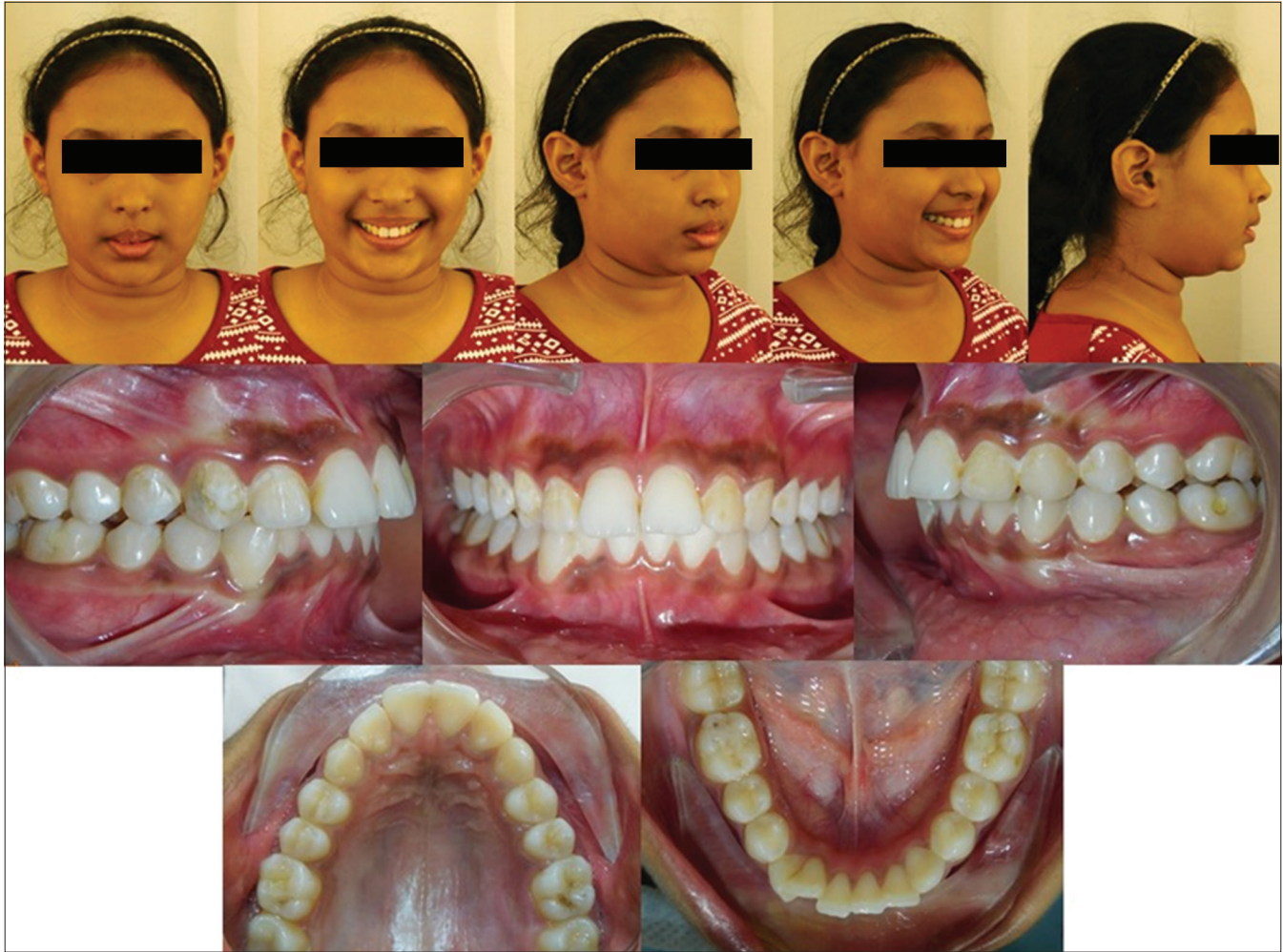

Figure 6: Post Twinkle R 3D appliance: Extra oral and intra oral photographs

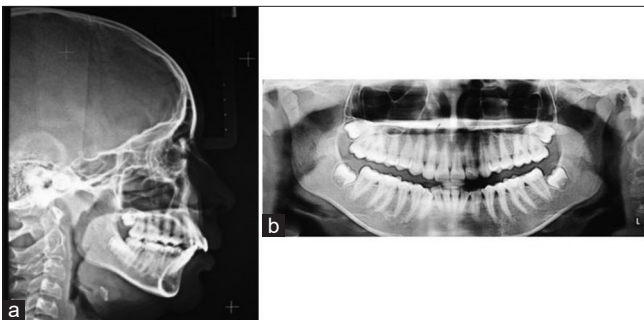


Figure 7: Posttreatment. (a) Lateral cephalogram. (b) Orthopantomogram

Frankel appliance stimulates normal function while eliminating lip trap, hyperactive mentalis and aberrant

buccinators and orbicularis oris action.^[6] The components of Frankel appliance, the buccal shields, and lip pads help in obliterating the adverse effects of abnormal perioral musculature such as constricted maxillary arch and abnormal mentalis muscle activity which is predominantly seen in this case. Forward mandibular positioning with Frankel appliance unloads the normal environmental pressure on the condyle and hence is the mechanism to stimulate mandibular growth.^[8] According to McNamara and Petrovic, a forward positioning of 3–4 mm is sufficient to elicit the desired response from the lateral pterygoid muscle and subsequent condylar feedback.^[8]

One of the limitations of twin block appliance is to elicit soft-tissue changes in and around the dentition. Hence,




Figure 8: Superimposition

in this case, the twin block appliance was modified by incorporating buccal shields and lip pads to the mandibular component, just as seen in a FR II appliance to bring about the desired changes in the perioral musculature. The above modification was done by taking into consideration Frankel's philosophy of vestibular arena of operation. To address the transverse problem, a jack screw was incorporated in the maxillary component of the appliance to actively expand the maxillary arch. According to the protocol, the patient was instructed to turn the jack screw once a week and was reviewed every 4 weeks. By amalgamating the concept of active expansion by jackscrew and passive expansion by buccal shields and lip pads, we were able to increase intercanine width from 30 mm to 33 mm and intermolar width from 42 mm to 47 mm.

In the treatment involving functional appliances, symmetrical overjet and possibility of advancing mandible without any interference are a critical issue.^[9] Active expansion in the maxillary arch increased the intercanine width allowing the mandible to be advanced without any interference.

Twin block showed a favorable mandibular response to treatment, resulting in an increase of SNB angle and reduction in ANB angle during the first 6 months of treatment,^[10] whereas in our case report, SNB angle increased by 3°, ANB angle reduced by 3° while SNA angle remained the same. Their study also proved that twinblock appliance not only resulted in forward positioning of the mandible but also depicted mandibular lengthening as shown by the linear measurements Co-Po, +7.17 mm, whereas in our case, mandibular length also increased by 4 mm. It was further seen that there was an increase of about 2.7 ± 1.7 mm in lower anterior facial height by clockwise rotation of the maxillary plane has been reported^[11] and in treatment of deep bite, bite blocks are trimmed selectively to encourage eruption of lower molars.^[10] which was advantageous in our case. Thus, vertical component, that is, lower anterior facial height increased by 4 mm. Patient was satisfied with the treatment results with her self-esteem being significantly improved.

Conclusion

Functional jaw orthopedics has been practiced since before the turn of the century. There have been significant improvements in the design of functional appliances, with the goal aimed at achieving greater patient acceptance and increased wear time. These appliances seem to offer a valuable treatment modality to the orthodontist.^[8] Hence, this is one such appliance which could act as an aid to orthodontist in the treatment of skeletal class II malocclusion.

Declaration of patient consent

The authors certify that they have obtained all appropriate patient consent forms. In the form the patient(s) has/have given his/her/their consent for his/her/their images and other clinical information to be reported in the journal. The patients understand that their names and initials will not be published and due efforts will be made to conceal their identity, but anonymity cannot be guaranteed.

Financial support and sponsorship

Nil.

Conflicts of interest

There are no conflicts of interest.

References

1. Agarwal SS, Jayan B, Chopra SS. An overview of malocclusion in India. *J Dent Health Oral Disord Ther* 2015;3:319-22.
2. Tulloch JF, Medland W, Tuncay OC. Methods used to evaluate growth modification in Class II malocclusion. *Am J Orthod Dentofacial Orthop* 1990;98:340-7.
3. Staley R. Etiology and prevalence of malocclusion. In: *Textbook of Orthodontics*. 1st ed. S. Bishara, W. B: Saunders Co., Philadelphia; 2001. p. 83.
4. Baccetti T, Franchi L, McNamara JA, Tollaro I. Early dentofacial features of Class II malocclusion: A longitudinal study from the deciduous through the mixed dentition, *Am. J. Orthod* 1997;111:502-9.
5. McNamara JA. Components of class II malocclusion in children 8-10 years of age. *Angle Orthod* 1981;51:177-202.
6. Graber TM, Rakosi T, Petrovic AG. *Dentofacial Orthopedics with Functional Appliances*. St. Louis: The CV Mosby Company, St. Louis; 1985.
7. Bukhari A, Kennedy D, Hannam A, Aleksejūniē J, Yen E. Dimensional changes in the palate associated with slow maxillary expansion for early treatment of posterior crossbite. *Angle Orthod* 2018;88:390-6.
8. Owen AH 3rd. Morphologic changes in the sagittal dimension using the Fränkel appliance. *Am J Orthod* 1981;80:573-603.
9. Proffit WR, Fields HW Jr., Sarver DM. *Contemporary Orthodontics*. St. Louis: Elsevier Health Sciences; 2014.
10. Clark WJ. *Twin Block Functional Therapy Application in Dentofacial Orthopaedics*. 2nd ed. St. Louis: Elsevier Health Sciences; 2002.
11. Illing HM, Morris DO, Lee RT. A prospective evaluation of bionator and twin block appliances. Part I-The hard tissues. *Eur J Orthod* 1998;20:501-16.