

doi:10.3969/j.issn.1673-5374.2013.23.011 [http://www.nrronline.org; http://www.sjzsyj.org]

Jiao LQ, Song G, Hua Y, Ma Y, Chen YF, Wang YB, Ling F. Recanalization of extracranial internal carotid artery occlusion: a 12-year retrospective study. *Neural Regen Res.* 2013;8(23):2204-2206.

Recanalization of extracranial internal carotid artery occlusion

A 12-year retrospective study

Liqun Jiao, Gang Song, Yang Hua, Yan Ma, Yanfei Chen, Yabing Wang, Feng Ling

Department of Neurosurgery, Xuanwu Hospital, Capital Medical University, Beijing 10053, China

Abstract

This study aimed to summarize therapy experience of carotid endarterectomy, carotid endarterectomy combined with Fogarty catheter embolectomy, and hybrid surgery for the treatment of extracranial internal carotid artery occlusion. The study included 65 patients with extracranial internal carotid artery occlusion who underwent carotid endarterectomy, carotid endarterectomy combined with Fogarty catheter embolectomy, or hybrid surgery in the Department of Neurosurgery, Xuanwu Hospital, Capital Medical University, China between January 2006 and December 2012. Prior to surgery, all patients underwent perfusion CT or xenon CT to evaluate the occlusion. The procedure for each patient was chosen according to digital subtraction angiography data. The carotid artery was successfully recanalized in 46 of 51 patients who underwent carotid endarterectomy, 9 of 10 patients who underwent carotid endarterectomy combined with Fogarty catheter embolectomy, and 3 of 4 patients who underwent hybrid surgery. In patients with symptomatic carotid artery occlusion, the carotid artery can be recanalized by choosing a treatment procedure based on imaging examination findings.

Key Words

neural regeneration; carotid occlusion; carotid; carotid artery stenting; carotid endarterectomy; recanalization; retrospective study; grants-supported paper; neuroregeneration

Liqun Jiao, M.D., Associate chief physician.

Corresponding author: Feng Ling, M.D., Professor, Department of Neurosurgery, Xuanwu Hospital, Capital Medical University, No.45 Changchun Street, Xuanwu District, Beijing 100053, China, jiaoliquan@gmail.com.

Received: 2013-05-28

Accepted: 2013-07-30
(N201307030)

Funding: This study was supported by a grant from the National 12th Five-Year Science and Technology Support Plan Project, No. 2011BAI08B00.

Author contributions: Ling F and Jiao LQ designed this study. Song G, Hua Y, Ma Y, Chen YF, and Wang YB performed the research. Jiao LQ and Song G analyzed the experimental data. Song G wrote the paper. All authors approved the final version of the paper.

Conflicts of interest: None declared.

Author statements: The manuscript is original, has not been submitted to or is not under consideration by another publication, has not been previously published in any language or form, including electronic, and contains no disclosure of confidential information or authorship/patent application/funding source disputations.

INTRODUCTION

Carotid endarterectomy can benefit 95% of patients with severe carotid artery stenosis^[1-2]. However, the therapeutic effects of this technique in patients with symptomatic internal carotid artery occlusion remain controversial. Symptomatic patients who receive optimal drug treatment but do not undergo carotid endarterectomy have an annual ipsilateral stroke rate of 6–20%^[3-4]. This retrospective study evaluated the efficacy of various treatment procedures for extracranial internal carotid artery occlusion.

RESULTS

Symptoms and comorbid conditions

Sixty-five patients with symptomatic carotid artery disease were enrolled, including 43 with transient ischemic attacks, 4 with amaurosis fugax, and 22 with strokes. Comorbidities included hypertension ($n = 36$), hyperlipidemia ($n = 28$), heart disease (coronary artery disease, myocardial infarction, and arrhythmia; $n = 18$), peripheral vascular disease ($n = 5$), and previous cerebrovascular angioplasty or surgery ($n = 7$). None of the patients had new cerebral infarction within 3 weeks before treatment.

Imaging evaluation

All patients were evaluated by xenon CT or perfusion CT before treatment. Xenon CT showed a decrease in cerebral blood flow in 6 patients and a decrease in ipsilateral dynamic cerebral autoregulation in 11 patients. Perfusion CT showed a decrease in cerebral blood flow in 11 patients and an increase in time to vascular enhancement in 32 patients.

Success rate of treatment

Carotid endarterectomy was performed in 51 patients and was unsuccessful in five patients. Hybrid surgery was performed in four patients and was unsuccessful in one patient. Carotid endarterectomy combined with Fogarty catheter embolectomy was performed in 10 patients and was unsuccessful in 1 patient. The success rate of treatment was 89% (58/65). Recanalization of the internal carotid artery in typical cases of carotid endarterectomy, carotid endarterectomy combined with thrombectomy, and hybrid surgery are shown in Figures 1–3.

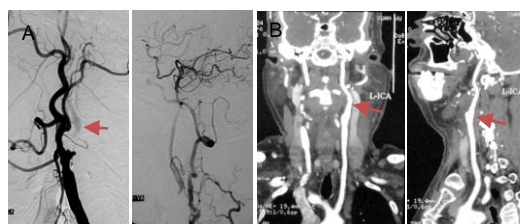

Figure 1 A 50-year-old male with paroxysmal right-sided limb weakness and dysphasia underwent carotid endarterectomy.

(A) Preoperative digital subtraction angiography showed left internal carotid artery occlusion (arrow). (B) Four days after surgery, CT angiography showed recanalization of the left internal carotid artery (L-ICA; arrows).

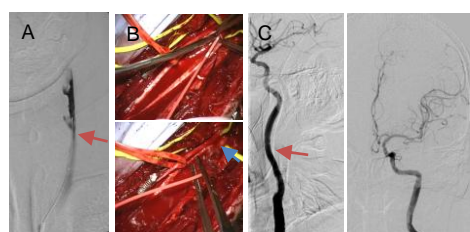


Figure 2 A 72-year-old male with right-sided limb weakness and dysphasia underwent carotid endarterectomy combined with Fogarty balloon catheter thrombectomy.

(A) Digital subtraction angiography of the distal part of the occluded internal carotid artery (arrow). (B) Good retrograde flow after Fogarty balloon catheter thrombectomy (arrow). (C) Digital subtraction angiography of the internal carotid artery at 5 days after surgery.

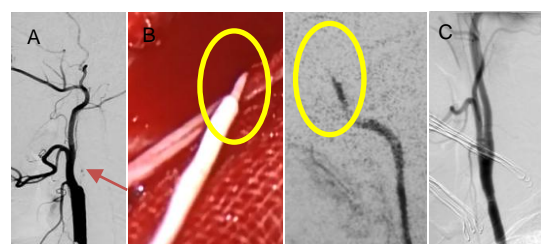


Figure 3 A 46-year-old male with right-sided limb weakness underwent hybrid surgery.

(A) Digital subtraction angiography showing occlusion of the left internal carotid artery. The distal ophthalmic artery is visualized (arrow). (B) Removed thrombus, showing white tissue. The shape of the thrombus corresponds to the internal shape of the artery on digital subtraction angiography (yellow circle). (C) Digital subtraction angiography showing recanalization of the carotid artery after stent placement.

Stroke or death within 30 days after surgery occurred in five patients. The stroke or death rate was 8% (5/65) overall, 3% (1/32) in patients with complete occlusion, and 12% (4/33) in patients with near occlusion.

DISCUSSION

Some studies reported that adequate assessment of patients with complete occlusion by preoperative imaging examinations increased the success rate of surgery and decreased the postoperative stroke or death rate^[3, 5-6]. This study included 32 patients with complete occlusion, and recanalization was unsuccessful in only four of these patients. The success rate of surgery was 87.5%, and only one patient had a postoperative stroke. Carotid endarterectomy is therefore a feasible treatment for carotid artery occlusion, and postoperative stroke or mortality can be minimized.

It may be possible to achieve patency of the internal carotid artery and improve neurological function by performing carotid endarterectomy in carefully selected patients^[7]. There are three important prerequisites for carotid endarterectomy: (1) carotid artery occlusion with symptoms of cerebral ischemia, (2) identification of areas of low perfusion in the ipsilateral cerebral hemisphere on xenon CT or perfusion CT, and (3) visualization of the cavernous and petrous segments of the internal carotid artery in DSA.

Hugenholtz and Elgie^[8] reported 35 patients who underwent carotid endarterectomy for carotid artery occlusion. They did not visualize the entire intracranial internal carotid artery in three patients, and recanalization was

unsuccessful in these patients. The posterior communicating artery segment or ophthalmic artery segment of the internal carotid artery was recanalized in six patients. The cavernous internal carotid artery or the segment of internal carotid artery penetrating into the carotid canal but not beyond the base of the skull was recanalized in 13 patients.

In this study, we visualized the cavernous and petrous segments of the internal carotid artery on digital subtraction angiography in 89% of cases. In patients with prolonged carotid artery occlusion, the thrombus can contain fibrous tissue. As this makes it more difficult to use a Fogarty balloon catheter and to recanalize the distal part of the artery, we used hybrid surgery in these cases. This procedure involved removal of the plaque by carotid endarterectomy, thrombectomy, and placement of a stent in the distal carotid artery. In this study, recanalization was successful in three of the four patients who underwent this procedure.

Taken together, these results indicate that with strict selection criteria according to the preoperative radiographic findings, recanalization is feasible in some patients with symptomatic extracranial internal carotid artery occlusion. Patients can be successfully treated by carotid endarterectomy, carotid endarterectomy combined with Fogarty balloon catheter thrombectomy, or hybrid surgery.

SUBJECTS AND METHODS

Design

A retrospective study.

Time and setting

Sixty-five patients with extracranial internal carotid artery occlusion who received treatment in the Department of Neurosurgery, Xuanwu Hospital, Capital Medical University, between January 2006 and December 2012 were included in this study.

Subjects

This study included 65 patients (59 males, 6 females) with a mean age of 60.7 ± 8.9 years (range, 41–77 years) who had carotid artery stenosis confirmed by duplex ultrasonography and digital subtraction angiography (North American Symptomatic Carotid Endarterectomy trial standard^[2]). Patients with near occlusion were di-

vided into a group without an angiographic string sign and a group with an angiographic string sign^[9]. Near occlusion was defined as (1) very severe stenosis at the site of the residual lumen, (2) delayed flow of angiographic contrast material, and (3) reduced arterial caliber secondary to artery collapse^[9]. Thirty-three patients had near occlusion and 32 had total carotid artery occlusion.

Methods

The patients were treated by carotid endarterectomy, carotid endarterectomy combined with Fogarty balloon catheter embolectomy, or hybrid surgery. At 30 days after surgery, all patients underwent carotid ultrasonography to know the condition of recanalization. The rates of death and stroke were recorded.

REFERENCES

- [1] Randomised trial of endarterectomy for recently symptomatic carotid stenosis: final results of the mrc european carotid surgery trial (ECST). *Lancet*. 1998;351:1379-1387.
- [2] Beneficial effect of carotid endarterectomy in symptomatic patients with high-grade carotid stenosis. North American symptomatic carotid endarterectomy trial collaborators. *N Engl J Med*. 1991;325:445-453.
- [3] Paty PS, Adeniyi JA, Mehta M, et al. Surgical treatment of internal carotid artery occlusion. *J Vasc Surg*. 2003;37:785-788.
- [4] Grubb RJ, Powers WJ. Risks of stroke and current indications for cerebral revascularization in patients with carotid occlusion. *Neurosurg Clin N Am*. 2001;12:473-487
- [5] Cho YP, Kwon TW, Kwon SU, et al. Carotid endarterectomy for symptomatic complete occlusion of the internal carotid artery. *Acta Med Okayama*. 2011;65:239-245.
- [6] Kasper GC, Wladis AR, Lohr JM, et al. Carotid thromboendarterectomy for recent total occlusion of the internal carotid artery. *J Vasc Surg*. 2001;33:242-249, 249-250.
- [7] Moore WS, Barnett HJ, Beebe HG, et al. Guidelines for carotid endarterectomy. A multidisciplinary consensus statement from the ad hoc Committee, American Heart Association. *Stroke*. 1995;26:188-201.
- [8] Hugenholtz H, Elgie RG. Carotid thromboendarterectomy: a reappraisal. Criteria for patient selection. *J Neurosurg*. 1980;53:776-783.
- [9] Fox AJ, Eliasziw M, Rothwell PM, et al. Identification, prognosis, and management of patients with carotid artery near occlusion. *AJNR Am J Neuroradiol*. 2005;26:2086-2094.

(Reviewed by Elgin M, Raye Z, Cai YL, Du YF)

(Edited by Li CH, Song LP, Liu WJ, Zhao M)