

# A predominantly left-sided skin reaction to pristinamycin in a patient with right hemiplegia

Fanny Delcroix,<sup>a</sup> Jean-Philippe Arnault, MD,<sup>a</sup> Guillaume Chaby, MD,<sup>a</sup>  
Valérie Gras-Champel, PharmD,<sup>b</sup> and Catherine Lok, MD, PhD<sup>a</sup>  
*Amiens, France*

**Key words:** drug eruption; hemiplegia; pristinamycin; skin reaction; stroke.

## INTRODUCTION

Unilateral skin reactions are rare in patients with neurologic impairments caused by vascular or metastatic disease. The pathophysiology of these unilateral reactions has not been characterized, although recent research in neurophysiology provides a few clues.

## CASE REPORT

Mr A (a 49-year-old man with right hemiplegia for the previous 18 months as a result of an ischemic stroke) was treated with pristinamycin (1 g, 3 times a day) for erysipelas of the right leg.

The patient had coronary heart disease and a history of alcohol and tobacco consumption. There had been no recent changes in his medications. He was treated for 2 years with amlodipine, baclofen, bisoprolol, cetirizine, fluoxetine, lysine acetylsalicylate, levetiracetam, pregabalin, rabeprazole, and atorvastatin. Seven days after the initiation of antibiotic treatment, he presented with left-sided maculopapular exanthema (MPE) on the trunk and the lower and upper limbs. The skin eruption was less widespread on the right upper and lower limbs (Figs 1 and 2). The patient did not have fever, mucosal erosions, skin blisters, adenopathy, digestive symptoms, or any severe systemic signs suggestive of a viral infection. The Naranjo score was 4, which means that an adverse drug reaction caused by pristinamycin was possible. Laboratory tests found hypereosinophilia (0.6 g/L) but no other abnormalities. Histologic analysis of the skin biopsy found an eczema-like pattern with a few necrotic keratinocytes and eosinophilic, perivascular, and

### Abbreviations used:

DTH: delayed-type hypersensitivity  
HFS: hand-foot syndrome  
MPE: maculopapular exanthema

dermal infiltration (Fig 3). We diagnosed a predominantly left-sided, MPE-type adverse reaction of the skin due to pristinamycin. The eruption resolved within 10 days (with no need for treatment other than pristinamycin withdrawal) and did not recur.

## DISCUSSION

Cutaneous side effects of pristinamycin (an antibiotic related to the macrolides) are rare. The most frequently reported adverse events of this kind are delayed-type, MPE-like reactions. There are also some reports of type 1 hypersensitivity (urticaria and angioedema), Steven Johnson syndrome, Lyell syndrome, acute generalized pustulosis, drug reactions with eosinophilia and systemic symptoms, and even a pityriasis rosea-like eruption. In view of the absence of other likely etiologies (and especially viral causes), the chronology of the eruption, and the fact that MPE-like reactions are the most frequent delayed-type hypersensitivity (DTH) skin reaction to antibiotics in general and to pristinamycin in particular, we considered that the MPE was an adverse reaction to the antibiotic. We would have preferred to perform skin tests to confirm this hypothesis, but, unfortunately, the patient was lost to follow-up soon after this episode. Bilateral skin tests might have reproduced the predominantly left-sided reactivity, although this type of exposure to the allergen might

From the Service de Dermatologie et Vénérologie,<sup>a</sup> and Service de Pharmacologie Clinique,<sup>b</sup> Centre Hospitalier Universitaire d'Amiens.

Funding sources: None.

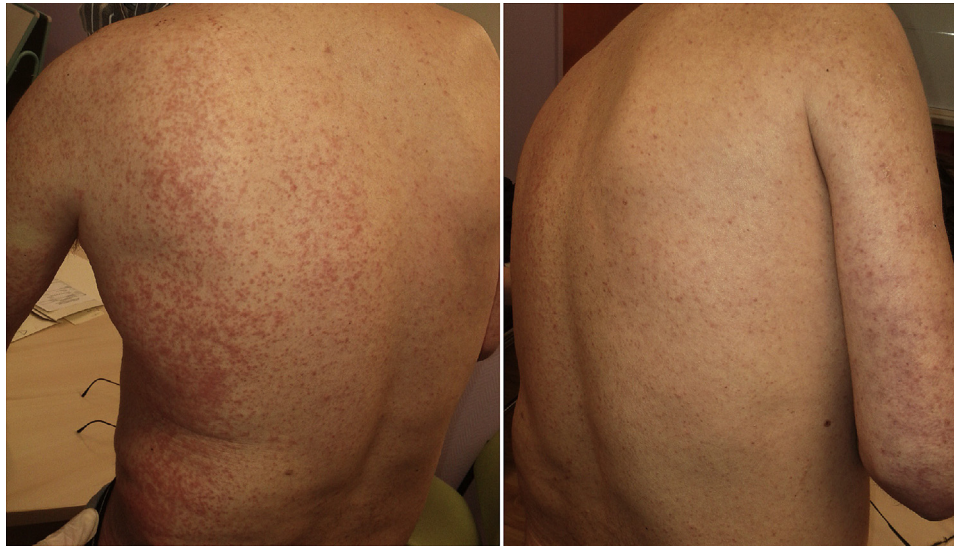Conflicts of interest: None declared.

Correspondence to: Fanny Delcroix, Service de Dermatologie and Vénérologie, Centre Hospitalier Universitaire d'Amiens Picardie, 2, Place victor Pauchet, 80080 Amiens, France. E-mail: [delcroix.fanny@chu-amiens.fr](mailto:delcroix.fanny@chu-amiens.fr).

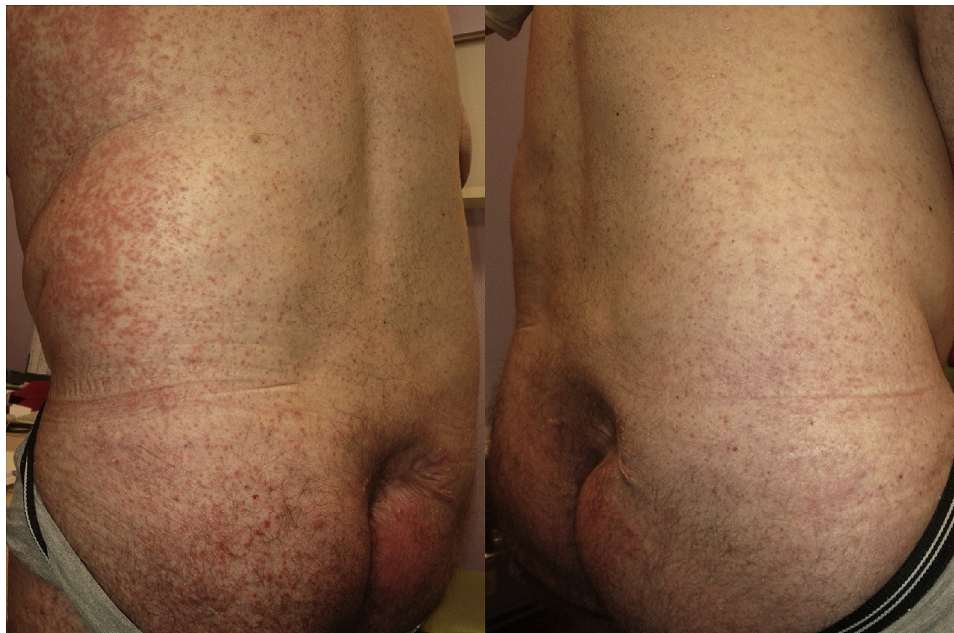
JAAD Case Reports 2016;2:84-6.  
2352-5126

© 2015 by the American Academy of Dermatology, Inc. Published by Elsevier, Inc. This is an open access article under the CC BY-NC-ND license (<http://creativecommons.org/licenses/by-nc-nd/4.0/>).

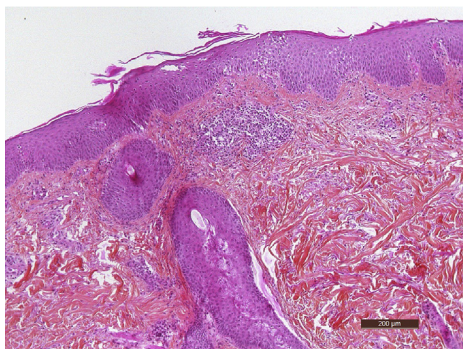
<http://dx.doi.org/10.1016/j.jidcr.2015.11.011>



**Fig 1.** Maculopapular exanthema, left-sided.



**Fig 2.** Maculopapular exanthema, left-sided.



**Fig 3.** Eczematous pattern with a few necrotic keratinocytes and eosinophilic, perivascular, dermal infiltration. (Hematoxylin-eosin-safran stain.)

have triggered hyperresponsiveness of the skin (sometimes referred to *angry back* or *excited skin syndrome*) or an even more serious systemic reaction.

We found 5 other literature reports of unilateral adverse skin reactions: 2 cases involved the targeted therapies, sorafenib and cetuximab, and the 3 others involved the antimetabolites, capecitabine and docetaxel (Table 1). Several pathophysiologic hypotheses may be considered. It is thought that hand-foot syndrome (HFS) may result from mechanical stress. Hence, hemiplegia might protect the affected side from this type of syndrome.<sup>1</sup> Given that many stroke patients have atherosclerosis, poor vascular flow

**Table I.** Unilateral adverse reactions: 5 case reports from the literature

Study	Unilateral adverse reaction/body side	Neurologic disorder	Drug
Almeida da Cruz et al <sup>1</sup>	Right HFS	Left hemiplegia	Capecitabine
Disel et al <sup>2</sup>	Left HFS	Right hemiplegia	Capecitabine
Truchuelo et al <sup>3</sup>	Onycholysis of the right hand	Left hemiplegia	Docetaxel
Chanal et al <sup>4</sup>	Right HFS	Hemiplegia of the left arm	Sorafenib
Kerob et al <sup>5</sup>	Right facial folliculitis	Right facial palsy	Cetuximab

might result in a lower concentration of drug metabolites (and thus a lower risk of HFS development) on the paretic side.<sup>2</sup> Abnormal innervation and lower levels of microtrauma on the paralyzed side might slow nail growth and thus reduce the risk of onycholysis. Lastly, lymphatic stasis might account for folliculitis on the paralyzed side because of the persistence of cetuximab binding to the epidermal growth factor receptor.<sup>5</sup> The latter hypothesis was already been suggested in a report on unilateral pemphigoid in a hemiplegic patient.<sup>6</sup> However, none of the aforementioned side effects were immune reactions like MPE. To the best of our knowledge, a predominantly unilateral, MPE-like skin reaction (ie, one with an immunoallergic mechanism) has not been described previously. The etiology of unilateral MPE has not been characterized, although several hypotheses can be considered. As mentioned above, lower levels of microtrauma and lymphatic stasis on the paralyzed side might protect the body by slowing down the flow of inflammatory mediators.

However, we propose a new hypothesis: immune impairment on the paralyzed side (probably related to T lymphocytes) may reduce the incidence or severity of exanthema. The relationships between the immune system and the central nervous system have been studied since the 1980s. Lévine et al<sup>7</sup> and then Tarkowski et al<sup>8</sup> reported that T cell immunity was asymmetric in hemiplegic patients. On the basis of the reactions to intradermal injections of tuberculin, these researchers found that patients with brain lesions caused by stroke displayed lateralized, DTH reactions.

The lateralization of DTH responses changed over time and was related to the severity, site, and the stroke phase (acute vs chronic).<sup>9</sup> Patients in the early phase of a minor stroke displayed a less-intense DTH response on the paretic side than on the nonparetic side, whereas patients with major stroke displayed a

larger DTH response on the paretic side than on the nonparetic side.<sup>9</sup> The lateralization may be reversed in the chronic phase, regardless of the stroke's severity.<sup>10</sup>

We observed a rare case of a unilateral adverse skin reaction on the valid body side of a patient with stroke-induced hemiplegia. This case illustrates that poststroke immune impairments may occur on the paralyzed side.

#### REFERENCES

- Almeida da Cruz L, Hoff PMG, Ferrari CLS, Riechelmann RSP. Unilateral Hand-Foot Syndrome: Does It Take Sides? Case Report and Literature Review. *Clin Colorectal Cancer*. 2012;11:82-84.
- Disel U, Gürkut Ö, Abalı H, et al. Unilateral hand-foot syndrome: an extraordinary side effect of capecitabine. *Cutan Ocul Toxicol*. 2010;29:140-142.
- Truchuelo M, Vano-Galvan S, Pérez B, Muñoz-Zato E, Jaén P. Unilateral taxane-induced onychopathy in a patient with a brain metastasis. *Dermatol Online J*. 2009;15:7.
- Chanal J, Mateus C, Arnault JP, et al. Un syndrome main-pied unilatéral avec respect du membre paralysé. *Ann Dermatol Venereol*. 2010;137:186.
- Kerob D, Hennequin V, Bousquet G, Behm E, Lebbe C. [Unilateral acneiform rash in facial palsy]. *Ann Dermatol Venereol*. 2010;137:727-729.
- Tsuruta D, Nishikawa T, Yamagami J, Hashimoto T. Unilateral bullous pemphigoid without erythema and eosinophil infiltration in a hemiplegic patient. *J Dermatol*. 2012;39:787-789.
- Lévine JD, Goetzel EJ, Basbaum AI. Contribution of the nervous system to the pathophysiology of rheumatoid arthritis and other polyarthritides. *Rheum Dis Clin North Am*. 1987;13:369-383.
- Tarkowski E, Jensen C, Ekholm S, Ekelund P, Blomstrand C, Tarkowski A. Localization of the brain lesion affects the lateralization of T-lymphocyte dependent cutaneous inflammation. Evidence for an immunoregulatory role of the right frontal cortex-putamen region. *Scand J Immunol*. 1998;47:30-36.
- Koch HJ, Uyanik G, Bogdahn U, Ickenstein GW. Relation between laterality and immune response after acute cerebral ischemia. *Neuroimmunomodulation*. 2006;13:8-12.
- Cerqueira JJ, Almeida OFX, Sousa N. The stressed prefrontal cortex. Left? Right!. *Brain Behav Immun*. 2008;22:630-638.