

# Pan-Enteric Capsule Endoscopy: Current Applications and Future Perspectives

Bruno Rosa<sup>a,b,c</sup> Patrícia Andrade<sup>d,e</sup> Sandra Lopes<sup>f</sup> Ana Rita Gonçalves<sup>g</sup>  
Juliana Serrazina<sup>g</sup> Pedro Marílio Cardoso<sup>d,e</sup> Andrea Silva<sup>f</sup>  
Vítor Macedo Silva<sup>a,b,c</sup> José Cotter<sup>a,b,c</sup> Guilherme Macedo<sup>d,e</sup>  
Pedro Narra Figueiredo<sup>f,h</sup> Cristina Chagas<sup>i</sup>

<sup>a</sup>Gastroenterology Department, Hospital da Senhora da Oliveira, Guimarães, Portugal; <sup>b</sup>Life and Health Sciences Research Institute (ICVS), School of Medicine, University of Minho, Braga, Portugal; <sup>c</sup>ICVS/3B's, PT Government Associate Laboratory, Braga/Guimarães, Portugal; <sup>d</sup>Gastroenterology Department, Centro Hospitalar Universitário de São João, Porto, Portugal; <sup>e</sup>WGO Gastroenterology and Hepatology Training Center Porto, Porto, Portugal; <sup>f</sup>Gastroenterology Department, Centro Hospitalar e Universitário de Coimbra, Coimbra, Portugal; <sup>g</sup>Gastroenterology Department, Hospital de Santa Maria, Centro Hospitalar Lisboa Norte, Lisboa, Portugal; <sup>h</sup>Faculty of Medicine, University of Coimbra, Coimbra, Portugal; <sup>i</sup>Gastroenterology Department, Centro Hospitalar de Lisboa Ocidental, Lisboa, Portugal

## Keywords

Capsule endoscopy · Pan-enteric endoscopy · Digestive bleeding · Inflammatory bowel disease · Crohn's disease

## Abstract

**Background:** The role of capsule endoscopy in the evaluation of the small bowel is well established, and current guidelines position it as a first-line test in a variety of clinical scenarios. The advent of double-headed capsules further enabled the endoscopic assessment of colonic mucosa and the opportunity for a one-step noninvasive examination of the entire bowel (pan-enteric capsule endoscopy [PCE]). **Summary:** We reviewed the technical procedure and preparation of patients for PCE, as well as its current clinical applications and future perspectives. In non-stricturing and non-penetrating Crohn's disease affecting the small bowel and colon, PCE monitors disease activity by assessing mucosal healing, a major treatment

outcome, with a higher diagnostic yield than cross-sectional imaging or conventional colonoscopy. Also in ulcerative colitis, double-headed capsules have been used to monitor disease activity noninvasively. Currently, validated scoring systems have been specifically devised for these double-headed capsules and permit a standardized assessment of the inflammatory burden. In suspected mid-lower digestive bleeding, some exploratory studies have demonstrated the feasibility and high diagnostic yield of PCE, which may work as a filter indicating which patients may benefit of further invasive procedures, namely, for planned hemostatic procedures. The possibility of using PCE is also discussed in the context of polyposis syndromes with simultaneous involvement of the small intestine and colon. **Key Messages:** PCE is a feasible, effective, and safe diagnostic procedure to evaluate the small bowel and colon. It has been increasingly explored in the setting of inflammatory bowel diseases and, more recently, in suspected mid-lower digestive bleeding. PCE is

expected to reduce the demand for invasive procedures and expand the scope of noninvasive intestinal evaluation in the coming future.

© 2023 The Author(s).  
Published by S. Karger AG, Basel

## Cápsula Endoscópica Pan-Entérica: Aplicações Atuais E Perspetivas Futuras

### Palavras Chave

Cápsula endoscópica · Endoscopia pan-entérica · Hemorragia digestiva · Doença inflamatória intestinal · Doença de Crohn

### Resumo

**Introdução:** O papel da endoscopia por cápsula na avaliação do intestino delgado encontra-se bem estabelecido, e as orientações atuais posicionam-na como um teste de primeira linha numa variedade de cenários clínicos. O advento das cápsulas de dupla câmara permitiu expandir a sua aplicação para a avaliação endoscópica da mucosa do cólon, oferecendo a oportunidade de um exame não invasivo de todo o intestino (endoscopia pan-entérica por cápsula, PCE). **Sumário:** Procedemos a uma revisão de vários aspectos do procedimento e preparação dos doentes para a PCE, bem como as aplicações clínicas atuais e as perspetivas futuras das cápsulas de dupla câmara. Na doença de Crohn não estenosante e não penetrante localizada ao intestino delgado e cólon, a PCE permite monitorizar a atividade da doença e avaliar a cicatrização da mucosa, um indicador importante da eficácia da terapêutica, com um rendimento de diagnóstico superior aos métodos convencionais, nomeadamente os exames imagiológicos ou a colonoscopia invasiva. Também na colite ulcerosa, as cápsulas de dupla câmara têm sido utilizadas para monitorizar a atividade da doença de forma não invasiva. Existem índices endoscópicos validados e especificamente concebidos para as cápsulas de dupla câmara, que permitem uma avaliação sistematizada e quantificação objetiva da atividade inflamatória. Na suspeita de hemorragia digestiva média ou baixa, alguns estudos exploratórios demonstraram a aplicabilidade e o elevado rendimento diagnóstico da PCE, podendo funcionar como um filtro de modo a permitir indicar quais os doentes que mais irão beneficiar de um procedimento invasivo subsequente, nomeadamente para a realização de procedimentos hemostáticos dirigidos. A possibilidade de utilização da PCE é também discutida

no contexto das síndromes de polipose com envolvimento simultâneo do intestino delgado e do cólon. **Mensagens-chave:** A PCE é um procedimento diagnóstico eficaz e seguro para avaliar diretamente a mucosa do intestino delgado e cólon. A sua aplicação tem vindo a expandir-se no contexto das Doenças Inflamatórias Intestinais e, mais recentemente, na suspeita de hemorragia digestiva média ou baixa. Existe a expectativa de que no futuro próximo possamos assistir a uma redução substancial da demanda por procedimentos endoscópicos invasivos, face à utilização crescente da PCE enquanto método de diagnóstico pan-intestinal não invasivo.

© 2023 The Author(s).  
Published by S. Karger AG, Basel

### Introduction

Capsule endoscopy, first described in 2000, was one of the most important advances in the investigation of small bowel diseases. A swallowed pill camera acquires images, subsequently converted to video format on a computer, as peristalsis propagates it through the gastrointestinal (GI) tract, allowing a noninvasive endoscopic evaluation of the GI tract [1, 2]. Since its first use 20 years ago, several models were developed, with the purpose of evaluating other GI segments, beyond the small bowel [3].

In 2006, the first double-headed capsule for colonic observation was developed – the PillCam COLON<sup>®</sup> (Given Imaging, Medtronic) which has been primarily used for colorectal cancer screening in average risk populations or when colonoscopy is contraindicated or incomplete [4, 5]. With two cameras recording simultaneously, one in each side of the capsule, the first-generation capsules had a sleep mode to save battery while traveling through the GI tract. The capsule shut down 5 min after ingestion and re-started to transmit images again 2 h after ingestion, in order to preserve the battery life during the progression of the capsule along the small bowel [3]. In 2009, a second generation of this capsule was developed (PillCam COLON2<sup>®</sup>), allowing a wider angle of vision and an enhanced adaptative frame rate – a technology that permits changing the rate of image capture from 4 to 35 frames per second, according to the velocity of progression of the capsule [3, 5]. Some recent studies have focused on the potential role of double-headed capsules in patients with ulcerative colitis (UC) and colonic Crohn's disease (CD) [6].

**Table 1.** Technical details of double-headed capsules currently used to perform PCE

	PillCam COLON2® (Medtronic, Given Imaging Inc.)	PillCam Crohn's® (Medtronic, Given Imaging Inc.)	OMOM CC® (Jinshan)
Dimensions, mm	11.6 mm × 31.5 mm	11.6 mm × 31.5 mm	11.6 mm × 31.5 mm
Optical domes	2	2	2
Resolution (pixels)	256 × 256	256 × 256	360 × 360
Lens angle (degrees)	172° per side	168° per side	172° per side
Frame rate (frames per second, fps)	4–35 fps	4–35 fps	4–35 fps
Sleep mode	Yes (can be deactivated)	No	No
Battery life	≥10 h	≥10 h	15 h

The idea of observing the entire small bowel and colon mucosa, in a single noninvasive procedure, was tested in several clinical scenarios, from GI hemorrhage to inflammatory bowel disease (IBD), due to the development of those double-headed capsules with long-lasting batteries [3, 7]. A few studies have reported the use of the PillCam COLON® for a complete evaluation of the GI tract by turning off the sleep mode, this marking the beginning of pan-enteric evaluation [3]. Boal Carvalho et al. [4] demonstrated that PillCam COLON2® allows for a new concept of noninvasive, safe, and well-tolerated examination of the entire GI tract.

In 2017, a new double-headed capsule named PillCam Crohn's® (Given Imaging, Medtronic) was released, combining two wide-angle cameras that permit a 344°-wide view between the two extremities of the device, with a long-lasting battery (over 12 h) [3, 6]. The pill is similar to the second generation of the PillCam COLON® in its hardware components but is designed to allow complete coverage of the gut from the mouth to the anus without any interruption in recording, allowing a panoramic vision of the GI tract in a single procedure. This new capsule comes with a dedicated software, in which the small bowel is divided into three segments according to their approximate length and the colon is divided into two parts (right and left) [8]. Not having a sleep mode avoids the need for early activation or manual turnoff, which eliminates the risk of accidental loss of small bowel frames [3]. Recently, another double-headed capsule was released for use in clinical practice (OMOM CC®, Jinshan), fulfilling the technical characteristics required to perform a pan-enteric capsule endoscopy (PCE) – Table 1.

PCE reduces the need for invasive procedures with the associated increased risk of complications and extra costs, allowing observation of all the bowel in a single procedure, in a more attractive and comfortable way for the patient [3, 7, 9]. Capsule endoscopy avoids insufflation or sedation, although it still requires bowel preparation, and the risks

associated with the procedure are reduced (capsule retention and potential bowel obstruction), although still more frequent in patients with established Crohn disease [4].

#### Procedure

The PillCam® Crohn's system is composed of four subsystems: the PillCam® Crohn's capsule; the PillCam® recorder; the PillCam® software, and the Given® Workstation [10]. Bowel preparation includes a clear liquid diet on the day prior to capsule swallowing and administration of a polyethylene glycol electrolyte solution divided into two doses: in the evening before and in the morning of the examination day [11]. Following capsule ingestion and depending on its progression through the digestive tract, the recorder receives and interprets real-time input from the capsule and provides audiovisual guidance to patients throughout the procedure; an additional laxative boost, such as the sodium phosphate, is required in order to enhance capsule propulsion and maintain adequate cleansing of the colon [10, 11]. Table 2 summarizes the current standard bowel preparation protocol for PCE.

The PillCam® data recorder emits sequential alerts along the examination, which trigger patient procedures and assist medical decisions: alert 0 informs the patient should take a prokinetic drug, such as metoclopramide 10 mg or domperidone 10 mg tablet by mouth; alert 1 suggests the intake of a laxative boost; alert 2 suggests the intake of a second laxative boost, after 3 h; alert 3 is given when there is a need to take a 10 mg bisacodyl suppository, after 2 h; alert 4 allows to eat a standard light meal, 2 h later; alert 5 marks the ending of the procedure and can occur any time after receiving alert 1.

All laxative boosts should be followed by the intake of additional water during the following hour. Clear liquid ingestion is permitted throughout the examination and preparation [11].

**Table 2.** Bowel preparation protocol for PCE

---

D-2
Low-fiber diet
D-1
Clear liquid diet
19.00 h–21.00 h – 2 L PEG
Examination day
06.30 h–07.30 h – 1 L PEG
08.15 h – 10 mg metoclopramide/domperidone
08.30 h – addition of 100–200 mg simethicone in water for capsule ingestion
09.30 h – check real-time viewer. Additional 10 mg metoclopramide/ domperidone if capsule remains in stomach
First alert (capsule detected in SB) – sodium phosphate, 30 mL + 1 L water
Second alert (3 h after 1st booster) – sodium phosphate, 15 mL + 0.5 L water
Third alert (2 h after 2nd booster) – 10 mg bisacodyl rectal suppository
Light meal allowed

---

---

### Clinical Applications

Current main indications and contraindications for PCE are summarized in Table 3.

#### *Inflammatory Bowel Diseases*

IBDs are a group of GI disorders characterized by chronic inflammation of the GI tract. The two main types of IBD are CD and UC. Colonoscopy and small bowel capsule endoscopy have a definite role in the management of patients with IBD [12]. The advent of PCE, allowing concomitant enteric and colonic evaluation, has created the expectation that this modality may allow a comfortable and accurate evaluation of the GI involvement in IBD in a single examination [3, 13]. Moreover, for IBD evaluation, patients are often submitted to separate colonic and small bowel evaluations, the latter frequently by radiologic exams. Hence, pan-enteric systems may also allow the avoidance of repeated exposure to radiation and overcome the limited sensitivity of radiology in recognizing inflammatory activity in proximal segments of the small bowel and colon segments [14]. Figures 1–3 document some examples of small bowel and/or colonic ulcerated lesions detected by PCE.

#### Crohn's Disease

Given CD's discontinuous nature and disease location, a pan-enteric approach is a valuable option for simultaneous evaluation of SB and colonic lesions, making PCE a convenient method to evaluate disease severity, extent, and distribution [15]. In fact, PCE can provide high diagnostic yields for lesion detection in the entire GI tract in these patients [16–18]. In a recent study by Yamada et al. [19], the diagnostic yield of PillCam COLON2<sup>®</sup> for detection of lesions in both small

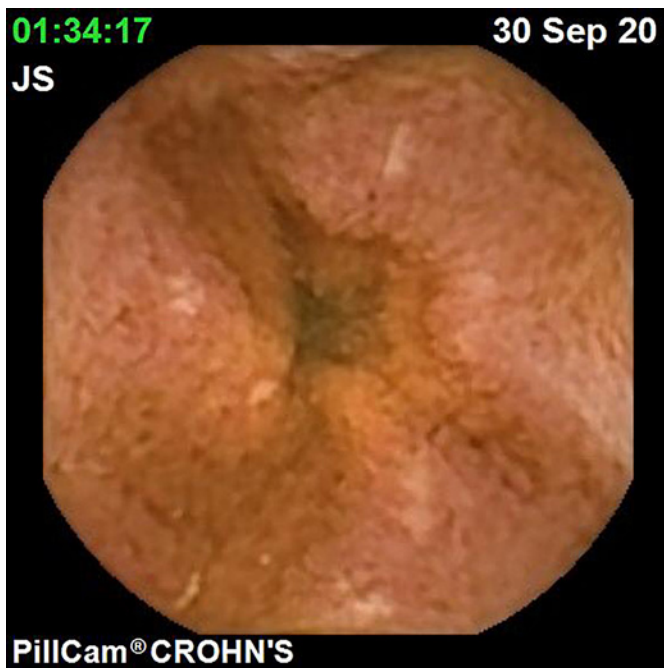and large bowels was analyzed using double balloon enteroscopy as the gold standard. Overall, PCE sensitivities for ulcer scars, erosion, and ulcers were 83.3%, 93.8%, and 88.5%, respectively, and the specificities were 76.0%, 78.3%, and 81.6%, respectively. Other studies have evaluated the diagnostic performances of PCE using the PillCam COLON2<sup>®</sup> or PillCam Crohn's<sup>®</sup> capsule in patients with CD. A recent systematic review and meta-analysis by Tamilarasan et al. [2], which included seven studies evaluating the performance of PCE for the detection of CD lesions, found a comparable diagnostic yield of PCE compared to magnetic resonance enterography and colonoscopy (pooled OR of 1.25 [95% CI: 0.85–1.86%]). In fact, there was a trend to superiority of PCE over MRE and colonoscopy, with an increased diagnostic yield of 5% and 7% for PCE compared with MRE and colonoscopy, respectively.

The role of PCE in postoperative settings has also been addressed. A study by Hausmann detected 50% (6/12) of active disease 4–8 months after surgery, whereas ileocolonoscopy detected significant inflammation in 33% (5/15) [20]. Mucosal healing is increasingly recognized as an important treatment goal in patients with IBD. The concept of treat-to-target underlying IBD management frequently requires endoscopic evaluations to assess mucosal healing. For that reason, a single-time pan-enteric evaluation is appealing. In a multicentric study by Tai et al. [21] PCE was performed in 71 patients with established CD and led to a change in disease management in 33 (46.5%) of patients.

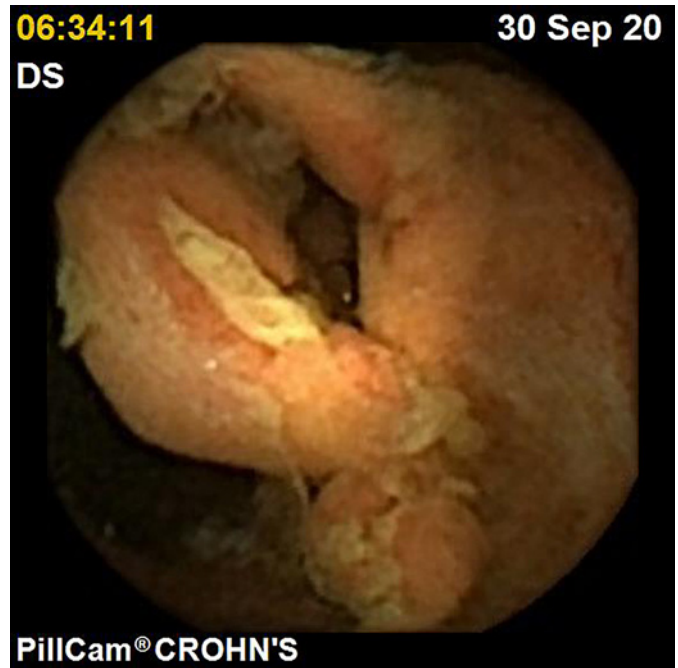
Despite the good performance of PCE in comparison with other endoscopic and imaging modalities, PCE detects only mucosal changes, so it might be insufficient to fully assess disease status (transmural and extramural involvement) [22]. Scoring systems allow for the standardization of reporting, increasing reproducibility and interobserver

**Table 3.** Indications and contraindications for PCE

Indications	Contraindications
<p>CD</p> <p>Inflammatory-type (non-stricturing, non-penetrating), extensive (affecting the small bowel and colon)</p> <ul style="list-style-type: none"> <li>Scheduled monitoring to evaluate mucosal healing in response to treatment (to justify and guide treatment change)</li> <li>Evaluate disease distribution and severity: stratify patients to low versus high risk (prognosis); asymptomatic CD patients with abnormal analysis; exclude active CD/ investigation of symptoms unrelated to disease activity</li> <li>Establish diagnosis in patients with IBD-U, suspected CD, or UC with atypical type, location, or distribution of lesions</li> </ul> <p>Gastrointestinal bleeding</p> <p>Suspected mid-lower GI bleeding (overt or occult)</p>	<ol style="list-style-type: none"> <li>Known or suspected intestinal strictures and/or fistulae (if patency not proven based on cross-sectional imaging and/or patency capsule assessment)</li> <li>Magnetic resonance imaging examination scheduled for same day or following days (requires prior confirmation of capsule excretion)</li> <li>Special conditions/relative contraindications: pregnancy, children under 8 years of age, swallowing disorders; gastric surgery; implanted cardiac electric devices: pacemakers, defibrillators, ventricular assist devices, telemetry; allergy or contraindications to any of the drugs or products used in the protocol; patients unable to walk for short periods and/or with neurological and/or psychiatric condition potentially favoring protocol deviations</li> </ol>
<p>IBD-U, inflammatory bowel disease-type unclassified; CD, Crohn's disease; UC, ulcerative colitis.</p>	



**Fig. 1.** Small bowel aphthous ulcers.

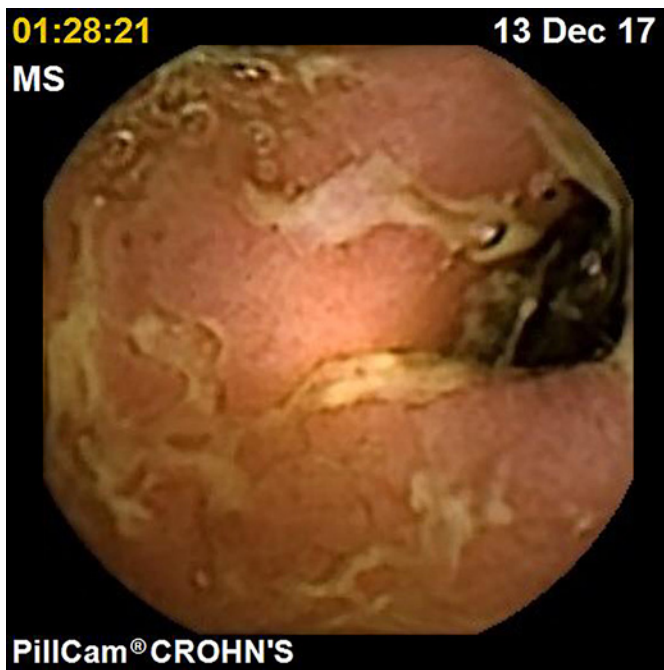

**Fig. 2.** Ileocecal valve ulcer.

agreement [23]. Whereas most scores have been established for colonoscopy and small bowel CE, their application in PCE to monitor IBD mucosal disease activity has also been proposed [13]. Niv et al. [24] extended the validated Capsule Endoscopy Crohn's Disease Activity Index (CECDAI) score to include the colon, introducing the novel CECDAIc score, allowing for an objective pan-enteric assessment of CD inflammatory activity [25]. In

2019, Arieira et al. [26] applied the CECDAIc score in a cohort of CD patients who underwent PCE and found an excellent interobserver agreement (Kendall's coefficient 0.94) and strong correlation with inflammatory parameters, especially calprotectin ( $r_s = 0.82$ ;  $p = 0.012$ ).

A novel PillCam Crohn's<sup>®</sup> capsule score (Eliakim score) for quantification of mucosal inflammation in CD was also developed. In this score, the whole bowel is



**Fig. 3.** Colon ulcers.

divided by length into five segments: the small intestine is divided into three tertiles, and the colon is divided into two (the right colon and the left colon). The score integrates the most common lesion, the most severe lesion, the extent of disease, and the presence of strictures [11]. In this initial study, the correlation between the two readers was excellent for Lewis score and PillCam Crohn's<sup>®</sup> capsule score (0.9,  $p < 0.0001$  for both). The correlation between PillCam Crohn's<sup>®</sup> score and fecal calprotectin was stronger than for Lewis score ( $r = 0.32$  and 0.54, respectively,  $p = 0.001$  for both) [27].

Regarding safety, a recent systematic review and meta-analysis reported a 2% rate of capsule retention for all indications, with a twofold increase in the setting of CD (relative risk = 4%) [28], while another meta-analysis described a retention rate of 4.63% (32 studies, 95% CI: [3.42; 6.25]) in patients with established CD versus 2.35% (16 studies, 95% CI: [1.31; 4.19]) in patients with suspected CD [29]. Although the risk of capsule retention is increased overall in patients with CD [29], it may be significantly decreased with the rationale use of dedicated small bowel imaging such as CT or MR enterography and/or patency capsule, particularly in the case of obstructive symptoms, known stricture or prior SB surgical anastomosis [30–32], where a patency capsule is still required even in cases of unremarkable cross-sectional imaging [31].

PCE seems to be a safe and feasible tool to examine the whole GI tract in patients with CD with a high diagnostic yield for CD lesions detection [33]. However, despite these encouraging results, the precise role and indication for PCE in CD remain unclear due to lack of large scale and randomized controlled trials.

#### Ulcerative Colitis

In recent years, several studies have shown a very good overall agreement between PCE and colonoscopy for assessing disease activity [34–36]. In 2013, a study by Hosoe et al. [37] found that endoscopic scores determined by the PillCam COLON2<sup>®</sup> showed a strong correlation with scores obtained by conventional colonoscopy (average  $\rho = 0.797$ ) in UC patients. In 2018, Hosoe et al. [33] developed an endoscopic severity score for the PillCam COLON2<sup>®</sup>. The final scoring system was fixed as “vascular pattern sum (proximal + distal) + bleeding sum + erosions and ulcers sum (minimum-maximum, 0–14)” and was named Capsule Scoring of Ulcerative Colitis (CSUC) [33]. Overall, the CSUC was an easy-to-use score consisting of three simple parameters (vascular pattern + bleeding + erosions). The correlation coefficient of CSUC with biomarkers and clinical score was similar to that of the Ulcerative Colitis Endoscopic Index of Severity (UCEIS) [38].

More recently, a systematic review and meta-analysis, including data from seven studies, showed that PCE had a diagnostic sensitivity of 94% and a specificity of 70% for the detection of UC [2]. Interestingly, a 2014 study using the PillCam COLON<sup>®</sup> or PillCam COLON2<sup>®</sup> in UC patients found that a small percentage of patients (7.1%) changed the diagnosis of UC to CD due to inflammation observed in the small bowel [39]. In fact, IBD remains unclassified in up to 10–15% of cases after conventional colonoscopy and histology [12], and PCE may have an important role for clarifying the diagnosis in patients with unclassified IBD. Histopathology is crucial not only for the diagnosis but also for disease monitoring. Histological remission is considered a desirable target along with symptomatic and endoscopic remission [22]. Moreover, initial diagnosis and surveillance for dysplastic changes or colitis-associated cancers are also needed [40]. The use of PCE for diagnosis and surveillance lacks the ability to provide histological information.

#### Cost-Effectiveness Considerations

There is already a great volume of publications on the topic of cost-effectiveness in the use of PCE for colorectal cancer screening. However, there is still little evidence of its use in IBD. A British National Health Service study

proposed to evaluate the cost impact of PCE in IBD patients (vs. colonoscopy  $\pm$  MRE). The authors found that, although initial costs were higher using PCE due to the earlier initiation of biologics, in the longer term, there was a financial benefit due to reduction in surgical interventions [41]. A study from USA assessed the cost and patient impact of using PCE for scheduled monitoring of CD. The results showed that the patient groups of PCE showed increased quality of life and increased life expectancy, making it a cost-effective option [42]. There are no data available on the cost-effectiveness in patients with UC.

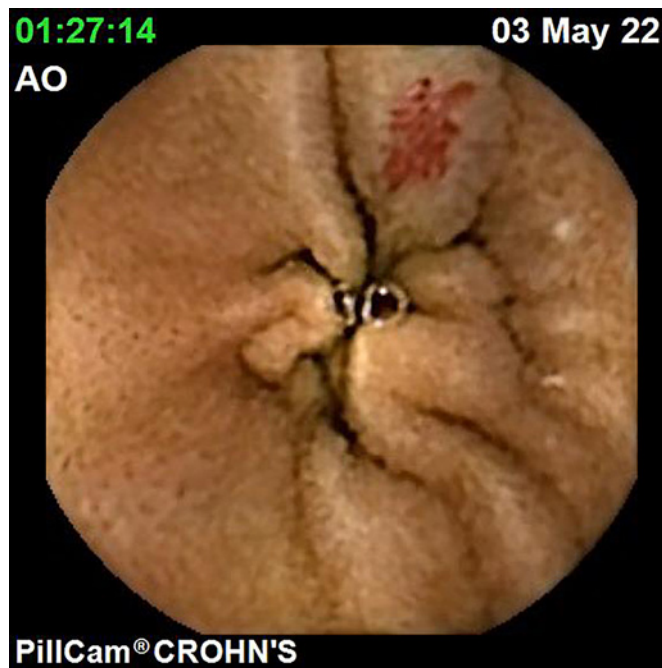
#### *PCE in Gastrointestinal Bleeding*

Despite being far more well established in the setting of IBD investigation, PCE is currently gaining further interest as a potentially useful procedure in many other clinical scenarios [43]. One of the most prominent and recently studied indications is GI bleeding, either overt (presenting as melena and/or hematochezia) or in the *occult* form as chronic iron deficiency anemia, due to its large prevalence in everyday clinical practice.

Esophagogastroduodenoscopy represents the first-line examination in patients presenting with melena [44]. Nevertheless, the examination can be inconclusive in up to 20–25% of the cases [45]. Therefore, colonoscopy is subsequently used to investigate patients presenting with melena after a nondiagnostic esophagogastroduodenoscopy. However, its diagnostic yield is not as high as expected, with the rate of therapeutic colonoscopies in this setting being even lower [45].

Small bowel capsule endoscopy has systematically been recommended as the first-line investigation procedure in patients with obscure GI bleeding – bleeding from the GI tract with negative findings in both esophagogastroduodenoscopy and ileocolonoscopy – which accounts for approximately 5% of all GI bleeding events [46]. Ever since, capsule endoscopy application in the event of obscure GI bleeding or iron deficiency anemia has almost exclusively been reserved to isolated small bowel examination.

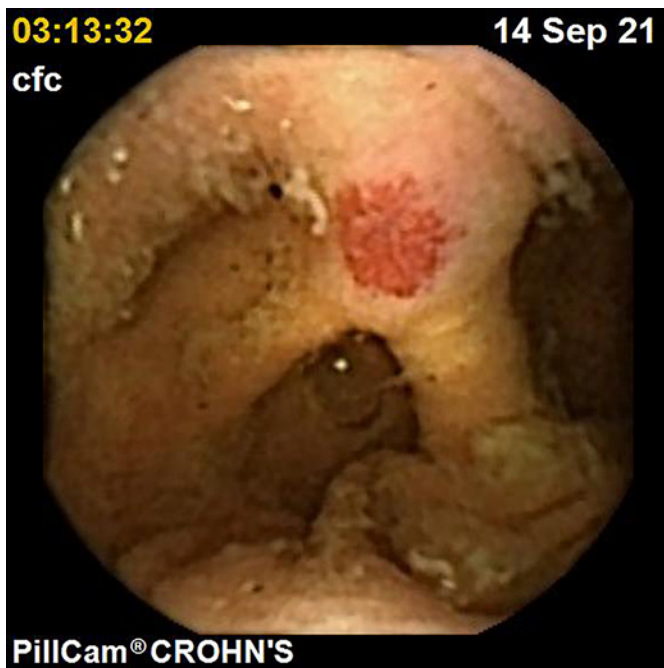
However, after PCE establishment, there has been a shift in this classical scenario, due to hypothetical advantages associated with this innovative diagnostic procedure. On one hand, capsule endoscopy now allows the examination of all GI segments on a single procedure [47]. Furthermore, an adequately timed pan-enteric evaluation may eventually avoid unnecessary inconclusive examinations, with subsequent organizational and economic benefits, as described by Rondonotti et al. [48]. Finally, capsule endoscopy is a technique easily accepted by patients when compared to other conventional



**Fig. 4.** Small bowel angioectasia.

endoscopy procedures, especially in terms of safety and comfort [49]. Figures 4, 5 represent cases of small bowel and colonic angioectasias, respectively, detected by PCE. For these reasons, there is now an ever-growing evidence on the use of a pan-enteric endoscopic approach in patients with GI bleeding, especially those in whom an upper digestive tract lesion has already been excluded, as this strategy could lead to a quicker identification of the bleeding site, drive further management, and potentially avoid other unnecessary examinations [50]. Moreover, it is already known that capsule endoscopy is able to detect proximal lesions missed by upper digestive endoscopy in a significant percentage of the individuals [51].

In 2018, Yung et al. [52] reported that patients with negative upper GI endoscopy and subsequent small bowel capsule endoscopy had shorter mean times from admission to capsule and hospital stays compared to those patients who underwent capsule endoscopy after negative upper and lower GI endoscopy. Therefore, the authors finally concluded that earlier access to capsule endoscopy in patients with melena or iron deficiency anemia, no signs of lower GI pathology, and negative upper GI endoscopy resulted in shortened hospital stays, good diagnostic yield from both the small bowel and upper GI tract, and two-thirds less unnecessary colon investigations.



**Fig. 5.** Colon angioectasia.

In 2021, Mussetto et al. [50] conducted a study aiming to assess the feasibility and performance of PCE in patients presenting with melena and negative digestive upper endoscopy. This investigation included a total of 128 consecutive patients presenting with melena, clinically significant bleeding and negative esophagogastroduodenoscopy, who then underwent PCE by swallowing the PillCam COLON2® capsule. In this proof-of-concept study, PCE was feasible and safe, identifying the bleeding site in 83% of patients. This led to small bowel therapeutic interventions in 50% of patients, thus avoiding unnecessary standard colonoscopy in a significant percentage of the included individuals.

A similar retrospective investigation was made by Carretero et al. [7] by analyzing 100 consecutive PCE performed in a GI bleeding setting. Positive findings were observed in 61% of the patients, with 46% having a previous negative upper endoscopy. The capsule detected small bowel lesions in 68% and colonic findings in 81% of the individuals. According to the authors, no further endoscopic studies would be needed in nearly 65% of the patients with negative gastroscopy. Thus, PCE with a capsule device could be useful and safe in bleeding high-risk patients by selecting those who would eventually need further therapeutic endoscopy.

Due to these recent developments, there is a new and interesting window for the use of PCE in suspected GI bleeding and investigation. Further prospective and

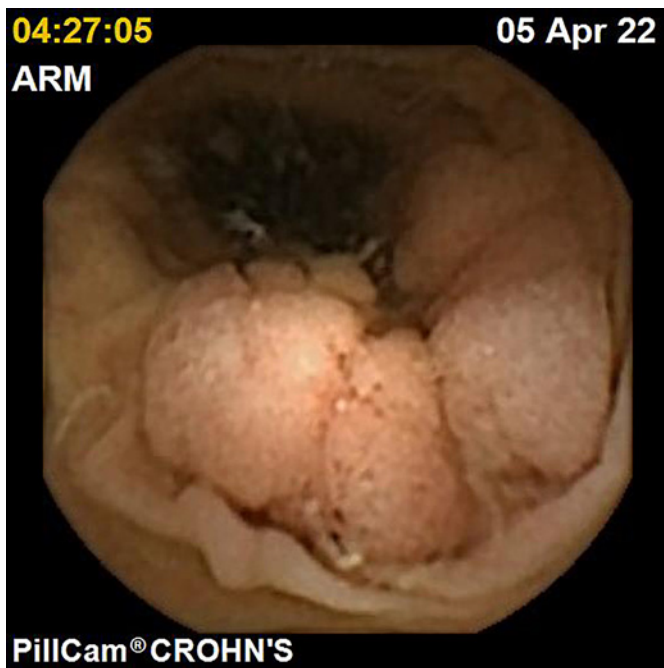
multicenter studies are needed in order to clarify the practical role of capsule endoscopy in this setting, especially in patients presenting a high risk for invasive endoscopic procedures, and the specific indications and timing to use it.

#### *Other Clinical Applications: Limitations and Future Perspectives of PCE*

Although the clinical applicability of PCE in the context of IBD, particularly CD [16, 17, 21, 53], and digestive hemorrhage [50, 52], has been demonstrated in recent studies, its window of use in other clinical scenarios remains narrow. Capsule endoscopy has previously been shown to be useful in the diagnosis of various esophageal diseases, such as varices [54] and Barrett's esophagus [55]; however, it has not been proven cost-effective when compared with traditional endoscopy. Its role in the diagnosis of gastric lesions, on the other hand, is limited by the extent of the mucosal surface and inability to control capsule movements.

The possibility of using a noninvasive pan-endoscopic method may seem appealing in the context of polyposis syndromes with simultaneous involvement of the small intestine and colon, such as familial adenomatous polyposis, Peutz-Jeghers syndrome, or juvenile polyposis syndrome. The role of conventional small bowel capsule endoscopy in the surveillance of polypoid syndromes is well established. Schulman et al. [56] prospectively evaluated 29 patients with familial adenomatous polyposis. From patients with duodenal adenomas, 24% had additional polyps in the jejunum or ileum. The authors concluded that this endoscopic capsule should be considered in the evaluation of these patients. In another study of patients with Peutz-Jeghers syndrome, Caspari et al. [57] demonstrated a superior diagnostic accuracy of CE compared to magnetic resonance imaging in detecting polyps <5 mm. Regarding colon evaluation, double-headed capsules have demonstrated validity in recent years in diagnosing polyps and screening for colon-rectal cancer – Figure 6. A prospective study of 884 asymptomatic patients evaluated initially by the PillCam COLON2® and subsequently conventional colonoscopy demonstrated a sensitivity of 81% and specificity of 93% for detection of polyps ≥ than 6 mm and a sensitivity of 80% and specificity of 97% for polyps ≥ 10 mm [58]. In 2017, the American Multi-Society Task Force positioned capsule colonoscopy as a 3rd-line test in colorectal cancer screening. ESGE also recommends its use as a screening method for colon-rectal cancer only in moderate risk groups, when conventional colonoscopy is incomplete or contraindicated [59]. The limitations of this method are mainly related to the suboptimal adequate preparation





**Fig. 6.** Colon polyps.

rates, the rate of incomplete examinations, the complexity of bowel preparation regimens, and lack of therapeutic capabilities.

These limitations are also transposable to the limitations of PCE. The diagnostic accuracy of the capsule as a pan-endoscopy tool is highly dependent on several parameters such as preparation quality, transit time, complete exam rate. Its applicability also depends on other factors such as patient acceptance and availability of human resources for reading and interpretation [49].

In a recent paper by Vuik et al. [49] evaluating PCE, the rate of patients with adequate colonic preparation (76.6%) was clearly below the standard recommended in conventional colonoscopy (>90%) [60]. The issue of adequate preparation is furthermore corroborated by a recent systematic review [3], where only 54% of studies had >90% of exams with adequate preparation. Vuik et al. [49] also reported complete (“mouth-to-anus”) examination rates of only 51%, similar to other publications [7, 11, 19] and clearly lower than recommended [60]. Another limitation relates to patients’ acceptability. Although capsule endoscopy is a painless and noninvasive method compared to conventional colonoscopy, the complexities of bowel preparation regimens negatively influence its acceptability [49, 61].

In the same work by Vuik et al. [49], the limitations of gastric/esophageal evaluation became apparent. The Z-line was visualized in less than 50% of the patients,

indicating an overly rapid esophageal transit; and although visualization of the gastric mucosa was considered good/excellent in most patients, capsule endoscopy does not allow for adequate observation of the gastric fundus.

The introduction of artificial intelligence systems for assisted reading of these exams is expected to address other current limitations of pan-enteric techniques, decreasing reading times and improving lesions’ detection [62]. In a proof-of-concept study conducted by Ferreira et al. [63] in the setting of CD, a deep learning model for automatic detection of small bowel and colonic ulcers and erosions using PillCam Crohn’s® capsule images was developed, with an overall sensitivity and specificity for lesions’ detection of 90.0% and 96.0%, respectively.

### Conclusion

New perspectives in the field of capsule endoscopy are being devised. PCE seems feasible, effective, and safe, and it has been increasingly explored in IBD and, more recently, GI bleeding, with promising results. Used individually, traditional endoscopic means for evaluation of the esophagus, stomach, and colon remain superior to PCE. However, PCE offers the unique opportunity to evaluate several digestive segments at the same time in a single noninvasive examination. Current well-established clinical indications include the evaluation of inflammatory-type (non-stricturing, non-penetrating) and extensive (affecting the small bowel and colon) CD, mainly for scheduled monitoring to evaluate mucosal healing in response to treatment. The use of PCE may also be useful to establish the diagnosis in atypical cases of UC, suspected CD, or inflammatory bowel disease-type unclassified. More recently, in the context of GI bleeding, PCE has been proven useful in patients with suspected overt or occult mid-lower GI bleeding.

With the introduction of further technological advances such as steerable capsules, intelligent image analysis systems [64], and refinement of protocols, PCE is expected to become an increasingly prevalent tool in future clinical practice, by allowing a noninvasive, safe, and comfortable diagnostic approach for a variety of diseases affecting the small bowel and the colon. PCE appears therefore in the verge of a new paradigm toward expanding the field for noninvasive endoscopy, enabling the direct endoscopic coverage of the entire surface of the small and large bowel in a single examination, and limiting the demand for invasive procedures such as conventional colonoscopy and/or device-assisted enteroscopy, which are expected to be tendentially reserved

only for those patients who require biopsies and/or therapeutic procedures, based on the findings first detected by PCE.

---

## Acknowledgments

Authors would like to thank the Portuguese Small Bowel Study Group (GEPID).

---

## Statement of Ethics

Due to the nature of the article (review article), ethical approval was not required.

---

## Conflict of Interest Statement

The authors have no conflicts of interest to declare.

---

## References

- Hale M, McAlindon ME. Capsule endoscopy as a panenteric diagnostic tool. *Br J Surg*. 2014 Feb;101(3):148–9.
- Tamilarasan AG, Tran Y, Paramsothy S, Leong R. The diagnostic yield of pan-enteric capsule endoscopy in inflammatory bowel disease: a systematic review and meta-analysis. *J Gastroenterol Hepatol*. 2022 Sep 23;37(12):2207–16.
- Cortegoso Valdivia P, Elosua A, Houdeville C, Pennazio M, Fernandez-Urien I, Dray X, et al. Clinical feasibility of panintestinal (or panenteric) capsule endoscopy: a systematic review. *Eur J Gastroenterol Hepatol*. 2021 Jul 1;33(7):949–55.
- Boal Carvalho P, Rosa B, Dias de Castro F, Moreira MJ, Cotter J. PillCam COLON 2 in Crohn's disease: a new concept of pan-enteric mucosal healing assessment. *World J Gastroenterol*. 2015 Jun 21;21(23):7233–41.
- Ahmed M. Video capsule endoscopy in gastroenterology. *Gastroenterol Res*. 2022 Apr;15(2):47–55.
- Skamnelos A, Lazaridis N, Vlachou E, Koukias N, Apostolopoulos P, Murino A, et al. The role of small-bowel endoscopy in inflammatory bowel disease: an updated review on the state-of-the-art in 2021. *Ann Gastroenterol*. 2021 Sep-Oct;34(5):599–611.
- Carretero C, Prieto de Frias C, Angos R, Betes M, Herraiz M, de la Riva S, et al. Pan-enteric capsule for bleeding high-risk patients. Can we limit endoscopies? *Rev Esp Enferm Dig*. 2021 Aug;113(8):580–4.
- Eliakim R. The impact of panenteric capsule endoscopy on the management of Crohn's disease. *Therap Adv Gastroenterol*. 2017 Sep; 10(9):737–44.
- Brodersen JB, Knudsen T, Kjeldsen J, Juel MA, Rafaelsen SR, Jensen MD. Diagnostic accuracy of pan-enteric capsule endoscopy and magnetic resonance enterocolonography in suspected Crohn's disease. *United European Gastroenterol J*. 2022;10(9):973–82.
- Eliakim R, Spada C, Lapidus A, Eyal I, Pecere S, Fernandez-Urien I, et al. Evaluation of a new pan-enteric video capsule endoscopy system in patients with suspected or established inflammatory bowel disease: feasibility study. *Endosc Int Open*. 2018 Oct;6(10):E1235–46.
- Eliakim R, Yablecovitch D, Lahat A, Ungar B, Shachar E, Carter D, et al. A novel PillCam Crohn's capsule score (Eliakim score) for quantification of mucosal inflammation in Crohn's disease. *United Eur Gastroenterol J*. 2020 Jun;8(5):544–51.
- Maaser C, Sturm A, Vavricka SR, Kucharzik T, Fiorino G, Annese V, et al. ECCO-ESGAR guideline for diagnostic assessment in IBD Part 1: initial diagnosis, monitoring of known IBD, detection of complications. *J Crohns Colitis*. 2019 Feb 1;13(2):144–64.
- Na SY, Lim YJ. Capsule endoscopy in inflammatory bowel disease: when? To whom? *Diagnostics*. 2021 Nov 30;11(12):2240.
- Greener T, Klang E, Yablecovitch D, Lahat A, Neuman S, Levhar N, et al. The impact of magnetic resonance enterography and capsule endoscopy on the re-classification of disease in patients with known Crohn's disease: a prospective Israeli IBD research nucleus (IIRN) study. *J Crohns Colitis*. 2016 May;10(5):525–31.
- Annese V, Manetti N. Capsule endoscopy in Crohn's disease: is there enough light in the tunnel? *J Crohns Colitis*. 2014;8(12):1598–600.
- Leighton JA, Helper DJ, Gralnek IM, Dotan I, Fernandez-Urien I, Lahat A, et al. Comparing diagnostic yield of a novel pan-enteric video capsule endoscope with ileocolonoscopy in patients with active Crohn's disease: a feasibility study. *Gastrointest Endosc*. 2017 Jan; 85(1):196–205.e1.
- Bruining DH, Oliva S, Fleisher MR, Fischer M, Fletcher JG; BLINK study group. Pan-enteric capsule endoscopy versus ileocolonoscopy plus magnetic resonance enterography in Crohn's disease: a multicentre, prospective study. *BMJ Open Gastroenterol*. 2020 Jun;7(1):e000365.
- Nam JH, Lee KH, Lim YJ. Examination of entire gastrointestinal tract: a perspective of mouth to anus (M2A) capsule endoscopy. *Diagnostics*. 2021;11(8):1367.
- Yamada K, Nakamura M, Yamamura T, Maeda K, Sawada T, Mizutani Y, et al. Diagnostic yield of colon capsule endoscopy for Crohn's disease lesions in the whole gastrointestinal tract. *BMC Gastroenterol*. 2021;21(1):75.
- Hausmann J, Schmelz R, Walldorf J, Filmann N, Zeuzem S, Albert JG. Panintestinal capsule endoscopy in patients with postoperative Crohn's disease: a pilot study. *Scand J Gastroenterol*. 2017 Aug; 52(8):840–5.

---

## Funding Sources

No subsidies or grants supported this work.

---

## Author Contributions

Bruno Rosa, Patrícia Andrade, Sandra Lopes, Ana Rita Gonçalves, and Cristina Chagas conceived the study design and the structured content. Andrea Silva, Sandra Lopes, Pedro Marílio Cardoso, Patrícia Andrade, Vítor Macedo Silva, Bruno Rosa, Juliana Serrazina, and Ana Rita Gonçalves performed the literature review, selection of studies, and writing. José Cotter, Guilherme Macedo, Pedro Narra Figueiredo, and Cristina Chagas critically reviewed the article. All the authors approved the final version to be published.

---

## Data Availability Statement

All data analyzed during this review are included in this article. Further inquiries can be directed to the corresponding author.

- 21 Tai FWD, Ellul P, Elosua A, Fernandez-Urien I, Tontini GE, Elli L, et al. Panenteric capsule endoscopy identifies proximal small bowel disease guiding upstaging and treatment intensification in Crohn's disease: a European multicentre observational cohort study. *United Eur Gastroenterol J*. 2021 Mar;9(2):248–55.
- 22 Solitano V, D'Amico F, Allocca M, Fiorino G, Zilli A, Loy L, et al. Rediscovering histology: what is new in endoscopy for inflammatory bowel disease? *Therap Adv Gastroenterol*. 2021;14:17562848211005692.
- 23 Limdi JK, Picco M, Farraye FA. A review of endoscopic scoring systems and their importance in a treat-to-target approach in inflammatory bowel disease (with videos). *Gastrointest Endosc*. 2020 Apr;91(4):733–45.
- 24 Niv Y, Gal E, Gabovitz V, Hershkovitz M, Lichtenstein L, Avni I. Capsule endoscopy Crohn's disease activity Index (CECDALic or niv score) for the small bowel and colon. *J Clin Gastroenterol*. 2018;52(1):45–9.
- 25 Tabone T, Koulaouzidis A, Ellul P. Scoring systems for clinical colon capsule endoscopy — all you need to know. *J Clin Med*. 2021;10(11):2372.
- 26 Arieira C, Magalhães R, Dias de Castro F, Boal Carvalho P, Rosa B, Moreira MJ, et al. CECDALic: a new useful tool in pan-intestinal evaluation of Crohn's disease patients in the era of mucosal healing. *Scand J Gastroenterol*. 2019 Nov;54(11):1326–30.
- 27 Rosa B, Margalit-Yehuda R, Gatt K, Sciberras M, Girelli C, Saurin JC, et al. Scoring systems in clinical small-bowel capsule endoscopy: all you need to know. *Endosc Int Open*. 2021 Jun;9(6):E802–23.
- 28 Cortegoso Valdivia P, Skonieczna-Żydecka K, Elosua A, Sciberras M, Piccirelli S, Rullan M, et al. Indications, detection, completion and retention rates of capsule endoscopy in two decades of use: a systematic review and meta-analysis. *Diagnostics*. 2022 Apr 28;12(5):1105.
- 29 Pasha SF, Pennazio M, Rondonotti E, Wolf D, Buras MR, Albert JG, et al. Capsule retention in Crohn's disease: a meta-analysis. *Inflamm Bowel Dis*. 2020 Jan 1;26(1):33–42.
- 30 Nemeth A, Kopylov U, Koulaouzidis A, Wurm Johansson G, Thorlacius H, Amre D, et al. Use of patency capsule in patients with established Crohn's disease. *Endoscopy*. 2016 Apr;48(4):373–9.
- 31 Rondonotti E, Soncini M, Girelli CM, Russo A, de Franchis R; collaborators on behalf of AIGO SIED and SIGE Lombardia, et al. Short article: negative small-bowel cross-sectional imaging does not exclude capsule retention in high-risk patients. *Eur J Gastroenterol Hepatol*. 2016 Aug;28(8):871–5.
- 32 Silva M, Cardoso H, Cunha R, Peixoto A, Gaspar R, Gomes S, et al. Evaluation of small-bowel patency in Crohn's disease: prospective study with a patency capsule and computed tomography. *GE Port J Gastroenterol*. 2019 Oct;26(6):396–403.
- 33 Hosoe N, Hayashi Y, Ogata H. Colon capsule endoscopy for inflammatory bowel disease. *Clin Endosc*. 2020 9;53(5):550–4.
- 34 Sung J, Ho KY, Chiu HM, Ching J, Travis S, Peled R. The use of Pillcam Colon in assessing mucosal inflammation in ulcerative colitis: a multicenter study. *Endoscopy*. 2012 Aug;44(8):754–8.
- 35 Shi HY, Chan FKL, Higashimori A, Kyaw M, Ching JYL, Chan HCH, et al. A prospective study on second-generation colon capsule endoscopy to detect mucosal lesions and disease activity in ulcerative colitis (with video). *Gastrointest Endosc*. 2017 Dec;86(6):1139–46.e6.
- 36 Adler SN, González Lama Y, Matallana Royo V, Suárez Ferrer C, Schwartz A, Bar-Gil Shitrit A. Comparison of small-bowel colon capsule endoscopy system to conventional colonoscopy for the evaluation of ulcerative colitis activity. *Endosc Int Open*. 2019 Oct;7(10):E1253–61.
- 37 Hosoe N, Matsuoka K, Naganuma M, Ida Y, Ishibashi Y, Kimura K, et al. Applicability of second-generation colon capsule endoscope to ulcerative colitis: a clinical feasibility study. *J Gastroenterol Hepatol*. 2013;28(7):1174–9.
- 38 Travis SPL, Schnell D, Krzeski P, Abreu MT, Altman DG, Colombel J-F, et al. Developing an instrument to assess the endoscopic severity of ulcerative colitis: the Ulcerative Colitis Endoscopic Index of Severity (UCEIS). *Gut*. 2012;61(4):535–42.
- 39 San Juan-Acosta M, Caunedo-Álvarez A, Argüelles-Arias F, Castro-Laria L, Gómez-Rodríguez B, Romero-Vázquez J, et al. Colon capsule endoscopy is a safe and useful tool to assess disease parameters in patients with ulcerative colitis. *Eur J Gastroenterol Hepatol*. 2014;26(8):894–901.
- 40 Hosoe N, Limpia Kamiya KJL, Hayashi Y, Sujino T, Ogata H, Kanai T. Current status of colon capsule endoscopy. *Dig Endosc*. 2021 May;33(4):529–37.
- 41 Lobo A, Torrejon Torres R, McAlindon M, Panter S, Leonard C, van Lent N, et al. Economic analysis of the adoption of capsule endoscopy within the British NHS. *Int J Qual Health Care*. 2020;32(5):332–41.
- 42 Saunders R, Torrejon Torres R, Konsinski L. Evaluating the clinical and economic consequences of using video capsule endoscopy to monitor Crohn's disease. *Clin Exp Gastroenterol*. 2019;12:375–84.
- 43 Oka P, McAlindon M, Sidhu R. Capsule endoscopy: a non-invasive modality to investigate the GI tract: out with the old and in with the new? *Expert Rev Gastroenterol Hepatol*. 2022 Jul;16(7):591–9.
- 44 Gralnek IM, Stanley AJ, Morris AJ, Camus M, Lau J, Lanis A, et al. Endoscopic diagnosis and management of nonvariceal upper gastrointestinal hemorrhage (NVUGIH): European Society of Gastrointestinal Endoscopy (ESGE) Guideline: update 2021. *Endoscopy*. 2021 Mar;53(3):300–32.
- 45 Etzel JP, Williams JL, Jiang Z, Lieberman DA, Knigge K, Faigel DO. Diagnostic yield of colonoscopy to evaluate melena after a nondiagnostic EGD. *Gastrointest Endosc*. 2012 Apr;75(4):819–26.
- 46 Pennazio M, Spada C, Eliakim R, Keuchel M, May A, Mulder CJ, et al. Small-bowel capsule endoscopy and device-assisted enteroscopy for diagnosis and treatment of small-bowel disorders: European Society of Gastrointestinal Endoscopy (ESGE) clinical guideline. *Endoscopy*. 2015 Apr;47(4):352–76.
- 47 Cortegoso Valdivia P, Toth E, Koulaouzidis A. Light flickering through a narrow window opening in capsule panendoscopy. *Endosc Int Open*. 2022 May;10(5):E582–3.
- 48 Rondonotti E, Pennazio M. Colon capsule for panendoscopy: a narrow window of opportunity. *Endosc Int Open*. 2021 Dec;9(12):E1860–2.
- 49 Vuik FER, Moen S, Nieuwenburg SAV, Schreuders EH, Kuipers EJ, Spaander MCW. Applicability of colon capsule endoscopy as pan-endoscopy: from bowel preparation, transit, and rating times to completion rate and patient acceptance. *Endosc Int Open*. 2021 Dec;9(12):E1852–9.
- 50 Mussetto A, Arena R, Fuccio L, Trebbi M, Tina Garrriba A, Gasperoni S, et al. A new panenteric capsule endoscopy-based strategy in patients with melena and a negative upper gastrointestinal endoscopy: a prospective feasibility study. *Eur J Gastroenterol Hepatol*. 2021 May 1;33(5):686–90.
- 51 Kitiyakara T, Selby W. Non-small-bowel lesions detected by capsule endoscopy in patients with obscure GI bleeding. *Gastrointest Endosc*. 2005 Aug;62(2):234–8.
- 52 Yung DE, Koulaouzidis A, Douglas S, Plevris JN. Earlier use of capsule endoscopy in inpatients with melena or severe iron deficiency anemia reduces need for colonoscopy and shortens hospital stay. *Endosc Int Open*. 2018 Sep;6(9):E1075–84.
- 53 Oliva S, Cucchiara S, Civitelli F, Casciani E, Di Nardo G, Hassan C, et al. Colon capsule endoscopy compared with other modalities in the evaluation of pediatric Crohn's disease of the small bowel and colon. *Gastrointest Endosc*. 2016 May;83(5):975–83.
- 54 McCarty TR, Afinogenova Y, Njei B. Use of wireless capsule endoscopy for the diagnosis and grading of esophageal varices in patients with portal hypertension: a systematic review and meta-analysis. *J Clin Gastroenterol*. 2017 Feb;51(2):174–82.
- 55 Galmiche JP, Sacher-Huvelin S, Coron E, Cholet F, Soussan EB, Sebille V, et al. Screening for esophagitis and Barrett's esophagus with wireless esophageal capsule endoscopy: a multicenter prospective trial in patients with reflux symptoms. *Am J Gastroenterol*. 2008 Mar;103(3):538–45.

- 56 Schulmann K, Hollerbach S, Kraus K, Willert J, Vogel T, Moslein G, et al. Feasibility and diagnostic utility of video capsule endoscopy for the detection of small bowel polyps in patients with hereditary polyposis syndromes. *Am J Gastroenterol*. 2005 Jan;100(1):27–37.
- 57 Caspari R, von Falkenhausen M, Krautmacher C, Schild H, Heller J, Sauerbruch T. Comparison of capsule endoscopy and magnetic resonance imaging for the detection of polyps of the small intestine in patients with familial adenomatous polyposis or with Peutz-Jeghers' syndrome. *Endoscopy*. 2004 Dec;36(12):1054–9.
- 58 Rex DK, Adler SN, Aisenberg J, Burch WC Jr, Carretero C, Chowers Y, et al. Accuracy of capsule colonoscopy in detecting colorectal polyps in a screening population. *Gastroenterology*. 2015 May;148(5):948–57.e2.
- 59 Spada C, Hassan C, Galmiche JP, Neuhaus H, Dumonceau JM, Adler S, et al. Colon capsule endoscopy: European society of gastrointestinal endoscopy (ESGE) guideline. *Endoscopy*. 2012 May;44(5):527–36.
- 60 Kaminski MF, Thomas-Gibson S, Bugajski M, Bretthauer M, Rees CJ, Dekker E, et al. Performance measures for lower gastrointestinal endoscopy: a European society of gastrointestinal endoscopy (ESGE) quality improvement initiative. *Endoscopy*. 2017 Apr;49(4):378–97.
- 61 Cash BD, Fleisher MR, Fern S, Rajan E, Haithcock R, Kastenber DM, et al. Multi-centre, prospective, randomised study comparing the diagnostic yield of colon capsule endoscopy versus CT colonography in a screening population (the TOPAZ study). *Gut*. 2021 Nov;70(11):2115–22.
- 62 Parigi TL, Mastrococco E, Da Rio L, Allocca M, D'Amico F, Zilli A, et al. Evolution and new horizons of endoscopy in inflammatory bowel diseases. *J Clin Med*. 2022 Feb 7; 11(3):872.
- 63 Ferreira JPS, de Mascarenhas Saraiva MJDQEC, Afonso JPL, Ribeiro TFC, Cardoso HMC, Ribeiro Andrade AP, et al. Identification of ulcers and erosions by the novel Pillcam™ Crohn's capsule using a convolutional neural network: a multi-centre pilot study. *J Crohns Colitis*. 2022; 16(1):169–72.
- 64 Dray X, Iakovidis D, Houdeville C, Jover R, Diamantis D, Histace A, et al. Artificial intelligence in small bowel capsule endoscopy: current status, challenges and future promise. *J Gastroenterol Hepatol*. 2021 Jan; 36(1):12–9.