

Upper thoracic vertebral abnormalities in a patient with rheumatoid arthritis

Chang-Nam Son¹, Seok-Chol Jeon², Seunghun Lee², Kyung-Bin Joo², and Jae-Bum Jun³

¹Division of Rheumatology, Department of Internal Medicine, Keimyung University Dongsan Medical Center, Daegu; Departments of ²Radiology and ³Rheumatology, Hanyang University Hospital for Rheumatic Diseases, Seoul, Korea

Received: January 27, 2014

Revised : April 21, 2014

Accepted: April 30, 2014

Correspondence to
Jae-Bum Jun, M.D.

Tel: +82-2-2290-9216

Fax: +82-2-2298-8231

E-mail: junjb@hanyang.ac.kr

A 25-year-old female with a 3-year history of rheumatoid arthritis (RA) underwent a 3-dimensional volume-rendered computed tomography (CT) scan of the thoracic spine for further investigation of thoracic spine abnormalities incidentally discovered on a routine chest X-ray. Her height was 145 cm, and she was shorter than her siblings (two brothers and a sister). She had no neck pain or torticollis. Her neurological examination findings were unremarkable. Neither additional anomalies nor tendencies toward other similar anomalies were reported or seen in either her or other members of her

family. She had been previously treated with methotrexate, sulfasalazine, prednisolone, and nabumetone. A 3-dimensional volume-rendered CT scan revealed a small right supranumerary T2 hemivertebra with an extra rib and pedicle as well as segmentation failure at T1 to 5, resulting in thoracic scoliosis (Fig. 1). Segmentation defects of the vertebrae cause kyphosis and scoliosis, contributing to common health problems that present as back and neck pain, disability, cosmetic disfigurement, and functional distress. The etiologies of vertebral segmentation disorders are thought to

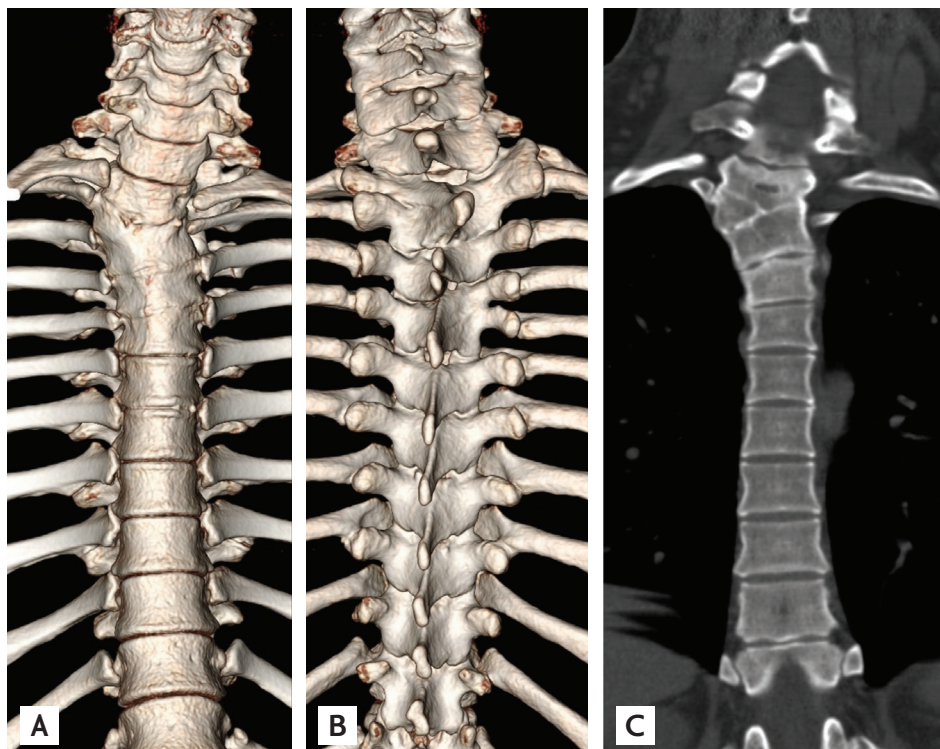


Figure 1. (A-C) A 3-dimensional volume-rendered computed tomography scan shows a small right supranumerary T2 hemivertebra with an extra rib and pedicle as well as segmentation failure at T1 to 5, resulting in thoracic scoliosis.

involve interactions between genetic and environmental factors. Recent studies have indicated that a periodic wave of gene expression, termed the “segmentation clock,” triggers the rhythmic production of segments in vertebrates. Our patient exhibited anterior failure of vertebral body formation (type 1) and a single vertebra of the posterior hemivertebrae; thus, her condition could be classified as (surgical/anatomical) congenital kyphosis/kyphoscoliosis.

She is being followed up and is not being considered for any treatment for the segmentation defects of her thoracic vertebrae.

Conflict of interest

No potential conflict of interest relevant to this article was reported.