

Research article

Min Bum Kim[#], Gil Chai Lim[#], Jin A Park, Yoo Suk Kim, Jeong Hong Kim, Ju Wan Kang^{*}

Computed tomography findings in patients with Samter's Triad: an observational study

<https://doi.org/10.1515/med-2019-0018>

received May 25, 2018; accepted January 14, 2019

Abstract: Samter's Triad is a disorder characterized by chronic rhinosinusitis (CRS) with nasal polyps (NPs), asthma, and intolerance to cyclooxygenase-1 inhibitors. However, there have been no studies investigating the prediction of Samter's Triad using imaging findings. Therefore, the authors aimed to investigate whether there is a difference in computed tomography (CT) findings between patients who have CRS with NPs and those with Samter's Triad. Patients were classified into a CRS group and a Samter group. Opacification was measured using data from CT scans by scoring each sinus on a numerical rating scale ranging from 0 to 4. The opacification scores of the ethmoid and frontal sinuses were significantly higher in the Samter's Triad group. Furthermore, Samter's Triad was more common in patients who scored ≤ 2 for maxillary opacification (7/16) than in those who scored ≥ 3 (4/45, $p=0.005$). Patients with Samter's Triad exhibited a tendency toward higher opacification scores for the ethmoid and frontal sinuses, with a relatively lower opacification score for the maxillary sinus. These findings could be helpful in distinguishing patients with Samter's Triad from those who have CRS with NPs, and to plan treatment strategies without having to perform additional laboratory or radiological tests.

Keywords: Samter; Nasal polyp; Chronic sinusitis; Computed tomography

***Corresponding author: Ju Wan Kang,** Department of Otorhinolaryngology, Jeju National University School of Medicine, 102 Jejudaehakno, Jeju 63243, South Korea, Tel: +82-64-717-1534, Fax: +82-64-717-1029, E-mail: juwankangmd@gmail.com

Min Bum Kim, Gil Chai Lim, Jin A Park, Yoo Suk Kim, Jeong Hong Kim, Department of Otorhinolaryngology, Jeju National University School of Medicine, Jeju, South Korea

Yoo Suk Kim, Department of Otolaryngology, Ajou University School of Medicine, Suwon, South Korea

[#]Both authors contributed equally to this work

1 Introduction

Samter's Triad, an aspirin-exacerbated respiratory disease (AERD), is a disorder characterized by chronic rhinosinusitis (CRS) with nasal polyposis, asthma, and intolerance to medications that inhibit the cyclooxygenase-1 (COX-1) enzyme. It has been reported that the prevalence of Samter's Triad among patients with CRS accompanied by nasal polyps (NPs) is approximately 16%, and that patients with Samter's Triad exhibit a tendency toward more severe rhinosinusitis [1]. In cases of CRS with NPs, medical treatments such as saline irrigation, administration of topical or systemic steroid(s), and administration of antibiotics, are recommended because they are designed to treat typical presentations of CRS. Additionally, sinus surgery can be recommended when there is insufficient response to medical treatment [2]. However, recurrences of NPs are frequently observed in patients with Samter's Triad, and a high percentage of these patients require revision surgeries [2]. Therefore, some authors have recommended that aspirin desensitization should be an additional treatment [3]. Aside from being needed to reduce refractoriness or frequent recurrence, confirming Samter's Triad among patients with CRS with NPs is critical because asthma and aspirin hypersensitivity can be life-threatening conditions [4]. Moreover, patients with Samter's Triad have worse disease than typical patients with CRS with NPs in the absence of nonsteroidal anti-inflammatory drugs (NSAIDs) [5].

Accurate diagnosis of AERD is needed for disease-tailored therapies; however, diagnosis based solely on clinical history may be insufficient [6]. CRS usually develops before asthma and is subsequently followed by aspirin intolerance [7,8]. It is difficult to suspect Samter's Triad in the absence of a history of asthma or aspirin intolerance. Some researchers have reported clinical and demographic differences, such as higher computed tomography (CT) scores, a greater number of sinus surgeries, lower age at the time of first surgery, and reduced lung function, in patients with Samter's Triad compared with patients with typical CRS with NPs [1]. Mascia et al reported that chronic eosinophilic rhinosinusitis may be a predictor of

AERD [9]. Therefore, characteristic CT findings of chronic eosinophilic rhinosinusitis could be used to differentiate Samter's Triad from typical CRS with NPs [10]. However, there have been no studies describing CT findings in patients with Samter's Triad. Therefore, this study aimed to determine whether there are any differences in CT findings between patients with CRS with NPs and patients with Samter's Triad.

2 Materials and methods

2.1 Subjects

The medical records and CT scans of patients who visited a tertiary medical center for CRS with NPs, and had undergone endoscopic sinus surgery in 2016, were reviewed. CRS and NPs were diagnosed using CT and nasal endoscopy. Diagnosis of asthma was confirmed on the basis of the results of pre- and post-bronchodilator pulmonary function tests. Aspirin intolerance was diagnosed on the basis of the patients' medication history using a questionnaire: e.g., have you ever had reactions (nasal congestion, runny nose, eye redness, wheezing, chest tightness, or rash of the skin) to any of the following medications (aspirin, ibuprofen, naproxen, or ketorolac)? Patients with tumorous conditions, such as inverted papilloma or malignancy, < 18 years of age, and those who had previously undergone sinus surgery were excluded. Ultimately, 61 patients with CRS with NPs, who had undergone CT scanning were enrolled. These patients were divided into 2 groups: CRS (those with CRS and NP, without a history of aspirin intolerance,

regardless of asthma); and Samter's Triad (those with CRS and NP, with a history of asthma and aspirin intolerance). The Institutional Review Board at the Jeju National University Hospital (Jeju, South Korea) approved this study. Written informed consent was obtained from all participants.

2.2 Opacification score of CT scans

All CT scans of the enrolled patients were reviewed and each sinus was scored using a numerical rating scale ranging from 0 to 4 (0: clear sinus; 1: sinus opacification < 25% of sinus; 2: sinus opacification 25% to 49% of sinus; 3: sinus opacification of 50% to 75% of sinus, and 4: sinus opacification > 75% of sinus). In the case of maxillary and ethmoid sinuses, sinus opacification was measured using the section of the CT scan that depicted the uncinate process most prominently. In the case of frontal and sphenoid sinuses, sinus opacification was measured using the section of the CT scan that depicted the largest part of each sinus.

2.3 Statistical analysis

Opacification scores of the CT scans demonstrated normal distribution after the Kolmogorov-Smirnov test. Therefore, differences in the scores of the CT scans were compared using the Student's t-test. The chi-squared test was used to compare differences in prevalence. All data were analyzed using SPSS version 17.0 (IBM Corporation, Chicago, IL, USA) for Windows (Microsoft Corporation, Redmond,

Table 1: Demographic data of study population

	CRS Group (n=50)	Samter Group (n=11)	P
Average age (yrs)	49.8 ± 17.42	52.37 ± 16.16	0.69
Proportion of female(%)	72	45.5	0.09
Opacification score			
Total	14.62 ± 7.42	19.82 ± 10.36	0.15
Maxillary sinus	4.72 ± 2.241	3.82 ± 3.401	0.417
Ethmoid sinus	4.80 ± 2.250	7.00 ± 1.949	0.004
Frontal sinus	2.92 ± 2.940	5.73 ± 2.453	0.005
Sphenoid sinus	2.18 ± 2.898	3.27 ± 3.744	0.288

WA, USA). A p-value of < 0.05 (two-tailed) was considered to be statistically significant.

3 Results

3.1 Demographic characteristics

The number of patients in the CRS and Samter groups were 50 and 11, respectively. In the CRS group, 3 of 50 patients had comorbid asthma. The mean (\pm standard deviation) age of the CRS group was 49.8 ± 17.42 years and that of the Samter group was 52.37 ± 16.16 years. Of the 61 patients, 41 (67.2%) were female. In the CRS group, 72% (36/50) of the patients were female, and in the Samter group 45.5% (5/11) were female. No statistical difference in age ($p=0.69$) or sex ($p=0.09$) was observed between the 2 groups (Table 1).

3.2 Opacification score

The average of the total summation of the CT scores of all patients was 15.56 ± 8.16 . The score was 14.62 ± 7.42 in the CRS group, and 19.82 ± 10.36 in the Samter group. There was no statistical difference ($p=0.15$) in the average CT scores of the 2 groups (Table 1). Comparison of each sinus between the groups revealed that the average score of maxillary sinuses was 4.72 ± 2.24 in the CRS group, and 3.82 ± 3.40 in the Samter group. The CRS group had a higher score than the Samter group; however, the difference was not statistically significant ($p=0.417$). In contrast, the scores for the ethmoid and frontal sinuses were significantly higher in the Samter group than in the CRS group. For the ethmoid sinuses, the score was 4.80 ± 2.25 in the CRS group and 7.00 ± 1.95 in the Samter group ($p=0.004$). For the frontal sinuses, the score was 2.92 ± 2.94 in the CRS group and 5.73 ± 2.45 in the Samter group ($p=0.005$). The Samter group exhibited a higher average score with respect to the sphenoid sinuses compared with the CRS group (2.18 ± 2.90 in CRS group versus 3.27 ± 3.74 in Samter group, $p=0.288$) (Figure 1); however, the difference was not statistically significant.

All subjects were divided according to their maxillary sinus opacification score: the first group included subjects who scored ≤ 2 ; and the second group included subjects who scored ≥ 3 . When the proportion of patients with Samter's Triad in both groups was analyzed (Figure 2), the proportion of patients with Samter's Triad (7/16) was significantly higher in the group that scored ≤ 2 for

maxillary opacification than in the group that scored ≥ 3 (4/45) ($p=0.005$).

Finally, the ratio of opacification score (maxillary sinus/ethmoid sinus) between Samter's patients and those with chronic sinusitis were compared. The mean value of ratio between maxillary sinus opacification score and ethmoid sinus opacification score in Samter's patients was 0.49 ± 0.12 . Furthermore, this value in Samter's patients was significantly different from that of patients with chronic sinusitis (1.20 ± 0.13 ; $p<0.016$).

4 Discussion

In the present study, patients with Samter's Triad exhibited more severe polyposis or inflammation in the ethmoid and frontal sinus than did patients with typical CRS with NPs. Furthermore, Samter's Triad was more common in patients with less severe maxillary inflammation. We speculate that this indicates that CT findings in patients with Samter's Triad exhibit severe polyposis/inflammation in the ethmoid sinus but a relatively preserved maxillary sinus (Supplemental Figure 1). These findings are similar to the characteristics of chronic eosinophilic rhinosinusitis. Sakuma et al suggested differential CT findings of chronic eosinophilic rhinosinusitis as: mean ethmoid sinus score ≥ 1 ; and mean ethmoid sinus score equal to or greater than mean maxillary sinus score using the Lund-Mackay scoring system [10]. Additionally, Mascia et al reported that chronic eosinophilic rhinosinusitis could be related to AERD [9].

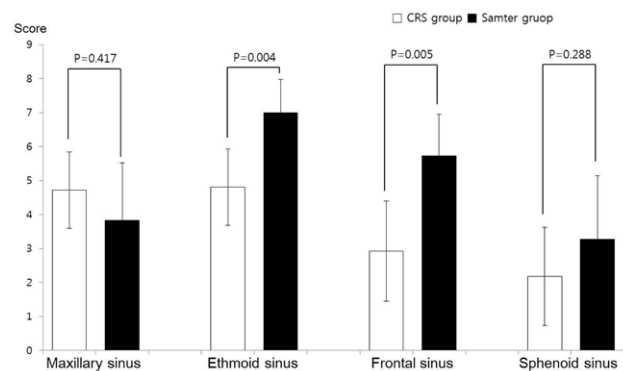


Figure 1: Average opacification scores of each sinus in the two groups

- 1) CRS group: patients with chronic rhinosinusitis with nasal polyp, without history of aspirin intolerance, regardless of asthma
- 2) Samter group: patients with chronic rhinosinusitis with nasal polyp, with history of asthma and aspirin intolerance

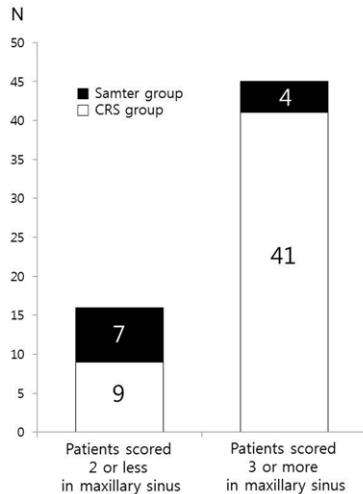


Figure 2: Comparison of proportions in the two groups divided according to opacification score of the maxillary sinus

- 1) CRS group: patients with chronic rhinosinusitis with nasal polyp, without history of aspirin intolerance, regardless of asthma
- 2) Samter group: patients with chronic rhinosinusitis with nasal polyp, with history of asthma and aspirin intolerance

Obstruction of the middle meatus or ostiomeatal unit (OMU) has been accepted as the fundamental pathophysiological mechanism of CRS. It blocks drainage from the maxillary sinus and results in inflammation of the involved sinuses. However, according to our results, this was not applicable to patients with Samter's Triad. We cannot discern the exact reason for the different findings observed in patients with Samter's Triad compared to those with typical chronic rhinosinusitis. However, a previous report by Snidvongs et al suggested that patients with chronic eosinophilic rhinosinusitis experience diffuse mucosal inflammation of the paranasal sinuses or often have a broader airway-wide inflammatory condition and, as such, diffuse disease is unlikely to be caused by an anatomical obstruction of the OMU [11].

The biological and pathological mechanisms that account for this difference are currently under investigation, and the dysregulation of arachidonic acid metabolism is considered to play an important role. Furthermore, increased levels of cysteinyl leukotrienes and expression of their receptors in the NPs of patients with AERD have been reported [12]. Laidlaw et al. reported that the numbers of platelets colocalizing with leukocytes in the NPs of patients with AERD was higher compared with those of patients with CRS with NPs alone [13]. These inflammatory changes in the broad respiratory mucosa of the sinonasal cavity may lead to diffuse nasal polyposis and rhinosinusitis that is not associated with obstruction of the OMU.

Patients with Samter's Triad usually require more extensive surgery and experience a higher recurrence rate of CRS and NPs after sinus surgery compared to those who have CRS with NPs alone [1]. Furthermore, sometimes other treatment modalities, such as aspirin desensitization, can be helpful [3]. It is critical to understand the typical characteristics of Samter's Triad for proper treatment and patient management because there may be a possibility of development of asthma or aspirin intolerance if CRS occurs.

However, performing a differential diagnosis before patients manifest the symptoms of asthma or aspirin sensitivity is exceedingly difficult. Only 15% of patients with Samter's Triad are aware of their diagnosis before an aspirin provocation test [3]. Therefore, some biomarkers, such as 24-h urinary leukotriene E₄ or exhaled nitric oxide, have been evaluated; however, there is no reliable *in vitro* diagnostic test for Samter's Triad [8]. Stevens et al. studied the clinical and demographic differences between patients with Samter's Triad and patients with typical CRS to distinguish these two conditions. They reported that patients with Samter's Triad exhibited higher CT scores, a greater number of sinus surgeries, lower age at the time of their first surgery, and reduced lung function than patients with usual CRS with NPs [1]. Based on the results of this study, we suggest that if CT scans of patients with CRS with NPs reveal the preservation of the maxillary sinus with an extensively involved ethmoid sinus, the possibility of Samter's Triad, and diagnostic tests for asthma or aspirin provocation test, should be considered.

This study had several limitations. First, diagnosis of Samter's Triad is challenging, and it is difficult to confirm the diagnosis of Samter's Triad before an aspirin provocation test. Previous studies have reported that up to 15% of patients who have a history of an NSAID-induced respiratory reaction exhibit a negative result in the aspirin provocation test [3]. In this study, we did not perform an aspirin provocation test for all subjects in the Samter's Triad group. Therefore, exact grouping of patients with Samter's Triad using aspirin provocation tests will be needed in future studies. Second, we should have considered acute exacerbation of chronic rhinosinusitis. During the course of chronic rhinosinusitis, patients experience waxing and waning of symptoms; therefore, we could not compare the same stage of disease progress or the same situation without acute exacerbation. Furthermore, we believed that this limitation could have affected our results of the comparison of the maxillary opacification score between patients with Samter's Triad and those with typical CRS with NPs. All patients with Samter's Triad with a maxillary opacification score ≥ 3 exhibited

total obstruction of all sinuses (Supplemental Figure 2). Therefore, the scores of patients with Samter's Triad could be higher than those of the patients with CRS with NPs, when we simply compared the opacification score of the maxillary sinus without consideration of opacification of other sinuses.

In conclusion, patients with Samter's Triad exhibited a tendency toward higher opacification scores for the ethmoid and frontal sinuses, and relatively lower opacification scores for the maxillary sinus, even though there were 4 patients with a fully opacified whole sinus in our study. We suggest that these findings could help differentiate patients with Samter's Triad from those who have CRS with NPs, which would facilitate the planning of treatment strategies without the need for additional laboratory or radiological tests.

Author contributions

J.W.K. and G.C.L. designed the research; M.B.K., J.A.P., J.H.K., and J.W.K. analyzed the data; M.B.K. and G.C.L. drafted the manuscript. G.C.L., J.H.K., Y.S.K., and J.W.K. revised the manuscript. J.W.K. had primary responsibility for final content. All authors read and approved the final manuscript.

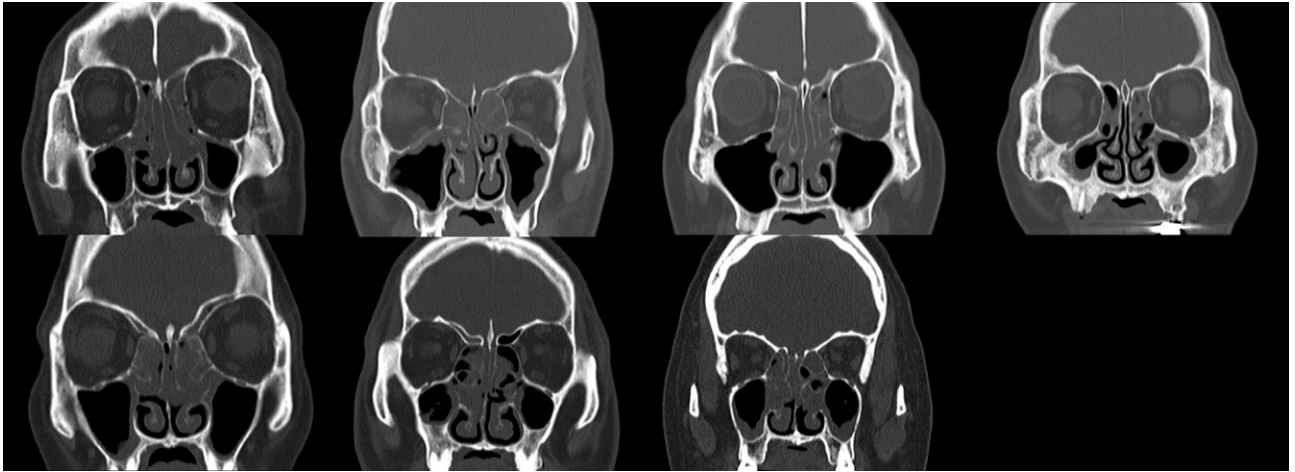
Source of funding

This work was supported by a research grant from Jeju National University Hospital development fund in 2016. The funders had no role in study design, data collection and analysis, decision to publish, or preparation of the manuscript.

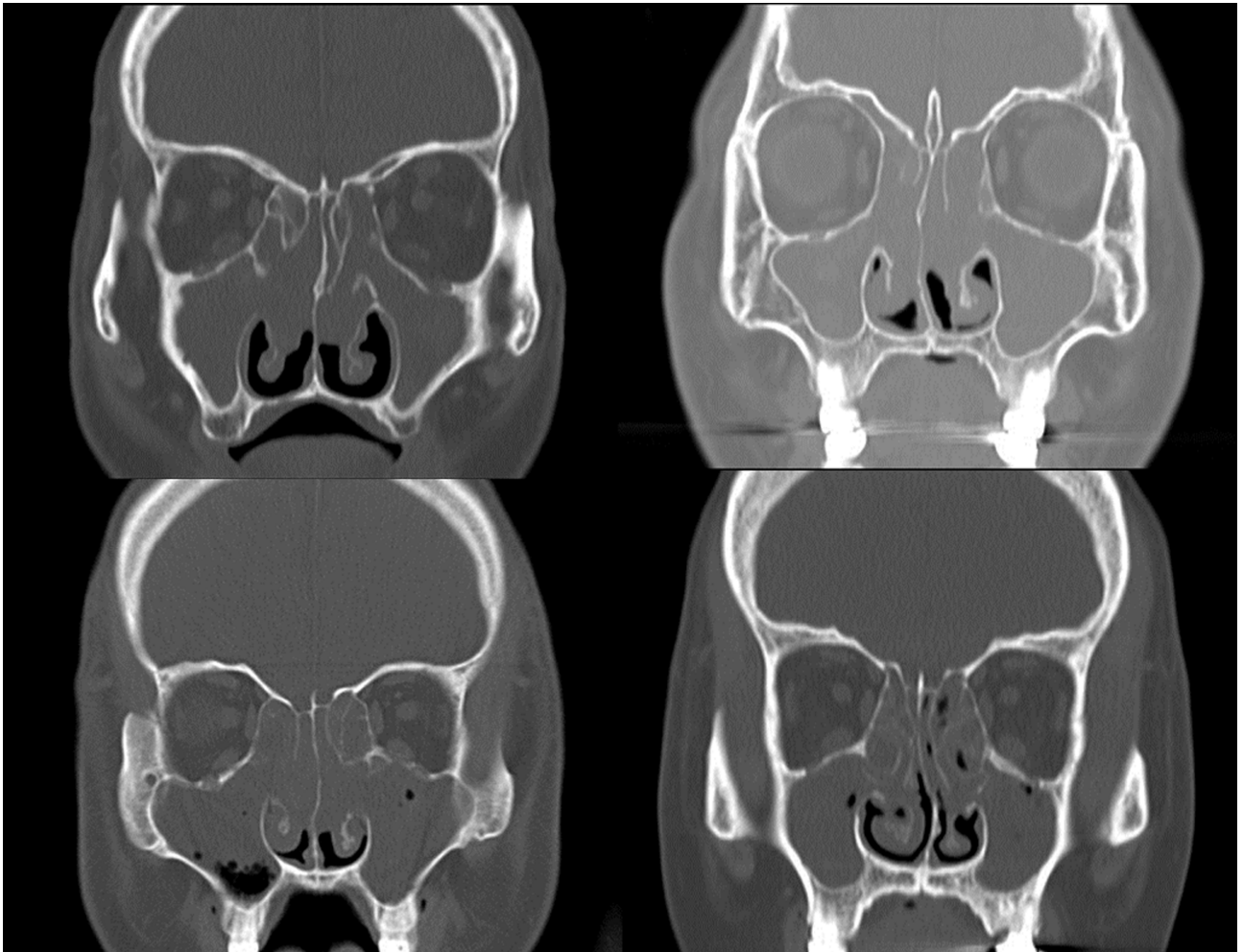
Conflict of interest statement: Authors state no conflict of interest

References

- [1] Stevens WW, Peters AT, Hirsch AG, et al. Clinical characteristics of patients with chronic rhinosinusitis with nasal polyps, asthma, and aspirin-exacerbated respiratory disease. *J Allergy Clin Immunol Pract* 2017;5:1061-1070.e3
- [2] Orlandi RR, Kingdom TT, Hwang PH, et al. International Consensus Statement on Allergy and Rhinology: Rhinosinusitis. *Int Forum Allergy Rhinol* 2016;6 Suppl 1:S22-209
- [3] Szczeklik A, Nizankowska E, Duplaga M. Natural history of aspirin-induced asthma. AIANE Investigators. European Network on Aspirin-Induced Asthma. *Eur Respir J* 2000;16(3):432-436
- [4] Ledford DK, Wenzel SE, Lockey RF. Aspirin or other nonsteroidal inflammatory agent exacerbated asthma. *J Allergy Clin Immunol Pract* 2014;2(6):653-657
- [5] Stevens WW, Schleimer RP. Aspirin-exacerbated respiratory disease as an endotype of chronic rhinosinusitis. *Immunol Allergy Clin North Am* 2016;36(4):669-680
- [6] Laidlaw TM, Cahill KN. Current knowledge and management of hypersensitivity to Aspirin and NSAIDs. *J Allergy Clin Immunol Pract* 2017;5(3):537-545
- [7] Adelman J, McLean C, Shaigany K, Krouse JH. The role of surgery in management of Samter's triad. *Otolaryngol Head Neck Surg* 2016;155(2):220-237
- [8] Kennedy JL, Stoner AN, Borish L. Aspirin-exacerbated respiratory disease: Prevalence, diagnosis, treatment, and considerations for the future. *Am J Rhinol Allergy* 2016;30(6):407-413
- [9] Mascia K, Borish L, Patrie J, Hunt J, Phillips CD, Steinke JW. Chronic hyperplastic eosinophilic sinusitis as a predictor of aspirin-exacerbated respiratory disease. *Ann Allergy Asthma Immunol* 2005;94(6):652-657
- [10] Sakuma Y, Ishitoya J, Komatsu M, et al. New clinical diagnostic criteria for eosinophilic chronic rhinosinusitis. *Auris Nasus Larynx* 2011;38(5):583-588
- [11] Snidvongs K, Chin D, Sacks R, Earls P, Harvey RJ. Eosinophilic rhinosinusitis is not a disease of ostiomeatal occlusion. *Laryngoscope* 2013;123(5):1070-1074
- [12] Stevens WW, Schleimer RP, Chandra RK, Peters AT. Biology of nasal polyposis. *J Allergy Clin Immunol* 2014;133(5):1503-1503.e1-4
- [13] Laidlaw TM, Kidder MS, Bhattacharyya N, et al. Cysteinyl leukotriene overproduction in aspirin-exacerbated respiratory disease is driven by platelet-adherent leukocytes. *Blood*. 2012;119(16):3790-379



Supplemental Figure 1: Computed tomography findings from patients with Samter's Triad. They are usually depicted as severe involvement of ethmoid sinuses with relative preservation of the maxillary sinuses.



Supplemental Figure 2: Computed tomography findings demonstrate total opacification of all sinuses in patients with Samter's Triad. We speculate that these findings are related to acute exacerbation or a progressed stage of sinusitis.