

Reduced intensity allogeneic stem cell transplant for treatment of blastic plasmacytoid dendritic cell neoplasm

Anand Lokare,¹ Emmanouil Nikolousis,² Neil Phillips,³ Zbigniew Rudzki,⁴ Richard Lovell,² Bhuvan Kishore,² Don Milligan,² Shankara Paneesha²

¹Hematology Department, University Hospital Walsgrave, Coventry;

²Hematology Department, Heart of England Hospital NHS Trust, Birmingham;

³Hematology Department, University Hospital North Staffordshire, Stoke on Trent, ⁴Histopathology Department, Heart of England NHS Trust, Birmingham, UK

Abstract

Blastic plasmacytoid dendritic cell neoplasm is a rare, aggressive tumor characterized by skin and/or marrow infiltration by CD4⁺ CD56⁺ cells. Historically, the tumor was variably thought to arise from either monocytes, T cells or NK cells giving rise to terms such as CD4⁺/CD56⁺ acute monoclonal leukemia, primary cutaneous CD4⁺/CD56⁺ hematodermic tumor and blastic NK-cell lymphoma. Whilst considerable progress has been made in understanding the histogenesis, the best modality of treatment remains to be defined. We are therefore reporting this case which was successfully treated with a T-deplete allogeneic transplant and the patient is currently alive and in remission 4 years post transplant.

Introduction

Blastic plasmacytoid dendritic cell neoplasm (BPDCN) is a rare, aggressive tumor characterized by skin and/or marrow infiltration by CD4⁺ CD56⁺ cells. Historically, the tumor was variably thought to arise from either monocytes, T cells or NK cells giving rise to terms such as CD4⁺CD56⁺ acute monoclonal leukemia, primary cutaneous CD4⁺/CD56⁺ hematodermic tumor and Blastic NK-cell lymphoma. It is now believed that these tumors arise from plasmablastic dendritic cells (also called type 2 dendritic cells, DC2) which have a major role to play in antiviral immunity.¹ Whilst considerable progress has been made in understanding the histogenesis, the best modality of treatment remains to be defined. Prognosis remains poor with median survival

of only a few months as the tumor exhibits a progressive course despite initial response to chemotherapy.

Case Report

We report a 62 year old retired postman with a Karnofsky score of 100, who presented in December 2008 with a 6 month history of a slowly growing, painless, discolored skin lesion on his upper back. Physical examination revealed a 4 cm nodular, raised bruise like lesion (Figure 1). There was no associated lymphadenopathy or hepatosplenomegaly. Initial investigations showed pancytopenia with a hemoglobin 12.1 g/mL, white cell count 1.7×10^9 /mL, platelets 96×10^9 /mL and neutrophils 0.5×10^9 /mL. Bone marrow was markedly hypercellular with a diffuse infiltrate of large atypical lymphoblastoid cells displaying prominent nuclear folding and scant eosinophilic cytoplasm (Figure 2). Immunophenotyping revealed a 73% clone of CD4⁺ CD56⁺ cells. Immunostaining of the bone marrow biopsy showed tumor cells to be positive for CD123, BDCA2, CD4, CD56, CD45, CD43, HLADR, CD33, and CD99. The cells were focally positive for CD117 and CD68R and negative for CD34, TdT, CD20, CD79a, CD3, CD5, CD2, CD7, CD8, CD57, CD30, myeloperoxidase, CD13, CD14, CD16, CD11c, CD163, perforin, granzyme B, and CD138. Ki-67 expression was seen in about 50% cells. *In situ* hybridization for Epstein-Barr virus encoded RNA (EBER) was negative. Based on these findings, a diagnosis of blastic plasmacytoid dendritic cell neoplasm was made.

The patient was treated with one course each of CODOX-M (cyclophosphamide, vincristine, doxorubicin and methotrexate) and IVAC (ifosfamide, etoposide and cytarabine) chemotherapy. He was in complete remission following this treatment with regression of the skin lesion and morphological and immunophenotypic remission in the bone marrow. As consolidation, he received a reduced intensity allogeneic stem cell transplant from a fully HLA matched unrelated donor. The patient was conditioned with fludarabine (30 mg/m^2 for 5 days), melphalan (140 mg/m^2 - single dose) and alemtuzumab (25 mg - 2 doses on days 2 and 1). Cyclosporin was used as graft *versus* host disease (GvHD) prophylaxis. Stem cell dose was 6×10^6 CD34 cells/kg and neutrophil engraftment (neut>0.5) occurred on D+14 while platelet engraftment occurred on D+20 (PLT>20 unsupported). He had grade II skin GvHD post transplant which responded to systemic steroids with complete resolution. Bone marrow assessment 3 months post-transplant confirmed continuing complete remission.

Correspondence: Emmanouil Nikolousis, Department of Hematology, Birmingham Heartlands Hospital, Bordesley Green East, Birmingham B9 5SS, UK.
Tel. +44.012.142.42704 - Fax: +44.012.176.67530.
E-mail: manos.nikolousis@heartofengland.nhs.uk

Key words: blastic plasmacytoid dendritic neoplasm, reduced intensity allograft, T-deplete.

Contributions: the authors contributed equally.

Conflict of interests: the authors declare no potential conflict of interests.

Received for publication: 8 October 2013.

Revision received: 1 December 2013.

Accepted for publication: 12 January 2014.

This work is licensed under a Creative Commons Attribution NonCommercial 3.0 License (CC BY-NC 3.0).

©Copyright A. Lokare et al., 2014
Licensee PAGEPress, Italy
Hematology Reports 2014; 6:5119
doi:10.4081/hr.2014.5119

He is currently well, alive and in remission 49 months from initial diagnosis (44 months post-transplant) with full donor chimerism in both whole blood and T cell compartments. Donor lymphocyte infusions were not administered at any stage post transplant.

Discussion

BPDCN is a disease of the elderly with 70% of the cases occurring in patients older than 50 years. 90% present with cutaneous *bruise-like* lesions or asymptomatic nodules/plaques. Associated nodal and splenic involvement is also well known. Peripheral blood and/or marrow involvement is seen in 60-90% patients with cytopenias being the commonest presentation.^{1,2} Marrow shows heavy infiltration with neoplastic cells which co-express CD4, CD56, CD45RA, CD43, CD303, and CLA,³ with varying expression of CD68, TdT, CD36, CD7 and HLADR. Expression of CD123 [Interleukin (IL)-3 receptor chain], and TCL1 (an AKT kinase regulator and lymphoid protooncogene), supports DC2 cell of origin.⁴ Complex karyotype is common with recurring abnormalities including deletions of 5q, 12q and 6q and loss of chromosomes 13, 15 and 9 as the 6.^{2,5} Skin biopsy typically reveals a dermal infiltrate with a periadnexal distribution. Differentiation from cutaneous T-cell lymphoma, cutaneous NK cell lymphoma and skin involvement by myelomonocyt-

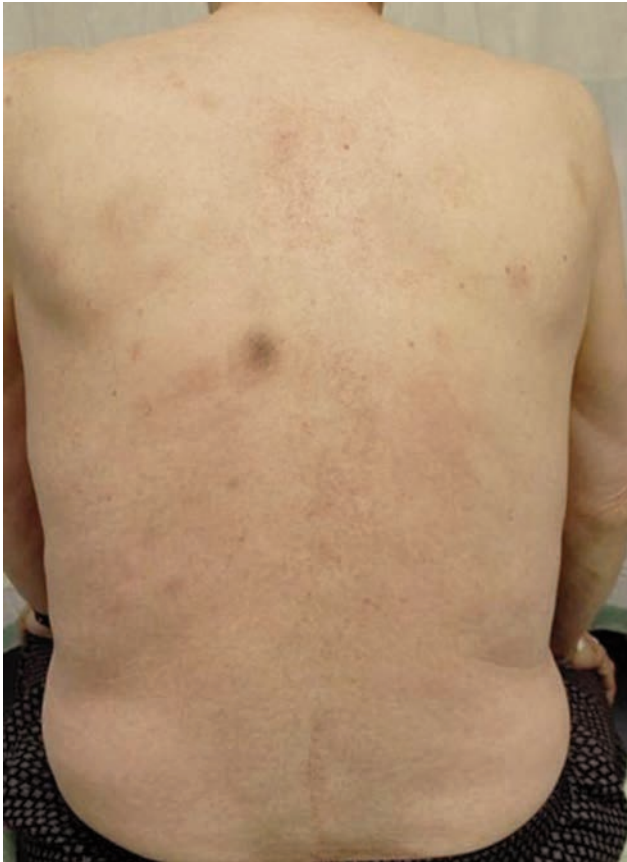

Figure 1. Bruise-like lesion on left side of thoracic vertebrae.

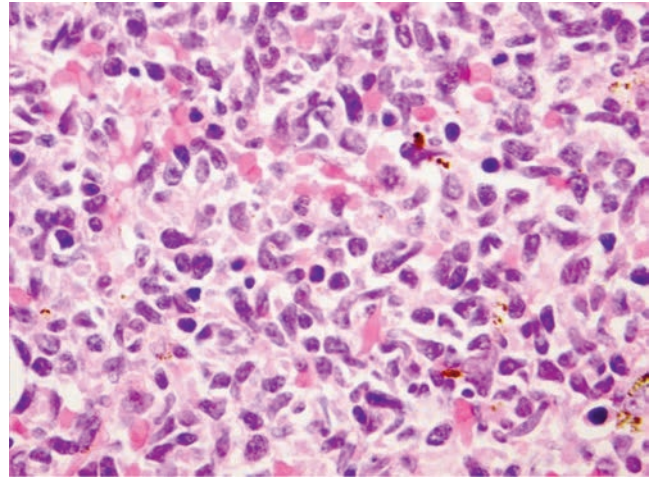


Figure 2. Bone marrow trephine showing medium sized cells with polymorphic, angulated nuclei with moderately basophilic chromatin and scant eosinophilic cytoplasm. Morphologically these cells resemble atypical lymphocytes. Mitoses are numerous (H&E, 63×).

ic leukemia is based on pattern of involvement, immunophenotype, T cell receptor (TCR) gene rearrangements and positivity for EBV. Some cases of BPDCN have relapsed with an acute myelomonocytic leukemia type clinical picture and the exact relationship between these diseases is not known.

Characteristically the tumor exhibits a progressive course despite initial response to variety of chemotherapy schedules, with a median time to progression of nine to 11 months and median survival of 13 months.¹ Feuillard *et al.* published the 1st large series of 23 patients with CD4⁺CD56⁺ malignancies treated with a variety of chemotherapy protocols. 86% patients achieved complete remission (CR) but most relapsed with a median time to relapse of 9 months. Three patients had an allogeneic transplant in 1st complete remission (CR), with one patient relapsing at 12 months.⁶ Patrella *et al.*⁷ and Reichard *et al.*⁸ published the 2 other big series with 30 and 10 cases respectively. In the first publication 75% of patients responded to radiotherapy and/or chemotherapy but 90% cases relapsed with median time to relapse being 11 months. Only 3 of the 30 patients were alive with median overall survival (OS) being 14 months. None of

the patients had an allogeneic transplant.¹ Reimer *et al.*⁹ evaluated 97 patients treated with either i) chemotherapy less intensive than CHOP, ii) CHOP and CHOP-like regimens, iii) regimens used for acute leukemia and iv) autologous stem cell transplantation. Of the 97 patients, six received an allogeneic stem cell transplant, four with TBI based conditioning. Only two of the six patients relapsed (with median OS of 38.5 months). In an age-adjusted evaluation, only allogeneic stem cell transplantation in first CR showed significant superiority in terms of overall survival to all other treatments in patients <60 years. Piccin *et al.*⁵ reported a patient who was successfully treated for BPDCN with a complex karyotype on an AML based regimen followed by an allogeneic stem cell transplant. In the pediatric setting Sakashita *et al.*¹⁰ reported a child with BPDCN treated with acute lymphoblastic leukemia-type regimen with skin and leukemic involvement followed by allogeneic stem cell transplant with a myeloablative protocol. In their review of 33 cases of pediatric BPDCN, the over survival was significantly lower in the patients with skin manifestation than those without cutaneous involvement and those patients with poor prognosis seemed

more likely to benefit from an allogeneic stem cell transplant in first remission which resembles the characteristics of our patients.

The first patient we could find in reported literature who had a non-myeloablative allogeneic stem cell transplant for BPDCN was reported by Amor *et al.*¹¹ We believe the patient we have reported in this review is the 2nd case treated with a reduced intensity conditioning Alemtuzumab based T-deplete conditioned allogeneic transplant. In light of our experience, reduced intensity T-deplete allogeneic stem cell transplant could be considered if age, performance status or comorbidities does not allow the use of a TBI based protocol. It appears a promising alternative in older patients with BPDCN and needs to be explored in future studies to improve the outcome in this disease.

References

1. Herling M, Jones D. CD4⁺/CD56⁺ hematodermic tumor. The features of an evolving entity and its relationship to dendritic cells. *Am J Clin Pathol* 2007;127:687-700.
2. Leroux D, Mugneret F, Callanan M, et al. CD4⁺, CD56⁺ DC2 acute leukemia is characterized by recurrent clonal chromosomal changes affecting 6 major targets: a study of 21 cases by the Groupe Français de Cytogénétique Hématologique. *Blood* 2002;99:4154-9.
3. Faceheti F, Jones DM, Petrella T. In: Swerdlow SH, Campo E, Harris N, et al, eds. WHO classification of tumours of haematopoietic and lymphoid tissues. 4th ed. Lyon: IARC Press; 2008.

4. Herling M, Teitell M, Shen R, et al. TCL1 expression in plasmacytoid dendritic cells (DC2s) and the related CD4+ CD56+ blastic tumors of skin. *Blood* 2003;101:5007-9.
5. Piccin A, Morello E, Svaldi M, et al. Post-transplant lymphoproliferative disease of donor origin, following haematopoietic stem cell transplantation in a patient with blastic plasmacytoid dendritic cell neoplasm. *Hematol Oncol* 2012;30:210-3.
6. Feuillard J, Jacob MC, Valensi F, et al. Clinical and biologic features of CD4(+)/CD56(+) malignancies. *Blood* 2002;99:1556-63.
7. Petrella T, Bagot M, Willemze R, et al. Blastic NK-cell lymphomas (agranular CD4+CD56+ hematodermic neoplasms): a review. *Am J Clin Pathol* 2005;123:662-75.
8. Reichard KK, Burks EJ, Foucar MK, et al. CD4(+) CD56(+) lineage-negative malignancies are rare tumors of plasmacytoid dendritic cells. *Am J Surg Pathol* 2005;29:1274-83.
9. Reimer P, Rudiger T, Kraemer D, et al. What is CD4+CD56+ malignancy and how should it be treated? *Bone Marrow Transplant* 2003;32:637-46.
10. Sakashita K, Saito S, Yanagisawa R, et al. Usefulness of allogeneic hematopoietic stem cell transplantation in first complete remission for pediatric blastic plasmacytoid dendritic cell neoplasm with skin involvement: a case report and review of literature. *Pediatr Blood Cancer* 2013;60:E140-2.
11. Amor R B, Hicheri Y, Pautas C, et al. Successful non-myeloablative allogeneic HLA-identical stem cell transplantation for CD4/CD56 positive acute leukemia. *Transplantation* 2007;84:1066-7.