

This is an Open Access article licensed under the terms of the Creative Commons Attribution-NonCommercial-NoDerivs 3.0 License (www.karger.com/OA-license), applicable to the online version of the article only. Distribution for non-commercial purposes only.

Blastocystis hominis and *Endolimax nana* Co-Infection Resulting in Chronic Diarrhea in an Immunocompetent Male

Mitanshu Shah^a Christopher Bryan Tan^a Dhyan Rajan^a
Shadab Ahmed^b Krishnaiyer Subramani^c Kaleem Rizvon^c
Paul Mustacchia^c

Departments of ^aInternal Medicine, ^bInfectious Diseases and ^cGastroenterology, Nassau University Medical Center, East Meadow, N.Y., USA

Key Words

Blastocystis hominis · *Endolimax nana* · Co-infection · Chronic diarrhea

Abstract

Blastocystis hominis and *Endolimax nana* exist as two separate parasitic organisms; however co-infection with the two individual parasites has been well documented. Although often symptomatic in immunocompromised individuals, the pathogenicity of the organisms in immunocompetent subjects causing gastrointestinal symptoms has been debated, with studies revealing mixed results. Clinically, both *B. hominis* and *E. nana* infection may result in acute or chronic diarrhea, generalized abdominal pain, nausea, vomiting, flatulence and anorexia. We report the case of a 24-year-old immunocompetent male presenting with chronic diarrhea and abdominal pain secondary to *B. hominis* and *E. nana* treated with metronidazole, resulting in symptom resolution and eradication of the organisms. Our case illustrates that clinicians should be cognizant of both *B. hominis* and *E. nana* infection as a cause of chronic diarrhea in an immunocompetent host. Such awareness will aid in a timely diagnosis and possible parasitic eradication with resolution of gastrointestinal symptoms.

Introduction

Blastocystis hominis and *Endolimax nana* are two intestinal parasitic organisms that are distributed worldwide with a higher prevalence in tropical and sub-tropical climates. Co-infection of these organisms occurs due to their identical mode of transmissions, via the fecal-oral route and ingestion of cysts from contaminated water

supplies. When ingested, these parasites are commonly reported to be pathogenic in immunocompromised individuals, resulting in a milieu of gastrointestinal symptoms ranging from mild abdominal pain and flatulence to acute and sometimes chronic diarrhea. Despite these organisms' role in immunocompromised individuals, their pathogenicity in immunocompetent individuals is debatable. Diagnosis of the infectious agents is made through stool analysis for ova and parasites. Stool specimens are examined for cysts by light microscopy after wet mount preparation, trichrome staining and formal-ethyl acetate concentration. We report the case of a recently emigrated 24-year-old male with chronic diarrhea and abdominal pain secondary to *B. hominis* and *E. nana*, which resolved with parasitic eradication.

Case Report

A 24-year-old male who had recently emigrated from El Salvador presented to the clinic with complaints of diffuse abdominal pain and diarrhea for the past 6 weeks. He stated that 6 weeks before he had begun noticing diffuse, intermittent abdominal pain that was neither relieved nor aggravated by any factors. He described the pain as sharp, and stated that episodes would last approximately 30 min before resolving by themselves. The patient also stated that for nearly 6 weeks, he had been having diarrhea, described as 4–5 loose bowel movements daily. He described the diarrhea as large-volume, watery, brown stool, which was non-bloody and void of mucus. He denied any unintentional weight loss, nausea, vomiting, intermittent constipation, melena, hematemesis, fevers or chills. He also denied any recent travel, sick contacts, changes in dietary habits or any recent antibiotic use.

Past medical and surgical history was unremarkable and family history was not significant, including the absence of any malignancy or gastrointestinal disorders. He denied the use of any tobacco, alcohol or recreational drugs and stated that he was taking no medications at home. He stated that he had never had sexual intercourse before and had never received blood transfusions. As part of a routine physical and laboratory examination prior to arrival in the United States 8 weeks earlier, purified protein derivative testing for tuberculosis and screening for human immunodeficiency virus had yielded negative results.

Physical examination revealed a well-built male in mild distress. Examination of the oral mucosa was significant for dry mucosal membranes, with no evidence of oral thrush. Abdominal examination was remarkable for mild epigastric tenderness without guarding, rebound tenderness or rigidity. Digital rectal examination was performed without evidence of overt bleeding. Laboratory evaluation including a complete blood count, comprehensive metabolic panel, thyroid stimulating hormone and coagulation panel were all within normal limits. Fecal occult blood testing was negative, as was testing for *Helicobacter pylori* stool antigen. Stool cultures were negative for bacterial or viral pathogens. Stool examination for ova and parasites performed was positive for *B. hominis* ([fig. 1](#)) and *E. nana* ([fig. 2](#)) species.

Given the diarrheal symptoms along with the apparent co-infection of *B. hominis* and *E. nana*, the patient was started on a course of 500 mg of metronidazole to be taken 3 times a day for 10 days. The patient was advised to return to the clinic in 14 days to re-evaluate symptomatology after a 10-day course of antibiotics directed towards *B. hominis* and *E. nana* eradication. When the patient returned to the clinic, he stated complete resolution of both abdominal pain and diarrhea. Physical examination performed was unremarkable and the patient appeared comfortable and in no acute distress. A repeat stool examination for ova and parasites was negative for *B. hominis* and *E. nana* in three separate stool samples, and the patient now continues to be symptom-free.

Discussion

B. hominis is single-celled protozoan intestinal parasite that is a member of the Blastocystis genus of Stramenopiles, which includes water molds, algae and diatoms. The *B. hominis* cysts are usually round, measuring 6–40 μm , with a large vacuole and absence of an internal nuclear structure; however the vacuole itself is bordered by numerous nuclei. The organism reproduces through binary fission and pseudopod extension and retraction [1]. *B. hominis* itself has an equal geographic distribution worldwide, however its clinical relevance in contributing to gastrointestinal symptomatology appears more in underdeveloped nations in tropical or sub-tropical climates [2]. The clinical prevalence in underdeveloped nations may be secondary to the organism's mode of transmission, as fecal-oral, water-borne (contaminated water) and food-borne (raw foods) vectors have been reported as the most likely sources. Pathogenicity occurs with ingestion of mature cysts leading to lysis of gut epithelium and secretion of diarrheagenic toxins [3].

E. nana is an amoeboid organism found in the intestines of humans and other animals. Cysts of *E. nana* are usually oval or round, measuring 5–10 μm in diameter [1]. Their properties include hyaline pseudopodia, which result in sluggish motility of the organisms. The cytoplasm of the organism is vacuolated and may or may not contain bacteria. *E. nana* is also known to have a worldwide distribution, with predominance in tropical regions and an equivalent mode of transmission as *B. hominis*. Gastrointestinal symptoms from *E. nana* occur from mature cyst ingestion and subsequent irritation of the intestinal mucosal crypts leading to fibrosis [2].

Although both *B. hominis* and *E. nana* exist as two separate parasitic organisms, co-infection with the two individual parasites has been well documented. One postulated reason for the high rates of this parasitic co-infection includes their identical mode of transmission. Poorly sanitized living conditions and unhygienic food and water sources allow one to be vulnerable to polyparasitic infiltration [4]. In a study by Lu and Sung [5], an immigrant population in northeastern Taiwan had stool studies performed to obtain evidence of *B. hominis* infiltration, along with the possibility of polyparasitic infection. The investigation concluded that over 20% of stool samples obtained were positive for polyparasitism, with nearly 79% of those individuals having evidence of *B. hominis* and a subsequent parasite transmitted via the fecal-oral mode such as *E. nana*. The study suggested that due to lower socioeconomic status and poor hygiene standards, these intestinal parasites had high rates of co-infection. Another suggested mechanism for polyparasitism includes intestinal susceptibility that occurs when the intestinal lumen is initially infested. Initial mucosal irritation and inflammation from parasitic infiltration may allow other parasitic organisms to infiltrate the gastrointestinal tract [2, 3]. Finally, it is thought that the incidence of polyparasitic infection may be directly proportional to the immune status of the affected individual.

B. hominis and *E. nana* have been reported as common pathogens in cases of acute or chronic diarrhea in immunocompromised patients [1, 2, 6]. For several years, *B. hominis* and *E. nana* have been reported to cause gastrointestinal symptoms in patients infected with the human immunodeficiency virus and those with acquired immunodeficiency syndrome. The severity of gastrointestinal symptoms in these individuals varied, as those patients with a severely compromised host immune status

appeared to have persistent and unremitting symptoms [7]. Patients with chronic renal insufficiency on hemodialysis are known to be immunocompromised, thus these patients appear to be susceptible to *B. hominis* and *E. nana* infection. In a study by Kulik et al. [2], patients with chronic renal insufficiency on hemodialysis with associated diarrhea were studied for parasitic prevalence. On stool samples, *B. hominis* and *E. nana* organisms were found in 20 and 16%, respectively, with co-infection occurring in 21% of the patients sampled. The study concluded that these organisms were pathogenic in uremic patients with diarrhea if other causes of diarrhea had been ruled out, emphasizing a need for parasitic eradication in these individuals.

In underdeveloped countries, *B. hominis* and *E. nana* have been reported in high prevalence as causes of acute diarrhea in children. This is likely due to immature immune systems along with poor sanitized conditions. In a study by Graczyk et al. [3], stool samples from school-aged children with diarrhea in Zambia were taken for testing. The samples were negative for bacterial and viral enteropathogens, however they were positive for *B. hominis* and *E. nana* (53.8 and 63.4%, respectively) and co-infection with both parasites in 43%. The study concluded a significant association between the parasites and diarrhea. Similar rates of infection were also reported in studies from Argentina, Chile, Kuwait, Thailand and Venezuela [8–12]. Although the pathogenicity of *B. hominis* and *E. nana* has been well reported in the literature regarding immunocompromised hosts, its clinical relevance in immunocompetent individuals is not clear.

In healthy individuals, the prevalence of *B. hominis* and *E. nana* is 10–15% worldwide, with higher rates in underdeveloped countries [7]. The pathogenicity of the organisms causing gastrointestinal symptoms in immunocompetent subjects has been debated, with studies revealing mixed results. In a 2-year study of enteropathogens associated with acute diarrhea, Oyoyo et al. [4] concluded that *B. hominis* and *E. nana* were indeed the cause of gastrointestinal symptomatology in a significant portion of immunocompetent individuals. To the contrary, Leder et al. [13] presented *B. hominis* positivity on stool samples to be equivalent in symptomatic and asymptomatic patients who were both immunocompetent and immunosuppressed, suggesting that the organisms may not be pathogenic, regardless of host immune status. Various case reports have argued the pathogenicity of these parasites as causes of gastrointestinal symptoms, and consensus guidelines regarding the approach to immunocompetent patients with or without symptoms have yet to be established [14, 15].

Clinically, both *B. hominis* and *E. nana* infection may result in acute or chronic diarrhea, generalized abdominal pain, nausea, vomiting, flatulence and anorexia. Complications from chronic diarrhea can be serious and sometimes fatal and may include dehydration, malnutrition and metabolic acidosis. Diagnosis of both *B. hominis* and *E. nana* infection can be made via stool sample testing for ova and parasites. Stool specimens are examined through light microscopy by direct wet mount, trichrome stains and formal-ethyl acetate concentration. Infectivity is classified by identification and quantification of *B. hominis* cysts and *E. nana* cysts and trophozoites present in stool specimens [1, 16–18]. Enzyme-linked immunosorbent assay for serum antibodies and polymerase chain reaction techniques can also be used for diagnosis, however availability is limited and appears to not be cost-effective.

The Centers for Disease Control and Prevention (CDC) has listed *B. hominis* as a 'common' intestinal parasite found throughout the world that may or may not induce gastrointestinal symptoms. The CDC recommends routine testing of stool ova and parasites in anyone with acute or chronic diarrhea, and suggests treatment of *B. hominis* if other causes of diarrhea have been ruled out. Unlike *B. hominis*, *E. nana* is labeled as non-pathogenic intestinal protozoa by the CDC in both immunocompetent and immunosuppressed individuals, not warranting treatment if the parasite is isolated in stool analysis. Despite the recommendations of the CDC, few case reports have concluded that treatment and eradication of *E. nana* in patients with diarrhea resulted in complete resolution of symptoms. It should be mentioned however that in a patient with co-infection of both *B. hominis* and *E. nana*, treatment aimed at eradication of both parasites is not specified [19, 20].

Metronidazole has been shown to be an effective treatment option for both *B. hominis* and *E. nana* infection. Case reports have suggested the efficacy of metronidazole in both clearance of organisms from stool samples and resolution of symptoms [17, 20]. Nitazoxanide and trimethoprim-sulfamethoxazole have also been reported to be effective in cases of metronidazole resistance [6, 16, 20]. Clearance of the organisms is determined with three separate negative stool samples. Patients with resolution of symptoms but persistent positive tests are known as asymptomatic carriers of the organisms, a title which currently appears to bear no clinical significance.

Conclusion

B. hominis and *E. nana* are intestinal parasites that have been shown to cause gastrointestinal symptoms in both immunocompetent and immunocompromised hosts. Although the pathogenicity of both parasites is debatable, our case illustrates that one should be cognizant of potential eradication of such organisms if found in the setting of chronic diarrhea. By the same token, we believe clinicians should be aware that these organisms may be non-pathogenic in immunocompetent individuals, and other causes of chronic diarrhea should be investigated if symptoms persist despite parasitic eradication after treatment.

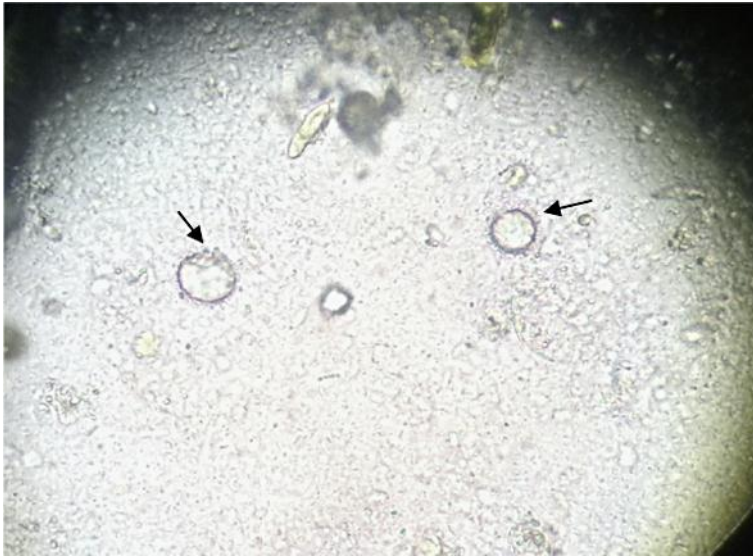


Fig. 1. Stool specimen, wet mount preparation (high-power field, 40× magnification). Note the *B. hominis* cyst with a large vacuole and the absence of internal nuclear structure (arrows).

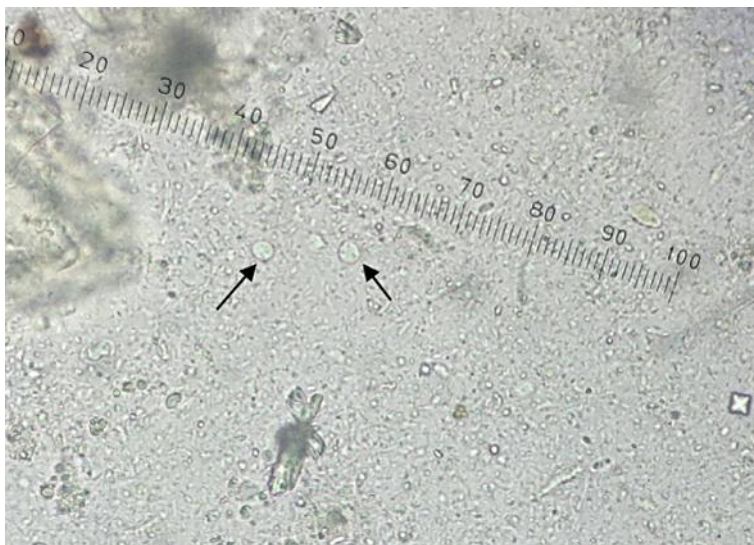

Fig. 2. Stool specimen, wet mount preparation (high-power field, 40× magnification). Note the presence of the multinucleated cyst of *E. nana* measuring 5–6 μm (arrows).

References

- 1 Stool: *Endolimax nana* and *Blastocystis hominis*. Enteric parasitology, clinical microbiology proficiency testing. 2007. www.cmpt.ca (retrieved March 5, 2012).
- 2 Kulik RA, Falavigna DL, Nishi L, Araujo SM: *Blastocystis* sp. and other intestinal parasites in hemodialysis patients. *Braz J Infect Dis* 2008;12:338–341.
- 3 Graczyk TK, Shiff CK, Tamang L, Munsaka F, Beitin AM, Moss WJ: The association of *Blastocystis hominis* and *Endolimax nana* with diarrheal stools in Zambian school-age children. *Parasitol Res* 2005;98:38–43.
- 4 Oyofa BA, Subekti D, Tjaniadi P, Machpud N, Komalarini S, Setiawan B, Simanjuntak C, Punjabi N, Corwin AL, Wasfy M, Campbell JR, Lesmana M: Enteropathogens associated with acute diarrhea in community and hospital patients in Jakarta, Indonesia. *FEMS Immunol Med Microbiol* 2002;34:139–146.
- 5 Lu CT, Sung YJ: Epidemiology of *Blastocystis hominis* and other intestinal parasites among the immigrant population in northeastern Taiwan by routine physical examination for residence approval. *J Microbiol Immunol Infect* 2009;42:505–509.
- 6 Carvalho-Costa FA, Gonçalves AQ, Lassance SL, de Albuquerque CP, Leite JP, Bóia MN: Detection of *Cryptosporidium* spp and other intestinal parasites in children with acute diarrhea and severe dehydration in Rio de Janeiro. *Rev Soc Bras Med Trop* 2007;40:346–348.
- 7 Derouin F, Lagrange-Xelot M: Treatment of parasitic diarrhea in HIV-infected patients. *Expert Rev Anti Infect Ther* 2008;6:337–349.
- 8 Navarrete N, Torres P: Prevalence of infection by intestinal helminthes and protozoa in school children from a coastal locality in the province of Valdivia, Chile. *Bol Chil Parasitol* 1994;49:79–80.
- 9 Guignard S, Arienti H, Freyre L, Lujan H, Rubinstein H: Prevalence of enteroparasites in a residence for children in the Córdoba Province, Argentina. *Eur J Epidemiol* 2000;16:287–293.
- 10 Saksirisampant W, Nuchprayoon S, Wiwanitkit V, Yenthakam S, Ampavasiri A: Intestinal parasitic infestations among children in an orphanage in Pathum Thani province. *J Med Assoc Thai* 2003;86 (suppl 2):S263–S270.
- 11 Rivero-Rodríguez Z, Chourio-Lozano G, Diaz I, Cheng R, Rucsón G: Intestinal parasites in school children at a public institution in Maracaibo municipality, Venezuela. *Invest Clin* 2000;41:37–57.
- 12 Iqbal J, Hira PR, Al-Ali F, Philip R: Cryptosporidiosis in Kuwaiti children: seasonality and endemicity. *Clin Microbiol Infect* 2001;7:261–266.
- 13 Leder K, Hellard ME, Sinclair MI, Fairley CK, Wolfe R: No correlation between clinical symptoms and *Blastocystis hominis* in immunocompetent individuals. *J Gastroenterol Hepatol* 2005;20:1390–1394.
- 14 Doyle PW, Helgason MM, Mathias RG, Proctor EM: Epidemiology and pathogenicity of *Blastocystis hominis*. *J Clin Microbiol* 1990;28:116–121.
- 15 Sheehan DJ, Raucher BG, McKittrick JC: Association of *Blastocystis hominis* with signs and symptoms of human disease. *J Clin Microbiol* 1986;24:548–550.
- 16 Nigro L, Larocca L, Massarelli L, Patamia I, Minniti S, Palermo F, Cacopardo B: A placebo controlled treatment trial of *Blastocystis hominis* infection with metronidazole. *J Travel Med* 2003;10:128–130.
- 17 Zierdt CH: *Blastocystis hominis* – past and future. *Clin Microbiol Rev* 1991;4:61–79.
- 18 Suresh K, Smith H: Comparison of methods for detecting *Blastocystis hominis*. *Eur J Clin Microbiol Infect Dis* 2004;23:509–511.
- 19 Centers for Disease Control and Prevention (CDC): Intestinal amoeba, parasites and health, laboratory identification of parasites of public health concern. Last modified August 8, 2009. www.dpd.cdc.gov (retrieved March 8, 2012).
- 20 Stauffer JQ, Levine WL: Chronic diarrhea related to *Endolimax nana*: response to treatment with metronidazole. *Am J Dig Dis* 1974;19:59–63.