

# Multipolar catheter entrapment in a mechanical mitral valve and successful retrieval of a sheared spine straying into the coronary artery



Chisa Asahina, MD,\* Satoshi Nagase, MD, PhD,<sup>†</sup> Masashi Fujino, MD, PhD,\*  
Yasuhide Asami, MD, PhD,\* Teruo Noguchi, MD, PhD,\* Kengo Kusano, MD, PhD, FHRS\*

From the \*Department of Cardiovascular Medicine, National Cerebral and Cardiovascular Center, Suita, Japan, and <sup>†</sup>Department of Advanced Arrhythmia and Translational Medical Science, National Cerebral and Cardiovascular Center, Suita, Japan.

## Introduction

High-density mapping is currently mandatory for catheter ablation of complex atrial tachycardia (AT) and atrial fibrillation (AF), especially after cardiac surgery. There is, however, concern that multipolar catheters for high-density mapping can be entrapped in the mechanical valve owing to structural problems, and several cases of entrapped catheters have been reported.<sup>1–5</sup> To date, there have been no reports of a PentaRay mapping catheter being entrapped, being sheared, and then straying into the coronary artery. Here, we describe a complex AT case after mitral valve (MV) replacement and the maze procedure in which a PentaRay catheter spine was successfully retrieved from a coronary artery following entrapment in the mechanical MV and rupture of the spine (detailed video clips are included as [Supplemental Material](#)).

## Case report

A 72-year-old woman with a mechanical bileaflet MV (St. Jude Medical, St. Paul, MN; 29 mm) underwent catheter ablation for AT. The patient had undergone MV replacement for mitral stenosis and regurgitation at the age of 43. During the operation, the maze procedure and left atrial appendage resection were added because of her previous history of AF. Ten years after surgery, several types of ATs appeared. Antiarrhythmic drugs failed to maintain her sinus rhythm, and repeated electrical cardioversions were required owing to worsening heart failure caused by ATs. Preoperative

**KEYWORDS** Catheter ablation; Atrial tachycardia; Atrial fibrillation; High-density mapping; Mechanical valve; PentaRay; Entrapment (Heart Rhythm Case Reports 2023;9:8–11)

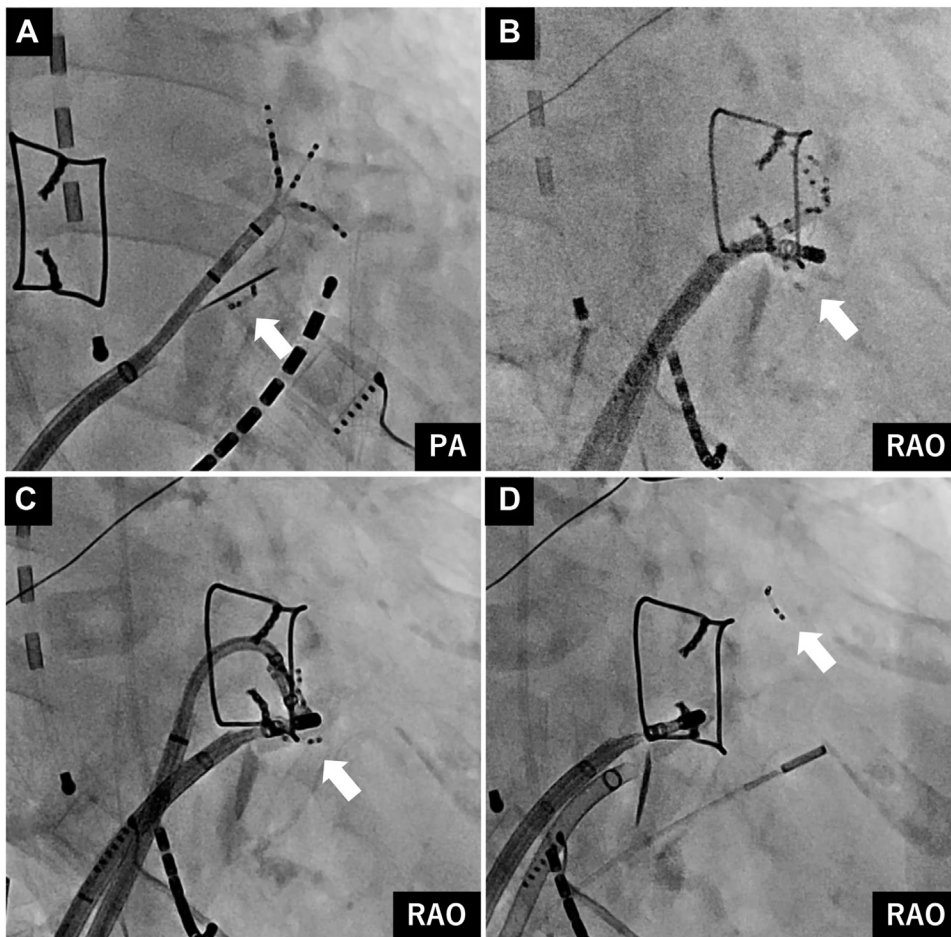
Funding Sources: None. Disclosures: Dr Satoshi Nagase is affiliated with a department endowed by Japan Medtronic Inc. The remaining authors have nothing to disclose. **Address reprint requests and correspondence:** Dr Satoshi Nagase, Department of Advanced Arrhythmia and Translational Medical Science, National Cerebral and Cardiovascular Center, 6-1 Kishibe-shinmachi, Suita, Osaka 564-8565, Japan. E-mail address: [snagase@ncvc.go.jp](mailto:snagase@ncvc.go.jp).

## KEY TEACHING POINTS

- The PentaRay catheter (Biosense Webster, Diamond Bar, CA) is essential for the treatment of complex arrhythmias, as it allows rapid and accurate mapping, but the risk of entrapment and subsequent shearing of spines must always be considered in patients with mechanical valves.
- Sheared spines can stray into critical blood vessels, and it is important to find and retrieve them quickly.
- Teamwork and the provision of specialized equipment for the rapid recovery of sheared spines are essential.
- Because embolisms caused by a torn spine in the coronary or intracranial artery can lead to serious outcomes, there is some debate as to whether to attempt release by catheter manipulation or to perform emergency open chest surgery in such cases.

echocardiography showed that the bileaflet prosthetic function remained normal.

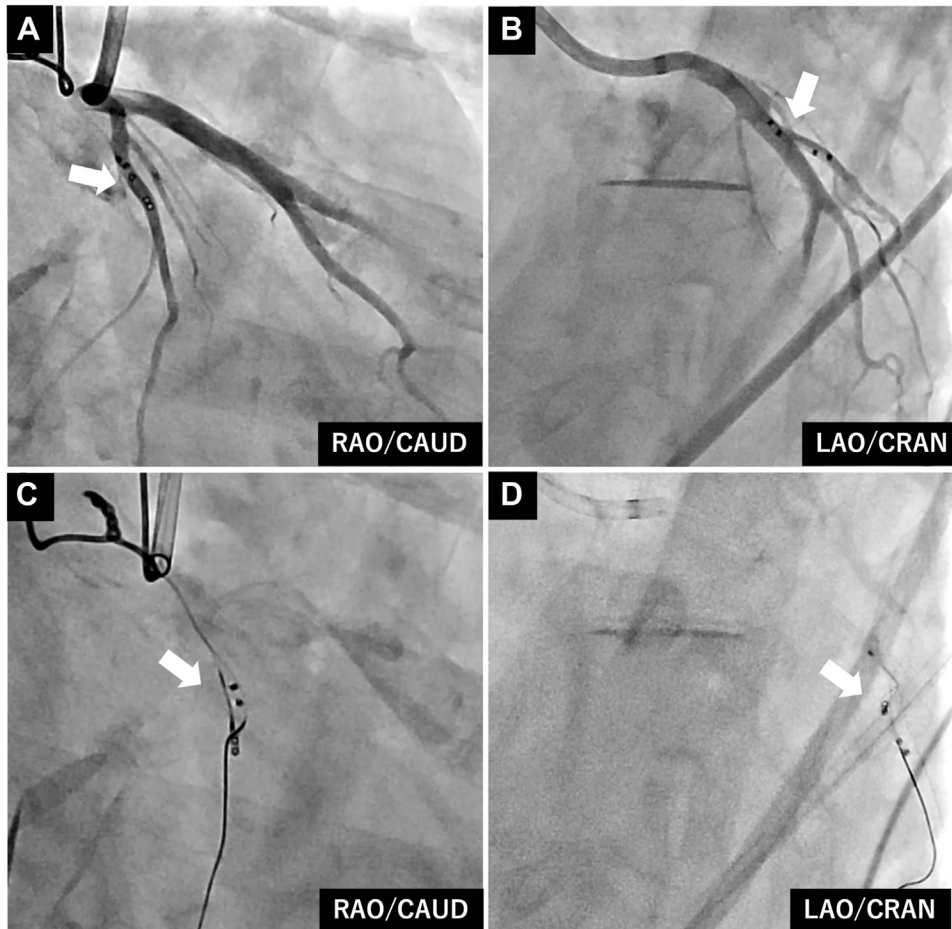
After intracardiac clots were excluded by transesophageal echocardiography, the procedure was performed under intravenous anesthesia. Three-dimensional electroanatomical mapping (CARTO 3, version 7; Biosense Webster, Diamond Bar, CA) using a multipolar catheter (PentaRay; Biosense Webster) and radiofrequency application using an ablation catheter (ThermoCool SmartTouch SF; Biosense Webster) were performed. PentaRay mapping demonstrated that induced ATs were macroreentry-associated, with the incision line in the right atrium, and radiofrequency applications were applied to create a complete conduction block across the critical isthmuses. Because we could not completely rule out the



**Figure 1** Fluoroscopic images. **A:** Fluoroscopic images of a spine entrapped in a mechanical valve. **B:** Advancing the ablation catheter toward the stuck disc and pushing on the hinge portion of the disc. **C:** Pushing a stuck disc using the shaft of the PentaRay catheter (Biosense Webster, Diamond Bar, CA). **D:** The mapping catheter was removed, but the spine sheared and strayed into the coronary artery. PA = posteroanterior view; RAO = right anterior oblique view.


possibility that the clinical AT was originated from the left atrium (LA), transseptal access was achieved using a radio-frequency needle, a nonsteerable sheath (8.5F, SL0; St. Jude Medical, St. Paul, MN) was introduced, and LA mapping was performed using PentaRay. Despite careful mapping around the mechanical MV, 1 of the PentaRay spines suddenly became entrapped in the mechanical MV. Fluoroscopic images revealed that 1 of the PentaRay spines was entrapped between the disc and the orifice ring, and the cover of the spine was torn and connected to the catheter body only by the metal wire (Figure 1A). The ipsilateral disc was fixed in a closed position, and the patient's vital signs were stable. An additional transseptal puncture was performed cephalad of the first puncture site, and the steerable sheath (Agilis Nxt; Abbott Laboratories, Abbott Park, IL) was inserted into the LA. We attempted to release the entrapped spine by advancing the ablation catheter toward the stuck disc with the support of the steerable sheath and pushing on the hinge portion of the disc with the catheter tip (Figure 1B, Supplemental Video 1). Although the stuck and closed disc was considerably opened, the deeply entrapped spine between the disc and the orifice ring was not released. Next,

we advanced the shaft of the PentaRay catheter toward the left ventricle (Figure 1C). Immediately thereafter, the entrapped catheter was extracted, but the wire was sheared off and the spine floated through the Valsalva sinus and strayed into the coronary artery (Figure 1D, Supplemental Videos 2 and 3). We promptly requested the cooperation of coronary intervention specialists. Coronary angiography via the right femoral artery showed that the spine was at the proximal segment of the left circumflex artery (LCx) (Figure 2A and 2B). Activated clotting time was maintained at more than 300 seconds to prevent intracoronary thrombus formation owing to the torn spine. A guide catheter (LAUNCHER 8F, JL 4.0 SH; Medtronic, Tokyo, Japan) was engaged in the left coronary artery, and a guidewire for percutaneous coronary intervention (PCI; SION blue; ASAHI-INTECC, Seto, Japan) was crossed into the LCx segment with the spine. Although the guidewire was carefully manipulated, the spine moved easily into the peripheral LCx. We attempted to grasp the spine with a snare (ONE Snare 4 mm; MERITMEDICAL, Tokyo, Japan), but the originally attached microcatheter with the snare pushed the spine further into the distal LCx because it was difficult to advance the original



**Figure 2** Coronary angiography and recovery with snare. **A, B:** Coronary angiography showed that the spine was in the left circumflex artery. **C, D:** Successful capture of the spine using a 4 mm snare. CAUD = caudal; CRAN = cranial; LAO = left anterior oblique; RAO = right anterior oblique.

snare system into the peripheral LCx on the PCI guidewire. Next, a 4.0 mm snare with a 1.8F PCI micro-guide catheter (Finecross MG; Terumo Corporation, Tokyo, Japan) was employed instead of the originally attached micro-catheter to advance the distal LCx on the guidewire smoothly and grasp the spine, which was successfully retrieved into the guide catheter (Figure 2C and 2D and Figure 3). Final coronary



**Figure 3** Recovered spine and PentaRay catheter (Biosense Webster, Diamond Bar, CA). One of the 5 spines was sheared near the root.

angiography confirmed that there were no remnants in the coronary arteries. Fluoroscopic images showed no restriction of mechanical valve mobility.

A computerized tomography scan of the head and trunk was performed immediately postoperatively to determine whether any segment of the catheter or wires remained in the body. The scan showed no residual foreign material throughout the body and no findings suggestive of acute cerebral infarction or systemic embolism. A detailed physical examination confirmed the absence of obvious paralysis or other neurological abnormalities. Postoperatively, troponin T was mildly elevated from 0.007 ng/mL to 0.321 ng/mL, but serum creatine kinase remained in the normal range. Transthoracic echocardiography after the procedure revealed that there was no significant change from the preoperative period, including mechanical valve function. Fortunately, the patient remained free of AT/AF at the 3-month postprocedure outpatient visit.

## Discussion

This case involves a serious complication that can occur when using multipolar mapping catheters in patients with mechanical valves. The use of multipolar mapping catheters, including PentaRay, is not officially approved in patients with prosthetic

valves owing to the risk of the valves becoming stuck. However, patients with prosthetic valve replacement have a high incidence of complex atrial arrhythmias, and PentaRay is widely used in practice to effectively eliminate refractory arrhythmias. There are some reports of successfully opening a stuck valve and releasing an entrapped PentaRay spine by pushing the fixed disc with an ablation catheter or the PentaRay itself if the spine is entrapped in the hinge portion between the disc and the orifice ring, as in the present case.<sup>1</sup> We attempted similar approaches and, although the PentaRay itself could be extracted, 1 of the spines sheared off. While these approaches are certainly useful, we must caution that the spine can tear and cause embolism. Previous reports have shown cases of torn PentaRay spines remaining in the LA<sup>2,3</sup> or straying into the femoral artery<sup>4</sup> and renal artery.<sup>5</sup> This is the first report of a torn PentaRay spine straying into the coronary artery following entrapment in the mechanical MV. Embolisms caused by a spine in the coronary or intracranial artery can lead to serious outcomes. Accordingly, immediate identification of the location and recovery of the torn spine are essential. We successfully retrieved the spine from the coronary artery with the quick support of coronary intervention specialists, and the patient suffered no significant sequelae. Although the retrieval was fortunately successful in this case, there is some controversy as to whether to attempt release by catheter manipulation or to perform emergency open chest surgery in such cases. Further discussion on this issue is necessary in the future.

## Conclusion

Because the PentaRay catheter allows rapid and accurate mapping with high density and its benefits in the treatment

of complex arrhythmias are enormous, it is practically quite difficult to avoid its use during the ablation procedure for refractory arrhythmia. However, the possibility of the entrapment and subsequent rupture of the spine must always be considered during the procedure when maneuvering the catheter near the mechanical valve. Embolisms caused by a torn spine, especially those in the coronary or intracranial artery, can lead to serious outcomes. This case also illustrates the importance of cooperation with coronary intervention specialists and the preparation of specialized equipment to enable the rapid retrieval of embolized material in significant organs.

## Appendix Supplementary data

Supplementary data associated with this article can be found in the online version at <https://doi.org/10.1016/j.hrcre.2022.09.016>.

## References

1. Yagishita A, Ayabe K, Sakama S, et al. A novel technique to release a PentaRay entrapped in a mechanical mitral valve using an ablation catheter. *JACC Clin Electrophysiol* 2020;6:1597–1598.
2. Lopes J, Sousa PA, Elvas L, Gonçalves L. Successful retrieval of a broken PentaRay catheter spine in a patient with mechanic mitral valve prosthesis. *J Interv Card Electrophysiol* 2021;61:625–626.
3. Sheldon SH, Good E. PentaRay entrapment in a mechanical mitral valve during catheter ablation of atrial fibrillation. *HeartRhythm Case Rep* 2016; 2:200–201.
4. Kawaji T, Kato M, Yokomatsu T. How to release PentaRay catheter entrapped in the hinge point of mechanical mitral valve? *Europace* 2020;22:204.
5. Fischer AJ, Nagarajan VD, Padley S, Ernst S. When a multipolar catheter misses an “arm”: a known complication experienced anew. *HeartRhythm Case Rep* 2020; 6:745–748.