

## Original Article

# Stenotic changes of the posterior cerebral artery are a major contributing factor for cerebral infarction in moyamoya disease

Akira Ohkura, Tetsuya Negoto<sup>1</sup>, Takachika Aoki<sup>1</sup>, Kei Noguchi<sup>1</sup>, Yuji Okamoto<sup>2</sup>, Hideki Komatani<sup>2</sup>, Takayuki Kawano<sup>3</sup>, Akitake Mukasa<sup>3</sup>, Motohiro Morioka<sup>1</sup>

Department of Neurosurgery, Saiseikai Fukuoka General Hospital, Chuo-ku, Fukuoka, <sup>1</sup>Department of Neurosurgery, Kurume University, School of Medicine, Kurume, <sup>2</sup>Department of Neurosurgery, Saiseikai Yahata General Hospital, Yahatahigashi-ku, Kitakyushu, <sup>3</sup>Department of Neurosurgery, Kumamoto University School of Medicine, Kumamoto, Japan

E-mail: Akira Ohkura - [ookura@saiseikai-hp.chuo.fukuoka.jp](mailto:ookura@saiseikai-hp.chuo.fukuoka.jp); Tetsuya Negoto - [negoto\\_tetsuya@med.kurume-u.ac.jp](mailto:negoto_tetsuya@med.kurume-u.ac.jp);  
Takachika Aoki - [takachi@med.kurume-u.ac.jp](mailto:takachi@med.kurume-u.ac.jp); Kei Noguchi - [noguchi\\_kei@med.kurume-u.ac.jp](mailto:noguchi_kei@med.kurume-u.ac.jp); Yuji Okamoto - [okamoto@yahata.saiseikai.or.jp](mailto:okamoto@yahata.saiseikai.or.jp);  
Hideki Komatani - [koma.0523@gmail.com](mailto:koma.0523@gmail.com); Takayuki Kawano - [tkawano-nsu@umin.ac.jp](mailto:tkawano-nsu@umin.ac.jp); Akitake Mukasa - [mukasa@kumamoto-u.ac.jp](mailto:mukasa@kumamoto-u.ac.jp);  
\*Motohiro Morioka - [mmorioka@med.kurume-u.ac.jp](mailto:mmorioka@med.kurume-u.ac.jp)  
\*Corresponding author

Received: 16 January 18 Accepted: 28 March 18 Published: 24 May 18

## Abstract

**Background:** Some patients with moyamoya disease (MMD) show broad infarction with moderate internal carotid artery (ICA) stenosis, whereas others with complete ICA occlusion show no infarction. This suggests that other factors contribute to the occurrence of infarction. Contributing factors predictive of cerebral infarcts must be identified for the prevention of infarction and the consequent neurological deficits.

**Methods:** We examined data from 93 patients with confirmed MMD for the presence of infarction ( $n = 72$ ), transient ischemic attack (TIA,  $n = 41$ ), asymptomatic presentation ( $n = 51$ ), or hemorrhage ( $n = 22$ ) in 186 bilateral cerebral hemispheres. We analyzed the relationship between the occurrence of infarction and several clinical factors, such as steno-occlusive status or the site of the ICA and posterior cerebral artery (PCA).

**Results:** The incidence of PCA steno-occlusive lesions was significantly higher in infarcted (77.8%) than in non-infarcted hemispheres (TIA, 14.6%; asymptomatic, 9.8%; hemorrhagic 9.1%;  $P < 0.01$ ). The steno-occlusive site of ICA was also a significant factor ( $P < 0.05$ ). There was no significant correlation between the occurrence of infarction and the steno-occlusive status of the ICA or grade of the moyamoya vessels. Multivariate statistical analysis demonstrated that the PCA steno-occlusive changes were an important contributing factor for infarction ( $P < 0.0001$ ).

**Conclusions:** This is the multivariate statistical analysis study identifying PCA steno-occlusive lesions as the most important independent factor that is predictive to cerebral infarction in moyamoya patients. The prediction and inhibition of PCA steno-occlusive changes may help to prevent cerebral infarction.

### Access this article online

**Website:**

[www.surgicalneurologyint.com](http://www.surgicalneurologyint.com)

**DOI:**

10.4103/sni.sni\_18\_18

**Quick Response Code:**

This is an open access journal, and articles are distributed under the terms of the Creative Commons Attribution-NonCommercial-ShareAlike 4.0 License, which allows others to remix, tweak, and build upon the work non-commercially, as long as appropriate credit is given and the new creations are licensed under the identical terms.

**For reprints contact:** [reprints@medknow.com](mailto:reprints@medknow.com)

**How to cite this article:** Ohkura A, Negoto T, Aoki T, Noguchi K, Okamoto Y, Komatani H, et al. Stenotic changes of the posterior cerebral artery are a major contributing factor for cerebral infarction in moyamoya disease. *Surg Neurol Int* 2018;9:105.  
<http://surgicalneurologyint.com/Stenotic-changes-of-the-posterior-cerebral-artery-are-a-major-contributing-factor-for-cerebral-infarction-in-moyamoya-disease/>

**Key Words:** Cerebral infarction, moyamoya disease, multivariate analysis, posterior cerebral artery, transient ischemic attacks

## INTRODUCTION

Moyamoya disease (MMD) is an unusual form of chronic, occlusive cerebrovascular disease characterized by bilateral stenosis or occlusion at the terminal portion of the internal carotid artery (ICA) and an abnormal vascular network (the so-called moyamoya vessels) at the base of the brain.<sup>[9,18-20]</sup> Many MMD patients experience cerebral ischemic or hemorrhagic events; pediatric patients primarily experience ischemic attacks and hemorrhage is prevalent among adults.<sup>[9,13,19]</sup>

Although bypass surgery improves the prognosis of moyamoya patients with cerebral infarction or transient ischemic attacks (TIA),<sup>[6,7,10]</sup> their symptoms vary; some patients experience frequent TIA but not infarction before bypass surgery, whereas the first attack leads to severe infarction in others. Some patients show broad infarction with moderate ICA stenosis, whereas others with complete ICA occlusion exhibit an absence of infarction. These facts suggest that there are other contributing factors for the occurrence of infarctions, besides ICA stenosis/occlusion.

As cerebral infarction may produce serious neurological deficits, it is important to identify factors predictive of its occurrence. Our previous experience with pediatric MMD patients suggested that steno-occlusive changes in the posterior cerebral artery (PCA) can be implicated in progression to cerebral infarction,<sup>[14]</sup> and a similar issue has been discussed recently for pediatric<sup>[3,5]</sup> and adult<sup>[2-4]</sup> patients with MMD. The importance of PCA steno-occlusive lesions<sup>[8,11,15-17]</sup> and other factors, such as age and moyamoya vessels,<sup>[15,17]</sup> have been suggested in MMD. In this study, we analyzed the clinical factors, including angiographic findings, to determine the factors contributing to infarction in MMD patients.

## MATERIALS AND METHODS

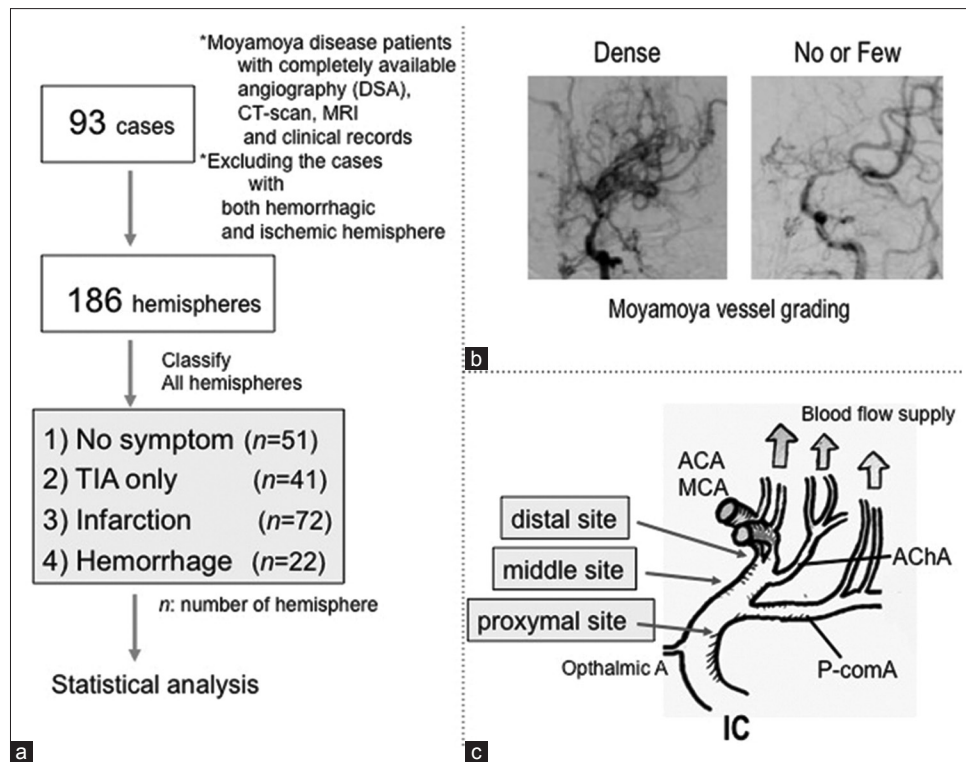
We obtained detailed clinical records of 93 MMD patients treated between January 2008 and December 2015 at the Departments of Neurosurgery of Kumamoto University and Kurume University [Figure 1a]. These 93 patients were registered consecutively in the study period. Of these, 74 patients (79.6%) had ischemic symptoms, including TIA and infarction, whereas the other 19 manifested hemorrhagic symptoms. In this study, we excluded patients with both ischemic and hemorrhagic symptoms. Complete angiographic records, including bilateral ICA, vertebral angiographs, and serial CT/magnetic resonance imaging scans, were available for

all patients. We access the angiogram obtained prior to the revascularization surgery.

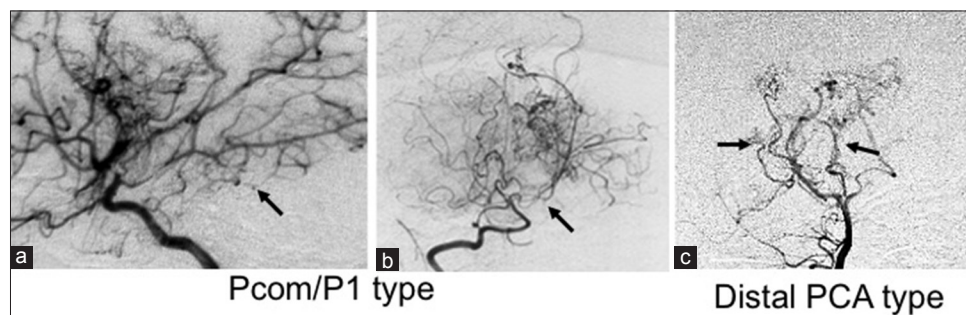
Both cerebral hemispheres of the 93 patients ( $n = 186$ ) were separately assessed as asymptomatic or manifesting TIA, infarction, or hemorrhage [Figure 1a]. ICA steno-occlusive status was defined as “stenotic” or “occluded.” The moyamoya vessels were graded as densely proliferated, that is, “Dense,” or as absent or few in number, that is, “No or Few,” according to our previous classification procedure<sup>[12]</sup> [Figure 1b]. Basal moyamoya vessels were graded as absent, few, or densely proliferated in our past study; however, from the viewpoint of the collateral flow, it is not important to distinguish between absent and few, and we combined them and made the new classification as described above. From our data,<sup>[12]</sup> we had inferred that the collateral blood flow in MMD was mainly effected by moyamoya vessels arising at the ICA top/A1/M1 and by perforators extending from the anterior choroidal artery (AChA) and posterior communicating artery (PcomA). Suzuki’s classification is commonly used for the assessment of the collateral flow. However, there are few comments concerning PCA and AChA status in Suzuki’s classification. Notably, in this study, we would like to emphasize the importance of the survival of the PCA flow and exclude the influence of AChA flow, and we classified ICA steno-occlusive sites as a 1) distal site (distal from the AChA), 2) proximal site (proximal to the PcomA), or 3) middle site (between the distal and proximal sites) [Figure 1c]. It is straightforward to classify the ICA lesion into three types in detail by observing the branching point of the AChA and PcomA in DSA.

PCA steno-occlusive status was defined as “No” or “Yes,” as evaluated using both, carotid and vertebral angiographies. PCA steno-occlusive sites were classified into two categories as 1) PCA-P1 type (proximal to PCA P1 portion including PcomA) [Figure 2a and b] and 2) distal PCA type (distal from PCA P2 portion) [Figure 2c]. PCA stenosis or occlusive change at distal from PCA P2 portion can occur, and we had expected that the PCA-P1 type lesion had a greater influence on collateral flow.

Statistical analysis to determine the possibility of clinical data to contribute to infarction occurrence was carried out with Pearson’s Chi-square test. Chi-square tests were repeated for each  $2 \times 2$  contingency table and for each of the “proximal,” “middle,” and “distal” regions of each subset of each hemisphere. Multivariate analysis was conducted using multiple logistic-regression analysis. Differences with  $P < 0.01$  and  $P < 0.05$  were considered statistically significant.



**Figure 1:** (a) Flowchart of statistical analysis study data. (b) Grading of the moyamoya vessels as “Dense” and “No or Few,” according to a previous report by Morioka *et al.*, 2003.<sup>[11]</sup> (c) Schematic illustration of the steno-occlusive sites in the internal carotid artery (ICA) and of the blood supply route in moyamoya disease (lateral view). Distal, distal from the anterior choroidal artery (AChA); proximal, proximal to the posterior communicating artery (PcomA); middle, located between the distal and proximal sites



**Figure 2:** Patterns of PcomA/PCA stenosis (a-c) (1) PcomA/PI type: (A) right ICA angiograph (lateral view) showing PcomA and PCA stenosis. (b) Right vertebral artery angiograph (VAG, antero-posterior view) demonstrating PI occlusion; (c) VAG (antero-posterior view) shows both distal PCA stenosis

## RESULTS

The mean age of the 74 MMD patients with ischemic symptoms (48 females and 26 males) was 19.9 (17.7) years (mean [SD]), ranging from 2.2 to 67.7 years. The 19 patients with hemorrhagic symptoms (11 females and 8 males) ranged in age from 5.3 to 59.4 (mean 39.6 [14.8]) years.

First, we looked for factors that may have contributed to the occurrence of infarction by comparing the infarction-hemisphere ( $n = 72$ ) with TIA ( $n = 41$ ), hemorrhage ( $n = 22$ ), and no symptom ( $n = 51$ ) hemispheres. There was no significant difference in the

sex, ICA steno-occlusive status, or grade of moyamoya vessels.

The ICA steno-occlusive site in 20 of the 72 infarcted hemispheres (27.8%) was proximal, that is, proximal to the PcomA [Figure 1c; Table 1], which was significantly more frequent than in the asymptomatic ( $P < 0.05$ ), TIA ( $P = 0.055$ ), and hemorrhagic hemispheres ( $P < 0.01$ ). On the other hand, there was no significant difference with respect to the middle and distal sites.

Although the hemispheres of the younger patients (under 20 years of age) tended to display ischemic symptoms (TIA or infarction), there was no obvious significant difference between the infarcted and TIA hemispheres.

**Table 1: Univariate analysis of the findings from the hemispheres of patients with moyamoya disease**

	Infarction	TIA	P	No Symptom	P	Hemorrhage	P
Total (n=186)	n=72 (100%)	n=41 (100%)		n=51 (100%)		n=22 (100%)	
Sex							
Female	48 (66.7%)	28 (68.3%)	0.859	29 (56.9%)	0.268	13 (59.1%)	0.515
Male	24 (33.3%)	13 (31.7%)		22 (43.1%)		9 (40.9%)	
Age							
Young (<20 years)	44 (61.1%)	31 (75.6%)	0.116	19 (37.3%)	<0.01	2 (9.1%)	<0.01
Adult (>20 years)	28 (38.9%)	10 (24.4%)		32 (62.7%)		20 (90.9%)	
ICA S/O status							
Stenosis	25 (34.7%)	16 (39.0%)	0.647	26 (51.0%)	0.071	5 (22.7%)	0.290
Occlusion	47 (65.3%)	25 (61.0%)		25 (49.0%)		17 (77.3%)	
Grades of moyamoya vessels							
Dense	34 (47.2%)	17 (41.5%)	0.554	19 (37.3%)	0.271	8 (36.4%)	0.370
No or Few	38 (52.8%)	24 (58.5%)		32 (62.7%)		63.6%	
ICA S/O site							
Proximal	20 (27.8%)	5 (12.2%)	0.055	6 (11.8%)	<0.05	0 (0%)	<0.01
Middle	10 (13.9%)	6 (14.6%)		8 (15.7%)		5 (22.7%)	
Distal	42 (58.3%)	30 (73.2%)		37 (72.5%)		17 (77.3%)	
PCA S/O lesion*							
Yes	56 (77.8%)	6 (14.6%)	<0.01	5 (9.8%)	<0.01	2 (9.1%)	<0.01
No	16 (22.2%)	35 (85.4%)		46 (90.2%)		20 (90.9%)	

ICA: Internal carotid artery, PCA: Posterior cerebral artery, PcomA: Posterior communicating artery, S/O: Steno-occlusion, TIA: Transient ischemic attack. Statistically significant difference compared to infarcted hemispheres;  $P < 0.05$ , by Pearson's Chi-square test. Chi-square tests were repeated for each  $2 \times 2$  contingency table and for each of "proximal", "middle" and "distal" with respect to each subset of the hemisphere

Subsequently, we examined the frequency and sites of steno-occlusive lesions in the PCA, which were detected at PCA-P1 type [Figure 2a and b] or distal PCA type [Figure 2c]. All hemispheres with PcomA stenosis were complicated with PCA-P1 site stenosis. Of the 72 infarcted hemispheres, 56 (77.8%) harbored PCA steno-occlusive lesions [Table 1]; the difference with respect to the other hemispheres was significant ( $P < 0.01$ ). Among the 56 stenotic PCA lesions in the infarcted hemispheres, 29 (51.8%) were located at a distal site, and the distribution of PCA stenosis did not demonstrate a statistical difference between infarcted and other hemisphere types [Table 2].

Using multiple logistic-regression analysis, we performed a multivariate analysis of the association between several factors, such as young age of patient (<20 years), female sex of patient, no or few grades of moyamoya vessels, PCA steno-occlusive lesions, ICA occlusion lesions, and ICA steno-occlusive lesion at the proximal side [Table 3], because these factors seemed to show a greater risk of infarction by univariate analysis as shown in Table 1. The presence of PCA steno-occlusive lesions was the most important factor (odds ratio: 22.29,  $P < 0.0001$ ) and patients with ICA steno-occlusive lesions at the proximal site were at increased risk ( $P = 0.03$ ).

## DISCUSSION

We detected PCA steno-occlusive lesions in 69 (37.1%) of the 186 hemispheres from patients with MMD. This

incidence is in concordance with the rate reported by others.<sup>[3,8,16,17,21]</sup> In our study, of the 72 infarcted hemispheres, 56 (77.8%) manifested PCA steno-occlusive lesions. Yamada *et al.*<sup>[17]</sup> also detected PCA steno-occlusive lesions in 43% of 152 hemispheres from MMD patients and their number increased significantly with the angiographic stage of the ICA steno-occlusive lesions. However, they had analyzed all types of cerebral ischemic hemispheres, including TIA and infarction. The most important finding is that our data indicate that PCA steno-occlusive lesions were highly specific for infarction, but not TIA hemispheres. Moreover, we have considered the influence of ICA steno-occlusive lesions by dividing them into three types: distal, middle, and proximal sites.

### Relationship between PCA and the ICA steno-occlusive site

Mugikura *et al.*<sup>[16]</sup> and Hishikawa *et al.*<sup>[3]</sup> reported that the ipsilateral ICA and PCA tend to simultaneously exhibit stenotic changes. Thus, steno-occlusive progression may occur at the same time in both the anterior and posterior circulations in the ischemic hemisphere. This is the first article that elaborates the site of ICA steno-occlusive lesions. In this study, we classified ICA stenosis according to three lesion sites, distal, middle, and proximal, and considered the factor that contributes to brain infarction. According to the results of univariate and multivariate analyses, only the proximal side of an ICA steno-occlusive lesion was identified as a significant factor influencing infarction. Compared to the ICA steno-occlusive lesion of



**Table 2: Distribution of PCA S/O lesions**

	Hemisphere exhibiting the following			
	Infarction	TIA	No symptom	Hemorrhage
Total	(51)	(41)	(72)	(22)
PCA S/O lesion				
Yes	56 (100%)	6 (100%)	5 (100%)	2 (100%)
PcomA/P1 (%)	27 (48.2)	4 (66.7)	3 (60.0)	2 (100)
Distal PCA (%)	29 (51.8)	2 (33.3)	2 (40.0)	0

**Table 3: Multivariate analysis of associations between various factors and risk for infarction**

Factors	All hemispheres (n=186)			
	Number (%)	Infarction (%)	P	Odds ratio
PCA S/O lesion	69 (37.1%)	56 (81.2%)	<0.0001	22.29
ICA S/O status				
Occlusion	114 (61.3%)	47 (25.3%)	0.364	
Age (<20 years)	96 (51.6%)	44 (45.3%)	0.321	
Sex; Female	118 (63.4%)	48 (40.7%)	0.538	
Moyamoya vessel				
None or Few	108 (58.1%)	38 (35.2%)	0.235	
ICA S/O site				
Proximal	31 (16.7%)	20 (64.5%)	0.026	4.51

ICA, internal cerebral artery; PCA, posterior cerebral artery; S/O, stenosis or occlusion

distal and middle sides, the proximal ICA steno-occlusive lesion directly reduces the flow of the PCA. Therefore, from the viewpoint of anterior circulation, collateral flow from the PCA via the posterior communicating artery is important for preventing the infarction.

### Mechanism of the development of infarction in moyamoya disease

Based on our data, we developed a hypothesis regarding the mechanism underlying the development of infarction in patients with MMD. In this disease, the cerebral blood flow to the anterior circulation territory is delivered through four routes: (a) the stenotic ICA/ACA/MCA, (b) moyamoya vessels, (c) perforators of the AChA/PcomA<sup>[8]</sup> that may be a part of the vascular moyamoya network, and (d) leptomeningeal collateral flow from the PCA.<sup>[2-5,11]</sup> These routes develop gradually in MMD, but three routes, namely, (a), (b), and (c), may supply a narrow restricted area. Therefore, the severity of ICA stenosis and density of moyamoya vessels are not independent risk factors contributing to the development of infarction. However, as leptomeningeal anastomosis from the PCA extending to the anterior circulation territory is a major source of the blood supply, PCA steno-occlusive lesions can induce infarction. For the same reason, we have stated the importance of the site of the ICA steno-occlusive lesions, as discussed above. Therefore, we suggest that PCA steno-occlusive lesions may be the predictive factor for cerebral infarction in

moyamoya patients. Funaki *et al.*<sup>[1]</sup> previously reported the related, but different topic about the association between PCA S/O and social outcomes of pediatric MMD. This paper identified PCA S/O and cerebral infarct as statistically significant risk factors for unfavorable social outcomes by multivariate logistic regression analysis. On the other hand, MMD is known to have various cerebral perfusion statuses; thus, regardless of the affected arterial site, cerebral infarct can occur at various cortical subcortical regions, and we cannot tell whether the PCA S/O change or brain infarction occurred first. However, we did not investigate the site of infarction, because we only wished to assess the extent of development of cerebral collateral flow owing to the presence or absence of the infarction lesion. Thus, we need to accordingly conduct future experiments.

Although this study demonstrated that a PCA steno-occlusive change is an obvious contributing factor to infarction, the lesions were not detected in 16 of the 72 infarcted hemispheres. Although the mechanism underlying this type of infarction is not well understood, we posit that stenotic ICA/ACA/MCA changes can progress rapidly without sufficient collateral flow provided by the moyamoya or other vessels.

### Distinction between infarction and TIA in moyamoya disease

Although TIA and infarction are considered ischemic symptoms in patients with MMD, TIA and infarcted hemispheres have obviously different characteristics and exhibit clearly differing prognoses. We distinguished the ischemic symptoms between TIA and infarction in our study, and found a significant difference between these in cases with ICA proximal steno-occlusive lesions and PCA steno-occlusive lesions. According to our data, TIA-hemisphere with sufficient PCA flow has a lower risk of infarction. Thus, frequent TIA symptoms may not be related to infarction. Although the pathogenesis of MMD remains largely unknown, inhibiting the progression of stenosis-occlusion in the PCA may reduce the incidence of cerebral infarction in these patients.

### Study limitations

The study was designed based on angiographic assessment and thus did not include quantitative or semi-quantitative grading. Furthermore, we could not obtain data from (semi-) quantitative analysis by SPECT or PET because of institutional differences in evaluation. However, we consider that angiographic assessment is sufficient to assess the extent of the collateral development.

### CONCLUSIONS

This multivariate statistical analysis study identifies PCA steno-occlusive lesions as the most important

independent factor for prediction of cerebral infarction in moyamoya patients. This prediction and inhibition of PCA steno-occlusive changes may help prevent cerebral infarction in these patients. Moreover, we found that the proximal site of the ICA steno-occlusive lesion had a major effect on PCA flow-related brain infarction.

### Financial support and sponsorship

Nil.

### Conflicts of interest

There are no conflicts of interest.

## REFERENCES

- Funaki T, Takahashi JC, Takagi Y, Yoshida K, Araki Y, Kikuchi T, et al. Impact of posterior cerebral artery involvement on long-term clinical and social outcome of pediatric moyamoya disease. *J Neurosurg Pediatr* 2013;12:626-32.
- Ge P, Zhang Q, Ye X, Liu X, Deng X, Wang R, et al. Clinical features, surgical treatment, and long-term outcome in elderly patients with moyamoya disease. *World Neurosurg* 2017;100:459-66.
- Hishikawa T, Tokunaga K, Sugiu K, Date I. Assessment of the difference in posterior circulation involvement between pediatric and adult patients with moyamoya disease. *J Neurosurg* 2013;119:961-5.
- Hishikawa T, Tokunaga K, Sugiu K, Date I. Long-term outcomes in adult patients with ischemic-type moyamoya disease involving posterior circulation. *Acta Neurochir (Wien)* 2014;156:1745-51.
- Ji YL, Seung KK, Ji HP, Kyu CW. Posterior cerebral artery insufficiency in pediatric moyamoya disease. *J Korean Neurosurg Soc* 2015;57:436-9.
- Karasawa J, Kikuchi H, Furuse S, Kawamura J, Sakaki T. Treatment of moyamoya disease with STA-MCA anastomosis. *J Neurosurg* 1978;49:679-88.
- Karasawa J, Touho H, Ohnishi H, Miyamoto S, Kikuchi H. Long-term follow-up study after extracranial-intracranial bypass surgery for anterior circulation ischemia in childhood moyamoya disease. *J Neurosurg* 1992;77:84-9.
- Kuroda S, Ishikawa T, Houkin K, Iwasaki Y. Clinical significance of posterior cerebral artery stenosis/occlusion in moyamoya disease. *No Shinkei Geka* 2002;30:1295-300.
- Masuda J, Ogata J, Yamaguchi T. Moyamoya disease. In: Barnett HJM, Mohr JP, Stein BM, Yatsu FM, editors. *Stroke, Pathophysiology, Diagnosis, and Management*. Churchill Livingstone: New York; 1998. pp 815-32.
- Matsushima Y, Fukai N, Tanaka K, Tsuruoka S, Inaba Y, Aoyagi M. A new surgical treatment of moyamoya disease in children: A preliminary report. *Surg Neurol* 1981;15:313-20.
- Miyamoto S, Kikuchi H, Karasawa J, Nagata I, Ikota T, Takeuchi S. Study of the posterior circulation in moyamoya disease: Clinical and neuroradiological evaluation. *J Neurosurg* 1984;61:1032-37.
- Morioka M, Hamada J, Kawano T, Todaka T, Yano S, Kai Y, Ushio Y. The angiographical dilatation and branch extension of the anterior choroidal and posterior communicating artery are predictors of hemorrhage in adult moyamoya patients. *Stroke* 2003;34:90-5.
- Morioka M, Hamada J, Todaka T, Yano S, Kai Y, Ushio Y. High-risk age for rebleeding in patients with hemorrhagic moyamoya disease: Long-term follow-up study. *Neurosurgery* 2003;52:1049-55.
- Morioka M, Hamada J, Kai Y, Yano S, Kawano T, Ohmori Y, et al. Contributing factors to long-term outcome and type of onset in young aged moyamoya disease patients with ischemic onset. *Surg Cereb Stroke* 2009;37:338-44.
- Mugikura S, Takahashi S, Higano S, Shirane R, Kurihara N, Furuta S, et al. The relationship between cerebral infarction and angiographic characteristics in childhood moyamoya disease. *Am J Neuroradiol* 1999;20:336-43.
- Mugikura S, Takahashi S, Higano S, Shirane R, Sakurai Y, Yamada S. Predominant involvement of ipsilateral anterior and posterior circulations in moyamoya disease. *Stroke* 2002;33:1497-500.
- Mugikura S, Higano S, Shirane R, Fujimura M, Shimanuki Y, Takahashi S. Posterior circulation and high prevalence of ischemic stroke among young pediatric patients with moyamoya disease: Evidence of angiography-based differences by age at diagnosis. *Am J Neuroradiol* 2011;32:192-8.
- Nishimoto A, Takeuchi S. Abnormal cerebrovascular network related to the internal carotid arteries. *J Neurosurg* 1968;29:255-60.
- Suzuki J, Kodama N. Moyamoya disease-A review. *Stroke* 1983;14:104-9.
- Suzuki J, Takaku A. Cerebrovascular "moyamoya" disease. Disease showing abnormal net-like vessels in base of brain. *Arch Neurol* 1969;20:288-99.
- Yamada I, Himeno Y, Suzuki S, Matsushima Y. Posterior circulation in moyamoya disease: Angiographic study. *Radiology* 1995;197:239-46.