

# Sudden death and cervical spine: A new contribution to pathogenesis for sudden death in critical care unit from subarachnoid hemorrhage; first report - An experimental study

## ABSTRACT

**Context:** Sudden death from subarachnoid hemorrhage (SAH) is not uncommon.

**Aims:** The goal of this study is to elucidate the effect of the cervical spinal roots and the related dorsal root ganglions (DRGs) on cardiorespiratory arrest following SAH.

**Settings and Design:** This was an experimental study conducted on rabbits.

**Materials and Methods:** This study was conducted on 22 rabbits which were randomly divided into three groups: control ( $n=5$ ), physiologic serum saline (SS;  $n=6$ ), SAH groups ( $n=11$ ). Experimental SAH was performed. Seven of 11 rabbits with SAH died within the first 2 weeks. After 20 days, other animals were sacrificed. The anterior spinal arteries, arteriae nervorum of cervical nerve roots (C6–C8), DRGs, and lungs were histopathologically examined and estimated stereologically.

**Statistical Analysis Used:** Statistical analysis was performed using the PASW Statistics 18.0 for Windows (SPSS Inc., Chicago, Illinois, USA). Intergroup differences were assessed using a one-way ANOVA. The statistical significance was set at  $P < 0.05$ .

**Results:** In the SAH group, histopathologically, severe anterior spinal artery (ASA) and arteriae nervorum vasospasm, axonal and neuronal degeneration, and neuronal apoptosis were observed. Vasospasm of ASA did not occur in the SS and control groups. There was a statistically significant increase in the degenerated neuron density in the SAH group as compared to the control and SS groups ( $P < 0.05$ ). Cardiorespiratory disturbances, arrest, and lung edema more commonly developed in animals in the SAH group.

**Conclusion:** We noticed interestingly that C6–C8 DRG degenerations were secondary to the vasospasm of ASA, following SAH. Cardiorespiratory disturbances or arrest can be explained with these mechanisms.

**Key words:** Cervical spinal root; dorsal root ganglion degeneration; subarachnoid hemorrhage; sudden death.

## Introduction

Subarachnoid hemorrhage (SAH) is a serious and debilitating condition<sup>[1]</sup> that leads to the development of many complications, which leads to high mortality and morbidity.<sup>[2]</sup> This situation typically warrants initial monitoring in a critical care setting. At present, medical practice is confronted by an explosion of technology.<sup>[3-5]</sup> New advances in the management of severely ill patients in the critical care unit have been observed. Even in the presence of modern technology and facilities in medical practice,<sup>[6,7]</sup> including the evolution of

**HIZIR KAZDAL, AYHAN KANAT<sup>1</sup>, MEHMET DUMLU AYDIN<sup>2</sup>, UGUR YAZAR<sup>3</sup>, ALI RIZA GUVERCIN<sup>3</sup>, MUHAMMET CALIK<sup>3</sup>, BETUL GUNDOGDU<sup>4</sup>**

Departments of Anesthesiology and Reanimation and <sup>1</sup>Neurosurgery, Medical Faculty, Recep Tayyip Erdogan University, Rize, Departments of <sup>2</sup>Neurosurgery and <sup>4</sup>Pathology, Medical Faculty, Ataturk University, Erzurum, <sup>3</sup>Department of Neurosurgery, Medical Faculty, Karadeniz Technical University, Trabzon, Turkey

**Address for correspondence:** Dr. Ayhan Kanat, Department of Neurosurgery, Medical Faculty, Recep Tayyip Erdogan University, Rize 53100, Turkey.  
E-mail: ayhankanat@yahoo.com

This is an open access article distributed under the terms of the Creative Commons Attribution-NonCommercial-ShareAlike 3.0 License, which allows others to remix, tweak, and build upon the work non-commercially, as long as the author is credited and the new creations are licensed under the identical terms.

For reprints contact: reprints@medknow.com

**How to cite this article:** Kazdal H, Kanat A, Aydin MD, Yazar U, Guvercin AR, Calik M, *et al.* Sudden death and cervical spine: A new contribution to pathogenesis for sudden death in critical care unit from subarachnoid hemorrhage; first report – An experimental study. J Craniovert Jun Spine 2017;8:33-8.

Access this article online	
<b>Website:</b> www.jcvjs.com	<b>Quick Response Code</b> 
<b>DOI:</b> 10.4103/0974-8237.199870	

neurocritical care, however, their impact on sudden death following SAH is unclear. Some patients following severe SAH lapse into coma and go into cardiorespiratory arrest. Sudden death may occur. Outcomes in patients with aneurysmal SAH need to improve.<sup>[8]</sup> A better understanding, identification, and management of modifiable risk factors for SAH are pivotal to reducing its incidence.<sup>[8,9]</sup> It would undoubtedly lead to better patient outcomes.<sup>[9]</sup> The effect of anterior spinal artery (ASA) vasospasm on the C6–C8 dorsal root ganglion (DRG) degeneration was previously studied.<sup>[10]</sup> However, its effect on respiratory and the cardiac function has never been investigated. To clarify the experimental profile of sudden death from SAH, we studied this subject.

## Materials and Methods

This study was conducted on 22 rabbits. The animal protocols were approved by the Ethics Committee of Ataturk University, Medical Faculty. Rabbits were randomly divided into three groups: Control ( $n = 5$ ), physiologic serum saline (SS;  $n = 6$ ), SAH group ( $n = 11$ ). The animals were anesthetized by subcutaneous injection with a mixture of ketamine hydrochloride (25 mg/kg), lidocaine hydrochloride (15 mg/kg), and acepromazine (1 mg/kg). A tracheal tube was inserted surgically to ensure an unobstructed airway, and the animal was allowed to breathe room air spontaneously through the tracheostomy during the experiment. After the occipitocervical region was prepared, autologous blood (0.5 mL) was taken from the auricular artery and injected using a 22-gauge needle into the spinal subarachnoid space at the level C6–C8 in the SAH group, and 1 mL of SS injected in the SS group over the course of 1 min. The animals in the control group were not subjected to this procedure. In the control group, the animals were followed for 20 days without any medical treatment. All animals were closely monitored for electrocardiographic (ECG) and respiratory irregularities. All parameters were analyzed by physicians who did not know the experimental group to which the individual animal belonged. Seven of 11 rabbits with SAH died within the first 2 weeks. After 20 days, other animals were sacrificed. Whole bodies of died and sacrificed animals were kept in 10% formalin solution after required cleaning procedures for histologic examination. Their anterior spinal arteries, arteriae nervorum of cervical nerve roots (C6–C8), DRGs, and lungs were removed. They were kept in 10% formalin solution for 7 days; then, 1- $\mu$ m tissue sections were taken and stained with hematoxylin and eosin (H and E) and examined histopathologically. Stereological methods were used to estimate cell density in all studies of histological specimens as described previously.<sup>[11–13]</sup> The physical dissector method was used to evaluate the numbers of neurons of the C6–C8 roots and the DRG. The mean numerical density of neurons/mm<sup>3</sup> was estimated using

the following formula: The mean numerical density of normal neurons (NNs) and degenerated neurons (DNs) in the C6–C8 DRG (NNn [number]/DNn) per cubic millimeter were estimated using the following formula:  $NNn/DNn = \Sigma Q-N / \Sigma A \times d$ , where  $\Sigma Q-N$  is the total number of counted neurons appearing only in the reference sections,  $d$  is the section thickness, and  $A$  is the area of the counting frame. The most effective way of estimating  $\Sigma A$  for the set of dissectors is using  $\Sigma A = \Sigma P$ , where  $\Sigma P$  is the total number of counting set frame points [Figure 1]. The Cavalieri volume estimation method was used to obtain the total number of neurons in each specimen. The total number of neurons was calculated by multiplication of the volume (mm<sup>3</sup>) and the numerical density of neurons in each C6–C8 DRG. The number of normal and DNs of C6–C8 DRG of all animals was counted. Vasospasm indexes (VSIs) of ASA arteries (wall surface/lumen surface), the degenerated axon numbers of C6–C8 roots ( $n/mm^2$ ), and the neuron density of C6–C8 DRG ( $n/mm^2$ ) were estimated stereologically, and the results were analyzed statistically with respiratory parameters. ASAs and pulmonary arteries (PAs) were obtained, stained with H and E dyes. For the calculation of VSI, all ASA samples were accepted as a cylinder, in view of their morphological characteristics, and simple geometric formulas were used to estimate their surface areas. As a measure of the degree of vasospasm, the use of ASA VSI was preferred over the only measurement of lumen radius and volume values. ASA and PA of all animals were cut into twenty segments. Then, twenty histopathological sections, 5  $\mu$ m apart, were obtained by microtome for each designation and were represented by the lines 1, 2, 3, ..., and 20. The mean external diameter and internal (luminal) diameter of each section was measured, and the external radius was represented as  $R1$  and the internal radius was represented as  $r1$ . The mean radius value of ASA and PA was calculated as  $R1 = R1 + R2 + R3 + \dots + R20 / 20$ ; and lumen radius was calculated as  $r1 = r1 + r2 + r3 + \dots + r20 / 20$ . The wall ring surface values were calculated using the following formula:  $S1 = \pi R1^2 - \pi r1^2$ . The lumen surface area was calculated using the same method. Hence, lumen surface value ( $S2$ ) =  $\pi r1^2$ . The VSI was calculated as the proportion of  $S1/S2 = \pi R1^2 - \pi r1^2 / \pi r1^2 = \pi (R1^2 - r1^2) / \pi r1^2 = R1^2 - r1^2 / r1^2$ . In summary,  $VSI = (R2 - r2) / r2$ . The differences between the ASA and PA of VSI, heart rates,

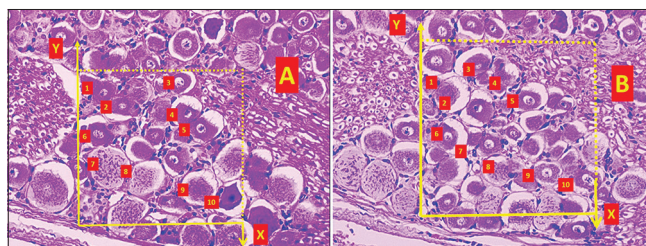


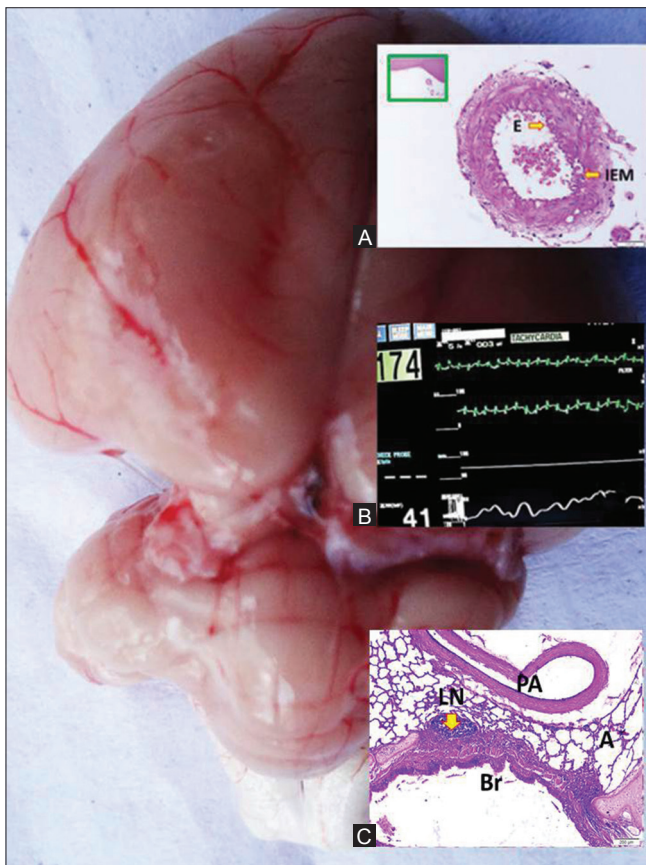
Figure 1: (A and B) Stereological cell counting method of dorsal root ganglion of C7 root is seen in rabbits (LM: H and E,  $\times 20$ )

and axon densities in the C6–C8 DRGs were compared statistically. The data were analyzed using a commercially available statistics software package (SPSS® for Windows v. 12.0, Chicago, Illinois, USA). This analysis consisted of the Kruskal–Wallis and Mann–Whitney U-test. Differences were considered to be statistically significant at  $P < 0.05$ .

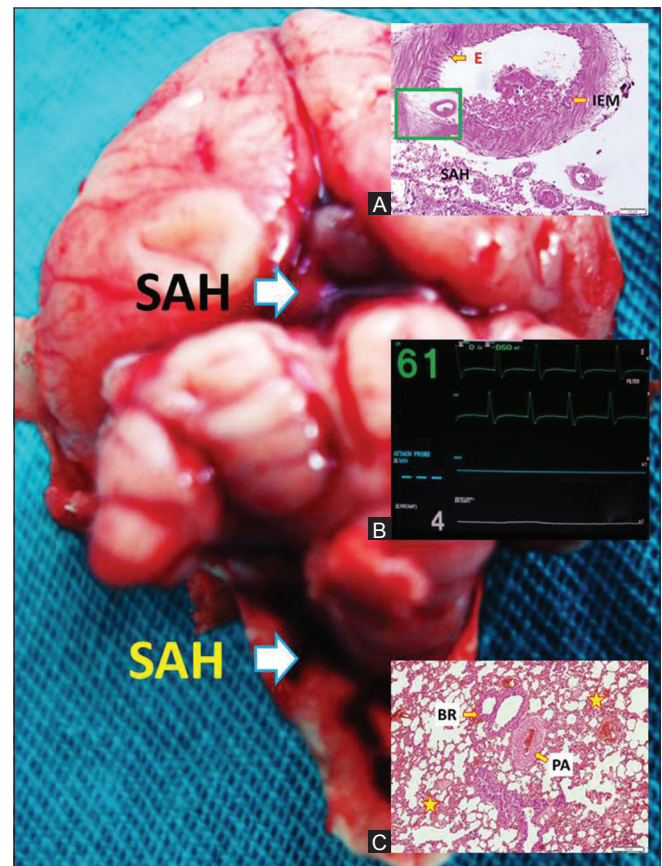
## Results

Figure 2 shows the anatomical appearance of a rabbit brain of the control group at the base. ASA, monitor finding, and histopathological appearance of a normal lung are shown in Figure 2A–C. Average heart rate of the control group was  $178 \pm 27$ /min; mean respiratory rate was  $39 \pm 5$ /min. In SAH group, the average heart rate had increased to  $342 \pm 28$ /min. In this group, the mean respiratory rate was  $34 \pm 6$ /min. Seven of 11 rabbits with SAH died within the first 2 weeks, likely due to cardiorespiratory complication. Figure 3 shows the anatomical appearance of a rabbit brain with SAH at the base. SAH and vasospastic ASA are shown in Figure 3A. The monitor finding is shown in Figure 3B and histopathological

appearance of a hemorrhagic lung in Figure 3C. In these animals, the heart rate was variable, and bradycardia and tachycardia irregularly occurred. Postmortem examination of all animals of SAH group verified extensive bleeding in the subarachnoid spaces of cisterna magna. Histopathologically, severe ASA and arteriae nervorum vasospasm, axonal and neuronal degeneration, and neuronal apoptosis were observed [Figure 4]. Figure 4 shows the anatomical appearance of a rabbit's spinal cord with SAH. Apoptotic neurons were seen among the NN of C7 DRG in Figure 4. The mean VSIs of groups were estimated as  $0.988 \pm 0.131$  in the control group and  $1.589 \pm 0.632$  in the sham group and  $2.198 \pm 0.721$  in the study group. The mean axon numbers in C6–C8 roots were as  $22.464 \pm 3.731/\text{mm}^2$  and degenerated axon numbers in C6–C8 roots of normal, sham, and study groups were estimated as  $8.50 \pm 1.61/\text{mm}^2$ ,  $75.23 \pm 9.61/\text{mm}^2$ ,  $831.45 \pm 103.64/\text{mm}^2$ , consecutively. The mean live neuron numbers in C6–C8 DRG ganglions were  $18.345 \pm 2.987/\text{mm}^3$ ; the mean DN densities of C6–C8 DRG of normal, SHAM, and study groups were  $19.32 \pm 4.41/\text{mm}^3$ ,  $512 \pm 43.32/\text{mm}^3$ , and



**Figure 2:** Anatomical appearance of a rabbit brain of control group at the base. Anterior spinal artery is seen in A (LM: H and E,  $\times 10$ ; E: Endothelin, IEM: Inner elastic membrane). A normal lung with pulmonary artery (PA), lymph node (LN), alveoli (A) and bronchiole (Br) in C (LM, H&E,  $\times 10$ ), Monitor finding is seen in B, and a normal lung with pulmonary artery in C

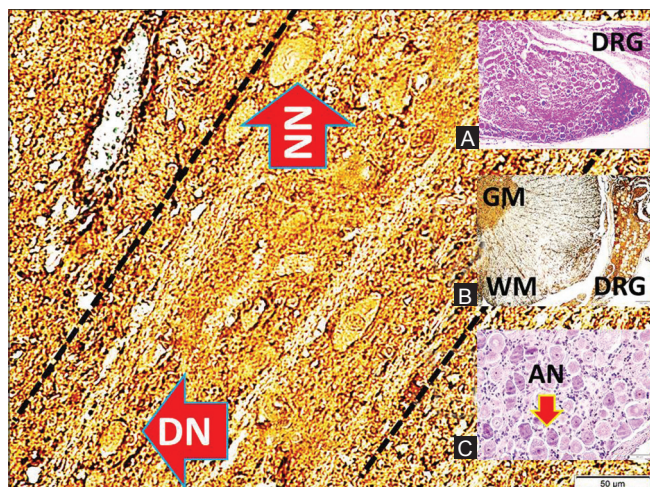


**Figure 3:** Anatomical appearance of a rabbit brain with subarachnoid hemorrhage at the base. Subarachnoid hemorrhage and vasospastic anterior spinal artery are seen in A (LM: H and E,  $\times 10$ ; E: Endothelin, IEM: Inner elastic membrane, SAH: Subarachnoid hemorrhage). Monitor finding is seen in B and histopathological appearance of a hemorrhagic lung is seen in C (PA: Pulmonary artery, BR: Bronchiole, Star: Hemorrhage)

**Table 1: Mean vasospasm indexes of anterior spinal artery, degenerated axon numbers, and neuron densities of C6–C8 in three groups**

	Mean vasospasm indexes of ASA	Degenerated axon numbers in C6–C8 roots	The mean degenerated neuron densities of C6–C8 DRG
Control groups	10.988±0.131	8.50±1.61/mm <sup>2</sup>	93±12 cm <sup>3</sup>
SHAM (serum saline) group	1.589±0.632	75.23±9.61/mm <sup>2</sup>	121±26 cm <sup>3</sup>
SAH group	2.198±0.721	831.45±103.64/mm <sup>2</sup>	176±49 cm <sup>3</sup>

ASA - Anterior spinal artery, DRG - Dorsal root ganglions, SAH - Subarachnoid hemorrhage



**Figure 4: Anatomical appearance of a rabbit spinal cord with subarachnoid hemorrhage at the base (LM: S-100, ×4; NN: Normal motor neuron, DN: Degenerated motor neuron). C7 dorsal root ganglion and degenerated neurons are seen in A (LM: H and E, ×10). Spinal cord (LM: S-100, ×10; GM: Gray matter, WM: White matter) and C7 dorsal root ganglion are seen in B. Apoptotic neurons are seen among the normal neuron of C7 dorsal root ganglion is seen in C. (LM: H and E, ×10)**

6421 ± 1.112/mm<sup>3</sup>, consecutively. Vasospasm of ASA caused to numerous axon and neuron degenerations in cervical DRG compartments in SAH group, animals with ASA vasospasm showing prominent DN densities in C6–C8 roots, DRG neurons. Respiratory rhythm disturbances, arrest, and lung edema occurred more commonly in these animals than in the control and SHAM groups. Vasospasm of ASA was not seen in the SS and control groups. The living neuron density was statistically significantly reduced in the SAH group compared to the control and SS groups ( $P < 0.05$ ). In stereological examinations, to estimate ASA of VSI, squared-lined glass plates were used while photographs were taken under microscope during the histopathological examinations of the ASA. The mean VSI of PAs was 0.722 ± 0.044 in the control group. The mean VSI of PAs was 1.642 ± 0.070 in the SAH group. Table 1 shows mean vasospasm indexes of ASA, degenerated axon numbers and neuron densities of C6–8 in three groups.

## Discussion

Spinal blood flow may be disturbed by SAH. In this study, the comparison of ASA vasospasm index and the histopathological

changes of the C6–C8 DRG and the lung led to the following conclusions: (a) The number of DNs in the C6–C8 DRG was higher in the animals that developed unexplained sudden death than in those in the control and SHAM groups. (b) In addition, animals that developed sudden death had increased ASA VSIs. Vasospasm following SAH degenerates the axons of the C6–C8 spinal nerve roots and the DRG due to the deprivation from the bloodstream. In addition, after rupture of a cerebral aneurysm, a high concentration of blood products accumulates in the subarachnoid space leading to meningeal irritation and ultimately arachnoiditis.<sup>[1]</sup> An extremely rare complication of aneurysmal SAH is delayed spinal arachnoiditis that can occur months to years after the causative SAH.<sup>[1]</sup> Onder *et al.* also demonstrated that SAH produces arachnoiditis and degenerates the axons of the spinal nerve roots due to ischemia, which is induced by vasospasm.<sup>[14]</sup> Although recent advances in the medical and surgical treatment of spinal lesions have led to better outcomes, adhesive arachnoiditis is still one of the most serious conditions.<sup>[15]</sup> Having broad knowledge of anatomy is essential for practicing neurosurgery. Certain anatomical structures call for detailed study due to their functional importance.<sup>[16,17]</sup> One of these structures is DRG because information from spinal afferents arrives in the central nervous system through the DRG.<sup>[2]</sup> SAH may cause descending neurodegeneration from the cortex to the DRG. This degeneration may be reason of sudden death of rabbits in this study. The effect of SAH on the neuronal and ganglionic cell changes has been the focus of much investigation.<sup>[10,16-18]</sup> Neuronal dysfunction occurs after SAH and contributes to the high morbidity and mortality. One problem with neurointensive care is that the diagnosis is often first made at the onset of neurological ischemic deterioration, precluding timely application of the preischemic treatment necessary for prevention of subsequent clinical deficits.<sup>[19]</sup> Our findings may be explained by ASA vasospasm, which may be responsible for the sudden death of animals because upper cervical ganglions innervate the anterior spinal arteries.<sup>[20]</sup> SAH can also cause respiratory arrest, which may result from severe brain edema and lesions to the respiratory centers in the first few days following the brain hemorrhage. While injury to the respiratory centers may result in respiratory arrest in

SAH, the results from the current study indicate that SAH not only causes crushing injury to the respiratory centers but also results in degeneration of C6–C8 DRG.

### Concluding remarks and clinical implications of the present study

Prompt management of aneurysmal SAH is important. Intensivists should be familiar with the complications of SAH. He/she devotes a considerable portion of each day to attempting to determine the neurological status of critically ill patients through the use of clinical examination. The most meaningful way to follow a traumatic or nontraumatic brain-injured patient in the Intensive Care Unit is to perform serial bedside neurological examinations. Unfortunately, with high-grade SAH, there is no examination to follow - the patient may remain completely comatose for days or weeks, and the only valuable clinical finding of any portent may be that of intact brainstem reflexes.<sup>[21]</sup> Cardiac and pulmonary complications following SAH are still common and a major cause of morbidity and mortality<sup>[22]</sup> and negatively affect overall outcome of patients with SAH. Sudden death after SAH is thought to be caused by neurogenic pulmonary edema<sup>[23]</sup> and cardiac complications.<sup>[24,25]</sup> Estanol *et al.* produced experimental SAH in dogs and showed that cardiac changes following SAH were correlated with the sudden increase in the intracranial pressure.<sup>[26]</sup> They also reported that the animals with sections of both vagi and heart sympathetic innervation, but with an intact spinal cord, developed arrhythmias that were delayed and did not correlate with the changes in intracranial pressure.<sup>[26]</sup> Intracranial pressure must be raised acutely to produce these changes. The occurrence of degenerative changes at C6–C8 DRG in this study is probably attributable to the drastic rise of spinal intradural pressure and reduction of spinal blood flow resulting in changes of ASA diameter secondary to increased intracranial pressure. The recognition of this fact is important, if indeed one is the first to report something and that something is of value.<sup>[18,27-29]</sup> Given the high frequency of sudden death following SAH, it is important for intensive care physicians to become familiar with their pathophysiology, allowing for more prompt and appropriate treatment of SAH patients. In some contexts, red flags mean that something important needs to be brought to immediate attention.<sup>[6]</sup> The present study may provide a red flag and added dimension to the pathophysiologic basis of sudden death of patients with SAH in critical care unit. The findings of our study suggest that new management strategies for cervical spine at early stages after SAH for minimizing cardiopulmonary arrest are required to effectively alter the clinical course of this disease. In particular, our results highlight the need for the identification of modifiable risk factors.

### Limitation of the study

Several limitations of this study deserve mention. We stated that cardiorespiratory dysfunction and sudden death occurred in animals with ASA vasospasm and degeneration C6–C8 DRGs following SAH [Figures 2-4], ECG changes, and abnormal histopathological pulmonary pictures were obtained; however, these disturbances were not quantified because the aim of this study is not to show these changes following SAH in rabbits. Another important limitation is that our experimental rabbit model of SAH may not accurately mimic the human disease process.<sup>[8,17,24,30]</sup> It cannot faultlessly represent a human spinal SAH model. However, our study will promote further studies on this subject.

### Conclusion

Neurocardiopulmonary interaction has many dimensions, but it may be conceptualized as divided into two major categories: The heart's and lung's effects on the brain, and the brain's effects on the heart and lungs. In this study, we found that ASA vasospasm with C6–C8 DRG degeneration after SAH may be considered an important factor in such cardiopulmonary disturbances and sudden death. The cause, ultimate clinical importance, and treatment of the brain-heart-lung connection in pathological states remain to be elucidated. We hope that with better understanding of this interaction, we will be able to mitigate harm to the heart and lungs. This line of research will likely shape future efforts to further understand the pathophysiology of cardiac and pulmonary damage after SAH and identify targets for clinical intervention. Larger studies are warranted to confirm our hypotheses.

### Acknowledgment

We would like to express our special gratitude and thanks to David Edson Marshall for giving time for English edition of the manuscript.

### Financial support and sponsorship

Nil.

### Conflicts of interest

There are no conflicts of interest.

### References

1. Abel TJ, Howard MA 3<sup>rd</sup>, Menezes A. Syringomyelia and spinal arachnoiditis resulting from aneurysmal subarachnoid hemorrhage: Report of two cases and review of the literature. *J Craniovertebr Junction Spine* 2014;5:47-51.
2. Ozturk C, Kanat A, Aydin MD, Yolas C, Kabalar ME, Gundogdu B, *et al.* The impact of L5 dorsal root ganglion degeneration and Adamkiewicz artery vasospasm on descending colon dilatation following spinal

- subarachnoid hemorrhage: An experimental study; first report. *J Craniovertebr Junction Spine* 2015;6:69-75.
3. Balik MS, Kanat A, Erkut A, Ozdemir B, Batcik OE. Inequality in leg length is important for the understanding of the pathophysiology of lumbar disc herniation. *J Craniovertebr Junction Spine* 2016;7:87-90.
  4. Kanat A, Yazar U, Ozdemir B, Coskun ZO, Erdivanli O. Frontal sinus asymmetry: Is it an effect of cranial asymmetry? X-ray analysis of 469 normal adult human frontal sinus. *J Neurosci Rural Pract* 2015;6:511-4.
  5. Kazdal H, Kanat A, Findik H, Sen A, Ozdemir B, Batcik OE, et al. Transorbital ultrasonographic measurement of optic nerve sheath diameter for intracranial midline shift in patients with head trauma. *World Neurosurg* 2016;85:292-7.
  6. Kazdal H, Kanat A, Sen A, Kirbas S, Ardic G, Tufekci A, et al. A novel clinical observation in neuroleptic malignant-like syndrome: First demonstration of early progression of hydrocephalus. *J Clin Psychopharmacol* 2015;35:211-2.
  7. Akca N, Ozdemir B, Kanat A, Batcik OE, Yazar U, Zorba OU. Describing a new syndrome in L5-S1 disc herniation: Sexual and sphincter dysfunction without pain and muscle weakness. *J Craniovertebr Junction Spine* 2014;5:146-50.
  8. Kanat A, Turkmenoglu O, Aydin MD, Yolas C, Aydin N, Gursan N, et al. Toward changing of the pathophysiologic basis of acute hydrocephalus after subarachnoid hemorrhage: A preliminary experimental study. *World Neurosurg* 2013;80:390-5.
  9. Kanat A. Pathophysiology of acute hydrocephalus after subarachnoid hemorrhage. *World Neurosurg* 2014;82:e386-7.
  10. Kanat A, Yilmaz A, Aydin MD, Musluman M, Altas S, Gursan N. Role of degenerated neuron density of dorsal root ganglion on anterior spinal artery vasospasm in subarachnoid hemorrhage: Experimental study. *Acta Neurochir (Wien)* 2010;152:2167-72.
  11. Gundersen HJ, Bendtsen TF, Korbo L, Korbo L, Marcussen N, Møller A, et al. Some new, simple and efficient stereological methods and their use in pathological research and diagnosis. *APMIS* 1988;96:379-94.
  12. Gundersen HJ. Stereology of arbitrary particles. A review of unbiased number and size estimators and the presentation of some new ones, in memory of William R. Thompson. *J Microsc* 1986;143(Pt 1):3-45.
  13. Sterio DC. The unbiased estimation of number and sizes of arbitrary particles using the disector. *J Microsc* 1984;134(Pt 2):127-36.
  14. Onder A, Serarslan Y, Aydin MD, Kanat A, Gursan N, Yolas C. Spinal arachnoiditis and the axonal degeneration of the spinal nerve roots due to ischemia induced by vasospasm: An experimental study. *J Neurol Sci (Turk)* 2009;26:416-23.
  15. Morisako H, Takami T, Yamagata T, Chokyu I, Tsuyuguchi N, Ohata K. Focal adhesive arachnoiditis of the spinal cord: Imaging diagnosis and surgical resolution. *J Craniovertebr Junction Spine* 2010;1:100-6.
  16. Aydin MD, Kanat A, Turkmenoglu ON, Yolas C, Gundogdu C, Aydin N. Changes in number of water-filled vesicles of choroid plexus in early and late phase of experimental rabbit subarachnoid hemorrhage model: The role of petrous ganglion of glossopharyngeal nerve. *Acta Neurochir (Wien)* 2014;156:1311-7.
  17. Turkmenoglu ON, Kanat A, Yolas C, Aydin MD, Ezirmik N, Gundogdu C. First report of important causal relationship between the Adamkiewicz artery vasospasm and dorsal root ganglion cell degeneration in spinal subarachnoid hemorrhage: An experimental study using a rabbit model. *Asian J Neurosurg* 2016. [Doi: 10.4103/1793-5482.145572].
  18. Ozdemir NG, Aydin MD, Yolas C, Kanat A, Levent A, Gundogdu C, et al. predictive role of external carotid artery vasospasm on cerebral ischemia in subarachnoid hemorrhage: Experimental study. *Turk Neurosurg* 2016. [Doi: 10.5137/1019-5149.JTN.17206-16.2].
  19. Treggiari-Venzi MM, Suter PM, Romand JA. Review of medical prevention of vasospasm after aneurysmal subarachnoid hemorrhage: A problem of neurointensive care. *Neurosurgery* 2001;48:249-61.
  20. Shi TJ, Tandrup T, Bergman E, Xu ZQ, Ulfhake B, Hökfelt T. Effect of peripheral nerve injury on dorsal root ganglion neurons in the C57 BL/6J mouse: Marked changes both in cell numbers and neuropeptide expression. *Neuroscience* 2001;105:249-63.
  21. Lee K, Choi HA, Edwards N, Chang T, Sladen RN. Perioperative critical care management for patients with aneurysmal subarachnoid hemorrhage. *Korean J Anesthesiol* 2014;67:77-84.
  22. Yolas C, Kanat A, Aydin MD, Altas E, Kanat IF, Kazdal H, et al. Unraveling of the effect of nodose ganglion degeneration on the coronary artery vasospasm after subarachnoid hemorrhage: An experimental study. *World Neurosurg* 2016;86:79-87.
  23. Onen MR, Yilmaz I, Ramazanoglu L, Tanriverdi O, Aydin MD, Kanat A, et al. Rational roots of sympathetic overactivity by neurogenic pulmonary edema modeling arising from sympathico-vagal imbalance in subarachnoid hemorrhage: An experimental study. *World Neurosurg* 2016;92:463-70.
  24. Yolas C, Ozdemir NG, Kanat A, Aydin MD, Keles P, Kepoglu U, et al. Uncovering a new cause of obstructive hydrocephalus following subarachnoid hemorrhage: Choroidal artery vasospasm-related ependymal cell degeneration and aqueductal stenosis-first experimental study. *World Neurosurg* 2016;90:484-91.
  25. Aydin MD, Kanat A, Yilmaz A, Cakir M, Emet M, Cakir Z, et al. The role of ischemic neurodegeneration of the nodose ganglia on cardiac arrest after subarachnoid hemorrhage: An experimental study. *Exp Neurol* 2011;230:90-5.
  26. Estanol BV, Loyo MV, Mateos JH, Foyo E, Cornejo A, Guevara J. Cardiac arrhythmias in experimental subarachnoid hemorrhage. *Stroke* 1977;8:440-9.
  27. Ozdemir B, Kanat A, Batcik OE, Gucer H, Yolas C. Ligamentum flavum hematomas: Why does it mostly occur in old Asian males? Interesting point of reported cases: Review and case report. *J Craniovertebr Junction Spine* 2016;7:7-12.
  28. Kanat A, Yazar U, Ozdemir B, Kazdal H, Balik MS. Neglected knowledge: Asymmetric features of lumbar disc disease. *Asian J Neurosurg* 2016. [Doi: 10.4103/1793-5482.145573].
  29. Kanat A, Balik MS, Kirbas S, Ozdemir B, Koksall V, Yazar U, et al. Paradox in the cubital tunnel syndrome – Frequent involvement of left elbow: First report. *Acta Neurochir (Wien)* 2014;156:165-8.
  30. Yolas C, Kanat A, Aydin MD, Ozturk C, Kabalar E, Akca N, et al. The important liaison between the Onuf's nucleus-pudental nerve ganglia complex degeneration and urinary retention in spinal subarachnoid hemorrhage: An experimental study. *World Neurosurg* 2016;89:208-14.