

Clinical value of cardiac color ultrasound and cardiac troponin T combined with dynamic electrocardiogram in treatment of acute pulmonary embolism

HONGJUN LI^{1*}, LIXIN KANG^{2*} and YONGQIANG SUN³

¹Electrocardiograph Room, ²Physical Examination Center and ³Department of Orthopedics, Jinan Zhangqiu District Hospital of Traditional Chinese Medicine, Jinan, Shandong 250200, P.R. China

Received November 16, 2017; Accepted December 12, 2017

DOI: 10.3892/etm.2017.5658

Abstract. The clinical value of cardiac color ultrasound and cardiac troponin T (cTnT) combined with dynamic electrocardiogram in evaluating the treatment effect on acute pulmonary embolism (APE) was investigated. Ninety-eight patients with APE treated in Jinan Zhangqiu District Hospital of TCM from March 2016 to February 2017 were selected, and they were examined via the cardiac color ultrasound, cTnT and dynamic electrocardiogram to evaluate the clinical value in the treatment of pulmonary embolism. Electrocardiogram showed that there was no significant difference in the poor prognosis rate between right ventricular strain group and non-right ventricular strain group ($P>0.05$); the poor prognosis rate in cTnT positive group was significantly higher than that in cTnT negative group ($P<0.05$). Moreover, the ultrasonic cardiogram revealed that the poor prognosis rate in right ventricular dysfunction group was significantly higher than that in non-right ventricular dysfunction group ($P<0.05$). It was found in the receiver operating characteristic (ROC) curve analysis that the areas under the curve (AUC) of ROC detected via cardiac color ultrasound and cTnT were >0.9 , while that detected via dynamic electrocardiogram was <0.7 . Besides, logistic regression analysis showed that cTnT and right ventricular dysfunction were the risk factors affecting the poor prognosis of patients with APE ($P<0.05$). In conclusion, cardiac color ultrasound can predict the prognosis of patients with APE through monitoring the right ventricular function; cTnT can also evaluate the prognosis of APE; but the electrocardiogram has little significance in evaluating the prognosis of APE.

Introduction

Acute pulmonary embolism (APE) is one of the common acute cardiovascular diseases, which belongs to the severest venous thromboembolisms (1). APE is characterized by a high incidence rate, high rates of missed diagnosis and misdiagnosis, and a high mortality rate, ranking third, following stroke and ischemic heart disease, in the cause of death due to the cardiovascular diseases (2). Computed tomographic pulmonary angiography (CTPA) and percutaneous pulmonary angiography are the main diagnostic means of APE, and the timely detection and appropriate treatment, such as thrombolysis and interventional therapy, can save the lives of patients in time to reduce the mortality rate (3-5). Despite of the timely treatment, prognoses vary from patients to patients; the early assessment of prognosis of patients with APE and appropriate treatment according to the assessment results are of great significance in reducing the mortality rate of patients. In this study, 98 patients were examined via the cardiac color ultrasound, cTnT and dynamic electrocardiogram after treatment, so as to assess their clinical value in the treatment.

Materials and methods

General materials. Ninety-eight patients with APE treated in Jinan Zhangqiu District Hospital of TCM from March 2016 to February 2017 were selected and retrospectively analyzed, and they were examined via the cardiac color ultrasound, cTnT and dynamic electrocardiogram. The study was approved by the Ethics Committee of the Jinan Zhangqiu District Hospital of TCM. Inclusion criteria: i) Patients diagnosed as APE via CTPA and percutaneous pulmonary angiography; ii) patients without specific congenital heart disease, heart failure and pulmonary heart disease in the past; iii) patients receiving anticoagulation, thrombolysis or interventional therapy; iv) patients who signed the informed consent. The general characteristics of patients are shown in Table I.

Correspondence to: Dr Yongqiang Sun, Department of Orthopedics, Jinan Zhangqiu District Hospital of Traditional Chinese Medicine, 1463 Xiushui Avenue, Zhangqiu, Jinan, Shandong 250200, P.R. China
E-mail: denlinlin_168@163.com

*Contributed equally

Key words: cardiac color ultrasound, cardiac troponin T, electrocardiogram, acute pulmonary embolism, prognosis

Methods

Treatment. After admission, all patients received anticoagulation, thrombolysis or interventional therapy. After the exclusion of contraindications for anticoagulation,

patients underwent anticoagulant therapy using enoxaparin (1 mg/kg, 2 times/day; manufacturer: Shenzhen Techdow Pharmaceutical Co., Ltd., National Medicine Permission no. H20056846) and the activated partial thromboplastin time (APTT) was monitored and maintained at 1.5-2.5. Patients with severe APE underwent thrombolytic therapy first within 48 h after onset using urokinase (manufacturer: Livzon Pharmaceutical Factory, Livzon Group; National Medicine Permission no. H44020646) and the contraindications for thrombolysis were excluded. Usage: The loading dose of initial intravenous infusion was 4400 IU/kg within 10 min, followed by 4400 IU/kg/h intravenous drip for 12-24 h; APTT was detected once every 2-4 h after administration, and anticoagulant therapy was given when APTT declined to 2 times that of the normal value. The patients with contraindications for thrombolysis received interventional therapy via percutaneous catheter and single catheter-directed thrombolysis.

Cardiac color ultrasound. After treatment, patients underwent color Doppler echocardiography; the left and right ventricular end-diastolic diameters of patients were detected transthoracically using the SONOS-5500 color Doppler instrument (Philips, Amsterdam, The Netherlands; probe frequency, 3.0-4.0 MHz); the ventricular septum motion and peak velocity of blood reflux of tricuspid valve were observed and the pulmonary artery pressure was detected.

Dynamic electrocardiogram. Patients underwent dynamic electrocardiography (voltage, 1 mV/10 mm; chart speed, 25 mm/sec), and the results were independently analyzed by two experienced physicians using the double-blind method without knowing the specific clinical conditions. Agreement was reached by negotiation when the results were not consistent.

cTnT detection. After treatment, 3 ml venous blood was drawn from patients, and cTnT concentration was detected using the immunoturbidimetric method. Relevant kits and COBAS INTEGRA 800 full automatic biochemical analyzer (both from Roche Diagnostics GmbH, Mannheim, Germany) were used for analysis.

Evaluation criteria

The right ventricular dysfunction was detected via cardiac color ultrasound. Evaluation criteria: i) ratio of right/left ventricular end-diastolic diameter >0.6; ii) pulmonary arterial systolic pressure >30 mmHg; iii) left motion of ventricular septum, paradoxical motion of systolic ventricular septum; iv) decreased motor function of right ventricular free wall. Patients meeting any one of the above criteria were diagnosed as the right ventricular dysfunction (6).

Evaluation of right ventricular strain via dynamic electrocardiogram. Diagnostic criteria: S¹Q³T³ and T wave inversion, complete right bundle branch block and right axis deviation (7); the poor prognosis of patients was observed, including thrombosis relapse, mechanical ventilation and cardiopulmonary-cerebral resuscitation, after treatment; the cTnT concentration was detected using the immunoturbidimetric method; cTnT concentration <0.01 ng/ml indicated the negative, while cTnT concentration ≥0.01 ng/ml indicated the positive (8).

Statistical analysis. SPSS 19.0 (SPSS Inc., Chicago, IL, USA) was used for data processing. Measurement data were presented as ratio and Chi-square test was used; and the

Table I. General characteristics of the patients.

Item	Subject (n=98)
Average age (years)	56.78±5.54
Sex (male/female)	48/50
Dyspnea, n (%)	72 (73.69)
Chest pain, n (%)	58 (59.18)
Hemoptysis, n (%)	13 (13.27)
Educational level, n (%)	
Junior high school and below	19 (19.38)
Senior high school and technical secondary school	41 (41.84)
Junior college and below	38 (38.78)

receiver operating characteristic (ROC) curve analysis was used for prognostic prediction. Logistic regression analysis was performed for the influencing factors of poor prognosis. P<0.05 suggested that the difference was statistically significant.

Results

Comparison of poor prognosis of patients. Electrocardiogram showed that there was no significant difference in the poor prognosis rate between right ventricular strain group and non-right ventricular strain group (P>0.05) (Table II).

Comparison of poor prognosis of patients via cardiac color ultrasound. The ultrasonic cardiogram revealed that the poor prognosis rate in right ventricular dysfunction group was significantly higher than that in non-right ventricular dysfunction group (P<0.05) (Table III).

Comparison of poor prognosis between cTnT positive patients and cTnT negative patients. The poor prognosis rate in cTnT positive group was significantly higher than that in cTnT negative group (P<0.05) (Table IV).

Analyses of influencing factors of poor prognosis of APE patients. Logistic regression analysis, with the poor prognosis as the dependent variable and with the patient's age, sex, educational level, cTnT, right ventricular dysfunction and right ventricular strain as the independent variables, showed that cTnT, cTnT, right ventricular dysfunction and right ventricular strain were used as independent variables. Logistic regression analysis showed that cTnT [odds ratio (OR)=1.938, P=0.008] and right ventricular dysfunction (OR=1.846, P=0.012) were the independent risk factors affecting the poor prognosis of patients (P<0.05) (Table V).

Prognostic prediction of APE. The area under the curve (AUC) of ROC detected via cTnT was 0.953, the sensitivity was 95.2% and the specificity was 96.7%; the AUC detected via cardiac color ultrasound was 0.925, the sensitivity was 90.6% and the specificity was 92.5%; the AUC detected via dynamic electrocardiography was 0.684, the sensitivity was 70.6% and the specificity was 62.5% (Fig. 1).

Table II. Poor prognoses in right ventricular strain group and non-right ventricular strain group [n (%)].

Group	n	Thrombosis relapse	Mechanical ventilation	Cardiopulmonary-cerebral resuscitation	Poor prognosis rate
Right ventricular strain group	46	7 (15.22)	13 (28.26)	9 (19.57)	29 (63.04)
Non-right ventricular strain group	52	8 (15.38)	15 (28.84)	11 (21.15)	34 (65.38)
χ^2					0.001
P-value					0.975

Table III. Poor prognoses in right ventricular dysfunction group and non-right ventricular dysfunction group [n (%)].

Group	n	Thrombosis relapse	Mechanical ventilation	Cardiopulmonary-cerebral resuscitation	Poor prognosis rate
Right ventricular dysfunction group	50	11 (22.00)	18 (36.00)	15 (30.00)	44 (88.00)
Non-right ventricular dysfunction group	48	4 (5.73)	10 (20.83)	5 (10.42)	19 (39.58)
χ^2					22.940
P-value					<0.001

Table IV. Poor prognoses in cTnT positive group and cTnT negative group [n (%)].

Group	n	Thrombosis relapse	Mechanical ventilation	Cardiopulmonary-cerebral resuscitation	Poor prognosis rate
cTnT positive	51	12 (23.53)	20 (39.22)	13 (25.49)	45 (88.24)
cTnT negative	47	3 (6.38)	8 (17.02)	7 (14.89)	18 (38.30)
χ^2					24.436
P-value					<0.001

cTnT, cardiac troponin T.

Table V. Logistic regression analysis of influencing factors of poor prognosis of APE patients.

Factor	β	SE	Wald	OR	95% confidence interval (CI)	P-value
Age (years)	0.336	0.408	3.705	0.732	0.373-0.872	0.218
Sex	0.417	0.507	4.152	0.346	0.124-0.789	0.312
Educational level	0.269	0.608	5.027	0.273	0.156-0.658	0.174
cTnT	0.915	0.804	6.495	1.938	1.196-3.516	0.008
Right ventricular strain	0.426	0.649	5.757	0.817	0.475-0.952	0.104
Right ventricular dysfunction	1.103	0.717	8.024	1.846	1.113-2.347	0.012

cTnT, cardiac troponin ; APE, acute pulmonary embolism.

Discussion

APE is a general term for clinical syndrome of pulmonary arterial embolization, including the fat embolism syndrome, pulmonary thromboembolism, air embolism and amniotic fluid embolism, among which pulmonary thromboembolism is the most common one, causing respiratory dysfunction and pulmonary circulation disorders (9,10). The clinical manifestations

of APE are atypical, and there is often no symptom, but it is similar to the symptoms of acute heart failure, pleurisy, pneumonia and chronic obstructive pulmonary disease, manifested as shortness of breath, dyspnea, angina, pleural inflammatory pain, hemoptysis, cardiogenic shock or sudden death; some patients will suffer from dyspnea, hemoptysis and chest pain, thus easily leading to missed diagnosis or misdiagnosis of APE, and challenging the timely treatment (11,12). Studies

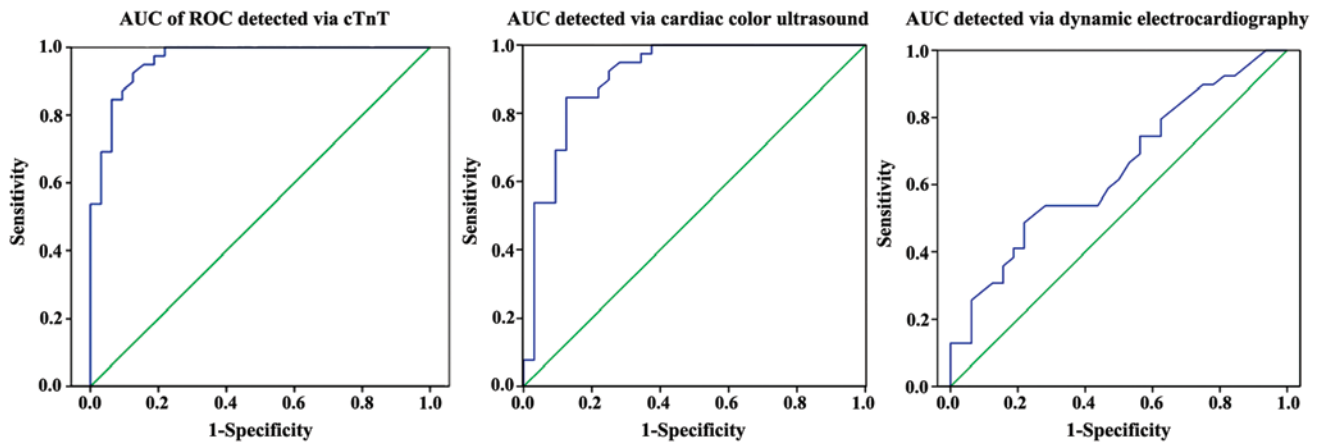


Figure 1. Prognostic prediction of acute pulmonary embolism (APE) via cardiac troponin T (cTnT), cardiac color ultrasound and dynamic electrocardiogram. receiver operating characteristic (ROC) curve analysis shows that the areas under the curve (AUC) detected via cardiac color ultrasound and cTnT are >0.9 , while that detected via dynamic electrocardiogram is <0.7 .

have shown that the mortality rate of APE patients without treatment will be $>30\%$ (13). Timely treatment of APE and evaluation of its treatment via appropriate methods have a great guiding significance in the prognosis of APE.

Clinically, APE patients are treated with anticoagulation, thrombolysis or interventional therapy (14). Once suspected as APE, patients can receive anticoagulant therapy before the definite diagnosis; in particular, conservative anticoagulant therapy can be given for those low-risk and intermediate-risk APE patients with triad syndrome. However, some patients with right ventricular dysfunction need to undergo thrombolytic therapy, so as to reduce the arterial pressure and reverse the right heart failure, effectively improving the hemodynamics (15). Those patients receiving failed thrombolysis or high-risk APE patients with thrombolytic contraindications can receive an alternative approach of interventional therapy, so as to reverse the cardiac shock or right heart failure (16).

The dynamic electrocardiogram monitoring of APE patients shows that the right ventricular strain is complicated, because the pulmonary embolism involves the pulmonary artery and right ventricle, which is manifested as $S_1Q_3T_3$, T wave inversion, complete right bundle branch block and right axis deviation in the electrocardiogram (17). In this study, electrocardiogram showed that there was no significant difference in the poor prognosis rate between right ventricular strain group and non-right ventricular strain group ($P>0.05$). Logistic regression analysis showed that the right ventricular strain was not an independent risk factor affecting the prognosis of patients; at the same time, the AUC detected via dynamic electrocardiogram was <0.7 (0.684), indicating that its sensitivity is lower in predicting the prognosis of patients, which may be related to the lower specificity of electrocardiogram in predicting the increased right ventricular load.

Ultrasonic cardiogram can directly detect the right and left ventricular end-diastolic diameters of APE patients, and observe the pulmonary artery pressure, ventricular septum motion and peak velocity of blood reflux of tricuspid valve, so as to know whether the patients are complicated with right ventricular dysfunction. In this study, the ultrasonic cardiogram revealed that the poor prognosis rate in right ventricular

dysfunction group was significantly higher than that in non-right ventricular dysfunction group ($P<0.05$). This is because the thrombosis in patients with APE leads to the increased pulmonary circulation resistance and high pulmonary artery pressure. It can be observed through ultrasonic cardiogram that the right ventricular afterload of patients with right ventricular dysfunction is increased, the right ventricular wall tension is also increased, and the right ventricle is enlarged, thus leading to left motion of ventricular septum and decreased cardiac output, such patients are prone to myocardial infarction, cardiac shock or sudden death, which results in a higher incidence rate of poor prognosis (18). Logistic regression analysis revealed that right ventricular dysfunction ($OR=1.846$) was an independent risk factor affecting the poor prognosis of patients, and the AUC detected via cardiac color ultrasound was >0.8 (0.925), indicating that it has a high sensitivity in prediction, which may be related to the fact that ultrasonic cardiogram can accurately and quickly detect the patient's myocardial damage and cardiac overload, thereby accurately determining whether the right ventricular dysfunction occurs.

cTnT is the main component of actin, a marker that can reflect the cell damage mainly existing in the myofibril thin filament. When the myocardial cells are damaged, the cell membrane permeability will be increased, so that cTnT is released into the blood and can be detected (19). In this study, the poor prognosis rate in cTnT positive group was significantly higher than that in cTnT negative group ($P<0.05$), which may be because the decreased cardiac output in patients with APE leads to the decreased coronary artery perfusion, so the coronary artery contraction and spasm will cause myocardial ischemic necrosis, thus resulting in the increased cTnT concentration; moreover, with the timely and effective treatment, myocardial cells will be gradually restored, so as to reduce the cTnT concentration and improve the prognosis of patients (20). Logistic regression analysis showed that cTnT ($OR=1.938$) was an independent risk factor affecting the poor prognosis of patients, and the AUC detected via cTnT was >0.8 (0.953), suggesting that the sensitivity and specificity of cTnT are higher in the attack and treatment of APE, and cTnT can be used as a predictor of APE prognosis with important clinical value in APE treatment.

In conclusion, electrocardiogram has little significance in the prognosis of APE, while cardiac color ultrasound and cTnT detection have important clinical value in APE treatment, with great guiding significance in prognosis of APE.

References

- Raja AS, Greenberg JO, Qaseem A, Denberg TD, Fitterman N and Schuur JD; Clinical Guidelines Committee of the American College of Physicians: Evaluation of Patients With Suspected Acute Pulmonary Embolism: Best Practice Advice From the Clinical Guidelines Committee of the American College of Physicians. *Ann Intern Med* 163: 701-711, 2015.
- Marti C, John G, Konstantinides S, Combesure C, Sanchez O, Lankeit M, Meyer G and Perrier A: Systemic thrombolytic therapy for acute pulmonary embolism: A systematic review and meta-analysis. *Eur Heart J* 36: 605-614, 2015.
- Meinel FG, Nance JW Jr, Schoepf UJ, Hoffmann VS, Thierfelder KM, Costello P, Goldhaber SZ and Bamberg F: Predictive value of computed tomography in acute pulmonary embolism: Systematic review and meta-analysis. *Am J Med* 128: 747-59.e2, 2015.
- Celik A, Ozcan IT, Gündes A, Topuz M, Pektas I, Yesil E, Ayhan S, Kose A, Camsari A and Cin VG: Usefulness of admission hematologic parameters as diagnostic tools in acute pulmonary embolism. *Kaohsiung J Med Sci* 31: 145-149, 2015.
- Jiménez D, de Miguel-Díez J, Guijarro R, Trujillo-Santos J, Otero R, Barba R, Muriel A, Meyer G, Yusen RD and Monreal M; RIETE Investigators: Trends in the Management and Outcomes of Acute Pulmonary Embolism: Analysis from the RIETE registry. *J Am Coll Cardiol* 67: 162-170, 2016.
- Perros F, Ranchoux B, Izikki M, Bentebbal S, Happé C, Antigny F, Jourdon P, Dorfmueller P, Lecerf F, Fadel E, *et al*: Nebivolol for improving endothelial dysfunction, pulmonary vascular remodeling, and right heart function in pulmonary hypertension. *J Am Coll Cardiol* 65: 668-680, 2015.
- Bharti S: Assessment of right ventricular dysfunction in COPD patients with electrocardiography and echocardiography. *J Assoc Physicians India* 64: 67, 2016.
- Sedaghat-Hamedani F, Kayvanpour E, Frankenstein L, Mereles D, Amr A, Buss S, Keller A, Giannitsis E, Jensen K, Katus HA, *et al*: Biomarker changes after strenuous exercise can mimic pulmonary embolism and cardiac injury - a metaanalysis of 45 studies. *Clin Chem* 61: 1246-1255, 2015.
- Elf JE, Jögi J and Bajc M: Home treatment of patients with small to medium sized acute pulmonary embolism. *J Thromb Thrombolysis* 39: 166-172, 2015.
- Gao XM, He R, Guan JF and Tian L: Effects of heparin catheter-sealing solution for implantable venous access ports on D-dimer levels in older cancer patients. *Eur Rev Med Pharmacol Sci* 21 (Suppl 3): 97-101, 2017.
- Bajaj A, Rathor P, Sehgal V, Kabak B, Shetty A, Al Masalmeh O and Hosur S: Prognostic value of biomarkers in acute non-massive pulmonary embolism: A systematic review and meta-analysis. *Lung* 193: 639-651, 2015.
- Pontana F, Henry S, Duhamel A, Faivre JB, Tacelli N, Pagniez J, Remy J and Remy-Jardin M: Impact of iterative reconstruction on the diagnosis of acute pulmonary embolism (PE) on reduced-dose chest CT angiograms. *Eur Radiol* 25: 1182-1189, 2015.
- Ende-Verhaar YM, Cannegieter SC, Vonk Noordegraaf A, Delcroix M, Pruszczyk P, Mairuhu AT, Huisman MV and Klok FA: Incidence of chronic thromboembolic pulmonary hypertension after acute pulmonary embolism: A contemporary view of the published literature. *Eur Respir J* 49: 1601792, 2017.
- Wärntges S and Konstantinides SV: Progress in the management of acute pulmonary embolism. *Curr Opin Pulm Med* 21: 417-424, 2015.
- Wang Y, Li Q, Wang J, Zhuang QK and Zhang YY: Combination of thrombolytic therapy and neuroprotective therapy in acute ischemic stroke: Is it important? *Eur Rev Med Pharmacol Sci* 19: 416-422, 2015.
- Avgerinos ED and Chaer RA: Catheter-directed interventions for acute pulmonary embolism. *J Vasc Surg* 61: 559-565, 2015.
- Kukla P, McIntyre WF, Fijorek K, Długopolski R, Mirek-Bryniarska E, Bryniarski KL, Jastrzębski M, Bryniarski L and Baranchuk A: T-wave inversion in patients with acute pulmonary embolism: Prognostic value. *Heart Lung* 44: 68-71, 2015.
- Khemasuwan D, Yingchoncharoen T, Tunsupon P, Kusunose K, Moghekar A, Klein A and Tonelli AR: Right ventricular echocardiographic parameters are associated with mortality after acute pulmonary embolism. *J Am Soc Echocardiogr* 28: 355-362, 2015.
- Dupuy AM, Sebbane M, Roubille F, Coste T, Bargnoux AS, Badiou S, Kuster N and Cristol JP: Analytical evaluation of point of care cTnT and clinical performances in an unselected population as compared with central laboratory highly sensitive cTnT. *Clin Biochem* 48: 334-339, 2015.
- Hakemi EU, Alyousef T, Dang G, Hakmei J and Doukky R: The prognostic value of undetectable highly sensitive cardiac troponin I in patients with acute pulmonary embolism. *Chest* 147: 685-694, 2015.



This work is licensed under a Creative Commons Attribution-NonCommercial-NoDerivatives 4.0 International (CC BY-NC-ND 4.0) License.