

# Effect of Vaginal Estriol Use in Total Laparoscopic Hysterectomy with Gonadotropin-Releasing Hormone Agonist Therapy

Go Hirata<sup>1</sup>, Hiroshi Yoshida<sup>2</sup>, Atsuko Furuno<sup>1</sup>, Masakazu Kitagawa<sup>1</sup>, Hideya Sakakibara<sup>1</sup>

<sup>1</sup>Department of Gynecology, Yokohama City University Medical Center, <sup>2</sup>Departments of Gynecology and Obstetrics, Yokohama Municipal Citizen's Hospital, Yokohama, Kanagawa, Japan

## Abstract

**Study Objectives:** The aim of this study is to evaluate the effects of vaginal estriol therapy in total laparoscopic hysterectomy (TLH) with gonadotropin-releasing hormone agonist (GnRH-a) treatment.

**Design:** Retrospective analysis.

**Design Classification:** Canadian Task Force classification II-2.

**Settings:** Department of Gynecology, Yokohama City University Medical Center, Japan.

**Methods:** We retrospectively investigated 50 fibroid cases that had TLH with preoperative GnRH-a treatment and compared the surgical outcome with or without vaginal estriol use (1mg). Estriol was used administered for two weeks before TLH.

**Measurements and Main Results:** A total of 12 patients (27%) received vaginal estriol (1 mg) for 14 days before TLH. As a result of vaginal estriol treatment, there were no group differences in uterus size reduction with GnRH-a treatment (22% vs. 15%,  $P = 0.20$ ), uterine removal time through the vagina (12.5 min vs. 18.5 min,  $P = 0.18$ ), rate of vaginal dehiscence (3% vs. 0%,  $P = 0.76$ ) or in the rate of perineal laceration (33% vs. 34%,  $P = 0.55$ ).

**Conclusion:** The use of vaginal estriol treatment before TLH with GnRH-a therapy did not improve surgical outcomes.

**Keywords:** Estriol, gonadotropin-releasing hormone agonist, laparoscopic hysterectomy

## INTRODUCTION

Total laparoscopic hysterectomy (TLH) has been shown to have advantages over abdominal hysterectomy, with more rapid recovery and fewer febrile episodes or wound infections.<sup>[1]</sup> Recently, TLH has been performed in patients with a large uterus weight  $\geq 500$  g,<sup>[2]</sup> as techniques in laparoscopic surgery have become more widespread. However, a unique aspect of TLH is that it may require the removal of a large uterus through small incisions.

Although power morcellators can remove the uterus from the abdomen in a minimally invasive fashion, small fragments may be disseminated.<sup>[3]</sup> Accordingly, in April 2014, the U. S. Food and Drug Administration discouraged power morcellation in minimally invasive hysterectomies due to reports of a higher incidence of undiagnosed sarcoma in women undergoing these procedures.<sup>[4]</sup> Although, in-bag power morcellation could reduce the risk of tissue

dissemination,<sup>[5]</sup> the technique is relatively new with insufficient data regarding its safety and efficacy. However, Balgobin *et al.* in their study reported on the safety of manual morcellation through vagina after laparoscopic hysterectomy with strict attention to the preoperative workup for the detection of occult malignancy.<sup>[6]</sup> With counseling to the patients, our institution usually removes the uterus with manual morcellation through the vagina.

Gonadotropin-releasing hormone agonist (GnRH-a) is sometimes used to facilitate TLH by reducing the uterine size, resulting in shorter operating time, and less blood loss.<sup>[7]</sup> Although uterine shrinkage induced by GnRH-a facilitates

**Address for correspondence:** Dr. Go Hirata,

Department of Gynecology, Yokohama City University Medical Center,  
4-57 Urafune-Cho, Minami-Ku, Yokohama 232-0024, Kanagawa, Japan.  
E-mail: gh046@yahoo.co.jp

This is an open access journal, and articles are distributed under the terms of the Creative Commons Attribution-NonCommercial-ShareAlike 4.0 License, which allows others to remix, tweak, and build upon the work non-commercially, as long as appropriate credit is given and the new creations are licensed under the identical terms.

**For reprints contact:** reprints@medknow.com

**How to cite this article:** Hirata G, Yoshida H, Furuno A, Kitagawa M, Sakakibara H. Effect of vaginal estriol use in total laparoscopic hysterectomy with gonadotropin-releasing hormone agonist therapy. *Gynecol Minim Invasive Ther* 2018;7:114-8.

### Access this article online

Quick Response Code:



Website:  
www.e-gmit.com

DOI:  
10.4103/GMIT.GMIT\_57\_18

TLH,<sup>[7]</sup> a side effect of GnRH-a is vaginal atrophy, which may cause difficulty in uterine removal through the vagina.

Vaginal estriol therapy is widely used for vulvovaginal atrophy with minimal systemic effects. Thus, we have sometimes administered vaginal estriol to patient undergoing GnRH-a treatment for vaginitis prevention. Vaginal estriol or estradiol therapy for menopausal women leads to the restoration of normal vaginal acidic pH and microflora, thickening of the epithelium, improvement in vaginal cell morphology, increased blood flow to the vagina, increased vaginal secretions, and decreased vaginal dryness.<sup>[8-11]</sup> In addition, perioperative estrogen therapy may promote vaginal wound healing after gynecological surgery.<sup>[12]</sup> A comparison between vaginal cell cytology with and without vaginal estriol therapy in our cases shows thickening of the vaginal epithelium and eosinophilic well-matured cells [Figure 1].

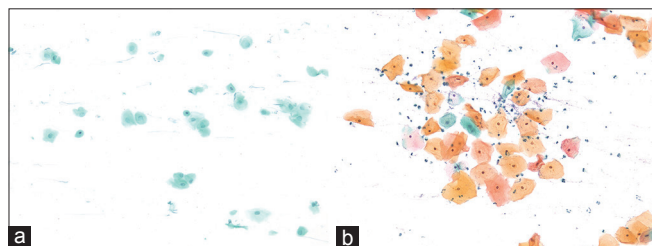
Therefore, we speculated that uterine removal through the vagina might be facilitated by using vaginal estriol before TLH with GnRH-a therapy, preventing perineal laceration and vaginal dehiscence. The aim of the present study was to evaluate the effect of vaginal estriol therapy in TLH with GnRH-a treatment.

## METHODS

### Study population

This study was approved by the Ethics Committee at the Yokohama City University Medical Center. The medical charts of patients undergoing TLH with GnRH-a pretreatment before surgery at the Department of Gynecology, Yokohama City University Medical Center in Japan between July 2014 and December 2016 were retrospectively reviewed. All patients were Asians. All patients who planned to have TLH were screened for uterine malignancy using uterine cervix and endometrial cytology, MRI, ultrasound, and serum lactate dehydrogenase. The patients were counseled regarding treatment choice and the possibility of the spread of occult malignancy during vaginal morcellation.

We compared the background characteristics (age, Body Mass Index, parity), surgical outcome (operative time from incision



**Figure 1:** Vaginal epithelial cells in patients undergoing gonadotropin-releasing hormone agonist with or without vaginal estriol therapy. (Pap stain,  $\times 20$ ) (a) Cells from a 43 years old woman without vaginal E3 during gonadotropin-releasing hormone agonist therapy are shown. (b) Cell from a 44 years old woman with vaginal E3 during gonadotropin-releasing hormone agonist therapy are shown

to closure, uterine removal time, blood loss, intraoperative complications including perineal laceration that needed suture, postoperative complications including vaginal dehiscence), reduction ratio of the fibroid maximum diameter by GnRH-a, serum estradiol and follicle-stimulating hormone (FSH) levels the day before surgery, and the weight of uterus, in patients receiving or not receiving vaginal estriol use (1 mg) before TLH. Patients were excluded for suspected uterine malignancy and a history of estrogen-dependent cancer.

In all cases, leuporelin acetate injections (1.88 mg or 3.75 mg; Takeda Pharmaceutical Co, Ltd., Osaka Japan) were administered as GnRH-a therapy. In patients undergoing estriol therapy, Holin<sup>®</sup>-V (estriol) vaginal tablets (1 mg; ASKA Pharmaceutical Co, Ltd, Tokyo Japan) was used for 14 days.

### Surgical technique

All surgeries were performed by one trained surgeon (H. Y.) with endoscopic surgical skill qualification from the Japan Society of Gynecologic and Obstetric Endoscopy and Minimally Invasive Therapy. In all cases, the specimen was removed through the vagina using surgical scissors.

### Statistical analysis

Data are expressed as medians (ranges) or frequencies (percentages). Group differences for continuous variables were evaluated using Mann–Whitney U-tests. Group differences for categorical variables were evaluated using Fisher’s exact tests. All statistical analyses were performed using Microsoft Excel 2013 (Redmond, WA). A value of  $P < 0.05$  was considered statistically significant.

## RESULTS

A total of 51 cases were identified. However, one patient who had a history of breast cancer was excluded from the analysis; thus, 50 patients were included in the analysis. Vaginal estriol was administered in 12 (24%) cases. Some patients had missing data: missing reduction ratio of fibroid diameter,  $n = 6$ ; missing serum E2,  $n = 29$ ; missing serum FSH,  $n = 29$ ; and missing uterine removal time,  $n = 2$ . The postoperative diagnosis was leiomyoma for all cases, with the exception of two cases of adenomyosis in each group. No cases of complex hyperplasia, atypical hyperplasia, or endometrial carcinoma were observed in either group.

Background characteristics of the 50 TLH patients with GnRH-a treatment are summarized in Table 1. Although there was statistically difference in the mean age (44 years vs. 46 years;  $P = 0.03$ ), no significant group differences were seen for the rate of nullipara (58% vs. 46%;  $P = 0.5$ ), uterine weight (633 g vs. 640 g;  $P = 0.25$ ), or GnRH-a treatment cycle (3 vs. 3,  $P = 0.27$ ).

Table 2 shows a comparison of the main outcomes between the estriol and non-estriol groups. There were no significant group differences in GnRH treatment-related uterus size reduction (22% vs. 15%,  $P = 0.2$ ), uterine removal time through the vagina (18.5 min vs. 12.5 min,  $P = 0.18$ ), vaginal

dehiscence (0% vs. 2.6%,  $P = 0.76$ ), or in the rate of perineal laceration (33% vs. 34%,  $P = 0.55$ ). However, the serum estradiol level was higher in the non-estriol group than in the estriol group (8.6 pg/mL vs. 0 pg/mL,  $P = 0.0078$ ).

No severe intraoperative or postoperative complications, with the exception of a case of postoperative vaginal dehiscence in nonvaginal estriol group, and a case of preoperative fever and abdominal pain in estriol group that was resolved by stopping vaginal estriol administration.

## DISCUSSION

The present study is the first to analyze the effect of the preoperative use of vaginal estriol in TLH with GnRH-a treatment. We hypothesized that uterine removal through the vagina would be facilitated with vaginal estriol therapy, preventing perineal laceration and vaginal dehiscence, as vaginal estriol improve the vaginal environments. In addition, perioperative estrogen therapy may promote vaginal wound healing after gynecologic surgery.<sup>[12]</sup> Vaginal estriol therapy is usually considered safe, with no endometrial effect even after 12 months of vaginal estriol treatment.<sup>[13]</sup>

The results of the present study suggest that the use of vaginal estriol treatment before TLH with GnRH-a therapy does not improve surgical outcomes. This may be a type II error due to the small sample size of the study. In addition, analyses involving surgery for myoma can be difficult; due to a wide range in uterine removal time even when the uterine weight is same because uterine myomas vary in stiffness, numbers, and location. For example, a stiff, single myoma is more difficult to

remove from the abdomen compared to soft, multiple uterine myomas. These problems could be resolved with the inclusion of a high volume of cases; however, as the present study involved a single institution, more cases could not be added.

While add-back therapy with oral low dose estrogen-progestin is also beneficial in preventing hypoestrogenic side effects and in maintaining amenorrhea and reductions in uterine volume,<sup>[14]</sup> no study has yet examined the surgical outcomes for add-back therapy in TLH, focusing on uterine removal through the uterus. Theoretically, preoperative vaginal estrogen therapy is more effective than oral estrogen therapy for improving the vaginal epithelium, with minimal systemic side effects such as thrombosis. In support of this, a previous meta-analysis has shown that vaginal estrogen therapy is significantly more effective than oral estrogen therapy in atrophic vaginitis.<sup>[15]</sup>

Data regarding the patient's symptoms such as vaginal atrophy and vasomotor symptoms were not available in the present study; however, the reported efficacy rate for urogenital symptom improvement is approximately 80%–90% with vaginal therapy and 75% with oral therapy.<sup>[16-19]</sup> Although one case in the estriol group had a fever and abdominal pain, these symptoms disappeared after the patient stopped taking the vaginal estriol of their own volition. As the patient did not come to the hospital for a week after the episode, it was difficult to determine whether the cause of the fever and abdominal pain was the vaginal estriol.

The estradiol level was not suppressed to a menopausal level (<40 pg/mL) in 4/10 patients (40%) in the non-estriol group and 1/11 patients (9%) in the estriol group even while undergoing GnRH-a therapy. The cause of high level of estradiol even with GnRH-a in some cases of the non-estriol group was uncertain. There are a data that the vaginal estriol administration did not increase the level of serum estradiol inpatient under GnRH-a therapy also reported in the previous study,<sup>[18]</sup> or did not affect the fibroids size reduction. The statistically significantly higher serum estradiol level in the non-estriol group might affect the results of the present study negatively.

In the present study, no case of leiomyosarcoma and endometrial cancer were found. Although the possibility of spreading an occult malignancy through vaginal morcellation still exists, theoretically, the possibility of spreading occult malignancy

**Table 1: Background and surgical characteristics of patients stratified by vaginal estriol therapy**

Characteristics	No vaginal estriol (n=38)	Vaginal estriol (n=12)	P
Age (year)	46 (34-55)	44 (38-46)	0.03
BMI (kg/m <sup>2</sup> )	22 (17-29)	23 (18-28)	0.69
Weight of uterus (g)	640 (113-1740)	633 (320-1560)	0.25
Nullipara (%)	20/38 (46)	7/12 (58)	0.5
GnRH-a administration	3 (1-7)	3 (2-11)	0.27

Continuous variables were compared using a nonparametric Mann-Whitney U-test and categorical variables were compared using Fisher's exact test. BMI: Body Mass Index, GnRH-a: Gonadotropin-releasing hormone agonist

**Table 2: Surgical outcomes of patients stratified by vaginal estriol therapy**

Characteristics	No vaginal estriol (n=38)	Vaginal estriol (n=12)	P <sup>†</sup>
Reduction ratio of fibroid diameter (%)	15 (0-49) (n=32) <sup>†</sup>	22 (2-37) (n=11) <sup>†</sup>	0.2
E2 (pg/ml)	8.6 (0-439.4) (n=10) <sup>†</sup>	0 (0-4.5) (n=11) <sup>†</sup>	0.0078
FSH (pg/ml)	6.5 (2.6-11.1) (n=10) <sup>†</sup>	3.7 (0.8-12.3) (n=11) <sup>†</sup>	0.067
Uterine removal time (min)	12.5 (2-84) (n=36) <sup>†</sup>	18.5 (5-46)	0.18
Vaginal dehiscence (%)	1 (2.6)	0	0.76
Perineal laceration (%)	13/38 (34)	4/12 (33)	0.55

<sup>†</sup>Some patients had missing data, Continuous variables were compared using a nonparametric Mann-Whitney U-test and categorical variables were compared using Fisher's exact test. FSH: Follicle-stimulating hormone

might be lower with our technique than with electrical power morcellation. While in-bag power morcellation could reduce the risk of tissue dissemination,<sup>[5]</sup> insufficient data on safety and efficacy exist. By avoiding the use of power morcellation, the device cost is reduced and the prolongation of a 5 mm-port incision to a 12-mm port for the insertion of the power morcellation is unnecessary.

The 14 days duration of vaginal estriol was a little shorter compared with that of previous studies. In the previous studies, the duration of vaginal estriol or estradiol use is usually daily 2–4 weeks, following twice weekly for 10–24 weeks.<sup>[20–24]</sup> Although we thought that the duration of 2 weeks of vaginal estriol use was relatively short, the duration of estradiol suppression expected to be limited to 2–3 months with median of three times of GnRH-a therapy, that was much shorter than that of postmenopausal women whose median age is 70 years in the previous study,<sup>[24]</sup> in the word, around 20 years of estradiol suppression. Moreover, as in this study showed, the comparison between vaginal cell cytology shows thickening of the vaginal epithelium and eosinophilic well-matured cells after 14 days of vaginal estriol therapy.

The main strengths of the present study are that it is the first to analyze the effect of vaginal estriol in TLH with GnRH-a therapy. Although the results suggest that vaginal estriol treatment before TLH with GnRH-a therapy does not improve surgical outcomes, vaginal estriol treatment did not affect fibroids size reduction and can be administered to a patient with vaginitis during GnRH-a therapy. The present study had several limitations. Namely, the sample size was small, and the study was retrospective in nature.

## CONCLUSION

The use of vaginal estriol treatment before TLH with GnRH-a therapy did not improve surgical outcomes; however, vaginal estriol treatment did not affect fibroid size reduction. Vaginal estriol therapy is safe and can be administered it to patients with the vaginal hypoestrogenic symptoms during GnRH-a therapy. Larger-scale studies are needed to investigate the effect of preoperative vaginal estriol therapy in TLH with GnRH-a.

## Financial support and sponsorship

Nil.

## Conflicts of interest

There are no conflicts of interest.

## REFERENCES

1. Aarts JW, Nieboer TE, Johnson N, Tavender E, Garry R, Mol BW, *et al.* Surgical approach to hysterectomy for benign gynaecological disease. *Cochrane Database Syst Rev* 2015;(8):CD003677.
2. Sinha R, Sundaram M, Lakhota S, Mahajan C, Manaktala G, Shah P, *et al.* Total laparoscopic hysterectomy for large uterus. *J Gynecol Endosc Surg* 2009;1:34-9.
3. The American College of Obstetrician and Gynecologists. Power Morcellation and Occult Malignancy in Gynecologic Surgery. Special Report; 2014. Available from: <http://www.acog.org/Resources-And-Publications/Task-Force-and-Work-Group-Reports/Power-Morcellation-and-Occult-Malignancy-in-Gynecologic-Surgery>. [Last accessed on 2014 May 15].
4. Laparoscopic Uterine Power Morcellation in Hysterectomy and Myomectomy: FDA Safety Communication; 2014. Available from: <http://www.fda.gov/MedicalDevices/Safety/AlertsandNotices/ucm393576.htm>. [Last accessed on 2014 Apr 17].
5. Vargas MV, Cohen SL, Fuchs-Weizman N, Wang KC, Manoucheri E, Vitonis AF, *et al.* Open power morcellation versus contained power morcellation within an insufflated isolation bag: Comparison of perioperative outcomes. *J Minim Invasive Gynecol* 2015;22:433-8.
6. Balgobin S, Maldonado PA, Chin K, Schaffer JI, Hamid CA. Safety of manual morcellation after vaginal or laparoscopic-assisted vaginal hysterectomy. *J Minim Invasive Gynecol* 2016;23:542-7.
7. Seracchioli R, Venturoli S, Colombo FM, Bagnoli A, Vianello F, Govoni F, *et al.* GnRH agonist treatment before total laparoscopic hysterectomy for large uteri. *J Am Assoc Gynecol Laparosc* 2003;10:316-9.
8. Manonai J, Chittacharoen A, Theppisai U. Effect of estradiol valerate and levonorgestrel on vaginal health. *Eur J Obstet Gynecol Reprod Biol* 2004;115:190-3.
9. Chollet JA. Efficacy and safety of ultra-low-dose vagifem (10 mcg). *Patient Prefer Adherence* 2011;5:571-4.
10. Santen RJ, Allred DC, Ardoin SP, Archer DF, Boyd N, Braunstein GD, *et al.* Postmenopausal hormone therapy: An endocrine society scientific statement. *J Clin Endocrinol Metab* 2010;95:s1-66.
11. Raz R, Stamm WE. A controlled trial of intravaginal estriol in postmenopausal women with recurrent urinary tract infections. *N Engl J Med* 1993;329:753-6.
12. Vesna A, Neli B. Benefit and safety of 28-day transdermal estrogen regimen during vaginal hysterectomy (a controlled trial). *Maturitas* 2006;53:282-98.
13. Gerbaldo D, Ferraiolo A, Croce S, Truini M, Capitanio GL. Endometrial morphology after 12 months of vaginal oestriol therapy in post-menopausal women. *Maturitas* 1991;13:269-74.
14. Thomas EJ. Add-back therapy for long-term use in dysfunctional uterine bleeding and uterine fibroids. *Br J Obstet Gynaecol* 1996;103 Suppl 14:18-21.
15. Cardozo L, Bachmann G, McClish D, Fonda D, Birgerson L. Meta-analysis of estrogen therapy in the management of urogenital atrophy in postmenopausal women: Second report of the hormones and urogenital therapy committee. *Obstet Gynecol* 1998;92:722-7.
16. Smith P, Heimer G, Lindskog M, Ulmsten U. Oestradiol-releasing vaginal ring for treatment of postmenopausal urogenital atrophy. *Maturitas* 1993;16:145-54.
17. Barnabei VM, Cochrane BB, Aragaki AK, Nygaard I, Williams RS, McGovern PG, *et al.* Menopausal symptoms and treatment-related effects of estrogen and progestin in the women's health initiative. *Obstet Gynecol* 2005;105:1063-73.
18. Long CY, Liu CM, Hsu SC, Wu CH, Wang CL, Tsai EM, *et al.* A randomized comparative study of the effects of oral and topical estrogen therapy on the vaginal vascularization and sexual function in hysterectomized postmenopausal women. *Menopause* 2006;13:737-43.
19. Simunić V, Banović I, Ciglar S, Jeren L, Pavčić Baldani D, Sprem M, *et al.* Local estrogen treatment in patients with urogenital symptoms. *Int J Gynaecol Obstet* 2003;82:187-97.
20. Santen RJ, Pinkerton JV, Conaway M, Ropka M, Wisniewski L, Demers L, *et al.* Treatment of urogenital atrophy with low-dose estradiol: Preliminary results. *Menopause* 2002;9:179-87.
21. Mainini G, Scaffa C, Rotondi M, Messalli EM, Quirino L, Ragucci A, *et al.* Local estrogen replacement therapy in postmenopausal atrophic vaginitis: Efficacy and safety of low dose 17beta-estradiol vaginal tablets. *Clin Exp Obstet Gynecol* 2005;32:111-3.
22. Akrivis Ch, Varras M, Thodos A, Hadjopoulos G, Bellou A, Antoniou N, *et al.* Action of 25 microg 17beta-oestradiol vaginal tablets in the treatment of vaginal atrophy in Greek postmenopausal women; clinical study. *Clin Exp Obstet Gynecol* 2003;30:229-34.
23. Illston JD, Wheeler TL 2<sup>nd</sup>, Parker CR Jr, Conner MG, Burgio KL,

Goode PS, *et al.* Low-dose 17- $\beta$ -estradiol cream for vaginal atrophy in a cohort without prolapse: Serum levels and vaginal response including tissue biomarkers associated with tissue remodeling. *Obstet Gynecol* 2014;124:1147-56.

24. Illston JD, Wheeler TL, Parker CR, Conner MG, Burgio KL, Goode PS, *et al.* Low-dose 17- $\beta$ -estradiol cream for vaginal atrophy in a cohort without prolapse: Serum levels and vaginal response including tissue biomarkers associated with tissue remodeling. *Maturitas* 2015;81:475-9.